Ital. J. Neurol. Sci. 7:613-616, 1986

Choroid plexus papillomas of the cerebellopontine angle in a child

Spallone A., Pastore F.S., Hagi Mao O.
Divisione di Neurochirurgia, Dipartimento di Scienze Neurologiche, Università di Roma "La Sapienza"

An 11-year-old girl was admitted with a 3-year history of decreasing hearing, and headache, occasional vomiting and poor school performance of 8 months duration. Neurologically she showed signs of a cerebellopontine angle mass. This was confirmed by CT scan, which showed an enhancing lesion in the right cerebellopontine angle. The lesion was totally removed, with excellent results. Histologically the tumor appeared to be a choroid plexus papilloma. Choroid plexus papillomas of the cerebellopontine angle are extremely rare in children.

Key-Words: Choroid plexus papilloma — cerebellopontine angle — CT scanning — children

Introduction

Choroid plexus papillomas are uncommon tumors, accounting for 0.3 to 0.7% of all intracranial tumors [1,2,4,8,10,12,16]. These tumors are located in the cerebellopontine angle in 7 to 16% of the instances [6,9,15,26] in adult patients. Cerebellopontine angle papillomas are extremely rare in children. We are aware of only two cases reported in the available literature [9,26]. We recently encountered one such case in a 11-year-old girl. The extreme rarity of this tumor prompted the present report.

Case report

This 11-year-old girl was admitted in May 1984, after a CT scan performed elsewhere had shown an enhancing lesion in the posterior fossa (Fig. 1 a-b).
She complained of decreasing hearing of 3 years duration. This had become more definite 8 months ago, when headache and occasional vomiting appeared and she began to perform poorly at school. On admission the general examination was unremarkable. Neurological examination disclosed a slightly hyporeactive girl, with right hypacusis and horizontal nystagmus. Right dysmetria was also present. No other abnormalities were detected. Fundoscopy was normal. Routine biochemical tests were normal. Skull X-rays pressure, whose protein and cell content was slightly increased.
Operation was performed in the sitting position. The tumor was exposed through a right retromastoid craniectomy and appeared as a purplish-red lobulated mass completely filling the cerebellopontine angle. The main part of the procedure was performed under an operating microscope. Initially the 5th an 6th cranial nerves superiorly, and the 9th-10th-11th cranial nerves and the PICA inferiorly were easily separated from the tumor capsule. Then many fine feeders coming from the AICA were coagulated and divided. The tumor, which seemed to originate from the foramen of Luschka, was removed piecemeal. The 7th and 8th cranial nerves, which were embeddeb in the tumor, were identified proximally and carefully dissected free. This allowed preservation of their anatomical integrity. The tumor was totally removed after clipping of one major feeder coming from the AICA.
Histological examination showed a typical choroid plexus papilloma (Fig. 2). Postoperatively, the child appeared irritable and complained of nasal voice. There was also a worsening of right incoordination. These symptoms disappeared within few weeks. At follow-up one year later the only detectable neurological abnormality was a

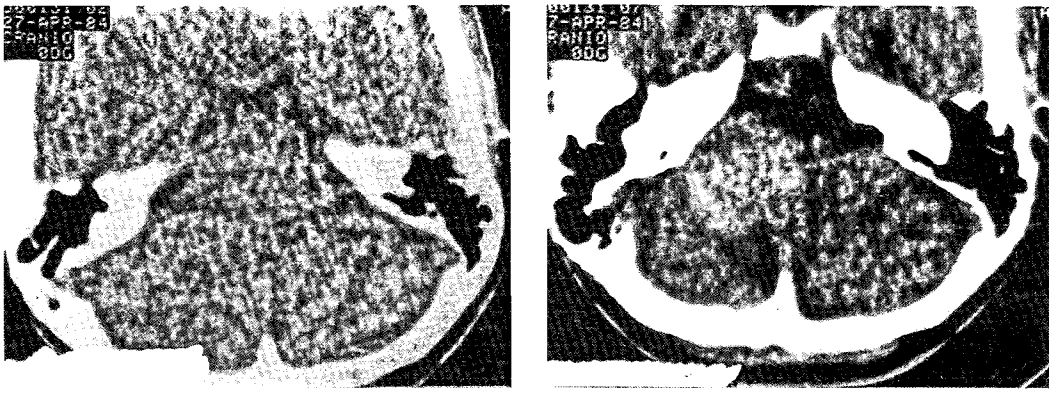

A B

Fig. 1. *CT scan (performed with a second generation scanner)*
A- The precontrast scan shows a lesion of slightly increased density in the right cerebellopontine angle.
B- Following contrast enhancement the lesion appears as a round irregularly-shaped mass of highly increased density.

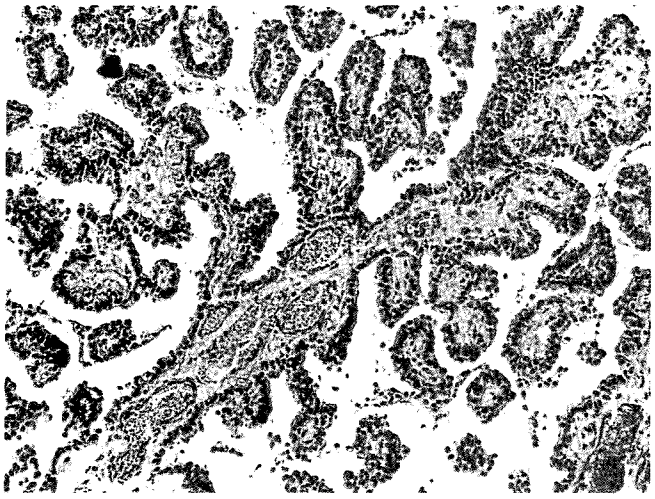

Fig. 2. *Photomicrograph (= 120), of the histological specimen demonstrates a typical choroid plexus papilloma.*

mild horizontal nystagmus to the right.
A control CT (Fig. 3) showed no recurrent tumor.

Discussion

The occurrence of cerebellopontine angle choroid plexus papilloma in infancy is extremely rare, as only two cases are quoted in the literature to date [9,26]. The first, occurring in a 8-years-old girl, was described in detail in 1976 by Hammock et al [9]. The second occurred in a 6-years-old child and was just mentioned by Zhang [26].
Clinical symptoms of papilloma of choroid plexus located in the cerebellopontine angle are not typical, often resembling that of other tumor in the same location such as acoustic neuroma or meningioma [6,7,9,15,26]. Acoustic neuroma has been found, although rarely, in children [23] and was considered a possibility in the present case too.
CT scan examination in the present case was not

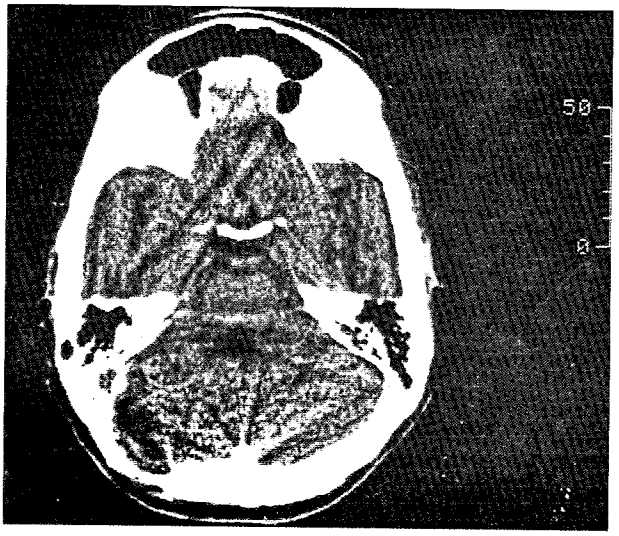

Fig. 3. *Control Ct scan (performed with a GE 9000 scanner, courtesy of the Nuova Clinica Latina, Roma). There are some motion artifacts. No tumor remnants or recurrences are present.*

helpful regarding tumor type. This was due mostly to the fact that the mass did not show a definitely lobulated CT image, as choroid plexus papillomas usually do [10,21]. Angiography may be helpful to the differential diagnosis, as underlined by Zhang [26], who mentioned the angiographic characteristics which he considered typical of cerebellopontine angle: paucity of contribution from the PICA and SCA. In the present case angiography was not performed, at the request of the patient's relatives, mainly because of her age.
The good result in the present case justifies the attempt at radical removal of these lesions. The operating microscope and careful microsurgical technique may allow total removal of papillomas in this location through careful dissection of the surrounding structures, nerves and brainstem vessels, with preservation of their integrity.

There may be some question about the origin of the lesion: should it be considered a spontaneous seeding of a still latent tumor or a direct extension of a fourth ventricle tumor through the foramen of Luschka? [20]. We are unable to give a definite answer but are inclined to think the latter more likely in our case.

Aknowledgement. Professor B. Guidetti, who performed operation in the present case, encouraged the present report by supplying part of the photographic material and offered valuable suggestions to the authors.

Sommario

Una bambina di 11 anni veniva ricoverata per una diminuzione dell'udito in AU dx, iniziata 3 anni prima ed accentuatasi da 8 mesi, quando erano comparsi altri sintomi quali cefalea, saltuari episodi di vomito e diminuzione del livello di rendimento scolastico. All'esame neurologico erano presenti segni di lesione espansiva dell'angolo ponto-cerebellare dx. Una TAC dimostrava una massa iperdensa, che assumeva marcatamente m.d.c., occupante l'angolo ponto-cerebellare dx. L'intervento chirurgico consentiva una rimozione totale della lesione, con eccellenti risultati. Il tumore risultava istologicamente essere un papilloma dei plessi coroidei, la cui localizzazione nell'angolo ponto-cerebellare è estremamente rara nell'infanzia.

Address reprint requests to: Dr. Aldo Spallone
Via Orti Flaviani, 37 - 00147 Roma

References

[1] AICARDI J., GARCIA J., LEPINTRE J., at al: *Les papillomes des plexus choroides chez l'enfant.* Arch. Franc. Ped. 1968, 25: 673-686.

[2] BAILEY P.: *Intracranial tumors.* Charles C. Thomas, Springfield, III 1933.

[3] CARTER LP., BEGGS J., WAGGENER JD.: *Ultrastructure of three choroid plexus papillomas.* Cancer 1972, 30: 1130.

[4] CUSHING H.: *The intracranial tumors of the pre-adolescence.* Am. J. Dis. Child, 1927, 33: 551-584.

[5] CUTLER RWP., PAGE L., GALICKH J.: *Formation and absorption of CSF in man.* Brain, 1968, 91: 707-720.

[6] DEVADIGA KV., ABRAHAM J., CHANDY J.: *Primary choroid plexus papilloma of the cerebellopontine angle.* I. Neurosurg., 1969, 30: 286-288.

[7] FRAIBURN B.: *Choroid plexus papilloma and its relation to hydrocephalus.* J. Neurosurg. 1960, 17: 166-171.

[8] GUIDETTI B., SPALLONE A.: *The surgical treatment of choroid plexus papilloma: the results of 27 years experience.* Neurosurg. Rev., 1981, 4: 129-137.

[9] HAMMOCK MK., MILHORAT T., BRECHBILL DL.: *Primary choroid plexus papilloma of the cerebellopontine angle presenting as brain stem tumor in a child.* Child's Brain, 1976, 2: 132-142.

[10] HAWKINS JC., III: *Treatment of choroid plexus papillomas in children: a brief analysis of twenty years experience.* Neurosurgery, 1980, 6: 380-384.

[11] LAURENCE KM.: *The biology of choroid plexus papilloma and carcinoma of the lateral ventricle.* Handbook of Clinic Neurology, Vinken PJ, Bruin GW, 1974, vol. 17, North Holland Publich. Co., Amsterdam.

[12] MATSON DD.: *Neurosurgery of infancy and childhood.* 2nd Ed., Thomas, Springfield, 1969, p. 934.

[14] MILHORAT TH., HAMMOCK MK., DAVIS DA., et al: *Choroid plexus papillomas I. Proof of CSF overproduction.* Child's Brain, 1976, 2: 273-289.

[15] MORELLO G., MIGLIAVACCA F.: *Primary choroid plexus papillomas in the cerebellopontine angle.* J. Neurol. Neurosurg. Psychiatr., 1964, 27:445-450.

[16] PARAICZ E., SZENASY I.: *Brain tumors in infancy and childhood: a report of 843 treated cases.* Acta Paed. Acad. Scient. Hung., 1981, 22:251-258.

[17] POLIZZI F.· *I papillomi dei plessi corioidei ad estrinsecazione extra-ventricolare; criteri differenziali con i tumori dell'angolo pontocerebellare.* Lav. Neuropsichiatr. 1955, 17: 67-84.

[18] RAIMONDI AJ., GUTIERREZ FA.: *Diagnosis and surgical treatment of choroid plexus papillomas.* Child's Brain, 1975, 1: 81-115.

[19] ROVIT RL., SCHECHTER RM., CODROFF P.: *Choroid plexus papilloma: observations on radiographic diagnosis.* Am. J. Roentgenol., 1970, 110:608-617.

[20] RUSSEL DS., RUBINSTEIN L.S.: *Pathology of tumors of the nervous system.* E. Arnold, London, 1977, 1: 318.

[21] SPALLONE A., GUIDETTI G., MERCURI S. et al: *Choroid plexus papillomas: neuroradiological diagnosis.* Neurochirurgia, 1982, 25: 165-169.

[22] THOMPSON SR., HARWOOD-NASH CR., FITZ CR.: *The neuroradiology of childhood choroid plexus neoplasms.* Am. J. Roentgenol. Rad. Ther. Nucl. Med., 1973, 118: 116-231.

[23] VASSILOUTHIS J., RICHARDSON AE.: *Acoustic neurinoma in a child.* Surg. Neurol., 1979, 12: 37-39.

[24] WILLIS RA.: *Pathology of tumors of children.* Edinburgh, Oliver & Boyd (Eds), 1962.

[25] WILSON CB.: *Diagnosis and surgical treatment of childhood brain tumors.* Cancer, 1975, 35: 950-956.

[26] ZHANG W.: *Choroid plexus papilloma of the cerebellopontine angle, with special reference to vertebral angiographic study.* Surg. Neurol., 1982, 18: 367-371.

[27] ZÜCH KJ.: *Brain tumors: the biology and pathology.* Springer Publish. Co. Inc., New York 1957, 2nd Ed, 1965.