

Immediate and Post-Retention Effects of Rapid Maxillary Expansion Investigated by Computed Tomography in Growing Patients

Fabiana Ballanti^a; Roberta Lione^a; Ezio Fanucci^b; Lorenzo Franchi^c; Tiziano Baccetti^c; Paola Cozza^d

ABSTRACT

Objective: To determine by low-dose computed tomography (CT) protocol the dental and periodontal effects of rapid maxillary expansion (RME).

Materials and Methods: The sample comprised 17 subjects (7 males and 10 females), with a mean age at first observation of 11.2 years. Each patient underwent expansion of 7 mm. Multislice CT scans were taken before rapid palatal expansion (T0), at the end of the active expansion phase (T1), and after a retention period of 6 months (T2). On scanned images, measurements were performed at the dental and periodontal levels. Mean differences between measurements at T0, T1, and T2 were examined through analysis of variance (ANOVA) for repeated measures with post-hoc tests.

Results: All interdental transverse measurements were significantly increased at both T1 and T2 with respect to T0. In the evaluation of T0-T1 changes, periodontal measurements were significant on the buccal aspect of banded teeth with a reduction in alveolar bone thickness corresponding to the mesial (-0.5 mm; $P < .05$) and distal (-0.4 mm; $P < .05$) roots of the right first molar and to the mesial root of the left first molar (-0.3 mm; $P < .05$). In the evaluation of overall T0-T2 changes, the lingual bone plate thickness of both first molars was found to be significantly increased ($+0.6$ mm; $P < .05$).

Conclusions: RME therapy induces a significant increase in the transverse dimension of the maxillary arch in growing subjects without causing permanent injury to the periodontal bony support of anchoring teeth discernible on CT imaging. (*Angle Orthod.* 2009;79:24–29.)

KEY WORDS: Rapid maxillary expansion; Computed tomography; Transverse dimension; Periodontal tissue

INTRODUCTION

The first clinical use of rapid maxillary expansion (RME) was described over a century ago by Emerson C. Angell in 1860.¹ Since then, numerous appliances

have been designed to apply orthopedic forces during expansion, thus limiting movement of teeth and maximizing skeletal displacement. However, a component of orthodontic effects following RME has been described by numerous authors.^{2–11} A relevant concern in this regard is represented by the possible periodontal consequences of RME because of risk of damage to the buccal cortical plate of alveolar bone in the correspondence of anchorage teeth and/or the development of recessions.^{3,4,6,12–15}

Most investigations^{6,7,9–11,14} have analyzed the dentoskeletal effects of RME through bidimensional radiographic examination, which does not allow for exact identification of the thickness of the buccal and lingual bone plates because of the superimposition of many structures on different planes of space. Timms¹⁶ in 1982 used computed tomography (CT) for the first time in studying basal bone changes induced by RME. Scans obtained by CT, a noninvasive and reproducible technique, permit the clinician to quantify exactly the

^a Research Fellow, Department of Orthodontics, University of Rome Tor Vergata, Rome, Italy.

^b Professor, Department of Radiology, University of Rome Tor Vergata, Rome, Italy.

^c Assistant Professor, Department of Orthodontics, University of Florence, Florence, Italy; Thomas M. Graber Visiting Scholar, Department of Orthodontics and Pediatric Dentistry, School of Dentistry, The University of Michigan, Ann Arbor.

^d Professor and Department Chair, Department of Orthodontics, University of Rome Tor Vergata, Rome, Italy.

Corresponding author: Dr Tiziano Baccetti, Department of Orthodontics, University of Florence, Via del Ponte di Mezzo, 46-48, Florence, Italy 50127 (e-mail: t.baccetti@odonto.unifi.it)

Accepted: March 2008. Submitted: January 2008.

© 2009 by The EH Angle Education and Research Foundation, Inc.

dentoalveolar modifications induced by orthopedic forces.¹⁷ Garib et al^{18,19} and Podesser et al²⁰ used this method of investigation recently to evaluate the dentoalveolar effects of RME. RME produced transverse effects in all patients, although dental, alveolar, and skeletal changes varied from subject to subject. These studies were undertaken before or after a very short period of retention. It should be noted that several authors^{2,5,21-24} reported that a retention period of at least 5 months is necessary to permit adequate mineralization of the midpalatal suture, in order to minimize the relapse tendency after rapid maxillary expansion.

The aim of this study was to evaluate with the use of low-dose CT the dental and periodontal changes associated with RME at the end of the active phase and after 6 months of retention in growing patients.

MATERIALS AND METHODS

The study sample comprised 17 white healthy children (7 male and 10 female) with a mean age of 11.2 years (range, 8 to 14 years) who sought orthodontic treatment at the Department of Orthodontics of "Tor Vergata" Dental School, University of Rome. Criteria for selection of the treatment group were as follows: constricted maxillary arches, possible presence of unilateral or bilateral posterior crossbite, variable degree of crowding, and one or both maxillary canines presenting with intraosseous displacement as assessed by panoramic radiography. Exclusion criteria included age older than 15 years, stages in cervical vertebral maturation as assessed on lateral cephalograms more advanced than CS4 (postpubertal),²⁵ absence of maxillary first molars, metallic restorations on the maxillary posterior teeth, previous periodontal disease, previous orthodontic treatment, and genetic disease. CS4 is one of the stages of cervical vertebral maturation: concavities at the lower borders of C2, C3, and C4 now are present. The bodies of both C3 and C4 are rectangular horizontal in shape. The peak in mandibular growth has occurred within 1 or 2 years before this stage.

This project was approved by the Ethical Committee at the University of Rome "Tor Vergata," and informed consent was obtained from parents. Each patient underwent a standardized protocol with RME in the form of the butterfly palatal expander that followed the basic design of Haas. This appliance has a butterfly-shaped stainless steel framework banded and cemented on maxillary first molars that extends forward to the palatal surfaces of deciduous molars²⁶⁻²⁸ (Figure 1).

The expansion screw was activated at two turns per day (0.25 mm per turn) for 14 days, thus reaching the total amount of expansion of 7 mm in all subjects. Then, the screw was tied off with a ligature wire, and

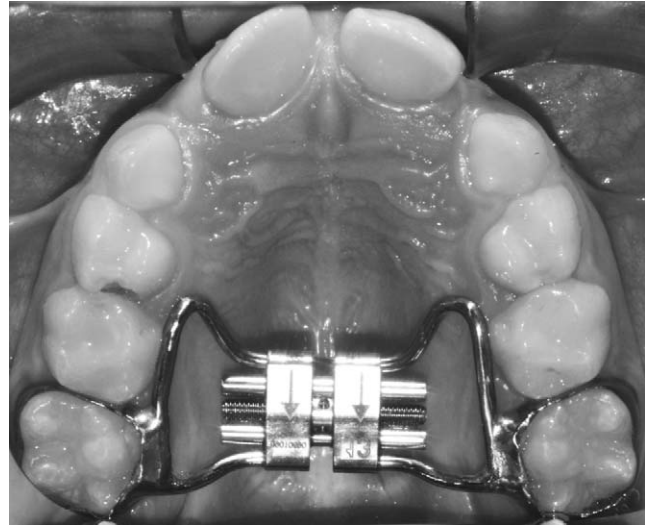


Figure 1. The butterfly rapid maxillary expander.

the butterfly expander was kept on the teeth as a passive retainer for 6 months.

Multislice CT scans were taken before rapid palatal expansion (T0), at the end of the active expansion phase (T1), and after a retention period of 6 months when the expander was removed (T2). All examinations were performed by a single trained radiographer at the same scanner console equipped with a Denta-scan reconstruction program that was used to study the maxillofacial region (Light-Speed 16, General Electric Medical Systems, Milwaukee, Wis). This machine is equipped with 16 detector rows and has a minimal rotation time of 0.5 sec, given a collimation between 0.75 and 1.5 mm with dose calibration. Subsequent scans were taken with a 1.25 mm slice thickness, 0.6 mm interval, and 11.25 mm table speed/rotation, at 100 mA, with a 13.7 cm field of view (FOV), a 512 × 512 matrix, and a 0 degree gantry angle, and following a low-dose protocol with 80 KV instead of the standard CT setting of 120 KV.

On scanned images, measurements were performed at the dental and periodontal levels, according to definitions provided in previous studies by Garib et al^{18,19} and by Podesser et al.²⁰

Dental Measurements on Orthoradially Oriented Images

The scanning plane was perpendicular to the plane of the hard palate, and the slice showed the entire palatal root and crown of the maxillary first molars.²⁰

- Intermolar width apex (IWA): Width between the tooth apices of the palatal root of the first permanent molars (Figure 2).
- Intermolar width crown (IWC): Width between the

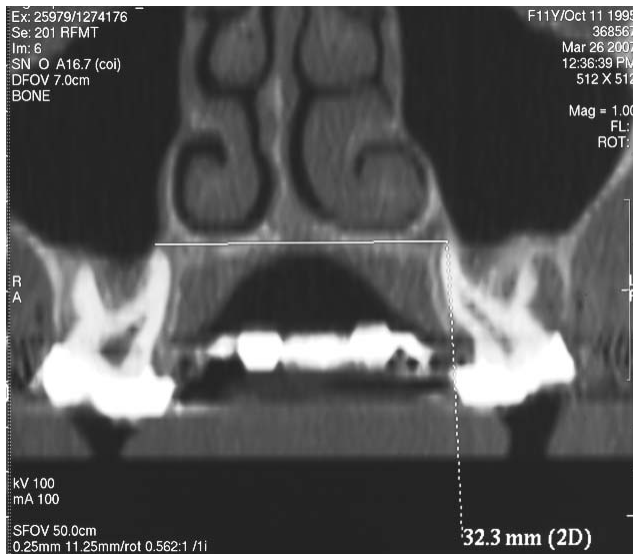


Figure 2. Measurement of intermolar width apex (IWA).

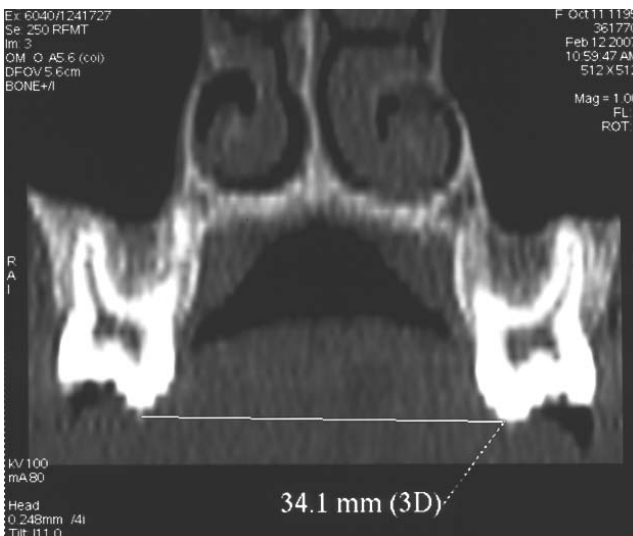


Figure 3. Measurement of intermolar width crown (IWC).

palatal cusp tips of the first permanent molars (Figure 3).

It was possible to evaluate IWC only at T0 and T2 because of the radiographic artifacts produced by the metallic material of the RME at T1.

Periodontal Measurements on Transversely Oriented Images (Figure 4)

The scanning plane was parallel to the palatal plane at the level of the right maxillary first molar furcation.¹⁹

- **Lingual bone plate thickness (LB):** Width between the external aspect of the palatal cortical plate and the center of the palatal aspect of the root of the first molar.

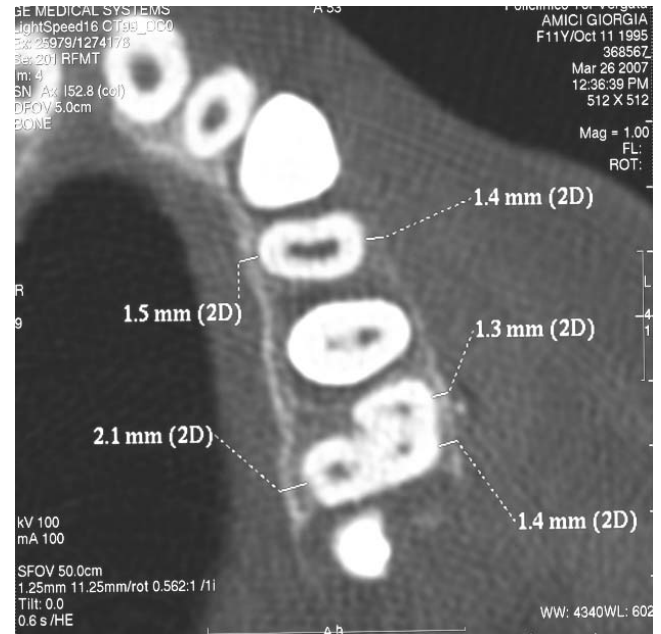


Figure 4. Measurements of lingual and buccal bone plate thicknesses (LB and BB).

- **Buccal bone plate thickness (BB):** Width between the external aspect of the buccal cortical plate and the center of the buccal aspect of mesial and distal roots of the first molars.

Evaluation of buccal and lingual plate thickness was performed on the axial section at the level of the right maxillary first molar furcation. When tooth rotation was present, in order to find standardized points, those measurements were taken by following the transverse diameter of the tooth.

The ratio between IWA and IWC was calculated at T0 and T2 in order to assess the prevalence of RME effects at the level of the crowns of the first molars when compared with effects at the level of the apices of the same teeth.

Statistical Analysis

All measurements were undertaken by two operators (Drs Ballanti and Lione) at the same scanner console, and these were repeated after a month at the same console by one of the two operators (Dr Ballanti). No difficulties were noted in defining identical slices on different CT scans because the method of CT examination and the level of the slices were standardized. The mean values of the four measurements was used for final analysis, as recommended by Baumrind and Frantz.²⁹ Casual and systematic errors were calculated by comparing the values of the measures taken by the two observers, as well as the first and second measurements, with paired *t*-tests and

Table 1. Descriptive Statistics and Statistical Analysis for All Measurements at T0, T1, and T2^{a,b}

	T0		T1		T2		Change, Comparison of Means			
	Mean	SD	Mean	SD	Mean	SD	<i>P</i>	T0-T1	T1-T2	T0-T2
IWA	30.8	2.9	34.4	4.1	35.9	3.6	.003**	.001**	.152	.001**
IWC	38.8	3.3	na	na	44.9	2.7	na	na	na	.001*
LB 16	1.4	0.8	1.4	0.6	2	0.9	.003**	.531	.021*	.030*
LB 26	1.4	1	1.6	0.8	2.1	1	.023*	.795	.046*	.011**
BB 16M	1.7	0.8	1.2	0.9	1.2	0.9	.098	.019*	.682	.081
BB 16D	1.9	0.8	1.5	0.8	1.7	0.8	.076	.044*	.09	.35
BB 26M	1.7	1	1.4	1.1	1.7	0.8	.002**	.009**	.116	.058
BB 26D	2	1.1	1.9	0.9	1.8	0.8	.125	.293	.261	.345
IWA/IWC ratio	0.8	0	na	na	0.8	0	na	na	na	.841

^a Mean differences in measurements at T0, T1, and T2 were examined with Friedman's analysis of variance for repeated measures; Wilcoxon's rank sum test was used only when two consecutive observations were performed (T0-T2).

^b na indicates not available.

* $P < .05$; ** $P < .01$.

IWA: intermolar width apex: width between the tooth apices of the palatal root of the first permanent molars; IWC: intermolar width crown: width between the palatal cusp tips of the first permanent molars; LB: lingual bone plate thickness: width between external aspect of palatal cortical plate and the centre of palatal aspect of root of first molars; BB: buccal bone plate thickness; width between external aspect of buccal cortical plate and the centre of buccal aspect of mesial and distal roots of first molars.

Dahlberg's formula (σ). Correlations between the two operators and between the first and second readings were calculated with Spearman's correlation analysis. Mean differences in measurements at T0, T1, and T2 were contrasted by means of Friedman's analysis of variance (ANOVA) for repeated measures, followed by post-hoc tests. Wilcoxon's rank sum test was used for those variables that presented only two consecutive observations (T0-T2). The level of significance was $P < .05$.

RESULTS

All measurement error coefficients (for interobservers and for repeated measures) were found to be close to 1.00 and within acceptable limits (range, 0.89 to 0.99). In the evaluation of changes between T0 and T1 (Table 1), periodontal measurements were found to be statistically significant on the buccal aspect of banded teeth, but not on the lingual side. On the buccal side, a significant reduction in alveolar bone thickness corresponding to the mesial (BB, 16 M -0.5 mm; $P < .05$) and distal (BB, 16 D -0.4 mm; $P < .05$) roots of the right first molar, and to the mesial root of the left first molar (BB, 26 M -0.3 mm; $P < .05$), was recorded. Of the two areas investigated on the buccal aspect of the first molars, the mesial aspect demonstrated the greatest bone resorption, corresponding to about 0.4 mm. The intermolar width apex was significantly greater at T1 than at T0 (IWA $+3.6$ mm; $P < .01$), and it was increased in all subjects. No root resorption or dehiscence was recorded.

In the evaluation of changes between the end of active expansion (T1) and the end of retention (T2), and of overall T0-T2 changes (Table 1), periodontal

measurements were significant on the lingual aspects, but not on the buccal side. The lingual bone plate thickness of both first molars was significantly increased. Transverse dimensions at the apex level of anchoring teeth did not present any significant changes in the T1-T2 interval, although they were significantly increased at the end of the observation period T2 (IWA $+5.1$; $P < .001$). During the same observation period, a significant increase in intermolar width at the level of the crowns was found (IWC $+6.1$; $P < .001$). No significant differences in the ratio between intermolar widths at the apex and crown levels were found.

DISCUSSION

The objective of the present study was to evaluate the dental and periodontal responses of dentoalveolar structures of the maxillary arch immediately at the end of the active phase of RME and after a 6-month retention period with the use of a low-dose CT protocol. All subjects in the sample examined in the current study underwent three-dimensional (3D) radiographic investigation for visualization of the exact position of displaced canines within the maxillary arch. A low-dose spiral protocol, obtained by reducing the voltage to the lowest possible level of 80 KV, was used. Image quality at the lower kilovoltage remains acceptable for quantitative measurements and for evaluation of bone quality.^{30,31} When milliamperes are kept constant, the radiation dose delivered by an X-ray tube increases, and the X-ray energy, that is, the kilovoltage, increases as well. This effect is largely exploited in diagnostic imaging performed on children, for whom a low radiation dose is required. As X-ray energy (kilovoltage)

decreases, the contrast between structures crossed by the X-ray beam increases.^{32,33}

With regard to previous reports that used CT images of patients who underwent RME,^{18–20,34} the present study investigated a notably larger group of patients (17 patients), and observations were recorded both after active expansion and after an adequate period for retention (6 months), thus allowing for reossification and reorganization of the midpalatal sutural tissue.^{21–24} Moreover, all treated subjects received RME therapy before or during the pubertal growth spurt (stages in cervical vertebral maturation from CS1 to CS4).²⁵ This aspect deserves consideration because it has been demonstrated that the relative amount of dental vs skeletal effect of RME is different in prepubertal vs postpubertal subjects, with prepubertal and pubertal patients showing a higher percentage of skeletal modification.³⁵

After 15 days of RME activation (7 mm of expansion at the level of the screw), all linear transverse measurements were significantly increased. The orthodontic and orthopedic effects of the expansion are demonstrated by an intermolar width apex of 3.6 mm. The value of 3.6 mm reported in our study is greater than the magnitude of 2.0 mm reported by Podesser et al.²⁰ This difference could be related to the different methods of investigation used; in our study sample, we performed the CT examinations immediately at the end of the active phase without removing the expander, whereas Podesser et al²⁰ removed the appliance before performing CT. Thus, we measured the exact amount of expansion without any component of relapse that could result from the time elapsed between the removal of RME and the performance of CT scan.

After the 6-month retention period in all subjects, width dimensions at the molar apex (+5.1 mm) and crown (+6.1 mm) levels increased farther, thus demonstrating an efficient maxillary transverse expansion (RME screw was activated by 7 mm). Maintenance of the pretreatment ratio between apex and crown intermolar widths at the postretention observation indicates that expansion was associated with an effective translatory movement of anchoring teeth within the alveolar bone and with remodeling of the dentoalveolar structures, as demonstrated by previous authors on bidimensional headfilms.^{3,4,6,15,36,37} The average increases observed in both transverse dimensions are of similar magnitude when compared with those (6.8 mm and 7.1 mm) reported by Garib et al¹⁸ in their study.

It has been demonstrated^{38,39} that orthodontic and orthopedic forces cause histologic modifications, such as activation of clastic cells in the direction of the periodontal ligament and hyalinization on the pressure side, and that lateral tipping of anchoring teeth, correlated with the necessity of completing RME therapy

when overcorrection is reached, may cause bone resorption at the dentoalveolar level. Investigators in the present study assessed reductions of 0.4 mm and 0.2 mm in the buccal bone plate thickness of the anchoring teeth (corresponding to the mesial and distal roots, respectively) at the end of the active phase. Despite buccal bone reduction and the absence of corresponding compensatory bone apposition on the lingual aspect, no fenestration, dehiscence, or attachment loss was observed. This finding is consistent with previous observations in which cone beam radiography was used.⁴⁰

After the retention period had ended, statistically significant bone apposition was observed on the palatal side of both anchoring teeth (+0.7 mm; $P < .05$) because of the translation movement of the first molars. These values are about half those reported by Garib et al,¹⁹ probably because of the smaller amount of bone resorption noted on the buccal aspect of the anchoring teeth in the present study. These outcomes in part may be related to the prepubertal or pubertal skeletal maturity of patients in the current study (with a younger pretreatment age than in the study by Garib et al¹⁹) in combination with a retention protocol of adequate duration (6 months), which is necessary for recovery of lingual and buccal bone plate thickness.^{2,5,21–24} In fact, the overall amount of bone loss on the buccal aspect of anchoring teeth in the current study was less than that reported by Garib et al,¹⁹ thus indicating further that a retention period longer than 3 months may be appropriate for recovery of lingual and buccal bone plate thickness.

CONCLUSIONS

- RME produced a significant increase in transverse maxillary dimensions at the crown and apex levels of first molars.
- At the end of the active phase of expansion, the buccal bone plate thickness of the supporting teeth showed a significant decrease; after a retention period of 6 months, recovery of both buccal and lingual plate thickness was observed.

REFERENCES

1. Angell EC. Treatment of irregularity of the permanent or adult teeth. *Dental Cosmos*. 1860;1:540–544.
2. Isaacson RJ, Murphy TD. Some effects of rapid maxillary expansion in cleft lip and palate patients. *Angle Orthod*. 1964;34:143–154.
3. Starnbach HK, Bayne D, Cleall JF, Subtelny DJ. Facio-skeletal and dental changes resulting from rapid maxillary expansion. *Angle Orthod*. 1966;36:152–164.
4. Davis MW, Kronman JH. Anatomical changes induced by splitting of the midpalatal suture. *Angle Orthod*. 1969;39:126–132.

5. Haas AJ. Palatal expansion: just the beginning of dentofacial orthopedics. *Am J Orthod.* 1970;57:219–255.
6. Wertz RA. Skeletal and dental changes accompanying rapid midpalatal suture opening. *Am J Orthod.* 1970;58:41–64.
7. Bishara SE, Taley RN. Maxillary expansion: clinical implications. *Am J Orthod Dentofacial Orthop.* 1987;91:3–14.
8. Sarver DM, Johnston MW. Skeletal changes in vertical and anterior displacement of the maxilla with bonded rapid palatal expansion appliances. *Am J Orthod Dentofacial Orthop.* 1989;95:462–466.
9. Akkaya S, Lorenzon S, Ucem TT. A comparison of sagittal and vertical effects between bonded rapid and slow maxillary expansion procedures. *Eur J Orthod.* 1999;21:175–180.
10. Cross DL, McDonald JP. Effect of rapid maxillary expansion on skeletal, dental, and nasal structures: a postero-anterior cephalometric study. *Eur J Orthod.* 2000;22:519–528.
11. Chung C-H, Flont B. Skeletal and dental changes in the sagittal, vertical, and transverse dimensions after rapid palatal expansion. *Am J Orthod Dentofacial Orthop.* 2004;126:569–575.
12. Handelman CS. Nonsurgical rapid maxillary alveolar expansion in adults: a clinical evaluation. *Angle Orthod.* 1997;67:291–308.
13. Handelman CS, Wang L, BeGole AE, Haas AJ. Nonsurgical rapid maxillary expansion in adults: report on 47 cases using the Haas expander. *Angle Orthod.* 2000;70:129–144.
14. Sandikcioglu M, Hazar S. Skeletal and dental changes after maxillary expansion in the mixed dentition. *Am J Orthod Dentofacial Orthop.* 1997;111:321–327.
15. Haas AJ. Rapid expansion of the maxillary dental arch and nasal cavity by opening the midpalatal suture. *Angle Orthod.* 1961;31:73–90.
16. Timms DJ, Preston CB, Daly PF. A computed tomographic assessment of maxillary induced by rapid expansion—a pilot study. *Eur J Orthod.* 1982;4:123–127.
17. Hatcher DC, Aboudara CL. Diagnosis goes digital. *Am J Orthod Dentofacial Orthop.* 2004;125:512–515.
18. Garib DG, Henriques JFC, Janson G, De Freitas MR, Coelho RA. Rapid maxillary expansion—tooth tissue-borne versus tooth-borne expanders: a computed tomography evaluation of dentoskeletal effects. *Angle Orthod.* 2005;75:548–557.
19. Garib DG, Henriques JFC, Janson G, De Freitas MR, Fernandes AY. Periodontal effects of rapid maxillary expansion with tooth-tissue-borne and tooth-borne expanders: a computed tomography evaluation. *Am J Orthod Dentofacial Orthop.* 2006;129:749–758.
20. Podesser B, Williams S, Crismani AG, Banteleon H-P. Evaluation of the effects of rapid maxillary expansion in growing children using computer tomography scanning: a pilot study. *Eur J Orthod.* 2007;29:37–44.
21. Ekstrom C, Henrickson CO, Jensen R. Mineralization in the midpalatal suture after orthodontic expansion. *Am J Orthod.* 1977;71:449–455.
22. Bell RA. A review of maxillary expansion in relation to rate of expansion and patient's age. *Am J Orthod.* 1982;81:32–37.
23. Mew J. Relapse following maxillary expansion: a study of twenty-five consecutive cases. *Am J Orthod Dentofacial Orthop.* 1983;83:56–61.
24. Bishara SE, Taley RN. Maxillary expansion: clinical implications. *Am J Orthod Dentofacial Orthop.* 1987;91:3–14.
25. Baccetti T, Franchi L, McNamara JA. The cervical vertebrae maturation (CVM) method for the assessment of optimal treatment timing in dentofacial orthopedics. *Semin Orthod.* 2005;11:119–129.
26. Cozza P, Giancotti A, Petrosino A. Butterfly expander for use in the mixed dentition. *J Clin Orthod.* 1999;33:583–587.
27. Cozza P, Giancotti A, Petrosino A. Rapid palatal expansion in mixed dentition using a modified expander: a cephalometric investigation. *J Orthod.* 2001;28:129–134.
28. Cozza P, DeToffol L, Mucedero M, Ballanti F. Use of a modified butterfly expander to increase anterior arch length. *J Clin Orthod.* 2003;37:490–495.
29. Baumrind S, Frantz RC. The reliability of head films measurements: landmark identification. *Am J Orthod.* 1971;60:111–127.
30. Matarese G, Portelli M, Mazza M, Militi A, Nucera R, Gatto E, Cordasco G. Evaluation of skin dose in a low dose spiral CT protocol. *Eur J Paediatr Dent.* 2006;2:77–80.
31. Ballanti F, Lione R, Fiaschetti V, Fanucci E, Cozza P. Low-dose CT protocol for orthodontic diagnosis. *Eur J Paediatr Dent.* In press.
32. Jurik AG, Jessen KA, Hansen J. Image quality and dose in computed tomography. *Eur Radiol.* 1997;7:77–81.
33. Scheck RJ, Copenrath EM, Kellner MW, et al. Radiation dose and image quality in spiral CT: multicentre evaluation at 6 institutions. *Br J Radiol.* 2002;75:140–150.
34. Habersack K, Karolgan A, Sommer B, Benner KU. High resolution multislice CT with multiplanar and 3D-reformation imaging in rapid palatal expansion (RPE). *Am J Orthod Dentofacial Orthop.* 2007;131:776–781.
35. Baccetti T, Franchi L, Cameron CG, McNamara JA. Treatment timing for rapid maxillary expansion. *Angle Orthod.* 2001;71:343–349.
36. Adkins MA, Nanda RS, Currier FG. Variazioni nel perimetro d'arcata nell'espansione rapida del palato. *Am J Orthod Dentofacial Orthop.* 1990;97:194–199.
37. Haas AJ. The treatment of maxillary deficiency by opening the midpalatal suture. *Angle Orthod.* 1965;35:200–217.
38. Da Silva OG, Prado Montes LA, Torelly LF. Rapid maxillary expansion in the deciduous and mixed dentition evaluated through posteroanterior cephalometric analysis. *Am J Orthod Dentofacial Orthop.* 1995;107:268–275.
39. Reitan K. Effects of force magnitude and direction of tooth movement on different alveolar bone types. *Angle Orthod.* 1964;34:244–256.
40. Rungcharassaeng K, Caruso JM, Kan JYK, Kim J, Taylor G. Factors affecting buccal bone changes of maxillary posterior teeth after rapid maxillary expansion. *Am J Orthod Dentofacial Orthop.* 2007;132:428.e1–428.e8.