British Journal of Neurosurgery (1995) 9, 537–541

SHORT REPORT

Peripheral aneurysms of the anterior inferior cerebellar artery. Case report and review of literature

A. SPALLONE, S. DE SANTIS & R. GIUFFRÈ

Division of Neurosurgery, University of Rome, 'Tor Vergata' Medical School, Rome, Italy

Abstract

Distal anterior inferior cerebellar artery aneurysms are rare. We recently treated one of these in a 46-year-old woman suffering from SAH and right facial and auditory deficit. The aneurysm was trapped 3 weeks after haemorrhage. Review of the pertinent literature revealed 36 similar cases which we analysed in detail. Guidelines for the proper management of these rare lesions are outlined.

Key words: *Anterior inferior cerebellar artery, intracranial aneurysms, subarachnoid haemorrhage.*

Introduction

Aneurysms located on the peripheral portions of the arteries of vertebrobasilar system are considered to be rare and are frequently reported as single cases. Those affecting the distal part of the anterior inferior cerebellar artery (AICA) are very rare, and no more than 36 have been described so far.[1–7]

We recently managed a case of AICA aneurysm located in the porus acusticus, which we report in detail, and the pertinent literature is reviewed.

Case report

A 46-year-old woman was admitted after a coma-producing subarachnoid haemorrhage (SAH). The patient regained consciousness shortly after the ictus, and a severe deficit of the right facial nerve and loss of hearing on the right became noticeable. CT (Fig. 1) revealed blood within the lateral and prepontine cisterns on the right, with extension into the fourth ventricle. Angiography demonstrated an aneurysm of the right distal AICA (Fig. 1) located in the internal auditory canal. Plain radiograph were carefully reviewed, but signs of bony erosion were not detected. The patient underwent a right paramedian posterior fossa craniectomy in the sitting position. The vertebral artery was inadvertently injured during opening along the extradural course between C1 and the occiput, but was satisfactorily repaired using encircling Sugita clips reinforced by a curved Sugita clip. After cerebellar retraction the right AICA was visualized proximally and followed towards the internal auditory canal. The aneurysm was identified in the meatus trapped (Fig. 2).

The postoperative course was uneventful. The facial paralysis and hearing loss persisted, with little improvement during the 6 months follow-up. Check angiography demonstrated no filling of the lesion and good flow through the right vertebral artery, although some narrowing of its lumen was present at the level of the intraoperative injury.

0268-8697/95/040537-05

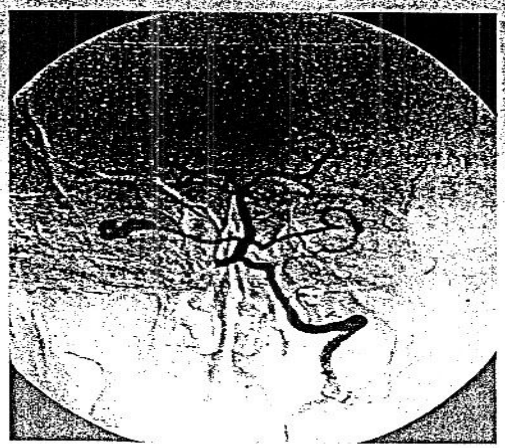

FIG. 1. Vertebral angiogram: an aneurysm located at the meatal loop of the right AICA is clearly demonstrated.

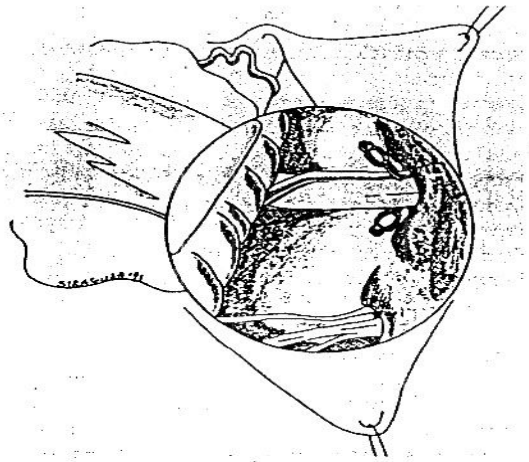

FIG. 2. Artist's drawing shows the anatomical relationships between the right VII–VIII nerve complex and the AICA. The proximal segment was located anteriorly and could be seen only after gentle retraction of the nerves. Trapping of the meatal segment of the AICA was performed at the porus acusticus.

Discussion

Review of literature

Aneurysms located in the peripheral portion of the AICA are very rare.[8] A recently published paper by Oana *et al.* reported 29 cases, 28 of which were collected from the literature. Cases where diagnosis was made at autopsy[9] were not considered. We were able to find seven additional cases described so far,[1–7] five of which were not considered for the present analysis, owing either to insufficient detail[4,6] or to coexistence of other intracranial vascular malformations.[3,10,11] In the remaining 32 cases including the one we have reported here, the following data were analysed.

Clinical findings

Distal AICA aneurysms occurred three times more frequently in females. The age of the patients (20–72 years, averaging 45.9 years) did not differ significantly from those of aneurysm patients in general.[8] No side predominance was observed. In the vast majority of cases the clinical history started with a SAH, usually accompanied by signs of cerebello-pontine angle (CPA) involvement. In at least four cases,[16–19] episodes of SAH were multiple, a fact which indicates that the risks of rebleeding are by no means negligible with these aneurysms. However, seven patients exhibited a progressive clinical course suggesting the presence of a CPA mass, and only three of them had a SAH later on, which led to the correct diagnosis. Hearing loss (23 cases), headache and vomiting (22 cases), and facial paralysis (20 cases) were the most common complaints at the time of admission. Symptoms and signs related to the dysfunction of other CPA nerves were also observed. Disturbances of consciousness were also noticed in some cases, while signs of long-tract involvement were occasionally seen.

Radiological findings

Erosion of the petrous bone on plain skull radiographs—a finding which could misleadingly lead to diagnosis of acoustic tumour—was

detected in one-third of the reported cases.[20,21] Information on CT findings were available in nine cases including ours.[5,11,18,20–24] This examination gave evidence of blood located in the posterior fossa, predominantly on the side of the lesion, in the six cases presenting with a recent SAH. Two unruptured aneurysms were highly enhanced with contrast,[20,22] although in one case widening of internal auditory meatus led to erroneous preoperative diagnosis of acoustic neurinoma.[20]

Vascular anatomy of AICA

Anatomy of the AICA is highly variable; furthermore, the literature on this subject is somewhat confusing, as is also the nomenclature of AICA branches.[19,25–30] In general, the AICA arises from the junction between the middle and the lower third of the basilar artery, courses along the pons and the middle cerebellar peduncle to which it gives a few perforating branches, then bifurcates into two major branches, called the (rostro-) lateral branch and the (caudo-) medial branch, respectively. The rostrolateral branch goes towards the internal auditory meatus close to the VII and VIII nerves complex, and gives off the labyrinthine artery or internal auditory artery (IAA). It is at this point that most peripheral AICA aneurysms are located. The branch then loops back medially at the middle cerebellar peduncle which receives some perforators from it and terminates with rami feeding the cerebellum which frequently anastomose with either SCA or PICA terminal branches. The caudomedial branch, where aneurysms are located only exceptionally,[21] courses medially close to the pons to which it sends a few perforators and terminates in cerebellar branches which also may anostomose with terminal posterior inferior cerebellar artery rami. The VII and VIII nerves complex is vascularized by the rami nervorum of the IAA,[31] which may have anostomoses with the carotid system via the otic capsula.[32] In general, the existence of anastomotic channels might theoretically protect from the consequences of the occlusion of each distal AICA branch. However, to what extent these anastomoses are functioning in each individual case is unpredictable.

Surgical management and results

Adequate information regarding surgical management and results was available in 26 cases from the literature. Wrapping was performed with excellent results in three cases,[1,21,33] although long-term follow-up was never mentioned. Proximal occlusion of the feeding artery was performed in three patients,[16,18,34] two of which[16,34] showed a stormy postoperative course probably owing to retrograde thrombosis with likely involvement of pontine branches. In the remaining case,[18] the postoperative course was uneventful. Clipping was performed in 14 cases, in three of which postoperative course is not mentioned.[11,12,15] Preoperative deficit of the VII–VIII complex persisted in three cases,[2,21,35] in spite of aneurysm removal to decompress the nerves[21] and was worsened in two other cases.[36,37] Six cases showed very good results[2,5,12,21,23,28] with improvement of a preoperative VIII nerve deficit in at least one of them.[38] In three of these cases[5,21,23] the aneurysm was located away from the AICA-IAA bifurcation and the internal auditory meatus. It appears that location of the lesion close to the meatus is a negative prognostic factor for postoperative VII–VIII nerves function, since it would require either extensive intrameatal dissection with resulting direct surgical trauma to the nerves or somehow 'blind' clipping of aneurysm with likely compromise of the IAA.[21] Trapping was performed in six cases, in three of which it caused a postoperative auditory and/or facial deficit,[17,22,24] In the remaining three cases, in which deficit of these nerves was present before surgery,[7,19,20] the postoperative course was uneventful. In no case did ischaemic middle cerebellar peduncle damage occur following trapping of the lesion at the internal auditory meatus. It would appear that trapping may be considered in the presence of an AICA aneurysm located close to internal auditory meatus particularly if an auditory and/or facial

deficit is present before the operation.[21] We managed the present case accordingly.

Address for correspondence: Aldo Spallone, MD, Università di Roma 'Tor Vergata', Cattedra di Neurochirurgia, via O. Raimondo, 8, 00173 – Roma, Italy.

References

1 Cabieses Molina F. Aneurisma de la arteria cerebelosa antero-inferior. Rev Neuropsiquiatr 1951; 14:528–31.

2 Fukuya T, Kishikawa T, Ikeda J, Kudo S, Kuwano H, Matsumoto S, Fujii K. Aneurysms of the peripheral portion of the anterior inferior cerebellar artery; Report of two cases. Neuroradiology 1987; 29:493–6.

3 Kaeck D, de Tribolet N, Lasjaunias P. Anterior inferior cerebellar artery aneurysm, carotid bifurcation aneurysm, and dural arteriovenous malformation of the tentorium in the same patient. Neurosurgery 1987; 21:575–82.

4 Niwa J, Kubota T, Okuyama T, Shimizu K, Hirai H. Supratentorial craniotomy of the cisternal clot removal in cases with ruptured aneurysms in the posterior fossa. Neurol Surg 1990; 18:385–9.

5 Oana K, Murakami T, Beppu T, Yamaura A, Kanaya H. Aneurysm of the distal anterior inferior cerebellar artery unrelated to the cerebellopontine angle: case report. Neurosurgery 1991; 28:899–903.

6 Ravon R. Les anévrismes artériels du système vertébrobasilaire. Thèse, Lyon, 1971.

7 Santucci N, Gazzeri G, Magliocco C. Aneurisma dell'arteria cerebellare anteriore inferiore (AICA). XVIII caso della letteratura. Riv Neurol 1985; 55:30–7.

8 Locksley HB. Report on the cooperative study of intracranial aneurysms and subarachnoid hemorrhage: Section V, part II. Natural history of subarachnoid hemorrhage, intracranial aneurysms and arteriovenous malformations. J Neurosurg 1966; 25:321–68.

9 Höök O, Norlen G, Guzman J. Saccular aneurysms of the vertebral-basilar arterial system: a report of 28 cases. Acta Neurol Scand 1963; 39:271–304.

10 Takara E, Inoue N, Kawano H. Disappearance of the co-existing aneurysm and arterio-venous malformation after wrapping of aneurysm. Neurol Surg 1980; 8:587–91.

11 Ueda T, Matsumura S, Ohtaki M, Kurokawa Y, Tanabe S, Hashi K. Aneurysm of the anterior inferior cerebellar artery at the internal auditory meatus. Report of two cases. Neurol Surg 1986; 14:1263–8.

12 Hitselberger WE, Gardner G Jr. Other tumours of the cerebellopontine angle. Arch Otolaryngol 1968; 88:712–14.

13 Krayenbühl H, Yasargil MG. Die vaskularen Erkrankungen im Gebiet der Arteria vertebralis und Arteria basialis. Georg Thieme, Stuttgart, 1957.

14 Glasscock ME III. Middle fossa approach to the temporal bone. An otologic frontier. Arch Otolaryngol 1969; 90:15–27.

15 Wiebel J, Fields VS, Campos RJ. Aneurysms of the posterior cervicocranial circulation: clinical and angiographic considerations. J Neurosurg 1967; 26:223–34.

16 Castaigne P, Pertuiset B, Cambier J, Brunet P. Anévrisme de l'artère auditive interne révélé par une paralysie faciale récidivante. Cure radicale. Presse Med 1967; 75:2493–6.

17 Hori T, Hirakawa K, Ishijima B, Manaka S, Fukushima T, Shimitsu N, Sato T. Aneurysm in the internal auditory meatus. Case report. J Neurosurg 1971; 35:605–9.

18 Johnson JH Jr, Kline DG. Anterior inferior cerebellar artery aneurysms. Case report. J Neurosurg 1978; 48:455–60.

19 Schwartz HG. Arterial aneurysm of the posterior fossa. J Neurosurg 1948; 5:312–6.

20 Dalley RW, Robertson WD, Nugent RA, Durity FA. Computed tomography of anterior inferior cerebellar artery aneurysm mimicking an acoustic neuroma. J Comput Assist Tomogr 1986; 10:881–94.

21 Nishimoto A, Fujimoto S, Tsuchimoto S, Matsumoto Y, Tabuchi K, Higashi T. Anterior inferior cerebellar artery aneurysm. Report of three cases. J Neurosurg 1983; 59:697–702.

22 Cantore GP, Ciappetta P, Vagnozzi R, Bozzao L. Giant aneurysm of the anterior inferior cerebellar artery simulating a cerebellopontine angle tumor. Surg Neurol 1982; 18:76–8.

23 Kamii H, Ogawa A, Sakurai Y, Kayama T. Anterior inferior cerebellar artery aneurysm with a sudden onset of caudal cranial nerve symptoms. Neurol Surg 1989; 17:387–91.

24 Nakagawa K, Sakaki S, Kimura H, Matsuoka K. Aneurysm of the anterior inferior cerebellar artery at the internal auditory meatus. Surg Neurol 1984; 21:231–5.

25 Atkinson WJ. The anterior inferior cerebellar artery. J Neurol Neurosurg Psychiatry 1949; 12:137–51.

26 Martin RG, Grant JL, Peace D, Theiss C, Rhoton AL Jr. Microsurgical relationships of the anterior inferior cerebellar artery and the facial-vestibulocochlear nerve complex. Neurosurgery 1980; 6:483–507.

27 Mazzoni A, Hansen CC. Surgical anatomy of the arteries of the internal auditory canal. Arch Otolaryngol 1970; 91:128–35.

28 Naidich TP, Kricheff IL, George AE, Lin JP. The normal anterior inferior cerebellar artery. Radiology 1976; 119:355–73.

29 Smaltino F, Bernini FP, Elefante R. Normal and pathological findings of the angiographic examination of the internal auditory artery. Neuroradiology 1971; 2:216–22.

30 Mazzoni A. Internal auditory canal: arterial relations at the porus acusticus. Ann Otol Rhinol Laryngol 1969; 78:797–814.

31 Fisch U. The surgical anatomy of the so-called internal auditory artery. In: Proceedings of the Tenth Nobel Symposium on Disorders of the Skull

Base Region, Almqvist & Wiksell, Stockholm, 1968; 121–30.
32 Hansen CC. Vascular anatomy of the human temporal bone. I. Anastomoses between the membranous labyrinth and its bony capsule. Arch Klin Exp Ohren Nasen u Kehlk Heilk 1971; 200:83–98.
33 Mori K, Miyazaki H, Ono H. Aneurysm of the anterior inferior cerebellar artery at the internal auditory meatus. Surg Neurol 1978; 10:297–300.
34 Malter IJ, Roberson G. Angiographic demonstration of anterior inferior cerebellar artery aneurysm by use of the base view. Radiology 1972; 103:125–6.
35 Kiya K, Uozumi T, Emoto K, Matsuoka T. Anterior inferior cerebellar artery aneurysms at the internal auditory meatus. Case report. Neurol Med Chir 1989; 29:592–5.
36 Benedetti A, Curri D, Carbonin C. Aneurysm of the internal auditory artery revealed by a partial cerebellopontine angle syndrome. Neurochirurgia (Stuttg) 1975; 18:126–30.
37 Higuchi H, Yajima K, Nakazawa S. A case of aneurysm of the left internal acoustic meatus. Neurol Surg 1978; 6:401–4.
38 Zlotnik EI, Sklyut JA, Smejanovich AF, Stasenko EN. Saccular aneurysm of the anterior inferior cerebellar internal-auditory artery. Case report. J Neurosurg 1982; 57:829–32.