



# Do We Still Believe There Is a G-spot?

Daniele Mollaioli<sup>1</sup> · Andrea Sansone<sup>1</sup> · Elena Colonnello<sup>1</sup> · Erika Limoncin<sup>1</sup> · Giacomo Ciocca<sup>2</sup> · Linda Vignozzi<sup>3,4</sup> · Emmanuele A Jannini<sup>1</sup>

Accepted: 1 June 2021 / Published online: 27 July 2021  
© The Author(s) 2021

## Abstract

In the field of female sexuality, the existence of the so-called “G-spot” represents a topic still anchored to anecdotes and opinions and explained using non-scientific points, as well as being overused for commercial and mediatic purposes.

## Purpose of Review

The scope of this review is to give an update on the current state of information regarding the G-spot and suggesting potential future directions in the research field of this interesting, albeit controversial, aspect of human sexual physiology.

## Recent Findings

From evolutionary, anatomical, and functional points of view, new evidence has rebutted the original conceptualization of the G-spot, abandoning the idea of a specific anatomical point able to produce exceptional orgasmic experiences through the stimulation of the anterior vaginal wall, the site where the G-spot is assumed to be. From a psychological perspective, only few findings to date are able to describe the psychological, behavioral, and social correlates of the pleasure experience by G-spot-induced or, better, vaginally induced orgasm (VAO).

## Summary

Recent literature suggests the existence of a G-spot but specifies that, since it is not a spot, neither anatomically nor functionally, it cannot be called G, nor spot, anymore. It is indeed a functional, dynamic, and hormone-dependent area (called clitorourethrovaginal, CUV, complex), extremely individual in its development and action due to the combined influence of biological and psychological aspects, which may trigger VAO and in some particular cases also female ejaculation (FE).

**Keywords** G-spot · Clitorourethrovaginal complex · Vaginal activated orgasm · Female ejaculation · Sexual pleasure

## Introduction

Shortly and simply, the question is, is the vagina a sexually inert organ, a fibromuscular tube which simply encases the penis

---

This article is part of the Topical Collection on Female Sexual Dysfunction and Disorders

---

✉ Emmanuele A Jannini  
ejannini@gmail.com

- <sup>1</sup> Chair of Endocrinology & Medical Sexology (ENDOSEX), Department of Systems Medicine, University of Rome Tor Vergata, Via Montpellier 1, 00131 Rome, Italy
- <sup>2</sup> Department of Dynamic and Clinical Psychology, Sapienza University of Rome, Rome, Italy
- <sup>3</sup> “Mario Serio” Department of Experimental and Clinical Biomedical Sciences, University of Florence, Florence, Italy
- <sup>4</sup> Andrology, Women’s Endocrinology and Gender Incongruence Unit, Careggi Hospital, Florence, Italy

during intercourse and allows for delivery during the parturition? And, if this is the case, are the women who believe they experience pleasure and orgasm during vaginal penetration without direct stimulation of the external clitoris to be considered “hysterical”? The scientific gap between male and female sexuality is a matter of evidence and one of the most important reasons for this lies in the complexity of female sexuality compared to the male one. Nevertheless, much has been done since the beginning of the century, providing plenty of scientific evidence related to female sexual behavior and its connections with hormonal, psychological, relational, and social aspects.

To date, one of the topics that still seems to be anchored more to anecdotes and opinions than to evidence is the existence of the so-called “G-spot”, i.e., a specific vaginal erogenous zone which, if stimulated, would be capable of producing an orgasm other than that obtained through the direct stimulation of the external clitoris. In this regard, a historical reconstruction of the identification of this area [1] documented

how the idea of the existence of a specific erogenous point in the anterior wall of the female vagina had already been hypothesized a couple of thousand years ago in a Chinese Poem written by Bai Xinjiang and entitled The pleasure of heaven and of the earth. This point, referred to as “milky / milky fruit”, would produce a whitish liquid upon stimulation, according to the description. Similarly, in India, both the Kama Sutra treatise written in the same period as the Chinese Poem and the thirteenth century *Anangaranga* refer to a vaginal erogenous zone called *madanagamanadola*, the stimulation of which would produce “a storm of water of love”.

In Western countries and cultures, however, investigating the existence of such an erogenous area was often considered improper. In the seventeenth century, Regnier de Graaf, in the *Tractatus de Virorum Organis Generationi Inservientibus*, mentioned the existence in the woman of a periurethral tissue, believed to be the equivalent of the male prostate gland, from which the female ejaculate would come [2]. Nevertheless, no scientific investigations were conducted until the second half of the twentieth century.

Based on these premises, and due to the absence of a clear explanation of what G-spot really means from the biological, psychological, and relational point of view, this review aims to give an update on the topic, with the intent of establishing the state of information regarding the G-spot and suggesting potential future directions in the research field of this interesting, albeit controversial, phenomenon.

## A Historical and Evolutionary Perspective on the Nature and Culture of the G-Spot

### The Historical Perspective

In the fourth century B.C, Aristotle observed that human females can conceive without involving the clitoris [3], directly or indirectly contributing to a lack of scientific interest in female orgasm. After the Greeks, also Persian and Arabic scientists produced a number of misconceptions about the clitoral function, which lasted for centuries. Only in the middle of the sixteenth century, the Italian anatomist Matteo Colombo, pupil of the more famous Andreas Vesalius, emphasized for the first time the role of the clitoris in female pleasure. This late “discovery”, according to Colombo, once again accounts for the embarrassing delay in anatomy and physiology of female sexuality [4]. Subsequently, despite the great contributions provided by many scientists (the Dutch Regnier De Graaf [2] and the German George Kobelt [5], to name a few), the medical society persisted in its total unrecognition of both the clitoris and the vagina as sexual organs, while attributing to them the role of risk factors in female psychiatric diseases instead [6]. Hence, Charcot and other scientists proposed to cure hysteria with clitoral excision

[7], based on the underlying belief that the clitoris plays a pivotal role in female psychopathology. Similarly, with the development of Freud’s theory on human sexuality, the previously almost ignored clitoris received increasing attention, but associated with a negative perception. As the vaginal orgasm was considered the “only true and mature” kind of female orgasm, the clitoral one was on the contrary read as the expression of an immature personality [8]. Following Freud’s interpretation, women with an immature temperament, and considered by Freud as frigid, point the attention towards the clitoris, as they are frustrated by the absence of the penis (a phenomenon well known in the psychodynamic milieu as penis envy (German: *Penisneid* [9])). For this reason, according to his theory, the cure for frigidity and the promotion of a mature sexuality may only be achieved by the surrender of the clitoris.

Surely, Freud’s theory regarding female sexuality promoted the pathologizing of the clitoral orgasm. However, it also contributed to building the concept of the existence of (at least) two separate kinds of female orgasm, the vaginal and clitoral one, hence his consideration promoted the broadening of female sexuality from an anatomical, sociological, and evolutionary point of view.

Contrary to this conception was initially only the psychiatrist Wilhelm Reich, one of Freud’s pupils, who was among the first to disagree with his master, pointing out the political and cultural function of the orgasm and being the first to consider male and female orgasm as equally important [10]. But only with the studies on human sexuality made by Kinsey [11], and later by Masters and Johnson [12], was the central role of the clitoris in female sexual pleasure redescribed and rediscovered [13].

From a sociocultural point of view, between the nineteenth and the twentieth century, the predominant importance given to vaginal orgasm over the clitoral one was of course necessary to guarantee the birth of as many children, who would later become a productive workforce, as possible. This perspective significantly contributed to supporting the traditional phallogocentric vision of female sexuality throughout the century.

### The Evolutionary Perspective

Comparative anatomy may provide more insights into the relative sexual roles of the clitoris and of the vagina, which seems to be a recent achievement of evolution. While the very large majority of mammals (and many non-mammals) have an exclusive *more ferarum* (= in the manner of wild beasts), or rear-entry, position for intercourse, the closest primate to humans evolutionally speaking, a pygmy chimpanzee living in the center of Africa, prefers the vis-à-vis (or missionary) position [14]. The location of the clitoris of the *Pan paniscus* (or bonobo) is more similar to that of *Homo sapiens* with

respect to that of the less evolved *Pan troglodytes* (or common chimpanzee [15]). Indeed, the bonobo clitorises are larger and more externalized than in most mammals [16]. As a possible consequence, the former regularly practices homosexual, intergenital rubbing with a ventro-ventral sexual stimulation as well the heterosexual, ventro-ventral copulations. It could be argued that the clitoris has achieved a role in female sexuality only recently in evolution terms.

Several theories, finally, have attempted to answer the paradoxical conundrum of why the male orgasm has evolved as an easy-to-reach and fast function, very frequently linked to ejaculation and reproduction, while female orgasm has evolved as a much less granted, much slower, and much more complex reaction not obtained from a unique stimulation. Table 1 illustrates the main fields of research and hypotheses on this topic.

In humans, instead of reproduction, a relationship seems to be one of the main goals of females, an aim reinforced by orgasm, as suggested by the orgasmic increase in oxytocin, a typical neurochemical mechanism of pair bonding [17], and by a higher prevalence of orgasmic experience during homosexual intercourse, where there is no reproductive goal, compared to heterosexual sex [23].

In line with this theory, it has been hypothesized that female orgasm is just a cultural artifice useful for male gratification. In support of this, some scientific evidence stresses the notion that women fake orgasms in order to prevent male frustration and to ameliorate couple dyadic adjustment [24, 25].

Hence, in the case of difficulty/impossibility in reaching orgasm, a female/male problem or dysfunction should be suspected. Symons has proposed the female orgasm as a product of anatomical, social, cultural, and emotional factors and, interestingly, a learned ability [26].

An interesting theory has suggested that female orgasm may also prevent the woman from getting up immediately

from a recumbent position, enhancing the possibility that the spermatozoa remain in the female genital tract [27]. Finally, the pleasure related to an orgasm may make women more prone to having more sexual intercourse.

## An Update on the Anatomy of Female Orgasms

In the 1950s, the gynecologist Ernst Gräfenberg published a short report in which he described the existence of an erogenous zone in female vaginas, along the course of the urethra and particularly “where it arises from the neck of the bladder” [28]. In the 1980s, this area was named G-spot, after Gräfenberg himself, by Ladas, Whipple, and Perry, who described it as being “composed of a complex network of blood vessels, the paraurethral glands and ducts (female prostate), nerve endings, and the tissue surrounding the bladder neck” [29, 30]. After that, several scientific papers appeared, trying to provide further anatomical, biochemical, and functional insights on this spot or, according to the general assumption, to deny its existence. Interestingly, the very large majority of papers in favor of the discovery have been experimental findings, i.e., evidence, while the very large majority of articles against the existence of the G-spot have been narrative review articles, i.e., opinions, written by authors without demonstrating scientific experience in producing experimental data in the field. In a famous, but very poorly researched, review article in the American Journal of Obstetrics and Gynecology, 20 years later, the psychologist Terence Hines of Pace University, Pleasantville, NY, compared it to a sort of gynecologic UFO: “much sought for, much discussed, but unverified by objective means” [31]. In reply to this, the following year, the same authors who coined the name G-spot replied with a letter to the editor defending its existence [32, 33].

While a more detailed description of female prostate was elaborated thanks to the meritorious work of the Slovak pathologist Milan Zaviacic [34], many ultrasound and MRI studies as well as cadaveric dissections have given other insights into its complex structure, but surprisingly still much controversy exists around this topic, and the existence of the G-spot is today still a matter of debate [35, 36].

What is certain according to evidence is that, at the genital level, the area devoted to female sexual pleasure has a complex and, most importantly, variable anatomical structure.

The vagina is a collapsed fibromuscular canal invested by two layers of smooth muscle, longitudinal and circular, which are fundamentally involuntary and cannot be consciously contracted. Near its opening — the introitus — lies the female urethra, which is about 1-cm long, surrounded by the clitoris.

The clitoris is an organ located under the urogenital diaphragm, in the anterior vaginal wall. It is mostly made up of highly vascularized erectile tissue, and its visible parts are the

**Table 1** Theories for the evolution of orgasm in female

Theories
Orgasm as a tool to reinforce pair bonding [17]
The orgasm helps in the selection of the “right” partner [18]
Both real or fake orgasms are a tool to increase the partner’s gratification [19]
The orgasmic reward motivates women to have more sexual intercourse [20]
The orgasmic contractions may help the swimming spermatozoa to reach the egg [21]
Immobilizing women for a little time in the recumbent position, the orgasm prevents sperm leakage [22]

Note that none of them is to be considered universal and scientifically robust, and none of them is useful enough to explain the complexity of the female orgasmic reaction compared to the male one

glans and the prepuce [37]. The erectile tissue here, histologically and functionally similar to that of the penis, is not surrounded by a complete albugineal layer, which explains why the vasocongestive process occurring during arousal and intercourse does not lead to a visible “erection”, like in males, but rather to a tumescence [38]. The mean transverse diameter of the glans, as recorded in 200 premenopausal women, was found to be 3.4 +/- 1.0 mm, while the longitudinal diameter was 5.1 +/- 1.4 mm, and the total length described as 16 +/- 4.3 mm [39]. However, other more recent studies demonstrated a greater dimension, with a length of the descending clitoral body, from the angle to the base of the glans, of 37 mm [40].

Age, height, weight, and current use of oral contraceptives were found to have no impact on clitoral size. However, in a retrospective study that evaluated pelvic MRI of female patients to measure clitoral anatomy in relation to sexual parameters, self-reported sexual function and orgasm were shown to have a correlation with anatomical structures [41]. Namely, better scores were associated with smaller clitoral structures, while larger clitoral anatomy was surprisingly associated with declining sexual function in women with greater BMI. Different results were achieved by other authors, who showed that worse sexual function was correlated with smaller clitoral glans, again farther from the vaginal lumen than women with normal orgasmic function [41–43], possibly because the distance from the urethra and vagina to the clitoris is shorter. Indeed, during arousal, it is reported that all the structure is engorged with blood and this process could bring the clitoral tissue closer to the vaginal lumen [44], which could aid in stimulation and sensation. While anatomical-functional literature about the penis delivers univocal messages when correlating anatomy, histology, physiology, pathophysiology, and metabolic status, the same seems to not be possible when dealing with the same issues in the clitoris.

Bulbs, body, and crura constitute most of the clitoral erectile tissue and are instead buried under the mucosa, with the roots located in contact with the ischiopubic ramus, covered by the ischiocavernosus muscles. In a series of dissections of 13 cadavers performed by the Melbourne urologist Helen O’Connell [45], no discrete macroscopic anatomic structure consistent with the G-spot concept was identified in any cadaver. Specifically, some erectile tissue was found but not in the putative area of the G-spot as described by Ostrzenski et al. some years before [46, 47], but rather, and only, anterior to the distal urethra. For this reason, the authors identified it as being part of clitoral bulbs. While the study denies the existence of a distinct, vascular, and erectile structure as a concrete spot, on the other hand, it corroborates the idea that a deep interrelation exists among the clitoris, vagina, and urethra with its glands, but not denying the existence and the role of an “erotogenic zone”, using Ernst Gräfenberg’s wording [28]. Both the urethral orifice and distal urethra indeed are surrounded by the

erectile tissue of the clitoral bulbs, providing evidence for the existence of a “clitoral complex” [44], or “clitoral urethral complex” (CUC) [48], and, lastly, in a more complete manner encompassing all the anatomical structures involved, “clitourethrovaginal complex” (CUV) [49], namely the terms which have been coined to denote this area in women. Despite the apparent plethora of anatomical studies, a consensus has not yet been reached on this topic; however, a functional correlation of CUV anatomy to sexual function is supported by the claims of a number of scientists and by the mentioned findings. For instance, Gravina et al. have shown that thicker anterovaginal space is correlated with a predisposition to vaginal orgasm [50], a result further confirmed in larger numbers of subjects by other independent researchers [51]. In comparison to the measurements presented in the study of Ostrzenski et al., significant differences can be observed pertaining to the distance of the urethral meatus to the G-spot complex, its height and thickness. This was confirmed by some authors who analyzed retrospectively 21 studies done with pelvic MRI on female patients in order to confirm or confute the data about G-spots obtained by anatomical dissection studies [52]. According to the findings, overall a G-spot complex could be identified in 13/21 patients (62%). The position of the G-spot complex was variable with 5/13 cases (38%) on the right side, 3/13 (24%) on the left side and 5/13 (38%) in a medial position.

Concerning the urethra and its surrounding exocrine glands, it is purported to be responsible for the secretions released during the peak of female arousal states. Specifically, the microscopic distal urethral glands, also known as Skene’s or paraurethral glands, are the claimed source for this milky fluid, which is then released by the small and short ducts that drain via the urethra; the finding of specific markers of prostatic tissue such as prostate-specific antigen (PSA), type 5 phosphodiesterase (PDE5) [53] and other markers such as chromogranin and nitric oxide (NO) synthases (NOS) [54, 55] in this “milky fluid” seem to have confirmed this theory, although the recognition of the “prostate foeminina” [2] is still not unanimously accepted. Nevertheless, a sort of vestigial “prostatic” tissue was found in around 90% of women [56], localized in the urethra, approximately 10% of it around the area of the bladder sphincter but the main part of the tissue being in the more distal urethra in 66% of women [57]. Even Gräfenberg, in his cited report, having observed women masturbating until orgasm, claimed that the fluid expelled by women at the time of maximal pleasure effectively comes from this area, and has no lubricating function as it appears at the acme of orgasm, not at the beginning of sexual stimulation (like vaginal transudate) nor during (like Bartholin’s glands secretion [28]).

To better describe such fluid, and to highlight the similarities with the male one, usually the term female ejaculation is adopted. However, whether this fluid really exists and where it

comes from is still a matter of debate. Some authors argue that it is merely hyperlubrication [58], while others, starting from the famous psychologist Havelock Ellis, believed it comes from Bartholin's glands [59] rather than Skene's. More recently, it has been sustained that the fluid is urine [60, 61]. To the present date, whether females can really ejaculate is still (unfortunately) not widely accepted despite the fact that the phenomenon of "squirting", the process of expulsion of fluid at orgasm by women, has been described for centuries [62]. A recent biochemical analysis of the fluids produced during an orgasm demonstrated that female ejaculation and squirting/gushing are two different phenomena, the former being a release of a very scanty, thick, and whitish fluid from the female prostate, while the latter is the expulsion of a very diluted fluid from the urinary bladder, rapidly produced by the kidney during arousal/plateau phases, stored in the bladder and released by the urethra. A large variability between women is, again, a matter of evidence also for the orgasmic expulsion of fluids [63].

Finally, since squirting, female ejaculation and coital incontinence are different phenomena with various mechanisms and could be easily differentiated according to source, quantity, expulsion mechanism, role in the erotic physiology, and subjective feelings during sexual activities [64], the existence of true female ejaculation in some women could be considered an indirect biomarker of the presence and physiological role of the CUV in the female erotic response.

### Which Function for the G-Spot? Towards a Multifactorial Explanation of the Female Sexual Experience

The analysis of the G-spot or CUV complex is strictly connected with the experience of female sexual pleasure. The reflex arc responsible for orgasm starts from the receptors of the clitoral complex, which convey sensation through somatic afferents of the pudendal nerves including the dorsal nerve of the clitoris and the perineal branches up to the spinal cord nerve roots S2–S4, from where visceral parasympathetic efferent fibers responsible for the vasodilation at genital level reach the erectile tissue [44]. This leads to dilation of sinusoids, engorgement with blood, and subsequent swelling of the clitoris and surrounding structures and production of a transudate, the lubricate fluid. If arousal continues, orgasm may be triggered by sympathetic fibers from T<sub>12</sub> to L<sub>1</sub> that mediate contraction of the skeletal muscles of the vagina, urethra, and anal sphincters via pudendal innervations and uterine smooth muscle via autonomic innervations. Together with anatomical changes, the orgasmic experience is accompanied also by hormonal, sensitive, cognitive, and emotional changes as well.

Female orgasm is therefore a complex and extremely variable neuromuscular phenomenon, modulated by localization

[65–67] and modalities [68] of sexual stimuli, individual characteristics such as personality [69] and self-image [70] and quality of romantic relationship [71], which lead to different degrees of orgasmic intensity and pleasure [72].

Biological, evolutionary, and socio-cultural theories have given some interesting explanations and interpretations of the "utility" of female orgasm, whether clitoral, vaginal, or induced by the CUV complex. However, its role in female sexuality and general psychological well-being is not yet completely clear.

To date, many researchers have tried to prove the anatomical presence of G-spot or CUV complex definitively, but few have focused on analyzing the functionality of this area for the female sexual experience.

Burri and colleagues, investigating whether the self-reported G-spot has an underlying genetic basis on a sample of monozygotic and dizygotic female twins, stated that the perception of this area was reported by 56% of the sample, independently of their genetic habits [73]. On these bases, it has been highlighted that self-perception of this genital area is the result of anatomical aspects together with personality, cognitive, emotional, relational, and social clues, lending to the idea that functionality of the CUV complex in female sexual pleasure has a multifactorial nature [74].

In a recent study, Kaya et al. investigated how the self-perception of a G-spot could impact sexual function and genital perception of 309 healthy women, finding that women who thought they have a G-spot (51% of the sample) reported higher genital perception and a better sexual function, especially in the orgasm subdomain of the Female Sexual Function Index (FSFI). These results are not only consistent with the recent literature, but they are aligned with the idea that G-spot self-perception contributes to a better sexual experience. This interesting point raises another controversial issue. Is the orgasm obtained from the CUV stronger and better than the clitoral one? Further studies should focus this aspect, with validated psychometric tools designed to examine self-perceived orgasmic intensity [72].

G-spot and CUV complex are in fact frequently associated with other sexual phenomena, such as squirting (SQ) [61, 75] and female ejaculation (FE) [62, 76–79]. FE is the secretion of a few milliliters of a thick, milky fluid by the female prostate (Skene's glands) during orgasm, which contains prostate-specific antigen. SQ is defined as the orgasmic transurethral expulsion of tenths of milliliters of a form of urine containing various concentrations of urea, creatinine, and uric acid.

Interestingly, the latter point has been studied with other tools. Several researchers showed that FE positively impacts both individuals and their partner's sexual experience. In a large sample of 1245 heterosexual health workers [80] (physicians, sex-therapists, nurses, counselors, etc.), almost 40% of participants reported to have ejaculated at least once, with the majority of them (59.5%) experiencing multiple orgasms

and orgasms of longer duration and a higher sexual satisfaction compared with non-ejaculators. Furthermore, 84% of women reported G-spot-induced orgasms irrespectively of ejaculation, indicating a higher overall psychological sexual satisfaction in comparison to 76.4% of women who did not experience orgasm induced by G-spot.

In another study [81], 330 women reported that ejaculation experience enriched their own (78.8%) and their partner's (90%) sexual life, despite only 0.6% of the sample considering it as pathological. On the other hand, almost half of the sample (44%) did not recognize the source area of their ejaculation.

The relationship between G-spot self-perception and sexual quality of life contributes to an increase in the requests for female genital cosmetic surgery, and in particular for the G-spot augmentation/amplification, carried out by hyaluronic acid or autologous fat transplantation procedures. Due to the lack of scientific evidence about this topic, the American College Obstetrician and Gynecologists (ACOG) Committee published during the last 15 years two committee opinion papers highlighting the inefficacy of such techniques and the potential risks (urinary tract infections) [82, 83].

Finally, a very small amount of studies were found about G-spot/CUV complex and psychological attributes (personality, defense mechanism, attachment styles) or sexual practices and fantasies [73]. This represents, to date, a strong limitation, because it does not allow us to better identify which factors determine the perception of the sensate genital area and its effects on sexual wellbeing.

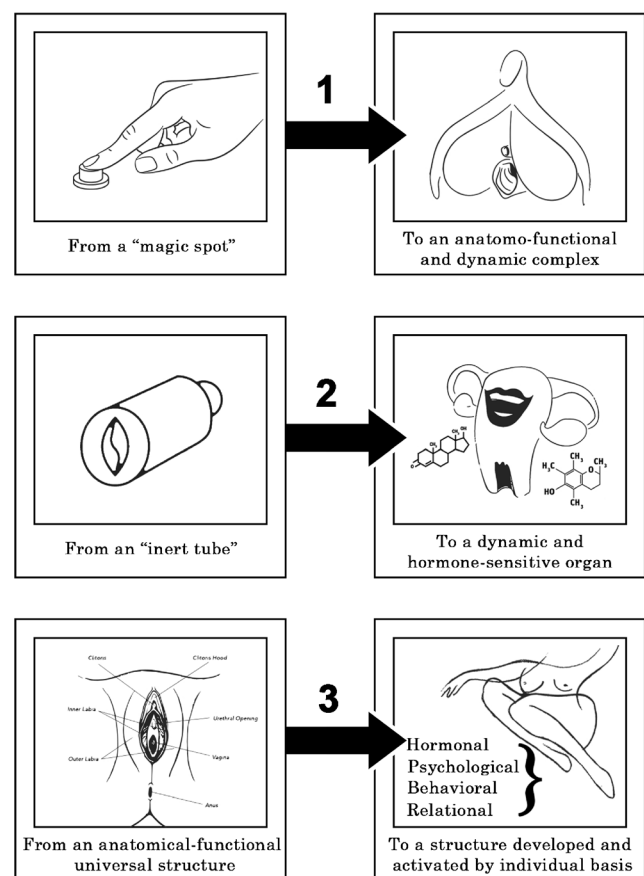
Therefore, future research on this topic should take into consideration not only the anatomical, but also the individual, relational, and social aspects, in order find new evidence that could shed light on which function the G-spot — CUV complex can have in female sexuality instead of arguing if this sensate genital area exists or not.

## Conclusions

The topic of the G-spot is to date, most likely, a unique controversial aspect of human gross-anatomy. There are three main reasons for it (Fig. 1). The first was choosing the wrong name. Although it recognizes the debt to Ernst Gräfenberg who pioneered the studies on human vagina, it should be said that the term “spot” following the initial of his last name produced a holy grail: a never-ending search to find, literally, a spot, a magic button delivering a unique orgasmic experience, which — this is absolutely true — does not exist. Unfortunately, the conundrum on the existence of such a spot has been very largely discussed by non-scientific media and, on many occasions, by review articles based on opinions. This produced evident harm for the whole field of sexual medicine.

There is a second element which produced skepticisms. In several gynecological settings, the vagina has been considered

no more than an inert tube for delivering babies. Some surgeons base their wrong assumption on the idea that the vagina, designed for this purpose, must be then poorly innervated and almost not sensitive. Of course, this position ignores the role of the numerous hormonal and neurotransmitter changes during the last hours of pregnancy and delivery. An excellent representation of the ignorance of some gynecologists has been well represented by the symphysiotomy, or Zarate's operation [84], and by the episiotomy itself [85, 86]. The two operations are very rarely needed, and the large majority of these interventions done in the past were based on ignorance, misogyny, and prejudices against female sexuality. Nowadays, the argument that the vagina is just a fibromuscular channel, sexually inert, is no longer tenable. In other words, if the vagina is a sexual organ, particularly responsive in its anterior wall, the G-spot, or however it is called, is a reality.



**Fig. 1** An infographic explaining the three reasons to abandon G-spot definition. Firstly, the term “G” and “Spot” are surpassed by new evidence highlighting a dynamic organization between the structures of female genitalia (clitoris, urethra, and vagina). Secondly, a conceptualization of the vagina as an “inert tube” should be abandoned due to its high sensitivity to hormone action and active role in sexual pleasure and orgasm; Finally, the anatomical-functional structure of female genitalia cannot be considered universal but extremely variable in its functioning owing to the action of hormones, cognitive, and emotional status and even partner's characteristics

The third reason generating the controversy can be found in the characteristics of the main actors of this anatomical region. The clitoris, urethra, female prostate, and vagina are exquisite hormone-dependent areas in their size, gross anatomy, histology, and function [87]. Moreover, nothing is more fluctuating than (steroid) hormones in females. Is this sufficient to admit that this region is definitively not universal in its anatomic and functional structure? Is this enough to admit that the findings denying the G-spot in a single or few cases are, at the very least, inconclusive? The surprising variations from woman to woman in referring to and experiencing arousal and orgasm, the dramatic differences in the same woman regarding the same experiences according to the various phases of the menstrual cycle or the reproductive/perimenopausal/postmenopausal status may suggest more humility when deciding that the G-spot does not exist (but also that every woman must have it).

But there is another, although para-scientific, argument which should be considered when attempting to answer the question embedded in the title of this article. The Italian version of Amazon is currently selling around 1000 different vibrators, 218 of them claiming to be able, due to shape and functionalities, to directly stimulate the G-spot. Shall we consider the fact that one out of every four buyers looking for a G-spot sexual aid is a victim, totally influenced by the wrong mediatic messages? If those tools do not work for the simple reason that the G-spot does not exist, their market would crash rapidly. The fact that it is a prosperous market, and that the haptic stimulation of the debated region is considered a plus of these tools [88], would suggest that the CUV area should deliver some pleasure, if not orgasms, when properly stimulated.

Despite all these reasons, it seems evident that the questions about the existence of the G-spot have not yet been definitively answered, as well as the question of the nature of FE and the existence of more than one female orgasm. However, it is important that the topic is finally addressed in a scientifically appropriate way, as the most recent studies [49] have improved our understanding of the complex anatomy and physiology of the female sexual response. On the other hand, the other aspects influencing the perception and the orgasmic experience connected to the G-spot remain in most cases anecdotal or understudied.

This intriguing topic, which finds explanatory roots in several disciplines (anatomy, physiology, psychology, sexology, history, evolution, anthropology, and sociology), will have to be studied for a long time with an even more scientific approach. However, we have here to conclude that the G-spot surely exists and is present, developed, and active on a tremendously individual basis. However, it is not a spot, and to reduce the risks of misinterpretations and vacuous discussions, it cannot be called G anymore. It is indeed a functional, hormone-dependent area, which may trigger VAOs and in some cases also FEs, well defined as CUV.

**Funding** Open access funding provided by Università degli Studi di Roma Tor Vergata within the CRUI-CARE Agreement.

**Open Access** This article is licensed under a Creative Commons Attribution 4.0 International License, which permits use, sharing, adaptation, distribution and reproduction in any medium or format, as long as you give appropriate credit to the original author(s) and the source, provide a link to the Creative Commons licence, and indicate if changes were made. The images or other third party material in this article are included in the article's Creative Commons licence, unless indicated otherwise in a credit line to the material. If material is not included in the article's Creative Commons licence and your intended use is not permitted by statutory regulation or exceeds the permitted use, you will need to obtain permission directly from the copyright holder. To view a copy of this licence, visit <http://creativecommons.org/licenses/by/4.0/>.

## References

- Pan S, Leung C, Shah J, Kilchevsky A. Clinical anatomy of the G-spot. *Clin Anat*. 2015;28:363–7.
- Jocelyn HD, Setchell BP. Regnier de Graaf on the human reproductive organs. An annotated translation of *Tractatus de Virorum Organis Generationi Inservientibus* (1668) and *De Mulieribus Organis Generationi Inservientibus Tractatus Novus* (1962). *J Reprod Fertil Suppl*. 1972;17:1–222.
- Leroi AM, MacPherson S, Koutsogiannopoulos D. *The lagoon : how Aristotle invented science*; 2015.
- Stringer MD, Becker I, Colombo and the clitoris. *Eur J Obstet Gynecol Reprod Biol*. 2010;151:130–3.
- Kobelt GL. The male and female organs of sexual arousal in man and some other mammals. In: Lowry TP, editor. *The Classic clitoris : historic contributions to scientific sexuality*. Chicago: Nelson-Hall; 1978. p. 44–7.
- Granville JM. *Nerve-vibration and excitation as agents in the treatment of functional disorder and organic disease*. London: Churchill; 1883.
- Lancaster RN, Di Leonardo M. *The gender/sexuality reader : culture, history, political economy*. New York: Routledge; 1997.
- Freud S, Strachey J. *Three essays on the theory of sexuality*. New York: Basic Books; 2000.
- Kleeman JA. Freud's views on early female sexuality in the light of direct child observation. *J Am Psychoanal Assoc*. 1976;24:3–27.
- Reich W. *The function of the orgasm : sex-economic problems of biological energy*. New York: Noonday Press; 1973.
- Kinsey AC, Pomeroy WB, Martin CE, Gebhard PH. *Sexual behavior in the human female*. Oxford, England: Saunders; 1953.
- Masters WH, Johnson VE. *Reproductive biology research F. Human sexual response*. Boston: Little, Brown; 1966.
- Masters WH, Johnson VE. *Reproductive biology research F. Human sexual response*. Bronx, NY: Ishi Press International; 2010.
- Waal FBM, Lanting F. *Bonobo: the forgotten ape*. University of California Press; 1998.
- Dahl JF. The external genitalia of female pygmy chimpanzees. *Anat Rec*. 1985;211:24–8.
- Balcombe J. *The Exultant Ark: a pictorial tour of animal pleasure*. 1 ed: University of California Press; 2011.
- Coria-Avila GA, Herrera-Covarrubias D, Ismail N, Pfaus JG. The role of orgasm in the development and shaping of partner preferences. *Socioaffect Neurosci Psychol*. 2016;6:31815–5.

18. Gallup GG Jr, Ampel BC, Wedberg N, Pogosjan A. Do orgasms give women feedback about mate choice? *Evol Psychol*. 2014;12:958–78.
19. Harris EA, Hornsey MJ, Larsen HF, Barlow FK. Beliefs about gender predict faking orgasm in heterosexual women. *Arch Sex Behav*. 2019;48:2419–33.
20. Prause N. The human female orgasm: critical evaluations of proposed psychological sequelae. *Sex Relatsh Ther*. 2011;26:315–28.
21. King R, Dempsey M, Valentine KA. Measuring sperm backflow following female orgasm: a new method. *Socioaffect Neurosci Psychol*. 2016;6:31927.
22. Custers IM, Flierman PA, Maas P, Cox T, van Dessel TJHM, Gerards MH, et al. Immobilisation versus immediate mobilisation after intrauterine insemination: randomised controlled trial. *BMJ*. 2009;339:b4080.
23. Garcia JR, Lloyd EA, Wallen K, Fisher HE. Variation in orgasm occurrence by sexual orientation in a sample of U.S. singles. *J Sex Med*. 2014;11:2645–52.
24. Opperman E, Braun V, Clarke V, Rogers C. “It feels so good it almost hurts”: young adults experiences of orgasm and sexual pleasure. *J Sex Res*. 2014;51:503–15.
25. Witherow MP, Chandraiah S, Seals SR, Bugan A. Relational intimacy and sexual frequency: a correlation or a cause? A clinical study of heterosexual married women. *J Sex Marital Ther*. 2016;42:277–86.
26. Symons D. *The evolution of human sexuality*. Oxford; New York: Toronto: Oxford University Press; 1981.
27. Morris D. *The naked ape : a zoologist's study of the human animal*. London: Vintage Books; 2017.
28. Gräfenberg E. The role of urethra in female orgasm. *International Journal of Sexology*. 1950;3:145–9.
29. Ladas AK, Whipple B, Perry JD. *The G spot and other recent discoveries about human sexuality*. New York: Dell; 1983.
30. Perry JD, Whipple B. Pelvic muscle strength of female ejaculators: evidence in support of a new theory of orgasm. *J Sex Res*. 1981;17:22–39.
31. Hines TM. The G-spot: a modern gynecologic myth. *Am J Obstet Gynecol*. 2001;185:359–62.
32. Whipple B, Perry JD. The G-spot: a modern gynecologic myth. *Am J Obstet Gynecol*. 2002;187:519 author reply 20.
33. Chalker R. The G-spot: some missing pieces of the puzzle. *Am J Obstet Gynecol*. 2002;187:518–9 author reply 20.
34. Zaviacic M, Ablin RJ. The G-spot. *Am J Obstet Gynecol*. 2002;187:519–20 discussion 20.
35. Buisson O. The G-spot and lack of female sexual medicine. *Gynecol Obstet Fertil*. 2010;38:781–4.
36. Puppo V, Gruenwald I. Does the G-spot exist? A review of the current literature. *Int Urogynecol J*. 2012;23:1665–9.
37. Pauls RN. Anatomy of the clitoris and the female sexual response. *Clin Anat*. 2015;28:376–84.
38. Toesca A, Stolfi VM, Cocchia D. Immunohistochemical study of the corpora cavernosa of the human clitoris. *J Anat*. 1996;188(Pt 3):513–20.
39. Verkauf BS, Von Thron J, O'Brien WF. Clitoral size in normal women. *Obstet Gynecol*. 1992;80:41–4.
40. Kelling JA, Erickson CR, Pin J, Pin PG. Anatomical dissection of the dorsal nerve of the clitoris. *Aesthet Surg J*. 2020;40:541–7.
41. Vaccaro CM, Fellner AN, Pauls RN. Female sexual function and the clitoral complex using pelvic MRI assessment. *Eur J Obstet Gynecol Reprod Biol*. 2014;180:180–5.
42. Oakley SH, Vaccaro CM, Crisp CC, Estanol MV, Fellner AN, Kleeman SD, et al. Clitoral size and location in relation to sexual function using pelvic MRI. *J Sex Med*. 2014;11:1013–22.
43. Wallen K, Lloyd EA. Female sexual arousal: genital anatomy and orgasm in intercourse. *Horm Behav*. 2011;59:780–92.
44. O'Connell HE, Eizenberg N, Rahman M, Cleeve J. The anatomy of the distal vagina: towards unity. *J Sex Med*. 2008;5:1883–91.
45. Hoag N, Keast JR, O'Connell HE. The “G-spot” is not a structure evident on macroscopic anatomic dissection of the vaginal wall. *J Sex Med*. 2017;14:1524–32.
46. Ostrzenski A. G-spot anatomy: a new discovery. *J Sex Med*. 2012;9:1355–9.
47. Ostrzenski A, Krajewski P, Ganjei-Azar P, Wasutynski AJ, Scheinberg MN, Tarka S, et al. Verification of the anatomy and newly discovered histology of the G-spot complex. *Bjog*. 2014;121:1333–9.
48. Oakley SH, Mutema GK, Crisp CC, Estanol MV, Kleeman SD, Fellner AN, et al. Innervation and histology of the clitoral-urethral complex: a cross-sectional cadaver study. *J Sex Med*. 2013;10:2211–8.
49. Jannini EA, Buisson O, Rubio-Casillas A. Beyond the G-spot: clitourethrovaginal complex anatomy in female orgasm. *Nat Rev Urol*. 2014;11:531–8.
50. Gravina GL, Brandetti F, Martini P, Carosa E, di Stasi SM, Morano S, et al. Measurement of the thickness of the urethrovaginal space in women with or without vaginal orgasm. *J Sex Med*. 2008;5:610–8.
51. Battaglia C, Nappi RE, Mancini F, Alvisi S, del Forno S, Battaglia B, et al. 3-D volumetric and vascular analysis of the urethrovaginal space in young women with or without vaginal orgasm. *J Sex Med*. 2010;7:1445–53.
52. Maratos YK, Gombergh R, Cornier E, Minart JP, Amoretti N, Mpotsaris A. The G-spot: an observational MRI pilot study. *Bjog*. 2016;123:1542–9.
53. D'Amati G, di Gioia CR, Bologna M, et al. Type 5 phosphodiesterase expression in the human vagina. *Urology*. 2002;60:191–5.
54. Zaviačić M, Doležalová S, Holomán IK, Zaviačičová A, Mikulecký M, Brázdil V. Concentrations of fructose in female ejaculate and urine: a comparative biochemical study. *J Sex Res*. 1988;24:319–25.
55. Jannini EA, Wise N, Frangos E, Komisaruk BR. Peripheral and central neural bases of orgasm. *Textbook of Female Sexual Function and Dysfunction*. 2018:179–95.
56. Tepper SL, Jagirdar J, Heath D, Geller SA. Homology between the female paraurethral (Skene's) glands and the prostate. Immunohistochemical demonstration. *Arch Pathol Lab Med*. 1984;108:423–5.
57. Levin RJ. The G-spot—reality or illusion? *Sex Relatsh Ther*. 2003;18:117–9.
58. Kinsey AC, Institute for Sex R. *Sexual behaviour in the human female*. New York: Pocket Books; 1973.
59. Ellis H. *Studies in the psychology of sex. Vol. 5 Vol. 5*. Davis: Philadelphia/Pa; 1928.
60. Goldberg DC, Whipple B, Fishkin RE, Waxman H, Fink PJ, Weisberg M. The Grafenberg spot and female ejaculation: a review of initial hypotheses. *J Sex Marital Ther*. 1983;9:27–37.
61. Salama S, Boitrelle F, Gauquelin A, Malagrida L, Thiounn N, Desvaux P. Nature and origin of “squirting” in female sexuality. *J Sex Med*. 2015;12:661–6.
62. Korda JB, Goldstein SW, Sommer F. The history of female ejaculation. *J Sex Med*. 2010;7:1965–75.
63. Rubio-Casillas A, Jannini EA. New insights from one case of female ejaculation. *J Sex Med*. 2011;8:3500–4.
64. Pastor Z, Chmel R. Differential diagnostics of female “sexual” fluids: a narrative review. *Int Urogynecol J*. 2018;29:621–9.
65. Jannini EA, Rubio-Casillas A, Whipple B, Buisson O, Komisaruk BR, Brody S. Female orgasm(s): one, two, several. *J Sex Med*. 2012;9:956–65.
66. Buisson O, Jannini EA. Pilot echographic study of the differences in clitoral involvement following clitoral or vaginal sexual stimulation. *J Sex Med*. 2013;10:2734–40.



67. Komisaruk BR, Whipple B, Crawford A, Liu WC, Kalnin A, Mosier K. Brain activation during vaginocervical self-stimulation and orgasm in women with complete spinal cord injury: fMRI evidence of mediation by the vagus nerves. *Brain Res.* 2004;1024:77–88.
68. Fugl-Meyer KS, Oberg K, Lundberg PO, Lewin B, Fugl-Meyer A. On orgasm, sexual techniques, and erotic perceptions in 18 to 74-year-old Swedish women. *J Sex Med.* 2006;3:56–68.
69. Harris JM, Cherkas LF, Kato BS, Heiman JR, Spector TD. Normal variations in personality are associated with coital orgasmic infrequency in heterosexual women: a population-based study. *J Sex Med.* 2008;5:1177–83.
70. Burri AV, Cherkas LM, Spector TD. Emotional intelligence and its association with orgasmic frequency in women. *J Sex Med.* 2009;6:1930–7.
71. Bancroft J, Long JS, McCabe J. Sexual well-being: a comparison of U.S. black and white women in heterosexual relationships. *Arch Sex Behav.* 2011;40:725–40.
72. Mollaioli D, Di Sante S, Limoncin E, et al. Validation of a visual analogue scale to measure the subjective perception of orgasmic intensity in females: The Orgasmometer-F. *PLoS One.* 2018;13:e0202076.
73. Burri AV, Cherkas L, Spector TD. Genetic and environmental influences on self-reported G-spots in women: a twin study. *J Sex Med.* 2010;7:1842–52.
74. Jannini EA, Gravina GL, Buisson O, Foldès P, Burri AV, Cherkas L, et al. A letter to the editor on the article by Burri et al. *J Sex Med.* 2010;7:2289–94.
75. Ostrzenski A. Anatomic documentation of the G-spot complex role in the genesis of anterior vaginal wall ballooning. *Eur J Obstet Gynecol Reprod Biol.* 2014;180:186–91.
76. Whipple B. Female ejaculation, G spot, A spot, and should we be looking for spots? *Curr Sex Health Rep.* 2015;7:59–62.
77. Addiego F, Belzer EG Jr, Comolli J, Moger W, Perry JD, Whipple B. Female ejaculation: a case study. *J Sex Res.* 1981;17:13–21.
78. Rodriguez FD, Camacho A, Bordes SJ, Gardner B, Levin RJ, Tubbs RS. Female ejaculation: An update on anatomy, history, and controversies. *Clin Anat.* 2021;34:103–7.
79. Alzate H, Hoch Z. The “G spot” and “female ejaculation”: a current appraisal. *J Sex Marital Ther.* 1986;12:211–20.
80. Darling CA, Davidson JK, Conway-Welch C. Female ejaculation: perceived origins, the Grafenberg spot/area, and sexual responsiveness. *Arch Sex Behav.* 1990;19:29–47.
81. Wimpissinger F, Springer C, Stackl W. International online survey: female ejaculation has a positive impact on women's and their partners sexual lives. *BJU Int.* 2013;112:E177–E85.
82. Committee on Gynecologic Practice ACoOaG. Elective female genital cosmetic surgery: ACOG Committee Opinion, Number 795. *Obstet Gynecol.* 2020;135:e36–42.
83. Committee on Gynecologic Practice ACoOaG. ACOG Committee Opinion No. 378: vaginal “rejuvenation” and cosmetic vaginal procedures. *Obstet Gynecol.* 2007;110:737–8.
84. Wilson A, Truchanowicz EG, Elmoghazy D, MacArthur C, Coomarasamy A. Symphysiotomy for obstructed labour: a systematic review and meta-analysis. *Bjog.* 2016;123:1453–61.
85. Thacker SB, Banta HD. Benefits and risks of episiotomy: an interpretative review of the English language literature, 1860-1980. *Obstet Gynecol Surv.* 1983;38:322–38.
86. Cameron J, Rawlings-Anderson K. Female circumcision and episiotomy: both mutilation? *Br J Midwifery.* 2001;9:137–42.
87. Cipriani S, Maseroli E, Di Stasi V, et al. Effects of testosterone treatment on clitoral haemodynamics in women with sexual dysfunction. *J Endocrinol Investig.* 2021; in press.
88. Moscatelli A, Nimbi FM, Ciotti S, Jannini EA. Haptic and somesthetic communication in sexual medicine. *Sexual Medicine Reviews.* 2020.

**Publisher's Note** Springer Nature remains neutral with regard to jurisdictional claims in published maps and institutional affiliations.