PEDIATRICS®

OFFICIAL JOURNAL OF THE AMERICAN ACADEMY OF PEDIATRICS

Unmanipulated Donor Lymphocytes for EBV-Related PTLD After T-Cell Depleted HLA-Haploidentical Transplantation

Maria Debora De Pasquale, Angela Mastronuzzi, Rita De Vito, Angela Cometa, Alessandro Inserra, Cristina Russo, Maria Antonietta De Ioris and Franco Locatelli

Pediatrics 2012;129;e189; originally published online December 5, 2011;
DOI: 10.1542/peds.2011-0636

Unmanipulated Donor Lymphocytes for EBV-Related PTLD After T-Cell Depleted HLA-Haploidentical Transplantation

AUTHORS: Maria Debora De Pasquale, MD, PhD,[a] Angela Mastronuzzi, MD,[a] Rita De Vito, MD,[b] Angela Cometa, MD,[a] Alessandro Inserra, MD,[c] Cristina Russo, MD,[d] Maria Antonietta De Ioris, MD, PhD,[a] and Franco Locatelli, MD, PhD[a,e]

Departments of [a]Pediatric Hematology-Oncology, [b]Histopathology, and [c]Surgery, and [d]Microbiology Service, Istituto Di Ricovero e Cura a Carattere Scientifico, Ospedale Bambino Gesù, Rome, Italy; and [e]Department of Pediatrics, University of Pavia, Pavia, Italy

KEY WORDS
post-transplantation lymphoproliferative disorders, donor lymphocyte infusion, graft-versus-host disease, EBV-immunity

ABBREVIATIONS
ATG—anti-thymocyte globulin
CT—computed tomography
CTL—cytotoxic T lymphocyte
DLI—donor leukocyte infusion
EBER—Epstein-Barr virus-encoded RNA
EBV—Epstein-Barr virus
GvHD—graft-versus-host disease
haplo-HSCT—HLA-haploidentical hematopoietic stem cell transplantation
HSCT—hematopoietic stem cell transplantation
IFN—interferon
PB—peripheral blood
PBMC—peripheral blood mononuclear cell
PTLD—post-transplantation lymphoproliferative disorder

The authors have indicated they have no financial relationships relevant to this article to disclose.

www.pediatrics.org/cgi/doi/10.1542/peds.2011-0636

doi:10.1542/peds.2011-0636

Accepted for publication Jul 20, 2011

Address correspondence to Maria Debora De Pasquale, MD, PhD, Department of Hematology-Oncology, IRCCS, Bambino Gesù Children's Hospital, Piazza San Onofrio, 4, 00165 Rome, Italy. E-mail: mdebora.depasquale@opbg.net

PEDIATRICS (ISSN Numbers: Print, 0031-4005; Online, 1098-4275).

abstract

Epstein-Barr virus (EBV)–related post-transplantation lymphoproliferative disorder (PTLD) is a life-threatening complication in patients given T-cell-depleted hematopoietic stem cell transplantation from an HLA-haploidentical relative (haplo-HSCT). We report the case of a child who developed severe EBV-related PTLD after haplo-HSCT from his mother. Despite receiving the anti-CD20 monoclonal antibody, the patient presented with intestinal obstruction due to huge abdominal lymphadenopathy, hematemesis, and nodulary pulmonary lesions. Histology showed that the lesions were due to CD20−/CD19+ large neoplastic B cells. The patient underwent double intestinal resection with partial abdominal lymphadenectomy and then received 3 monthly doses of donor-derived unmanipulated mononuclear cells. The initial dose of CD3+ cells was 3×10^5/kg recipient body weight. The 2 additional doses consisted of 5×10^5 CD3+ cells/kg. No sign or symptom attributable to graft-versus-host disease was observed, and the patient completely cleared EBV-related lesions. The child was disease-free for 13 months after the first lymphocyte infusion. This case demonstrates that repeated infusions of controlled numbers of donor CD3+ cells cure EBV-related PTLD in haplo-HSCT without inducing graft-versus-host disease. *Pediatrics* 2012;129:e189–e194

Post-transplantation lymphoproliferative disorder (PTLD) is a well-known, severe complication of both solid organ and hematopoietic stem cell transplantation (HSCT) with a mortality rate often exceeding 50%.[1] Because of uncontrolled B-lymphocyte proliferation in immunocompromised hosts, PTLD is, in most cases, related to Epstein-Barr virus (EBV) infection or reactivation.

The main risk factors for developing PTLD after HSCT have been demonstrated to include donor-recipient HLA disparity, T-cell depletion of the graft, use of anti-thymocyte globulin (ATG) or anti-T-cell monoclonal antibodies for prevention of graft-versus-host disease (GvHD),[2,3] and number of residual B cells in the graft. Indeed, in HSCT recipients, most EBV-related PTLDs are of donor origin,[4,5] whereas they are of host origin after solid organ transplantation.[6]

PTLD is usually preceded by a preclinical phase characterized by increased EBV DNA load in peripheral blood (PB). Monitoring EBV DNA levels in PB represents a fundamental tool for early diagnosis and timely application of preemptive treatment.[7] Histologic features of PTLD range from benign hyperplasia to malignant lymphoma (World Health Organization classification).[8]

Several modalities have been explored for management of EBV PTLD, including reduction of immunosuppression, chemotherapy, antiviral drugs, anti-CD20 monoclonal antibody (rituximab), unmanipulated donor leukocyte infusion (DLI), and infusion of EBV-specific cytotoxic T lymphocytes (CTLs). However, there is still considerable controversy regarding optimal treatment.

We describe the case of a child with EBV-related PTLD after T-cell-depleted HLA-haploidentical HSCT (haplo-HSCT) who reached complete remission with DLI treatment only.

PATIENT PRESENTATION

A 3-year-old boy with β-thalassemia was referred to our hospital for intestinal obstruction due to abdominal lymphadenopathy. Six months earlier, he had received T-cell-depleted haplo-HSCT from his mother at another institution. The pre-transplantation conditioning regimen included hydroxyurea, azathioprine, fludarabine, busulphan, cyclophosphamide, and ATG.[9]

Three months after transplantation, he developed EBV-related PTLD with cervical lymphadenopathies and bone lesions. He received 8 weekly doses of rituximab, achieving a marked decrease of EBV DNA load (from 80 000 to 3000 copies/mL) and reduction in size and number of adenopathies.

One week after the last dose of rituximab, he presented with fever, hematemesis, and abdominal pain. An abdominal computed tomography (CT) scan (Fig 1) showed intestinal obstruction due to a large abdominal lymphadenopathy. The child underwent urgent surgical intervention, which consisted of double intestinal resection, partial abdominal lymphadenectomy, and formation of 2 stomas for the proximal and distal intestinal tracts. Microscopically, lymph nodes showed effacement of normal architecture with diffuse infiltration by blastic large cells with marked nuclear polymorphism. Some cells showed centroblast-like appearance, with a large vesicular chromatin pattern and 1 to several peripherally arranged nucleoli. Other cells resembled immunoblasts; cells with plasmablastic appearance were also evident. The background consisted of small lymphocytes and histiocytes. The immunophenotype of neoplastic cells was as follows: CD79a+, CD19+, Bcl6−, CD10−, CD138+, MUM1+, CD20−; percentage of Ki67 positive cells was 70%. EBV-encoded RNA (EBER) was positive in all neoplastic cells. The background of small lymphocyte showed a T (CD3+) phenotype, with prevalence of CD8+ cells (Figs 2 and 3).

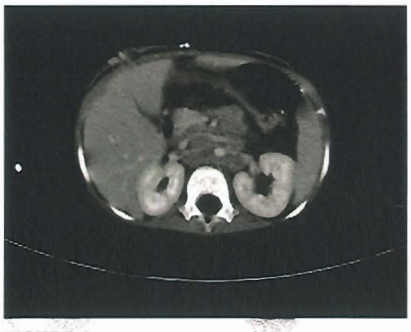

FIGURE 1
Large abdominal lymphadenopathies, present at time of PTLD diagnosis.

At that time, the EBV-DNA copy number in PB mononuclear cells (PBMCs) was 500 000/mL. One week later, another episode of severe hematemesis occurred, and a second surgical intervention was performed to remove 1 appendicular and 2 gastric lesions, both sites of PTLD. The patient was in poor general condition with persistent fever; a CT scan revealed 2 left pulmonary nodular lesions (Fig 4) and persistence of abdominal adenopathies. Biopsy of 1 pulmonary nodule confirmed the diagnosis of PTLD. We then decided to treat him with DLI from his mother. At that time, analysis of chimerism on the patient's leukocytes showed the presence of only donor cells. He received 3 monthly doses of donor-derived unmanipulated mononuclear cells. The initial dose of CD3+ cells was 3×10^5/kg recipient body weight. The dose of the 2 additional infusions was 5×10^5 CD3+ cells/kg recipient body weight. Treatment was well tolerated, without any sign or symptom of both acute and chronic GvHD. Two weeks after the first infusion, fever disappeared and EBV-DNA copies decreased to 100 000/mL. After the third infusion, the EBV DNA load was undetectable, and a CT scan showed marked reduction in size of both abdominal and pulmonary lesions (Figs 5 and 6). At present, 15 months after diagnosis of PTLD and 13 months

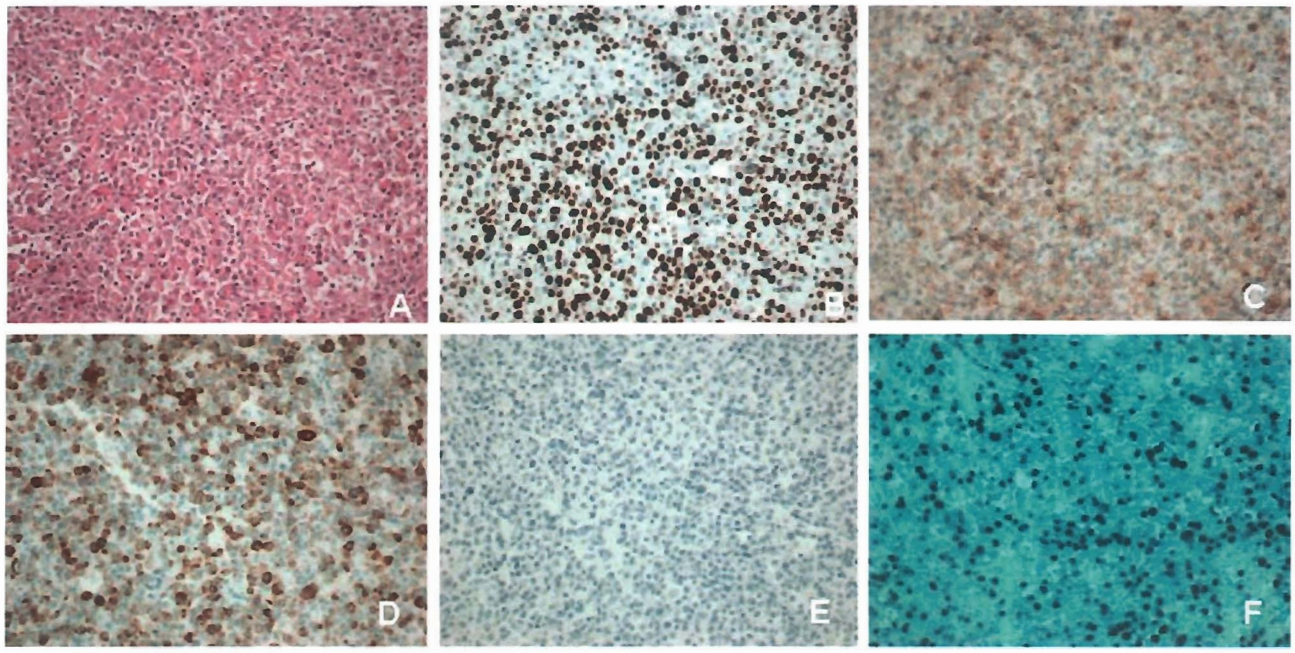

FIGURE 2
A, On conventional hematoxylin and eosin staining at higher magnification, there was evidence of a population of blastic cells with high proliferative activity, as shown by MIB-1 positivity (panel B). C, Immunolabeling confirmed the B-cellular origin of most blastic cells because they were CD19+ and CD79a+ (panel D), but CD20− (panel E). F, Blastic cells were positive for EBV-encoded RNA.

after the first DLI, the patient is well, transfusion independent, with complete donor chimerism and without any sign or symptom of PTLD; EBV-DNA load remains undetectable. Surgical intervention has been successfully performed to recanalize the intestine. To evaluate the effects of DLI administration on the frequency of interferon (IFN)-γ secreting EBV-specific T lymphocytes and on EBV-directed cytotoxic activity, PB samples were collected at baseline

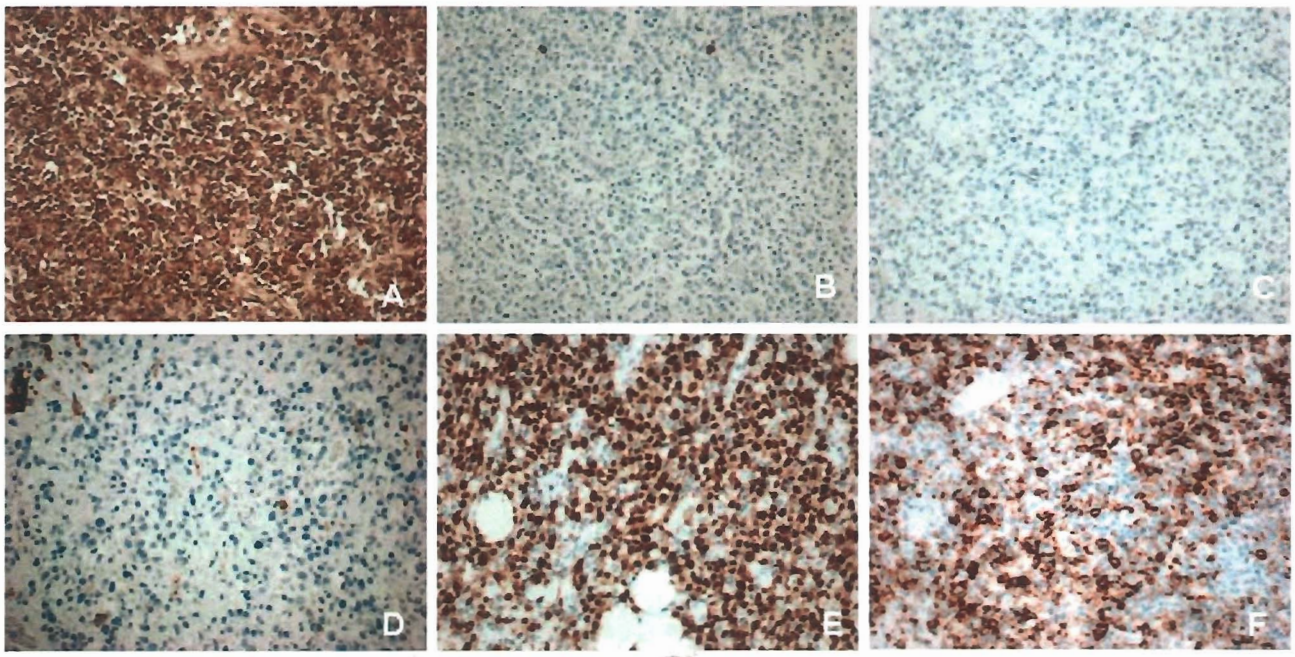

FIGURE 3
The neoplastic population was positive for λ chain (panel A), negative for κ chain (Panel B), and negative for Bcl6 (Panel C) and CD10− (Panel D), with diffuse nuclear positivity for MUM1 (Panel E) and positivity for CD138 (Panel F).

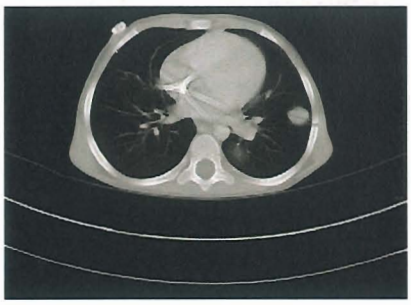

FIGURE 4
CT scan of thorax showing the presence of 2 left pulmonary nodal lesions.

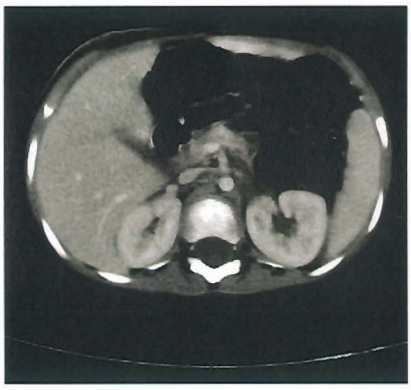

FIGURE 5
Reduction in size of abdominal lymphadenopathy observed after DLI.

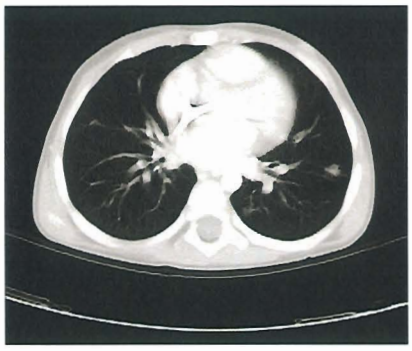

FIGURE 6
Reduction of the pulmonary lesions of PTLD observed after DLI.

and at different times after DLI (see also Table 1). IFN-γ secreting lymphocytes were measured by enzyme-linked immunospot assay, and specific cytotoxicity was evaluated by 51 chromium release assay, as previously described.[10,11] Although the frequency of EBV-responding cells was nearly undetectable before transplantation (mean: 3.5 spots/10^5 PBMCs), it significantly increased after the second DLI (mean: 429 spots/10^5 PBMCs, see also Table 1 for additional details), remaining stable thereafter. Likewise, the lytic activity against donor B-lymphoblastoid cell line significantly increased after DLI (cytotoxicity at a 5:1 effector to target ratio being 5% and 39%, before and after the second administration of donor cells, respectively; see Table 1 for additional details).

TABLE 1 Frequency of IFN-γ Secreting EBV-Specific T Lymphocytes and Percentage of Cytotoxicity Against EBV LCL at Different Time Points After Beginning of DLI

	Before DLI	After First DLI	After Second DLI	3 Mo After Third DLI
IFN-γ secreting EBV-specific T lymphocytes	3.5 spots/10^5 PBMCs	50 spots/10^5 PBMCs	429 spots/10^5 PBMCs	320 spots/10^5 PBMCs
Cytotoxicity against EBV LCL (effector to target ratio 5:1)	5%	15%	39%	30%

LCL, lymphoblastoid cell lines.

DISCUSSION

PTLD is usually sustained by EBV-driven B-lymphocyte proliferation in immunocompromised individuals, although EBV-negative cases, as well as cases of T/NK lymphoproliferation, have been reported.[12–14] The degree of pharmacological immunosuppression and HLA mismatch, as well as the absence of protective levels of virus-specific T cells, are the main risk factors for developing PTLD.[15]

Treatment of EBV-related PTLD is aimed at either reducing the tumor burden through antiviral agents,[12,16] cytotoxic drugs,[15–17] and B-cell directed monoclonal antibodies[14,16,18–20] or at restoring virus-specific immunity by reducing pharmacological immunosuppression[21] or infusing CTL. In HSCT recipients, although chemotherapy administered early after transplantation is contraindicated considering its myelotoxicity, rituximab has proved to be effective in preventing and treating overt PTLD in 40% to 60% of patients.[14,18,19] However, relapses have been observed after anti-CD20 therapy, in large part because of selection of a CD19+, CD20− tumor cell population.[18]

An alternative treatment is represented by targeted cell therapy that selectively abrogates the EBV-bearing tumor cell compartment. Determination of neoplastic cell origin is fundamental in using the cell therapy approach, because the choice of the source of T cells to be used will also depend on this information. Indeed, most cases of EBV-related PTLD after HSCT are of donor origin.[4,5] The first attempt at EBV-directed adoptive immunotherapy in humans demonstrated that remission of PTLD could be achieved in HSCT recipients through the administration of unselected donor leukocytes.[22] However, this treatment is potentially associated with development of GvHD because of the concomitant transfer of alloreactive T cells. Therefore, 2 approaches have been explored to reduce the risks related to alloreactivity associated with DLI: introduction of a suicide gene (ie, herpes thymidine kinase) into donor lymphocytes[23] and ex vivo production of EBV-specific CTL.[24]

The infusion of EBV-specific polyclonal CTLs proved to be safe and effective in the prevention of EBV-related PTLD.[24–26] Moreover, HSCT recipients developing clinically overt PTLD may reach complete remission after CTL therapy,[18,24,26] with evidence of T-cell homing to tumor lesions. Infusion of virus-specific polyclonal CTLs, containing both CD4+ and CD8+ lymphocytes, was effective in restoring antigen-specific long-term immunologic memory.[18,24–26] Gene marking studies have shown the persistence of these donor-derived EBV-specific T cells

in patients' PB for years after infusion, as well as their in vivo reexpansion during episodes of viral reactivation.[26]

Our patient, having received T-cell-depleted HSCT after a conditioning regimen including ATG, presented many risk factors for development of EBV PTLD. At the onset, he was successfully treated with rituximab, after 8 courses presenting with a marked decrease of EBV DNA load and reduction in size and number of the adenopathies. Unfortunately, as previously reported,[18] because of selection of CD20-negative tumor cell population, the lymphoproliferative disease subsequently progressed, coupled with an increase in EBV load. Consistent with this interpretation, after rituximab, the immunophenotype of tumor cells in the neoplastic masses was CD19+, CD20−. When the child was referred to our hospital, besides the surgical approach, the only treatment available seemed to be T-cell therapy with DLI. Unfortunately, EBV-specific CTLs had not been previously prepared and were unavailable. In view of the poor clinical condition of the patient and the negativity of tumor cells for CD20, we were compelled to try DLI from the mother despite the high risk of inducing serious GvHD. To minimize this risk, we infused a low number of CD3+ cells. Notably, 2 weeks after the first infusion, the fever disappeared, and a marked decrease of EBV-DNA copies was recorded. After the third infusion, the EBV load was undetectable, and a CT scan showed complete resolution of all PTLD lesions. The short time interval required for response to DLI is suggestive of a rapid in vivo expansion of the infused EBV-specific T cells in response to the presence of the antigen, as previously described by Heslop et al.[26] Support to this hypothesis is provided by the increase in both number of IFN-γ secreting EBV-specific T lymphocytes and EBV-directed cytotoxic activity. Treatment was well tolerated, and no signs of GvHD were recorded. The fact that our patient was a child and less prone to GvHD may have contributed to the favorable outcome.

Although infusion of EBV-specific CTLs is currently the best choice for cell therapy of PTLD, this immunotherapy has been confined to few selected centers with specialized good manufacturing practice laboratories. Moreover, expansion of suitable numbers of virus-specific CTLs requires a certain time and experienced laboratories, both factors limiting their potential for use. The use of HLA partially matched, third-party allogeneic CTL may be a feasible option,[27,28] provided that the financial burden of supporting a CTL bank is covered by a willing institution.

Our case study suggests that DLI based on the use of repeated doses of a limited number of CD3+ cells may represent a valuable alternative when CTLs are not available.

ACKNOWLEDGMENT

This work was partly supported by the special "5 per Mille" grant from the Associazione Italiana per la Ricerca sul Cancro assigned to Dr Locatelli.

REFERENCES

1. Opelz G, Döhler B. Lymphomas after solid organ transplantation: a collaborative transplant study report. *Am J Transplant.* 2004;4(2):222–230
2. Gerritsen EJ, Stam ED, Hermans J, et al. Risk factors for developing EBV-related B cell lymphoproliferative disorders (BLPD) after non-HLA-identical BMT in children. *Bone Marrow Transplant.* 1996;18(2):377–382
3. Curtis RE, Travis LB, Rowlings PA, et al. Risk of lymphoproliferative disorders after bone marrow transplantation: a multi-institutional study. *Blood.* 1999;94(7):2208–2216
4. Shapiro RS, McClain K, Frizzera G, et al. Epstein-Barr virus associated B cell lymphoproliferative disorders following bone marrow transplantation. *Blood.* 1988;71(5):1234–1243
5. Zutter MM, Martin PJ, Sale GE, et al. Epstein-Barr virus lymphoproliferation after bone marrow transplantation. *Blood.* 1988;72(2):520–529
6. Baldanti F, Grossi P, Furione M, et al. High levels of Epstein-Barr virus DNA in blood of solid-organ transplant recipients and their value in predicting posttransplant lymphoproliferative disorders. *J Clin Microbiol.* 2000;38(2):613–619
7. Baldanti F, Gatti M, Furione M, et al. Kinetics of Epstein-Barr virus DNA load in different blood compartments of pediatric recipients of T-cell-depleted HLA-haploidentical stem cell transplantation. *J Clin Microbiol.* 2008;46(11):3672–3677
8. Swerdlow SH, Webber SA, Chadburn A, et al. Post transplant lymphoproliferative disorders. In: Swerdlow SH, Campo E, Harris NL, eds. *Classification of Tumours of Haematopoietic and Lymphoid Tissues.* 4th ed. Lyon, France: International Agency for Research on Cancer; 2008:342–349
9. Sodani P, Isgrò A, Gaziev J, et al. Purified T-depleted, CD34+ peripheral blood and bone marrow cell transplantation from haploidentical mother to child with thalassemia. *Blood.* 2010;115(6):1296–1302
10. Comoli P, Labirio M, Basso S, et al. Infusion of autologous Epstein-Barr virus (EBV)-specific cytotoxic T cells for prevention of EBV-related lymphoproliferative disorder in solid organ transplant recipients with evidence of active virus replication. *Blood.* 2002;99(7):2592–2598
11. Comoli P, Pedrazzoli P, Maccario R, et al. Cell therapy of stage IV nasopharyngeal carcinoma with autologous Epstein-Barr virus-targeted cytotoxic T lymphocytes. *J Clin Oncol.* 2005;23(35):8942–8949
12. Cohen JI. Epstein-Barr virus infection. *N Engl J Med.* 2000;343(7):481–492
13. Williams H, Crawford DH. Epstein-Barr virus: the impact of scientific advances on clinical practice. *Blood.* 2006;107(3):862–869
14. Gottschalk S, Rooney CM, Heslop HE. Post-transplant lymphoproliferative disorders. *Annu Rev Med.* 2005;56:29–44
15. Gross TG, Steinbuch M, DeFor T, et al. B cell lymphoproliferative disorders following hematopoietic stem cell transplantation: risk factors, treatment and outcome. *Bone Marrow Transplant.* 1999;23(3):251–258
16. Comoli P, Rooney CM. Treatment of Epstein-Barr virus infections. In: Jenson HB, Tselis

A, eds. *Epstein-Barr Virus*. New York, NY: Taylor & Francis; 2006:351–372

17. Gross TG, Bucuvalas JC, Park JR, et al. Low-dose chemotherapy for Epstein-Barr virus-positive post-transplantation lymphoproliferative disease in children after solid organ transplantation. *J Clin Oncol*. 2005;23 (27):6481–6488
18. Comoli P, Basso S, Zecca M, et al. Preemptive therapy of EBV-related lymphoproliferative disease after pediatric haploidentical stem cell transplantation. *Am J Transplant*. 2007;7 (6):1648–1655
19. van Esser JWJ, Niesters HGM, van der Holt B, et al. Prevention of Epstein-Barr virus-lymphoproliferative disease by molecular monitoring and preemptive rituximab in high-risk patients after allogeneic stem cell transplantation. *Blood*. 2002;99(12):4364–4369
20. Choquet S, Leblond V, Herbrecht R, et al. Efficacy and safety of rituximab in B-cell post-transplantation lymphoproliferative disorders: results of a prospective multicenter phase 2 study. *Blood*. 2006;107(8):3053–3057
21. Starzl TE, Nalesnik MA, Porter KA, et al. Reversibility of lymphomas and lymphoproliferative lesions developing under cyclosporin-steroid therapy. *Lancet*. 1984;1 (8377):583–587
22. Papadopoulos EB, Ladanyi M, Emanuel D, et al. Infusions of donor leukocytes to treat of Epstein-Barr virus-associated lymphoproliferative disorders after allogeneic bone marrow transplantation. *N Engl J Med*. 1994;330(17):1185–1191
23. Bonini C, Ferrari G, Verzeletti S, et al. HSV-TK gene transfer into donor lymphocytes for control of allogeneic graft-versus-leukemia. *Science*. 1997;276(5319):1719–1724
24. Rooney CM, Smith CA, Ng CYC, et al. Infusion of cytotoxic T cells for the prevention and treatment of Epstein-Barr virus-induced lymphoma in allogeneic transplant recipients. *Blood*. 1998;92(5):1549–1555
25. Gustafsson A, Levitsky V, Zou JZ, et al. Epstein-Barr virus (EBV) load in bone marrow transplant recipients at risk to develop posttransplant lymphoproliferative disease: prophylactic infusion of EBV-specific cytotoxic T cells. *Blood*. 2000;95(3):807–814
26. Heslop HE, Ng CYC, Li C, et al. Long-term restoration of immunity against Epstein-Barr virus infection by adoptive transfer of gene-modified virus-specific T lymphocytes. *Nat Med*. 1996;2(5):551–555
27. Haque T, Wilkie GM, Jones MM, et al. Allogeneic cytotoxic T-cell therapy for EBV-positive post-transplantation lymphoproliferative disease: results of a phase 2 multicenter clinical trial. *Blood*. 2007;110(4):1123–1131
28. Barker JN, Doubrovina E, Sauter C, et al. Successful treatment of EBV-associated post-transplantation lymphoma after cord blood transplantation using third-party EBV-specific cytotoxic T lymphocytes. *Blood*. 2010;116(23): 5045–5049