



Correspondence

Solitary fibrous tumor of the pleura in a 6-year-old boy

To the Editor,

Solitary fibrous tumor (SFT) is a rare tumor that occurs most commonly in the pleura and other serosal surfaces such as pericardium and peritoneum [1]. Extrapleural sites of SFT, including the soft tissues and visceral organs, have also been reported [2,3]. In adults, most SFT are benign, but 13% to 36% may be malignant [4,5]. The incidence in children is lower than in adults with only 11 cases reported in the literature, compared with the 800 noted in adult series [6,7]. More than 50% of the pediatric cases had a thoracic localization. Only 1 case was considered malignant compared with 13% to 36% cases of malignant SFT seen in adult series [7].

A six-year-old boy was referred to our institution for a solitary mass in the right hemithorax. The tumor was found incidentally on a chest radiograph taken in another hospital evaluating the patient for fever and cough. Blood tests upon admission were all within normal limits, including urinary catecholamines, serum α -fetoprotein, and carcinoembryonic antigen. On physical examination, auscultation of the chest revealed hypoventilation of the medium-basal right lobe of the lung. Chest radiograph showed a marked opacity of the right thorax, whereas computed tomographic scans showed a large lesion in the right hemithorax compressing the lung with relevant left-sided mediastinal shift (Fig. 1A).

The mass was contiguous to the anterior and lateral chest wall without any vascular compression. Pericardial infiltration and effusion with right atrioventricular collapse were confirmed by echocardiography. Because of a rapid worsening of his general condition, the patient underwent surgical intervention. Through a median sternotomy incision, a voluminous complex mass arising from the inferior mediastinum, shifting the heart, and collapsing the lung was observed. Pericardiotomy was performed to evacuate the effusion and remove any infiltration of the lesion inside the right anterolateral pericardium. The pericardial defect was partially closed to avoid cardiac herniation and permit spontaneous drainage of any residual effusion. The tumor was dissected from the pericardium, chest wall, and the diaphragm and removed en bloc with no macroscopic residual tumor. Neither extrapleural dissection nor diaphragmatic resection were necessary to achieve complete removal. Multiple frozen

sections obtained from biopsies of those regions were also negative for microscopic disease. Bone marrow biopsies and marrow aspiration were also done. The child was transferred to the intensive care unit, where he stayed until the fifth postoperative day. The postoperative period was unremarkable with no signs of infection or cardiac alterations. Macroscopic examination showed a complex tumor measuring 13.5 × 9 × 9 cm partially covered by a white and translucent pseudocapsule. Histopathologic examination revealed a massive proliferation of spindle-shaped cells with a background fibroblast-like pattern (Fig. 1B). High-proliferation index (24 × 10 high-power field) was evident, as well as a hemangiopericytoma-like vascular component and many necrotic areas with myxoid elements. Radical excision was confirmed by histopathologic examination showing negative margins of the resection. Cytologic analysis of the pericardial effusion was negative for neoplastic cells.

Immunohistochemical stains were positive for vimentin, CD34 (Fig. 1C), Bcl2, and CD99 but negative for actin, desmin, myogenin, S100, cytokeratin MNF116, cytokeratin 7, cytokeratin AE1/3, epithelial membrane antigen, and neuron specific enolase. To exclude the possibility of synovial sarcoma and recognizing that a wide variety of karyotypic anomalies and numeric and structural abnormalities have been detected in SFT [1], biologic studies were performed, which were negative for t(X;18)(q11;q11) and absence of anomalies for the SYT-SSX1 and SYT-SSX2 transcripts. Based on these findings, no adjunctive chemotherapy was administered. Two months later, the patient underwent surveillance computed tomographic scans, which showed no evidence of disease recurrence. Twelve months later, the patient is alive and disease free.

Solitary fibrous tumor of the pleura has been described in all age groups from 30 months to 87 years, with a peak in the sixth and seventh decades of life and being very rare in childhood. Distribution is similar between men and women [6,7]. Most of the patients with malignant pleural SFT are symptomatic and present with large tumors [6,7]. Symptoms usually include cough, chest pain, and dyspnea. More rarely, hemoptysis and pneumonia are observed as a result of airway obstruction. Digital clubbing and hypertrophic pulmonary osteoarthropathy (Pierre-Marie-Bamberg syndrome) have been described in 10% to 20% of patients with either benign

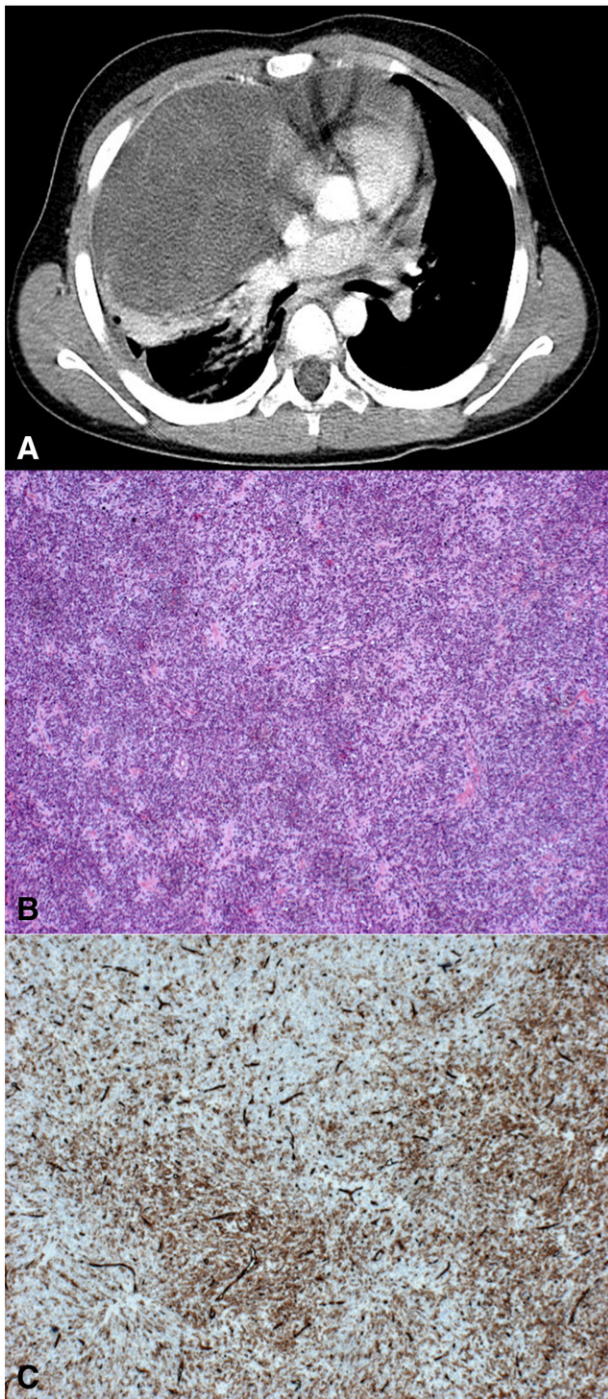


Fig. 1 A, Large lesion of the right side of thorax, causing compression of the lung, mediastinal shift. B, Microscopic appearance of the neoplasm: dishomogeneous cellularity with oval and spindle-shaped cells in a hemangiopericytoma pattern are interposed to fibrous areas of low cellularity (Hematoxylin & eosin staining, original magnification $\times 4$). C, CD34 immunohistochemical staining shows strong reactivity in both tumor and endothelial cells (original magnification $\times 4$).

or malignant SFT [6,7]. These clinical features usually resolve within 2 to 5 months, or sometimes longer, after removal of the tumor but may reappear with tumor

recurrence [6,7]. The causes of digital clubbing and hypertrophic pulmonary osteoarthropathy may be related to an abnormal production of hepatocyte growth factor for the former and an excessive release of hyaluronic acid by the tumor for the latter finding [8]. In less than 5% of patients, SFT may also secrete insulinlike growth factor II, which causes refractory hypoglycemia (Doege-Potter syndrome) [6]. A high serum level of insulinlike growth factor II is typically associated with low levels of insulin and insulinlike growth factor I, which return to normal values within 3 to 4 days after resection of the tumor [9].

Surgical resection is the treatment of choice for SFT [9-11]. The goal of surgery is complete excision of the mass with clear margins and minimal resection of parenchyma. Resection with a 1- to 2-cm tumor-free margin is recommended. The operative approach and extent of surgical excision should be dictated by the size and location of the SFT. The most common presentation of SFT is the pedunculated form, which may be successfully excised by video-assisted thoracoscopic surgery, usually performed for mediastinal tumors measuring less than 6 cm in diameter without invasion of the major vessels and chest wall [9]. Extreme caution should be used to avoid contact between the tumor and the thoracoscopic sites because contact metastasis and local recurrence at the port sites have been reported [9]. Large sessile tumors can be difficult to resect because of extensive adhesions and may occasionally require a lobectomy or a pneumonectomy to achieve complete resection [10,11]. In 3% or less of cases, the tumor may be "inverted," growing inside the lung parenchyma; these tumors often require lobectomy or sleeve resection [7,11].

The role of adjuvant therapy in SFT has not been systematically explored, but some authors suggest that radiotherapy and chemotherapy may be beneficial in selected patients. Suter et al [12] reported 9 cases of malignant SFT: 5 recurred, which resulted in death in 2 cases. One benign tumor recurred after 1 year and was treated successfully by repeat resection and radiotherapy. Veronesi et al [13] reported significant reduction of tumor size in an inoperable recurrent SFT after administration of ifosfamide and adriamycin. Currently, De Perrot [14] recommends adjuvant therapy after resection of malignant sessile tumors, particularly if they are recurrent. Brachytherapy and photodynamic therapy as well as other therapies proposed for the treatment of other pleural malignancies (ie, pleural mesothelioma) could also be considered for SFT, especially if they cannot be completely resected. However, the use of such therapies has rarely been reported, and data concerning follow-up are scant [14].

Laura Merli
Alessandro Crocoli
General and Thoracic Surgery Unit
Bambino Gesù Pediatric Hospital
Piazza S. Onofrio 4, 00165, Rome, Italy
E-mail address: alessandro.crocoli@opbg.net

Renata Boldrini
*Pathology Unit
 Bambino Gesù Pediatric Hospital
 Piazza S.Onofrio 4, 00165, Rome, Italy*

Alessandro Inserra
*General and Thoracic Surgery Unit
 Bambino Gesù Pediatric Hospital
 Piazza S.Onofrio 4, 00165, Rome, Italy*

doi:10.1016/j.jpedsurg.2011.10.072

References

- [1] Torabi A, Lele SM, DiMaio D, et al. Lack of a common or characteristic cytogenetic anomaly in solitary fibrous tumor. *Cancer Genet Cytogenet* 2008;181(1):60-4.
- [2] Van de Rijn M, Lombard CM, Rouse RV. Expression of CD34 by solitary fibrous tumors of the pleura, mediastinum, and lung. *Am J Surg Pathol* 1994;18:814-20.
- [3] Travis WD. Sarcomatoid neoplasms of the lung and pleura. *Arch Pathol Lab Med* 2010;134(11):1645-58.
- [4] England DM, Hochholzer L, McCarthy MJ. Localized benign and malignant fibrous tumors of the pleura: a clinicopathologic review of 223 cases. [erratum in *Am J Surg Pathol*. 1991; 15(8):818] *Am J Surg Pathol* 1989;13(8):640-58.
- [5] De Perrot M, Fischer S, Bründler MA, et al. Solitary fibrous tumors of the pleura. *Ann Thorac Surg* 2002;74:285-93.
- [6] Briselli M, Mark EJ, Dickersin GR. Solitary fibrous tumors of the pleura: eight new cases and review of 360 cases in the literature. *Cancer* 1981;47:2678-89.
- [7] Kanamori Y, Hasizume K, Sugiyama M, et al. Intrapulmonary solitary fibrous tumor in a eight-years-old male. *Pediatr Pulmonol* 2005;40:261-4.
- [8] Hojo S, Fujita J, Yamadori I, et al. Hepatocyte growth factor and digital clubbing. *Intern Med* 1997;36:44-6.
- [9] Cardillo G, Facciolo F, Cavazzana AO, et al. Localized (solitary) fibrous tumors of the pleura: an analysis of 55 patients. *Ann Thorac Surg* 2000;70:1808-12.
- [10] Thakkar RG, Shah S, Dumbre A, et al. Giant solitary fibrous tumour of pleura—an uncommon intrathoracic entity—a case report and review of literature. *Ann Thorac Cardiovasc Surg* 2011;17:400-3.
- [11] Furukaka N, Hansy B, Niedermeyer J, et al. A silent gigantic solitary fibrous tumor of the pleura: case report. *J Cardiothorac Surg* 2011;6(1):122.
- [12] Suter M, Gebhard S, Boumghar M, et al. Localized fibrous tumours of the pleura: 15 new cases and review of the literature. *Eur J Cardiothorac Surg* 1998;14:453-9.
- [13] Veronesi G, Spaggiari L, Mazzarol G, et al. Huge malignant localized fibrous tumor of the pleura. *J Cardiovasc Surg* 2000;41:781-4.
- [14] De Perrot M. Fibrous tumors of the pleura. *Curr Treatment Options Oncol* 2000;1:293-8.

Glowing in the dark: should the time of day determine radiographic imaging in the evaluation of abdominal pain in children?

To the Editor,

I read with interest the article titled “Glowing in the dark: time of day as a determinant of radiographic imaging in the

evaluation of abdominal pain in children” written by Burr et al and published in the January issue of the *Journal of Pediatric Surgery* [1]. The authors have highlighted the important issue of utilization patterns of ultrasonography (US) vs computed tomography (CT) in the evaluation of abdominal pain in children during the day and night. The authors have also raised concern for the relatively increased usage of the CT scan facility at night because of nonavailability of a radiologist at night. I find the article very interesting on several accounts and also have some pertinent queries as detailed below.

Whether, and if so, when a patient with abdominal pain should undergo US or CT or US followed by CT should be dictated by the history, detailed clinical assessment, and provisional diagnosis of the patient and not by the time of the day as has been noted in this study. As a general rule, all patients with an acute abdomen particularly pediatric patients who require imaging should first undergo US. The CT scan should be reserved as a complementary or problem-solving tool when US is suboptimal or equivocal for any reason. A dedicated US would obviate the need for a CT scan in a significant number of cases and also suggest alternative and quite often nonsurgical diagnosis, thereby reducing the number of unnecessary surgical procedures. Under no circumstances should CT be used as an alternative to US because of a lack of emergency radiologists in a facility. I cannot think of a tertiary care hospital without an on-call radiologist or at least a radiology resident. Ideally, such patients can be referred to a hospital where the requisite facilities exist.

Another question is that if radiologists are not available for US, then who interprets the CT scans? Are the emergency department physicians or surgeons competent enough to interpret the CT scans? It may be mentioned here that, although CT scan is considered to be more objective and reproducible than US, there is a lot of subjectivity involved in the interpretation of CT scans particularly in the emergency setting. Besides, the technique of CT scans, ideally, should not be left entirely up to the discretion of the CT technician particularly when dealing with pediatric patients where radiation dose reduction depends on the CT technique and length of coverage.

Emergency department physicians can be encouraged to learn and practice preliminary/basic US in the emergency setting in the absence of a radiologist. It could be quite useful if one can diagnose free fluid in the abdomen (especially in the pelvis), probe tenderness in a particular area, identify the presence or absence of hydronephrosis, and others, which really does not require extensive training.

Another point, which the authors have also highlighted, is that not all patients with abdominal pain who arrive in the emergency department especially at night need to be hastily subjected to imaging. What is needed is a thorough clinical assessment and, if required, admit the patient. There is a definite role for observation, initial hematologic investigations, provisional treatment, and periodic reevaluation in