



## Pleural thymoma: Radiological and histological findings

Eliseo Picchi<sup>a,b</sup>, Francesca Di Giuliano<sup>a,b,\*</sup>, Donatella Ferrari<sup>a,b</sup>, Chiara Adriana Pistolese<sup>a,b</sup>, Francesco Garaci<sup>a,b</sup>, Roberto Floris<sup>a,b</sup>

<sup>a</sup> Diagnostic Imaging and Neuroradiology, Policlinico Tor Vergata, Viale Oxford 81, 00133, Rome, Italy

<sup>b</sup> Department of Biomedicine and Prevention, UOC of Diagnostic Imaging, University of Rome "Tor Vergata", Viale Oxford 81, 00133, Rome, Italy

### ARTICLE INFO

#### Keywords:

Pleural thymoma

X-ray

Computed tomography

Positron emission tomography

Radiological staging

### 1. Introduction

Epithelial thymic tumors (thymoma and thymic carcinoma) are rare neoplasms. The incidence of thymomas is estimated to be 0.15 cases per 100,000 persons/year in the USA [1] and it represents less than 1% of primary malignancies in adults. However, it remains the most common primary neoplasm of the anterior mediastinum, accounting for 20% of tumors in this location [2]. Ectopic thymomas have been described in the neck, middle mediastinum, posterior mediastinum, lung and pleura; few reports have described giant intrathoracic tumors, but they account only 4% of all thymomas [3,4]. Usually, about 70% of patients with thymomas remains asymptomatic; the rest of patients may present local symptoms related to tumor encroaching on surrounding structures like cough, chest pain, superior vena cava syndrome, dysphagia, and hoarseness of voice. Only 30% of patients with thymoma has clinic related to myasthenia gravis. An additional 5% of patients have other systemic syndromes including red cell aplasia, dermatomyositis, systemic lupus erythematosus, Cushing syndrome and syndrome of inappropriate antidiuretic hormone secretion (SIHAD) [5].

The aim of this report is to describe the main radiological finding on X-ray, computed tomography (CT) and positron emission tomography (PET), in a case of pleural thymoma. We also report how perform radiological thymoma staging.

### 2. Case discussion

A 49-years old Caucasian woman was admitted at our Emergency Department with shortness of breath and mild respiratory discomfort. She has no significant past medical history and she has never smoked. No history of cough, fever, weight loss or night sweat had been detected. There were no allergies, no exposure to active tuberculosis, but she reported a history of exposure to asbestos. Cardiovascular examination was normal. There was no significant lymphadenopathy or thyromegaly. Respiratory sounds were impaired on the right lung. No abnormalities were detected in blood chemistry.

A first chest X-Ray (Fig. 1) executed in posterior-anterior (PA) and lateral projection, showed multiple nodules, hilar-mediastinal enlargement and nodular radiopacity at right hilum; also, pleural effusion on the right lung and obliteration of ipsilateral costophrenic angle was detected.

Abdomen Ultrasound (US) has been performed in order to exclude any pathological masses, primary neoplasm or metastatic disease. As collateral findings, US confirmed the pleural effusion with multiple solid rounded masses at pulmonary bases (Fig. 2).

Total-body CT scan was performed using a Lightspeed VCT 64-slice (General Electric, Boston, Massachusetts USA), with a pre-contrast phase, and a parenchymal phase, 70 s after administration of 120 mL of non-ionic contrast agent injection (350 mg I/ml, 2.5 mL/s.). The CT (Fig. 3), revealed a large mediastinal mass overrunning the right

**Abbreviations:** CT, computed tomography; PET, positron emission tomography; PA, posterior-anterior; CECT, contrast enhanced computed tomography; <sup>18</sup>F-FDG, <sup>18</sup>F-fluorodeoxyglucose; ROI, region of interest; MRI, magnetic resonance imaging; RECIST, response evaluation criteria in solid tumors; ITMIG, International Thymic Malignancy Interest Group

\* Corresponding author at: Diagnostic Imaging and Neuroradiology, Policlinico Tor Vergata, Viale Oxford, 81., Rome, 00133, Italy.

E-mail addresses: [eliseo.picchi@hotmail.it](mailto:eliseo.picchi@hotmail.it) (E. Picchi), [francescadigiuliano@msn.com](mailto:francescadigiuliano@msn.com) (F. Di Giuliano), [donatella.ferrari91@gmail.com](mailto:donatella.ferrari91@gmail.com) (D. Ferrari), [chiarapistolese@gmail.com](mailto:chiarapistolese@gmail.com) (C.A. Pistolese), [garaci@gmail.com](mailto:garaci@gmail.com) (F. Garaci), [roberto.floris@uniroma2.it](mailto:roberto.floris@uniroma2.it) (R. Floris).

<https://doi.org/10.1016/j.ejro.2018.08.003>

Received 7 August 2018; Received in revised form 12 August 2018; Accepted 12 August 2018

2352-0477/ © 2018 The Authors. Published by Elsevier Ltd. This is an open access article under the CC BY-NC-ND license (<http://creativecommons.org/licenses/by-nc-nd/4.0/>).

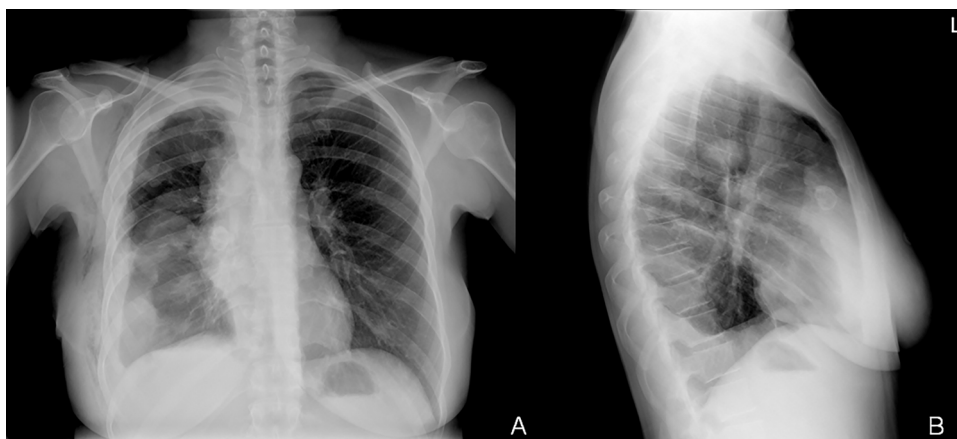


Fig. 1. Chest X-ray, on posterior-anterior (A) and lateral (B) views, demonstrates hilar-mediastinal enlargement with multiple nodular radiopacities in right hemithorax and pleural effusion on the same side.

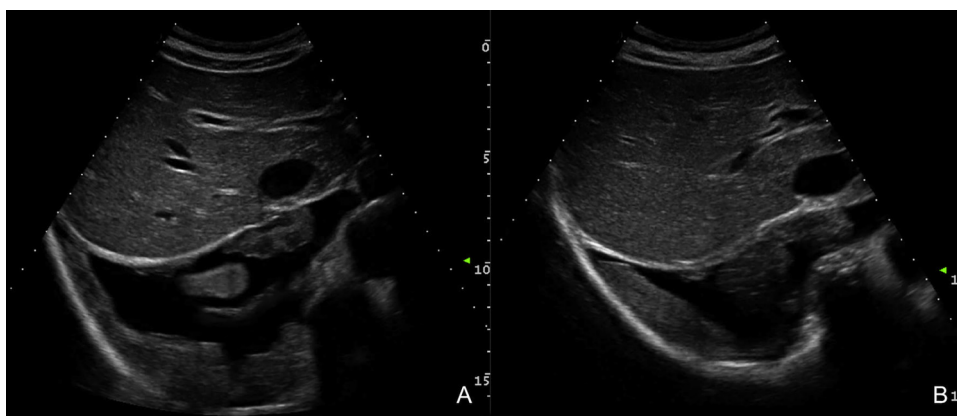


Fig. 2. Abdomen Ultrasound (A and B) showed lobular and inhomogeneous masses in the right hemithorax with pleural effusion.

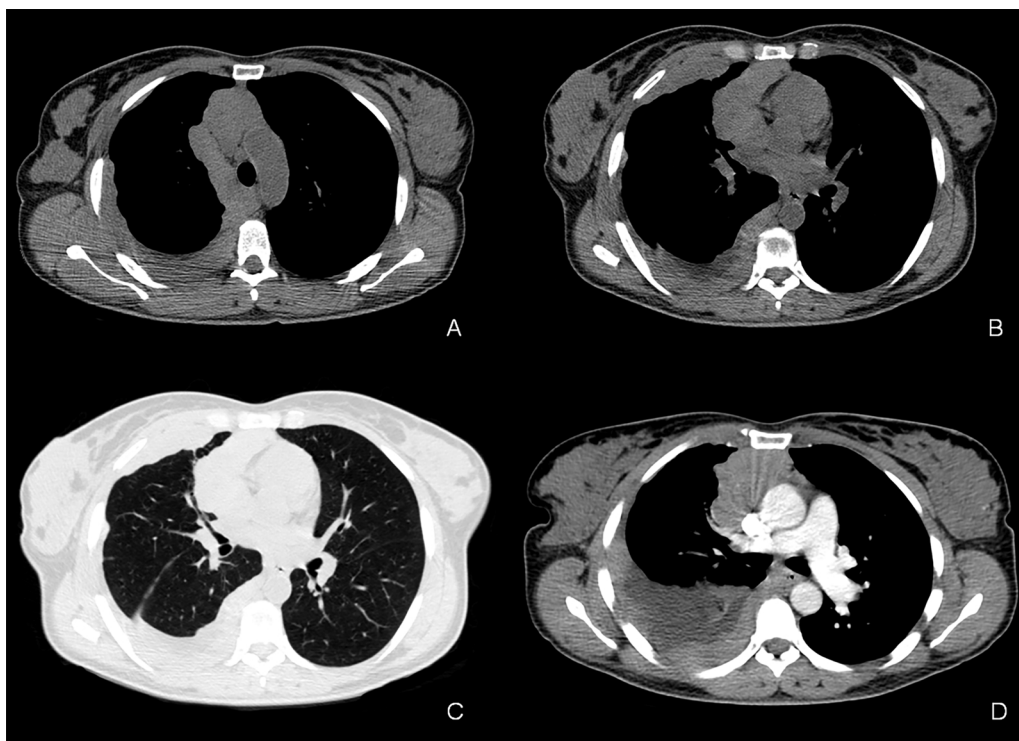


Fig. 3. Chest Computed Tomography (CT) axial plane, on mediastinal windows, showing multiple masses in mediastinum and right pleura, with pleural free fluid, without displacement of mediastinal structures (A–B). No bronchial compression or atelectasis of lung is noted on lung window (C). After injection of iodinated contrast, the lesion appears hypo-vascular, with enhancing margins, internal lobulation and septation, and few calcific spots (D).

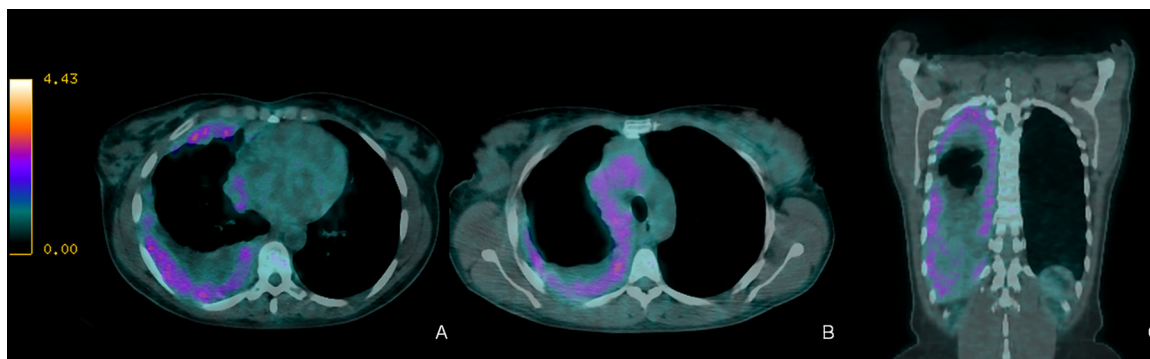


Fig. 4. Positron Emission Tomography (PET) images show increased uptake of <sup>18</sup>F-fluorodeoxyglucose in the parietal and mediastinal pleura of right lung (A–B). Chest and abdomen coronal section demonstrates no further uptakes suspicious for recurrences (C).

hemithorax, with pleural free fluid and multiple solid pleural masses on the right. No displacement of mediastinal structures has been noted. After injection of iodinated contrast, the lesions appear hypo-vascular, with enhancing margins, internal lobulation and septation, and few calcific spots. No direct endoluminal invasion in the main mediastinal vessels has been detected.

Contrast Enhanced CT (CECT) scan of abdomen, pelvis and brain was negative.

During the hospitalization the patient underwent to <sup>18</sup>F-fluorodeoxyglucose (FDG)-PET (Fig. 4): the patient received intravenous injection of <sup>18</sup>F-FDG (radioactivity: 371 mBq) and rested for 45 min before PET-scan. The mass showed an increased uptake involving the parietal, mediastinal and diaphragmatic pleura of right lung. Two Region of Interest (ROI) were positioned (Fig. 5): the first one on anterior chest wall (ROI 1: SUV 3,6), the second one near the posterior cost-vertebral arch (ROI 2: SUV 4,4) and maximum standardized uptake values were calculated.

Subsequently a CT-guided percutaneous biopsy (14 G cutting needle) of the mass in the right hemithorax was performed. Histopathological examination (Fig. 6) revealed a tissue made-up by bands of sclerosis and average size lymphocytes with T-immature phenotype (precursor T cell, CD3+, CD5+/-, CD4+, CD8+, TdT+),

associated also with irregular oval shape epithelial cells (CKAE1-AE3+, Calretinin-).

The above-mentioned histological findings are consistent with thymoma type B2 (cortical).

After definitive diagnosis of thymoma and disease staging, the patient chose to receive treatment in another Institute and so we lost her to follow-up.

### 3. Discussion

Thymoma originates from the epithelial thymic cells, is the most common neoplasm of anterior mediastinum and the most important primitive thymic tumor, resulting in 15–20% of all the primitive mediastinal masses. Patients, frequently are between 50–60 years old, being this neoplasm extremely rare before 20 years [7], with a slight male predominance [5]. No particular risk factors have been identified, however in addition to the typical association with myasthenia gravis, a correlation with other autoimmune diseases has also been noted.

Due to the embryological origin of the thymus from the third and fourth branchial pouches, sometimes ectopic thymic tissue, and therefore ectopic thymomas, can occur. Less than 4% of all thymomas occurs as ectopic mass affecting the neck, the middle or posterior mediastinum

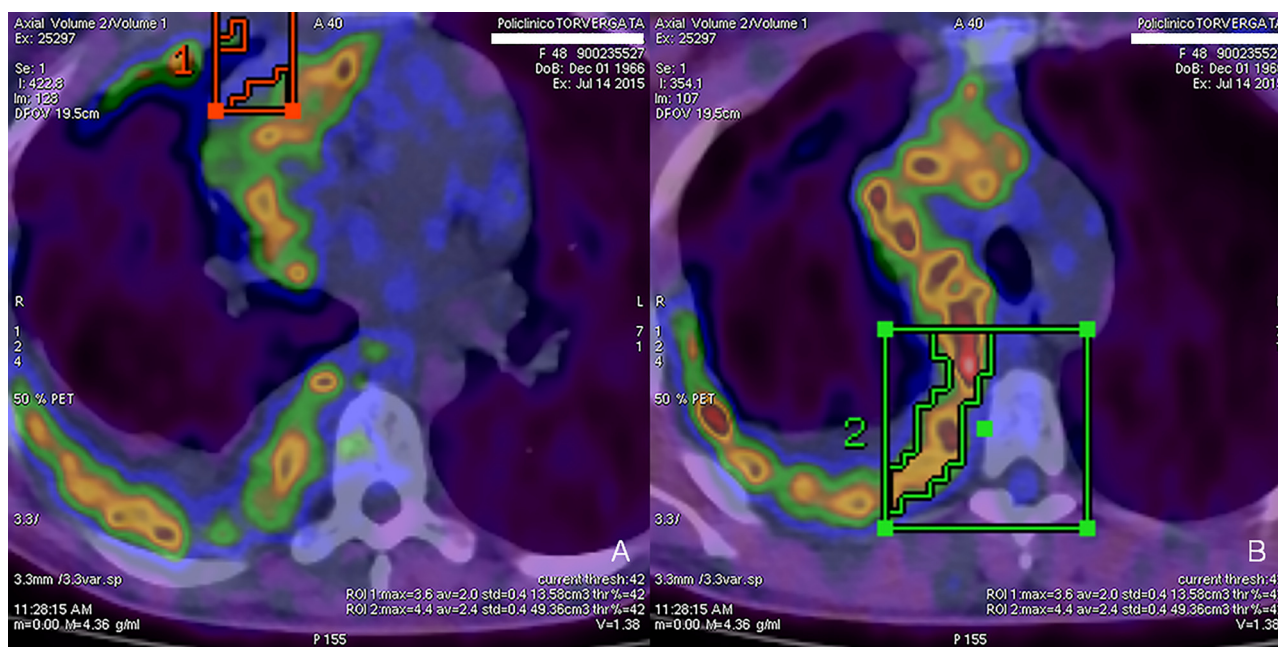
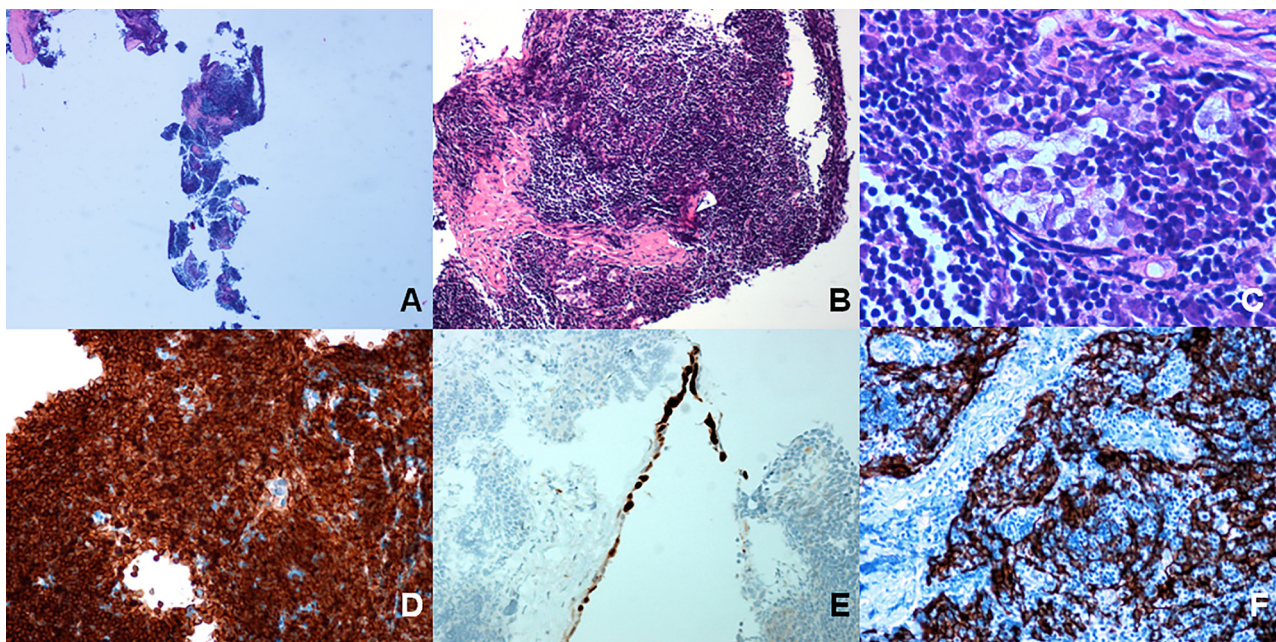


Fig. 5. The first Region of Interest (ROI) positioned on anterior chest wall shows SUV 3,6 (A), the second one near the posterior cost-vertebral arch shows SUV 4,4 (B).



**Fig. 6.** Histopathological examination shows findings consistent with type B2 (cortical) thymoma. The hematoxylin and eosin stain with original magnification 2X (A), 10X (B) and 40X (C) show that the tumor is made up of epithelial cells and a high population of lymphocytic cells with bands of sclerosis. Note the neoplastic cells which are large and polygonal with high ratio nucleus/cytoplasm. The immunohistochemical with CD3 at magnification 20X (D) shows the presence of CD3, a co-receptor of T-cells that is first expressed in the cytoplasm of pro-thymocyte stem cells to whom raise thymus T-cells. It is also high specific marker of T-cells because it is expressed at each stage of development of T-cells. Note the high-density of the T-cells in the specimen. The immunohistochemical with Calretinin 20X (E), shows the presence of a monolayer of cells of pleural origin in close proximity with the population of lymphocytes of thymic origin. The immunostaining for pan-CK (AE1/AE3) at magnification 20X (F) is useful in demonstrating the epithelial origin or not of tumors, because these monoclonal antibodies bind with high affinity the human cytokeratin. Here CKAE1-AE3 shows the epithelial cells that made up mucoepidermoid carcinoma component.

or the lung. The most common radiological appearance of ectopic thymoma originating from the pleura (both visceral and mediastinal), is an anterior intrathoracic mass [1].

Thymomas originating from the pleura are extremely rare, and very few cases are described in the literature [8]; instead thymomas originating from mediastinum and spreading along the pleura are more common [9].

Most thymomas are asymptomatic and they are diagnosed as incidental findings during chest X-Ray or CT evaluation. Nevertheless, pleural thymomas, referring to a more advanced state of the disease, are often detected with radiological exams related to the symptomatology.

Although pleural thymomas could have non-specific signs on X-ray film, usually they are characterized by unilateral mediastinal mass with defined borders, smooth or lobulated profile associated with ipsilateral pleural nodularity or thickening. On the PA projection they could hide the right or left edge of the heart, while on the lateral view are often visible as an abnormal radiopacity in the retrosternal space.

Pleural thymomas are usually identify on CT as one or more unilateral pleural nodules, separate from the main mass localized in anterior-superior mediastinum, typically swelling in the same side. The main mass appears, round or oval, with well demarcated, smooth or sometimes lobulated margins and homogeneous densitometric values; within or peripherally, various kind of calcifications could be present. Ipsilateral pleural effusion could be present and indicates an advanced disease. After injection of iodinated contrast thymomas are characterized by homogeneous enhancement; often large thymomas could look heterogeneous due to are areas of necrosis, haemorrhage or cystic components. In addition, the purpose of CETC is to evaluate the local tumor invasiveness and to search for metastasis, in order to stage the disease: the presence of well-delimited adipose tissue between the mass and other organs and mediastinal structures suggests low aggression. The main vessels, pericardial or pleural overrun instead, hematogenous or lymphatic metastasis lean toward an invasive disease.

The main radiological differential diagnoses of pleural thymoma are solitary fibrous tumours of the pleura, sarcomas of the chest wall, malignant pleural mesotheliomas and metastatic tumours. The diagnosis between these different neoplasms is quite difficult with radiological imaging because they have usually a similar appearance and only the biopsy of the mass is able to identify the nature of the lesion.

Macroscopically thymic tumors have a variable shape; thymomas typically shows rounded and protruding outer surface. The cut surface is tan or grey-pink with lobulated architecture, separated by fibrous septa. Larger tumors are more likely to demonstrate cystic changes as well as haemorrhage and calcification.

On the contrary, PET is not usually employed for the study of epithelial thymic tumors, due to the variable  $^{18}\text{F}$ -FDG uptake by normal thymus, hyperplastic non-neoplastic thymus and thymomas. The role of functional imaging, particularly  $^{18}\text{F}$ -FDG-PET imaging, for evaluating the tumor response in some other solid tumor types is well known; for this reason, PET can also be used for thymic epithelial tumors. Although, some histologic types of thymic epithelial tumors have very low  $^{18}\text{F}$ -FDG activity [6].

Both non-invasive and invasive thymomas may appear to have an intact capsule and microscopic examination is necessary. Numerous histological classification systems for thymic epithelial neoplasms have been proposed over the years. According to World Health Organization (WHO), the classification of thymic epithelial tumors, illustrated in Table 1, is based on histological appearance and correlates with likelihood of invasiveness and thus with staging. As long as, both type A and type AB are usually clinically benign and encapsulated; type B has a greater likelihood of invasiveness, especially type B3 and type C is almost always invasive [10].

The Masaoka staging system is commonly adopted to staging thymic epithelial tumors and to select treatment.

As shown in Table 2, it focuses on local extension. Our patient had a radiological Masaoka's stage IVa.

**Table 1**  
World Health Organization Classification of thymic epithelial tumors [14].

Type	Histological findings
A	Medullary thymoma
AB	Mixed thymoma
B1	Predominantly cortical thymoma,
B2	Cortical thymoma
B3	Epithelial thymoma
C	Thymic carcinoma

**Table 2**  
Masaoka staging system [15].

Stage	Histological findings
I	Microscopically encapsulated thymic gross mass
IIa	Microscopic invasion through the capsule
IIb	Macroscopic invasion into thymic or surrounding fatty tissue
III	Macroscopic invasion of neighboring organs such as pleura, lung, pericardium, main blood vessels, phrenic or vagus nerve
IVa	Pleural or pericardial dissemination
IVb	Hematogenous or lymphatic metastasis.

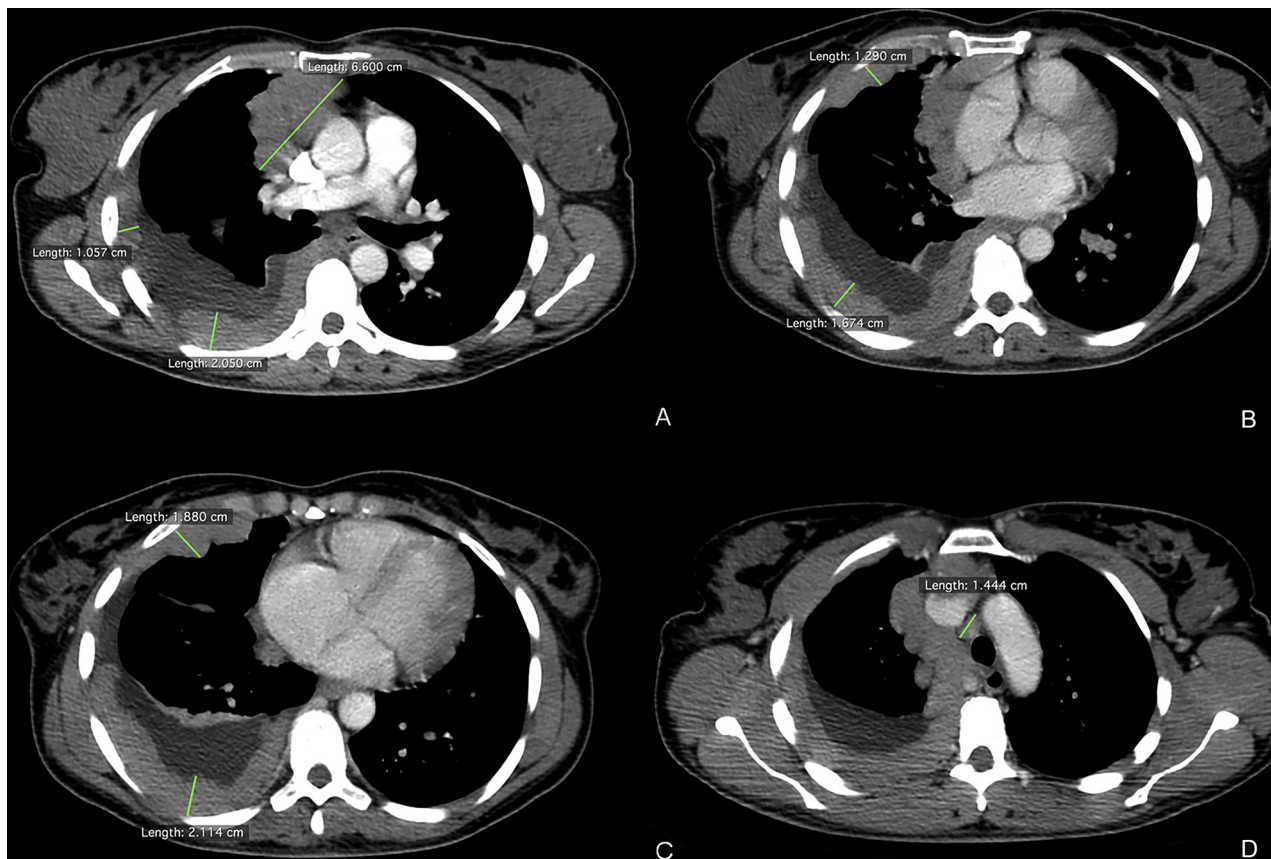
Even if this classification can be evaluated only after surgical resection, the initial reference for thymomas staging is CECT, studying local invasion and looking for metastasis in order to identify patients eligible directly to surgery for a complete resection, and those eligible for neoadjuvant therapy.

CT is the recommended imaging modality for thymic epithelial

tumors follow-up, because it is the most reproducible imaging technique for measuring lesions and therefore quantify the response to therapy [11,12]. Measurements of thymic tumors may be more laborious and time intensive, in order to require a manual delineation. The use of tumor size measurements to assess response to therapy has evolved over the years, and has included the World Health Organization, Response Evaluation Criteria In Solid Tumors (RECIST) and RECIST version 1.1 criteria. Currently, the most commonly used method is RECIST version 1.1, which is an unidimensional tumor measurement [13]. According to this method the overall tumor burden is defined by 5 target lesions at most (two per organ, including lymph nodes > 15 mm and a maximum of two pleural lesions), with an axial (long axis) plane measurement, except for lymph nodes that are measured along the short axis.

However, this method has certain limitations due to the thymomas growth pattern, which tend to spread along the pleura, insinuating around the vessels, with vague borders and irregular size; hence measurement should be tailored on these features. Therefore, ITMIG (International Thymic Malignancy Interest Group) recommends to adhering the criteria established for pleural measurement in mesothelioma, measuring tumor thickness at short-axis diameter perpendicular to the chest wall and using unidimensional pleural measurement composed of six lesions: two sites at three different levels [9].

It's quite important to establish the overall tumor burden because it represents an objective data for restaging after therapy. Reproducibility of the measurements is essential and anatomical landmarks are required. In our case, following the ITMIG-modified RECIST criteria, the patient had a score of 16.6 cm before treatment (Fig. 7). The score consists of the sum of the mediastinal primary tumour long axis



**Fig. 7.** According to International Thymic Malignancy Interest Group (ITMIG) modified RECIST measurement criteria, this thymoma get a score of 16.6 cm, consisting of the sum of the mediastinal primary tumor long axis diameter (A) and the six pleural diameters attributed to two pleural implants, measured at three different level (A–B–C): 6.6 cm + (1.0 cm + 1.3 cm + 1.9 cm) + (2.0 cm + 1.7 cm + 2.1 cm). The mediastinal lymph node (D) has not been indicated as a target lesion due to its size less than 15 mm.

diameter (6.6 cm) and the six pleural short axis diameters attributed to the two pleural implants, measured at three different levels: respectively, the most ventral one 4.2 cm (in cranium-caudal direction 1.0 cm + 1.3 cm + 1.9 cm), and the most dorsal one 5.8 cm (in cranium-caudal direction 2.0 cm + 1.7 cm + 2.1 cm). No lymph node target lesion was included due to its small size (1.4 cm).

#### 4. Conclusion

Thymomas are very rare occurrences in clinical practice, due to the rarity of this malignancies there are no randomized control, and clinical trials are available.

Definitive diagnosis and staging are histological, but thymomas have typical radiological characteristics.

X-rays is the first level exam, but gold standard in detection and evaluation of the response to oncologic therapy is chest CT, that allow a panoramic mediastinal and pleural evaluation from pulmonary apices to costophrenic recesses. The iodinated contrast administration is necessary to assess the adjacent structures involvement.

Thymomas are chemotherapy and radiotherapy sensitive, nevertheless, complete surgical excision is the preferred treatment whenever technically executable. Most of the CT features that indicate an advanced disease, were associated with late Masaoka staging, that was significantly associated with an incomplete surgical resection.

#### Conflict of interest

The authors and the authors institutions have no conflicts of interest.

This research did not receive any specific grant from funding agencies in the public, commercial, or not-for-profit sectors.

#### Acknowledgements

Authors whose names appear on the submission have contributed sufficiently to the scientific work and therefore share collective responsibility and accountability for the results. Consent to submit has been received explicitly from all co-authors, before the work was

submitted.

#### References

- [1] P.L. Filosso, L. Delsedime, R.C. Cristofori, et al., Ectopic pleural thymoma mimicking a giant solitary fibrous tumour of the pleura, *Interact. Cardiovas. Thorac. Surg.* 15 (5) (2012) 930–932, <https://doi.org/10.1093/icvts/ivs360>.
- [2] S.A. Hayes, J. Huang, A.J. Plodkowski, et al., Preoperative computed tomography findings predict surgical resectability of thymoma, *J. Thorac. Oncol.* 9 (7) (2014) 1023–1030, <https://doi.org/10.1097/JTO.000000000000204>.
- [3] F.C. Deterbeck, A.M. Parsons, Thymic tumors, *Ann. Thorac. Surg.* 77 (5) (2004) 1860–1869, <https://doi.org/10.1016/j.athoracsur.2003.10.001>.
- [4] B. Yan, D. Lim, F. Petersson, Ectopic cervical thymoma: a report of two cases of a rare entity frequently misdiagnosed on fine needle aspiration cytology and frozen section, *Head Neck Pathol.* 4 (2) (2010) 152–156, <https://doi.org/10.1007/s12105-010-0172-8>.
- [5] S. Dashottar, A.K. Singh, V. Suhag, B.S. Sunita, Ectopic thymoma-presenting as large pleural mass, *J. Cancer Res. Ther.* 11 (4) (2015) 1033, <https://doi.org/10.4103/0973-1482.147388>.
- [6] E.M. Marom, Imaging thymoma, *J. Thorac. Oncol.* 5 (10 Suppl 4) (2010) S296–S303, <https://doi.org/10.1097/JTO.0b013e3181f209ca>.
- [7] W.R. Webb, C.B. Higgins, *Imaging del torace*, Verducci, second ed., Roma, 2012.
- [8] K. Yamazaki, I. Yoshino, T. Oba, et al., Ectopic pleural thymoma presenting as a giant mass in the thoracic cavity, *Ann. Thorac. Surg.* 83 (1) (2007) 315–317, <https://doi.org/10.1016/j.athoracsur.2006.03.092>.
- [9] M.F. Benveniste, R.J. Korst, A. Rajan, et al., A practical guide from the International Thymic Malignancy Interest Group (ITMIG) regarding the radiographic assessment of treatment response of thymic epithelial tumors using modified RECIST criteria, *J. Thorac. Oncol.* 9 (9 Suppl 2) (2014) S119–124, <https://doi.org/10.1097/JTO.0000000000000296>.
- [10] M. Nishino, S.K. Ashiku, O.N. Kocher, et al., The thymus: a comprehensive review, *Radiographics* 26 (2) (2006) 335–348, <https://doi.org/10.1148/rg.262045213>.
- [11] J. Huang, F.C. Deterbeck, Z. Wang, et al., Standard outcome measures for thymic malignancies, *J. Thorac. Oncol.* 5 (12) (2010) 2017–2023, <https://doi.org/10.1097/JTO.0b013e3181f13682>.
- [12] E.A. Eisenhauer, P. Therasse, J. Bogaerts, et al., New response evaluation criteria in solid tumours: revised RECIST guideline (version 1.1), *Eur. J. Cancer* 45 (2) (2009) 228–247, <https://doi.org/10.1016/j.ejca.2008.10.026>.
- [13] N.R. Bogot, E.A. Kazerooni, A.M. Kelly, et al., Interobserver and intraobserver variability in the assessment of pulmonary nodule size on CT using film and computer display methods, *Acad. Radiol.* 12 (8) (2005) 948–956, <https://doi.org/10.1097/JTO.0b013e3181f209ca>.
- [14] Tumours of the Thymus – IARC Publications. Available online.
- [15] K.M.Y. Koga, M. Noguchi, K. Mukai, et al., A review of 79 thymomas: modification of staging system and reappraisal of conventional division into invasive and non-invasive thymoma, *Pathol. Int.* 44 (1994) 359–367.