

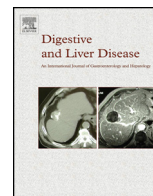


ELSEVIER

Contents lists available at ScienceDirect

Digestive and Liver Disease

journal homepage: www.elsevier.com/locate/dld



Progress Report

Italian consensus guidelines for the diagnostic work-up and follow-up of cystic pancreatic neoplasms

Italian Association of Hospital Gastroenterologists and Endoscopists, AIGO
Italian Association for the Study of the Pancreas, AISP

ARTICLE INFO

Article history:

Received 20 September 2013
Accepted 30 December 2013
Available online xxx

Keywords:

Neoplasms, cystic, mucinous, and serous
Pancreatic cyst
Pancreatic neoplasms

ABSTRACT

This report contains clinically oriented guidelines for the diagnostic work-up and follow-up of cystic pancreatic neoplasms in patients fit for treatment. The statements were elaborated by working groups of experts by searching and analysing the literature, and then underwent a consensus process using a modified Delphi procedure. The statements report recommendations regarding the most appropriate use and timing of various imaging techniques and of endoscopic ultrasound, the role of circulating and intracystic markers and the pathologic evaluation for the diagnosis and follow-up of cystic pancreatic neoplasms.

© 2014 Editrice Gastroenterologica Italiana S.r.l. Published by Elsevier Ltd. All rights reserved.

1. Introduction

Cystic pancreatic neoplasms (CPNs) have been increasingly identified over the past two decades due to the widespread use of high-resolution non-invasive abdominal imaging.

The characterisation and management of these cysts are a dilemma since there is a significant overlap in the morphology of benign and premalignant lesions; the 2010 WHO classification of CPNs is reported in Table 1 [1]. Of these entities, five types of neoplasms account for approximately 90% of all cystic tumours of the pancreas: intraductal papillary mucinous neoplasms (IPMNs) (either main duct, branch duct or mixed), mucinous cystic neoplasms (MCNs), serous cystic neoplasms (SCNs) and pseudopapillary neoplasms.

CPNs are mostly detected incidentally when non-invasive abdominal imaging is performed for unrelated indications. The prevalence of incidental pancreatic cystic lesions in the adult population is high, and ranges from 2.6 to 19.6% [2–4]. Autopsy

series report an increase in CPN prevalence with age: 8% below 70 yrs of age and 18%, 30% and 35% in the age ranges of 70–79, 80–89 and >90 yrs of age, respectively [5]. The size and number of CPNs (per patient) also increase with age [2–4]. Of note, a non-negligible proportion of CPNs, especially those with small diameters, are usually not described in imaging reports in patients without a past history of pancreatic disease (69% of cystic lesions with a mean diameter of 6 mm were not reported) [3].

While there is now an increased awareness of these lesions, their natural history is still partially unclear, and optimal management is still under debate.

Therefore, clinicians are faced with a high, and ever increasing, prevalence of CPNs due to population ageing, and management difficulties of these lesions, with the inherent risks of over- or misuse of diagnostic tests, entailing unnecessary risk and discomfort for patients and resources wasted for the health care system.

Evidence-based practice guidelines exist for pancreatic mucinous neoplasms [6]; European consensus statements regarding all CPNs have also been drafted [7].

Comprehensive guidelines regarding all CPNs, oriented by clinical patient presentation rather than the pathologic diagnosis, and based on a sound consensus methodology, are however lacking. Additionally, in Europe, the national welfare systems are significantly different, and the availability of high-end diagnostic techniques is not uniform in different countries. Thus, guidelines need to be tailored to the specific country [8].

Of note, consensus regarding clinical practice is particularly valuable in this context where limited data are available and health providers are faced with difficult clinical decisions; controversial issues still exist in the evaluation and management of CPNs, particularly regarding lesion size, the presence of high-risk lesion features,

Elisabetta Buscarini^{a,*}, Raffaele Pezzilli^b, Renato Cannizzaro^c, Claudio De Angelis^d, Massimo Gion^e, Giovanni Morana^f, Giuseppe Zamboni^g, Paolo Arcidiacono^h, Gianpaolo Balzanoⁱ, Luca Barresi^j, Daniela Basso^k, Paolo Bocus^l, Lucia Calculli^m, Gabriele Capursoⁿ, Vincenzo Canzonieri^o, Riccardo Casadei^p, Stefano Crippa^q, Mirko D'Onofrio^r, Luca Frulloni^s, Pietro Fusaroli^t, Guido Manfredi^a, Donatella Pacchioni^u, Claudio Pasquali^v, Rodolfo Rocca^w, Maurizio Ventrucci^x, Silvia Venturini^f, Vincenzo Villanacci^y, Alessandro Zerbi^z, Massimo Falconi^q, Cystic Pancreatic Neoplasm Study Group¹.

^a Gastroenterology Unit, Maggiore Hospital, Crema, Italy;

^{b-z} See Appendix A.

* Corresponding author.

E-mail address: ebuscarini@rim.it (E. Buscarini).

¹ See Appendix B.

Table 1
WHO classification of cystic pancreatic tumours, 2010.

Epithelial tumours
Benign
Acinar cell cystadenoma
Serous cystadenoma
Premalignant lesions
Intraductal papillary mucinous neoplasm (IPMN)
Mucinous cystic neoplasm (MCN)
Malignant lesions
Acinar cell cystadenocarcinoma
Intraductal papillary mucinous carcinoma (IPMN) with an associated invasive carcinoma
Mucinous cystic neoplasm (MCN) with an associated invasive carcinoma
Serous cystadenocarcinoma
Solid-pseudopapillary neoplasm
Neuroendocrine neoplasms with cystic degeneration
Mesenchymal tumours
Lymphangioma, NOS
Secondary tumours with cystic degeneration

the role of different diagnostic techniques, and the accuracy of markers and cytology for CPN definition.

Therefore, the Italian Association of Hospital Gastroenterologists and Endoscopists (Associazione Italiana Gastroenterologi ed Endoscopisti Ospedalieri, AIGO) and the Italian Association for the Study of the Pancreas (Associazione Italiana per lo Studio del Pancreas, AISP) have produced the present consensus guidelines which: (1) are limited to the diagnostic work-up and follow-up of all CPNs according to WHO classification (and excluding cystic inflammatory lesions of the pancreas due to acute or chronic pancreatitis with a compatible patient history), (2) are based on a sound consensus methodology (see Appendix D) to allow evaluation of published data and their quality, and to synthesise them with expert opinions wherever data in the literature are either missing or of low quality, (3) are clinically oriented in order to address the clinical scenarios encountered when caring for patients with CPNs, and (4) consider also the characteristics of the Italian Health Care System, with its inherent availability of different diagnostic techniques. The consensus was reached for each statement according to the Delphi procedure [9] and both the level of evidence (EL) and the grade of recommendation (RG) were reported according to the Oxford criteria [10]. The following recommendations are applicable only to those patients for whom a therapeutic opportunity is suitable at the time of diagnosis or during the follow-up. No additional examinations are required when the patient, after diagnosis, is found to be unfit for any treatment and asymptomatic.

2. Consensus statements

2.1. Indications for work-up

1) Which patients with pancreatic cystic lesions need an additional diagnostic work-up, after exclusion of those unsuitable for treatment or unwilling to undergo diagnostic work-up?

Statement

All patients with pancreatic cystic neoplasms require a diagnostic work-up [11–18].

Evidence level 2a, Recommendation grade B, Agreement 96%

Comment

All patients with pancreatic cystic neoplasms, symptomatic or asymptomatic, require a diagnostic work-up in order to evaluate appropriate treatment or surveillance.

Patients with asymptomatic, small (<1 cm) pancreatic cystic neoplasms also require a diagnostic work-up since malignancy can occur (2%). If the cystic lesion was discovered by a high resolution technique (such as MRI or MDCT), no further investigation is usually needed.

2) Define clinical presentation on the basis of the presence/absence of sign/symptoms.

In *symptomatic* patients, what are the signs/symptoms of a pancreatic cystic lesion?

Statement

Signs/symptoms of a pancreatic cystic lesion include: abdominal pain, acute pancreatitis, nausea, vomiting, weight loss also due to exocrine pancreatic insufficiency with steatorrhea, anorexia, recent onset or worsening diabetes, obstructive jaundice and a palpable mass [14,19–33].

Evidence level 4, Recommendation grade D, Agreement 94%

Comment

Symptoms can differ according to the type of cystic lesion: IPMNs are often discovered after pancreatitis; large MCNs and SCNs may be discovered as a result of the presence of a palpable abdominal mass. Jaundice, severe abdominal pain, weight loss, anorexia and diabetes are more likely associated with malignant behaviour.

3) In the setting of *symptomatic* patients, which diagnostic technique/s is/are necessary before treatment?

Statement

In the setting of symptomatic patients, high resolution imaging techniques, including MRI with MRCP and/or MDCT with a pancreatic protocol, represent the first diagnostic step [12,34–47].

Evidence level 1a, Recommendation grade A, Agreement 98%

Comment

MRI with MRCP and/or MDCT characterise the cyst and stage the neoplasm (i.e. local infiltration, distant metastases). Since surgery is required for all symptomatic resectable cystic lesions no additional procedures are usually necessary. If distant metastases are suspected, but not clearly demonstrated, PET/CT with ¹⁸FDG can be performed.

If local infiltration is suspected, MDCT is usually enough to assess the infiltration; in doubtful cases, EUS with or without FNA can also be carried out.

4) Which data regarding personal or familial history, and which laboratory findings should be considered in asymptomatic patients?

Statement

A family history for pancreatic cancer and/or other malignancies, and a personal and familial history consistent with Von Hippel–Lindau (VHL) disease should be considered.

Serum carbohydrate antigen (CA) 19-9 and glucose levels should be evaluated as well [48–59].

Evidence level 2a, Recommendation grade B, Agreement 94%

Comment

Von Hippel–Lindau disease is associated with pancreatic involvement in approximately 75% of cases (more frequently true cysts (90%), serous cystic tumours (12%), and neuroendocrine cystic tumours (12%) or combined lesions (11%).

The development of extra-pancreatic neoplasms is reported in 10–40% of patients with IPMNs, and they most frequently include benign colonic polyps, and colorectal, breast and gastric cancer.

Family history of pancreatic cancer is reported as a risk factor for malignant degeneration in IPMNs, although this observation has not been confirmed in large cohorts of resected patients.

Increased serum CA 19-9 levels can be associated with an increased risk of malignant degeneration in IPMNs; however, a negative result of CA 19-9 assessment does not exclude the presence of malignancy. Onset/worsening diabetes mellitus may be related to the presence of a ductal carcinoma in patients with IPMNs.

5) In asymptomatic patients, can morphological findings of CPNs indicate treatment directly?

Statement

An enhancing solid component within the cyst represents an indication for treatment. For IPMNs, the presence of a main duct >10mm is another indication for treatment [24,25,27,28,58,60-67].

Evidence level 2a, Recommendation grade B, Agreement 76%

Comment

Other suspicious morphological features include: cyst diameter ≥ 3 cm; thickened enhancing cyst wall; main duct size 5-9 mm, a non-enhancing mural nodule, and an abrupt change in the calibre of the pancreatic duct with distal pancreatic atrophy. These latter suspicious features represent an indication for an additional diagnostic work-up, including EUS with fine needle aspiration (FNA) and cytology; in the case of a mucinous content of the cyst, surgery is indicated.

6) In asymptomatic patients, which technique/s is/are necessary for either treating or following up patients with pancreatic cystic lesions?

Statements

In asymptomatic patients, high resolution imaging techniques, including MRI with MRCP and/or MDCT with a pancreatic protocol, represent the first diagnostic step [12,35,49,51,60,62,68-77].

When "suspicious" morphological features are identified or in patients with an uncertain radiologic diagnosis (i.e. small branch-duct IPMNs versus small SCNs), EUS with FNA for cytology is recommended [12,35,49,51,60,62,68-77].

Evidence level 4, Recommendation grade C, Agreement 85%

Comment

"Suspicious" morphological features represent an indication for an additional diagnostic work-up, including EUS with FNA; evaluation of the intracystic CEA level is not useful in differentiating between benign and malignant cysts.

Different variables should also be considered: (1) patient age and comorbidities (i.e. consider surgery in young patients), (2) patient willingness to undergo close follow-up evaluations and (3) patient family history of pancreatic cancer (i.e. consider surgery if there are 2 family members with pancreatic cancer). In the setting of patients with suspicious morphological features, serum CA 19.9 level could be useful in choosing the most appropriate approach (i.e. surgery for those with elevated CA 19.9 levels).

7) In asymptomatic patients without morphological indications for treatment, which medical history-laboratory-demographic data change the decision to treat?

Statement

A family history of pancreatic cancer (≥ 2 first degree family members) represents an indication for surgical resection of mucinous cysts, even in patients without morphological indications for treatment [11,49,58].

Evidence level 4, Recommendation grade C, Agreement 62%

Comment

In deciding whether to treat, type of lesion (MCN or IPMN), size, site, multifocality and age of the patient should be considered.

In addition to a family history of pancreatic cancer, other data from medical history-laboratory-demography which could change the decision to treat the patient include: young age at onset with long life expectancy, elevated CA 19-9 antigen, the possibility of performing a parenchyma-sparing resection and strong willingness of the patient to be treated.

8) Do CPNs of the pancreas exclude the patient from organ transplantation?

Statement

No, CPNs of the pancreas do not exclude the patient from organ transplantation [89].

Evidence level 4, Recommendation grade C, Agreement 91%

Comment

Careful evaluation and characterisation of the cyst is however important, particularly if a mucinous cyst (IPMN/MCN) is suspected. In all cases, FNA for cytology is recommended. If "suspicious" features are present, a more aggressive approach should be considered before transplantation.

9) Which diagnostic work-up is required in organ transplant candidates with evidence of a cystic lesion of the pancreas but without morphological characteristics of malignancy?

Statement

MRI/MRCP and EUS with FNA are recommended in organ transplant candidates. Laboratory tests including CA 19.9 and glucose levels and a careful clinical evaluation for cyst-related symptoms should be carried out [82].

Evidence level 4, Recommendation grade C, Agreement 93%

Comment

Even if the level of evidence based on the literature is low, all available diagnostic tests can be recommended in order to improve the possibility of identifying a malignancy and to stratify the risk of these patients.

Regarding the follow-up of patients in which observation has been chosen, the aims of a follow-up are: (1) to demonstrate size variations over time (either as a cystic lesion increases or decreases in size, or disappears); (2) to confirm diagnosis (test of time), the following questions arise.

10) What is the imaging test of choice for follow-up?

Statement

The imaging test of choice for follow-up is MRI with MRCP. At any follow-up evaluation, a careful clinical examination to identify symptoms plus laboratory tests including, CA 19.9 and glucose levels have to be carried out, especially in mucinous lesions [13,19,49,61,62,65,76,78-87].

Evidence level 2a, Recommendation grade B, Agreement 81%

Comment

The test of choice for follow-up evaluation depends on the initial characterisation of the cyst. Especially in SCNs, cyst size should be evaluated over time and US could therefore be used. If there is cyst growth and/or the presence of symptoms, then MRI with MRCP or CT should be performed. In branch-duct IPMNs without "suspicious" features, MRI with MRCP plus laboratory tests, including CA 19.9 and glucose levels should be carried out.

In patients with "suspicious" features or with modifications of the cyst (i.e. an increase in size even if to less than 3 cm), EUS with FNA should be considered.

11) What is the correct timing of a follow-up?

Statement

Follow-up should be carried out on a yearly basis and be related to the morphological characteristics of the cystic lesion,

a family history of pancreatic cancer, diabetes mellitus and serum CA 19-9 levels [13,19,49,61,62,65,76,78–88].

Evidence level 3, Recommendation grade B, Agreement 91%

Comment

A suggested timing for follow-up according to the type of cystic lesion is reported in Table 2.

12) In the transplanted patient does the presence of an asymptomatic cystic lesion of the pancreas without morphological aspects of malignancy require alternative follow-up strategies of diagnostic tests and timing?

Statement

No, in the transplanted patient follow-up strategies do not differ [89].

Evidence level 4, Recommendation grade C, Agreement 87%

Comment

Transplant recipients usually undergo immunosuppressive treatment to prevent rejection. It could be hypothesised that immunosuppressive therapy could increase the risk of tumour degeneration of pre-neoplastic lesions, such as branch-duct IPMNs. However, this hypothesis is not supported by current evidence. Therefore, diagnostic tests and follow-up timing do not require alternative strategies in this specific setting.

2.2. Laboratory tests, serum markers

1) Is hyperglycaemia a marker of malignant behaviour for pancreatic cystic neoplasms?

Statement

Hyperglycaemia by itself is not a marker of malignant behaviour for pancreatic cystic neoplasms.

Evidence level 5, Recommendation grade D, Agreement 98%

Comment

A recent diagnosis or worsening of diabetes was found to be more common among malignant IPMNs [90] while no significant differences were found in the frequency of worsening of diabetes when comparing the subgroups with benign and malignant tumours [91].

Long-standing diabetes mellitus is considered a risk factor for pancreatic adenocarcinoma while new-onset diabetes mellitus is considered a unique form of diabetes mellitus which is caused by the cancer [91–93].

Type II diabetes mellitus is common in the general population and pancreatic cancer is relatively uncommon; the

Table 2
Suggested follow-up timing according to the type of cystic lesion.

Type of cystic lesion	Follow-up ^a	
SCN	Yearly imaging	If no growth occurs for 3 years, consider to stop the follow-up
MCN and main duct IPMN	Resection and no specific follow up recommendations	
Branch duct IPMN	Diameter less than 10 mm	Every 12 months
	Diameter 10–20 mm	Every 6–12 months
	Diameter greater than 20 mm	Every 3–6 months
	If after two years from initial diagnosis the branch duct IPMN is stable, follow-up timing can be modified as follows:	
	Diameter less than 10 mm	Every 24 months
	Diameter 10–20 mm	Every 18 months
	Diameter greater than 20 mm	Every 12 months

^a See statement 5, cross sectional imaging, for imaging choices.

two forms of diabetes are not clinically distinguishable [94].

2) Is direct hyperbilirubinemia a marker of malignant behaviour for a pancreatic cystic neoplasm located in the head of the gland?

Statement

An isolated increase in direct bilirubinemia is not a specific marker of malignant behaviour for a pancreatic cystic neoplasm located in the head of the gland, although increased bilirubin levels should prompt additional investigation.

Evidence level 5, Recommendation grade D, Agreement 85%

Comment

Jaundice as a clinical sign has indeed been evaluated in pancreatic cystic neoplasms located in the head of the gland. In two cohort studies of patients with main/branch duct IPMNs, jaundice was significantly more frequent in the subgroups with malignant tumours [90,91].

In a retrospective review of 166 resections of cystic tumours ≤3 cm in size, jaundice significantly correlated with malignancy [51]. However, in these studies, jaundice was only reported as a sign and neither elevation of serum bilirubin nor the best cut off to apply was characterised.

3) What is the post-test probability that an abnormal serum CA19.9 level indicates malignant behaviour in a pancreatic cystic neoplasm?

Statement

CA19.9 is not a marker of CPN malignancy. However, serum CA19.9 determination provides additional information within the diagnostic work-up since a positive result is associated with the presence of an invasive carcinoma with a specificity ranging from 79 to 100% and a PPV of 74%. Conversely, a negative result does not exclude the presence of a malignancy (sensitivity 37–80%) [95–101].

Evidence level 4, Recommendation grade C, Agreement 84%

Comment

The degree of increase in CA 19-9 levels may be useful in differentiating pancreatic adenocarcinoma from inflammatory conditions of the pancreas. On the contrary, circulating CA19.9 is not effective for distinguishing pancreatic cancer from benign pancreatic diseases since the specificity and sensitivity of CA19.9 are not adequate for reaching an accurate diagnosis. CA19.9 is frequently elevated in patients with jaundice, independently of the cause of the biliary tract obstruction and it may not be elevated in small malignant tumours of the pancreas. People lacking the Lewis antigen (5% of the general population) are unable to synthesise CA19.9 [102–104].

4) Does any specific caution exist in order to obtain a reproducible result of circulating biomarkers when measured in serial determinations?

Statement

CA19.9 determination must be performed in the same laboratory and with the same method when evaluating serial samples from the same patient.

Evidence level 5, Recommendation grade D, Agreement 92%

Comment

The inter-method variability of a CA19.9 assay is still elevated, as shown by external quality assurance programmes. When the method is changed, the levels of CA19.9 must be determined by both assays on two to four serial samples for each patient in order to establish new reference values and an appropriate cut-off [105,106].

5) Does any combination with other serum tests increase the diagnostic performance of CA19.9?

Statement

The association of other circulating markers does not provide additional information for differentiating benign from malignant CPNs and is not recommended.

Evidence level 4, Recommendation grade C, Agreement 100%

Comment

Available evidence does not support the determination of CEA, other mucin markers or amylase in differentiating benign from malignant CPNs.

2.3. Imaging and nuclear medicine

1) Which is the best imaging modality (US/CEUS, MDCT, MRI-MRCP, secretin MRCP or FDG-PET) in differentiating between benign and malignant cystic pancreatic lesions?

Statements (Agreement 77%)

Conventional US of the pancreas is not able to definitively diagnose CPNs.

Evidence level 5, Recommendation grade C

The different dynamic imaging modalities (CEUS, MDCT, MR) have a similar high accuracy.

Evidence level 1b, Recommendation grade A

Available data do not support the use of S-MRCP in the differential diagnosis of benign versus malignant CPNs.

Evidence level 5, Recommendation grade D

The accuracy of FDG-PET-CT is high.

Evidence level 1b, Recommendation grade B

Comment

US of the pancreas is not able to definitively diagnose CPNs and CEUS is affected by the same technical limitations. When CPNs are well visible at ultrasound, in the differential diagnosis between benign and malignant CPNs, CEUS has a sensitivity, specificity, PPV, NPV and accuracy ranging from 79% to 94%, 76% to 99%, 66% to 90%, 94% to 98% and 84% to 98%, respectively [107-110].

In the identification of intra-cystic nodules, CEUS has a sensitivity, specificity, PPV, NPV and accuracy of 75%, 96%, 85.7%, 92.3% and 90.9%, respectively while, in the identification of septa, CEUS has a sensitivity, specificity, PPV, NPV and accuracy of 93%, 88%, 87%, 94% and 90%, respectively [110].

In cases of IPMNs, CEUS has a sensitivity of 88.2% in identifying enhancing solid nodules [111]. MDCT is accurate in differentiating benign from malignant CPNs with an accuracy of 71-84% [112] and an AUROC (accuracy calculated using ROC curves) ranging from 0.64 to 0.86 [113-115]. The sensitivity, specificity, PPV and NPV are 57-69%, 63-83%, 25-80% and 73-78%, respectively [112-115]. The PPVs and NPVs were higher for non-mucinous than for mucinous CPNs, and for CPNs > 3 cm [113].

In cases of mucinous cystoadenoma, CT can predict malignancy with a sensitivity and specificity of 81% and 83%, respectively. The presence of septa or parietal calcifications, thick walls or thick septa is highly suggestive of malignancy: when all are present, the likelihood of malignancy is 94% and when all are absent, the likelihood of malignancy is 2% [116].

In the differential diagnosis between benign and malignant CPNs, MR with MRCP has a sensitivity and specificity of 94% and 75%, respectively [117], an accuracy of 73-81% [112,114] and AUROC values of 0.73-0.91 [112,114,115,117,118]. MR is able to exclude the malignancy of CPNs with an NPV of 74-96% [112-114].

In cases of IPMNs, in the diagnosis of benignity vs. malignancy according to some "suspicious" features, MDCT has a sensitivity, specificity and accuracy of 70%, 87% and 76%, respectively [119]. With different criteria (mural nodule > 3 mm, main pancreatic duct > 6 mm) MDCT has a sensitivity, specificity, PPV, NPV and accuracy of 83%, 81%, 85%, 78% and 82%, respectively [120]. As regards specific "suspicious" features, for septa, MDCT has a

sensitivity of 85% [112], and for nodules within CPNs, it has a sensitivity of 0-100% [112,119].

MDCT, also thanks to curved MPR post-processing [121], has a high capacity for assessing the presence of communication with the main pancreatic duct, with a sensitivity of 83-87% [112-119] and an AUROC of 0.774-0.790 [121].

As regards specific "suspicious" features in CPNs, for septa MR has a sensitivity of 91-94% [110,112,118], a specificity, PPV and NPV of 61%, 66% and 91%, respectively [110] and an accuracy of 75-95% [110,118]; for nodules, MR has a sensitivity of 33-87% [110,112,118], a specificity, PPV and NPV of 80%, 58% and 95%, respectively [110], and an accuracy of 71-81% [110,118].

In cases of IPMNs, in the diagnosis of benignity vs. malignancy according to some "suspicious" features (nodules, main pancreatic duct > 10 mm, thick septa, calcifications), MR with MRCP has a sensitivity, specificity and accuracy of 70%, 92% and 80%, respectively [119].

MR with MRCP has a high capacity for assessing the presence of communication with the main pancreatic duct, with a sensitivity and specificity of 91-100% and 89%, respectively [112,117], an accuracy of 90% [118] and an AUROC of 0.91-0.94 [117,121].

The majority of studies published focus on IPMNs, indicating that ¹⁸FDG-positive studies have a high specificity in detecting malignancy [66,122-124]. In a prospective study, the sensitivity, specificity, positive and negative predictive values, and accuracy of ¹⁸FDG-PET in detecting malignant cystic pancreatic lesions were 94%, 94%, 89%, and 97%, respectively [125].

The sensitivity (94%) and specificity (100%) of ¹⁸FDG-PET-CT in depicting malignant cystic pancreatic lesions have been shown to be superior to those of ¹⁸FDG-PET (sensitivity 56%, specificity 83%) and CT (sensitivity 81%, specificity 100%) separately [126].

2) Which is the best imaging modality (US/CEUS, MDCT, MRI-MRCP, secretin MRCP or FDG-PET) for differentiating between mucinous and non-mucinous cystic pancreatic lesions?

Statement

MDCT and MR are the best imaging modalities for differentiating mucinous and non-mucinous CPNs, both having high accuracy.

E 1b, R A

There are no corresponding detailed data on CEUS and ¹⁸FDG-PET. Data supporting the use of S-MRCP are not available.

E 5, R D

Agreement 78%

Comment

MDCT has high accuracy in differentiating mucinous from non-mucinous CPNs, ranging from 71 to 85% [112,113]. Accuracy is higher for CPNs > 3 cm (AUROC 0.90-0.93) than for smaller ones (AUROC 0.82) [113]. CT imaging findings suggesting a SCN are microcystic appearance, lobulated margins and a central scar. Only a microcystic appearance is significantly associated with the diagnosis of SCN. A central scar has a sensitivity, specificity and PPV of 32%, 100% and 100%, respectively. The combination of microcystic appearance and lobulated margins has a sensitivity, specificity and PPV of 68%, 100% and 100%, respectively [127]. To differentiate IPMNs from other CPNs, MDCT has a sensitivity, specificity, PPV, NPV and an AUROC of 80%, 86%, 89%, 76% and 0.850-0.875, respectively [121].

MR has a sensitivity of 91% [128] and an accuracy of 78-81% [112] in differentiating mucinous from non-mucinous CPNs. To differentiate IPMNs from other CPNs, MR has a sensitivity, specificity, PPV, PNV and an AUROC of 96%, 90%, 92%, 95% and 0.932-0.995, respectively [121].

3) What is the role of the different imaging techniques in patients with CPNs (diagnostic algorithm)?

Statements (Agreement 72%)

MR and MDCT are first level techniques in differentiating benign from malignant CPNs. The performance of CEUS is similar to that of MR and MDCT, when CPNs are visible at US.

Evidence level 1b, Recommendation grade A

MR with MRCP is the best imaging modality for evaluating the communication of CPNs with the main pancreatic duct.

Evidence level 1b, Recommendation grade A

Based on the above statements, MR with MRCP is the imaging method of choice for the study of CPNs.

Evidence level 5, Recommendation grade C

¹⁸FDG-PET must be considered as second level if clinical suspicion for malignancy is high and other imaging modalities are inconclusive or if other imaging modalities are suspicious for malignancy but have a low level of confidence.

Evidence level 5, Recommendation grade D

Comment

MR with MRCP is highly reliable in assessing the presence of communication with the main pancreatic duct, having a sensitivity and specificity of 91–100% and 89%, respectively [112,117], an accuracy of 90% [118] and an AUROC of 0.91–0.94 [117,121].

MR is the standard of reference in the diagnostic management of CPNs; it is mandatory in young patients and women of fertile age.

MDCT has slightly lower capacity of assessing the presence of communication with main pancreatic duct, having a sensitivity of 83–87% [112,119] and an AUROC of 0.774–0.790 [121], but it is more invasive.

S-MRCP has a limited value in the management of CPNs; it can be useful in clarifying the presence of communication between the CPNs and the main pancreatic duct which is not clear in standard MRCP.

Proposed diagnostic algorithm:

1. US diagnosis of CPNs.
2. MRI or MDCT for characterising and differentiating benign from malignant CPNs.
3. In cases of unclear communication between the CPN and main pancreatic duct: S-MRCP.
4. In cases of unclear imaging findings for malignancy with high clinical suspicion: ¹⁸FDG-PET.

4) What is the role of percutaneous guided sampling?

Statement

There are no data supporting the role of percutaneous guided sampling of CPNs. The FNA of CPNs has to be performed using the EUS approach.

Evidence level 5, Recommendation grade D, Agreement 89%

Comment

The EUS approach for FNA of CPNs is preferable and supported by data in the literature.

5) What is the role of the different imaging techniques (US/CEUS, MDCT, MRI–MRCP, secretin MRCP and ¹⁸FDG-PET–CT) in the follow-up of patients with asymptomatic CPNs?

Statements (Agreement 78%)

The role of any individual method depends on both the size and the number of CPNs.

a. Small single cyst (<1 cm) visible at US: US is preferred until size change occurs. If size change occurs, CEUS or MR imaging should be performed to evaluate the presence of “suspicious”

features. MR with MRCP, alternated with US, should be used to evaluate the development of new CPNs. If MR identifies new CPNs, a follow-up must be carried out with MR.

b. Small single cyst (<1 cm) not visible at US: MR/MRCP.

Evidence level 5, Recommendation grade D

c. Large single cyst (≥1 cm) visible at US: US is preferred until size change occurs. If size change occurs, CEUS or MR imaging should be performed to evaluate the presence of “suspicious” features (size, nodules, septa, content, morphology). MR with MRCP, alternated with US, is used to evaluate the development of new CPNs. See above Comment for small lesions.

d. Large single cyst (≥1 cm) not visible at US: MR with MRCP or MDCT. In cases with strict follow-up (e.g. 3 months), MDCT should be used only in older patients without renal insufficiency or in patients with absolute contraindications to MR.

Evidence level 5, Recommendation grade D

e. Multiple cysts: MR with MRCP

Evidence level 5, Recommendation grade D

S-MRCP is not indicated in the follow-up due to the limited information provided.

Evidence level 1b; Recommendation grade A

¹⁸FDG-PET is not indicated in the follow-up due to high costs and radiation exposure issues.

Evidence level 5, Recommendation grade D

2.4. EUS/endoscopy

1) What is the role of EUS in differentiating between benign and malignant CPNs?

Statement

EUS can identify morphological features which increase the suspicion of malignancy in CPNs. However, morphologic features identified at EUS alone cannot exclude the presence of malignancy in CPNs.

Evidence level 2b, Recommendation grade B, Agreement 91%

Comment

Two studies regarding the EUS features [129,130] of resected IPMNs showed that “suspicious” features were significantly ($P < 0.05$) associated with malignant lesions. On the basis of these morphological features, the accuracy of EUS for malignancy was 86%. EUS is more sensitive than MDCT in detecting solid components in IPMNs (84% EUS vs. 68% MDCT), less specific (33% EUS vs. 100% MDCT) but with similar accuracy (76.5% EUS vs. 70.6% MDCT) [131]. However, the usefulness of EUS in distinguishing mucus from mural nodules has been recently assessed [82,132], with a 75% sensitivity and 83% specificity versus a 24% sensitivity and 100% specificity of CT.

2) What is the role of EUS in differentiating between mucinous and non-mucinous pancreatic CPNs?

Statement

Although EUS morphology alone cannot provide a definite differential diagnosis between mucinous and non-mucinous CPNs, some EUS features offer useful information on the type of lesion.

Evidence level 4, Recommendation grade C, Agreement 96%

Comment

A review [133] of seven studies [78,134–139] regarding the diagnostic accuracy of EUS morphology in differentiating mucinous and non-mucinous CPNs, reported accuracies ranging from 51 to 90%. Interobserver agreement between endosonographers in the diagnosis of CPNs appears low [138,140,141]. Conversely, EUS shows some cystic features which are specific for different types of CPNs [40,134–138,142,143]. EUS and MRI have similar sensitivities in identifying communication with the main pancreatic duct (100% for MRI vs. 88.9% for EUS, $P = > 0.8$), particularly in

the diagnosis of branch-duct IPMNs [118]. EUS allows the visualisation of multifocal CPNs, which are usually suggestive of IPMNs [61,144] better than cross-sectional imaging (13% for CT vs. 47% for EUS, $P = <0.0001$ and 34% for MRI vs. 58% for EUS, $P = <0.0002$) [144].

3) Does the use of contrast during EUS increase the diagnostic accuracy of EUS for CPNs?

Statement

Contrast-enhanced EUS may be helpful in the differential diagnosis of CPNs and in ruling out neoplastic degeneration. The analysis of intracystic nodules at contrast-enhanced EUS may help in differentiating neoplastic vegetations from mucus and debris.

Evidence level 4, Recommendation grade C, Agreement 96%

Comment

The literature on the use of contrast in the differential diagnosis of CPNs is very limited. SCNs typically appear hyperenhanced at contrast-enhanced EUS; the signal is detected inside the septa and cyst wall [145]. In the context of IPMNs, intracystic nodules that are tumoural may show some degree of enhancement, unlike mucus plugs and debris which are non enhanced [132].

4) What is the expected complication rate of diagnostic EUS?

Statement

The expected complication rate of diagnostic EUS is very low and is estimated to be approximately 0.03% [146-149].

Evidence level 2a, Recommendation grade B, Agreement 98%

Comment

Echoendoscopes are the most difficult instruments to use in digestive endoscopy. Oesophageal and duodenal perforations are the most common complications [150-156].

5) When is EUS-FNA recommended for differentiating between benign and malignant CPNs?

Statement

EUS-FNA is indicated when a previous diagnostic modality has shown CPNs with "suspicious" features other than an enhancing solid component, when the other diagnostic modalities fail to obtain a definite diagnosis, or in cases of advanced malignant CPNs when chemotherapy is considered.

Evidence level 2a, Recommendation grade B, Agreement 91%

Comment

EUS-FNA can target areas inside the lesion which are not obtainable by other bioptic modalities. In the differential diagnosis of benign and malignant CPNs, prospective and retrospective studies have shown that cytology seems to be more accurate than fluid analysis, with accuracy rates ranging from 75 to 88% [137,157,158]; the adequacy of cytological sampling in CPNs ranges from 30 to 70%; the combination of cytology and fluid analysis is the best modality for diagnosing malignant lesions [118,159-164].

6) When is EUS-FNA recommended in the differential diagnosis between mucinous and non-mucinous CPNs?

Statement

EUS-FNA is indicated when the other diagnostic modalities fail to obtain a definite differential diagnosis.

Evidence level 2a, Recommendation grade B, Agreement 96%

Comment

In the differentiation between SCNs vs. branch-duct IPMNs and MCNs, EUS-FNA is the only method which can obtain a diagnosis with accuracy rates near 80%. In this setting, CEA levels in the cyst fluid provide the best predictor; the most valuable cut-off for SCN diagnosis is $CEA < 5$ ng/ml while the best cut-off to differentiate a mucinous lesion is $CEA > 192$ [33,78,159,165-167].

A size of 1.5 cm is the minimum required to obtain fluid for at least one analysis which should be CEA [55].

EUS-FNA is not necessary if surgery is planned irrespectively of the differentiation between serous and mucinous CPNs.

7) Are there any data available regarding particular needles, devices, sampling techniques or ROSE (rapid on-site evaluation) of the sampled material which increase the performance of EUS-FNA of CPNs?

Statement

Both cytology brush, which allows brushing of the walls in CPNs, and targeted cyst wall biopsy, using either the trucut biopsy needle or a standard EUS-FNA needle, showed better results than only cytological samples from FNA of cystic fluid. No data are available regarding ROSE in CPNs.

Evidence level 2b, Recommendation grade B, Agreement 91%

Comment

Although better results for both the cytobrush-needle and the trucut needle than with standard needles were reported [168-172], one study showed poorer results [169] and two studies [168,171] observed an elevated rate of complications (8-10%), including one fatality. Both the trucut and the cytobrush needles (requiring a 19-gauge needle) had technical limitations in lesions of the pancreatic head and uncinate process [168-170,173].

Confocal microscopy probes [174] and optical catheters [175] have been used in small case series to directly visualise the cyst lining and are still considered experimental.

8) What is the expected complication rate from EUS-FNA?

Statement

EUS-FNA of CPNs has a rate of intra-cyst haemorrhage of approximately 4%. Bleeding is usually self-limiting. No death has been reported after EUS-FNA performed in the standard modality with standard needles. Different risks of complications have been reported with different technical modalities of FNA or using different devices.

Evidence level 4, Recommendation grade C, Agreement 94%

Comment

A significantly higher incidence of complications for EUS-FNA of CPNs than for pancreatic solid lesions (14% vs. 0.5%); $P < 0.001$ has been reported [176-179].

Haemorrhage is usually caused by needle passage through the cyst wall, or by scratching the distal wall or septa with the needle tip (to increase the yield of cytology).

Other reported complications are anecdotal and include pancreatic fistula, acute pancreatitis, pancreatic abscess and infection.

9a) Does antibiotic prophylaxis reduce the infectious complication rate of EUS-FNA of CPNs?

Statement

There is insufficient data to demonstrate that antibiotic prophylaxis reduces the rate of infectious complications.

Evidence level 5, Recommendation grade D, Agreement 87%

Comment

Even if no increase in the rate of bacteraemia has been demonstrated after EUS-FNA in comparison to upper GI endoscopy, the incidence of infectious complications using antibiotic prophylaxis was low (0-1.4%); on the basis of these data, antibiotic prophylaxis is commonly applied in everyday clinical practice; fluoroquinolones or betalactam antibiotics administered intravenously before the procedure and orally for 3-5 days thereafter are the most commonly used regimens [155,180-182].

9b) Are there safety differences regarding needles or devices for EUS-FNA of CPNs?

Statements (Agreement 98%)

For FNA of pancreatic lesions, 19G, 22G, 25G standard needles have similar safety profiles [172,183,184].

Evidence level 1c, Recommendation grade A

Standard FNA needles are safer than cytology brush and trucut biopsy needle [168,173].

Evidence level 2c, Recommendation grade B

Comment

The use of brushing devices is associated with an increase in complication rates [168,171], and should be limited to selected cases.

Trucut biopsy needles targeted on the cystic wall may provide histological material, thus guiding management decisions but, due to their increased risk of complications, they are not currently indicated.

9c) Does the sampling technique reduce the complication rate of EUS-FNA for CPNs?

Statement

There is in sufficient data to demonstrate that the sampling technique reduces the complication rate of EUS-FNA for CPNs.

Evidence level 5, Recommendation grade D, Agreement 95%

Comment

Based on expert opinion, the following recommendations can, however, be made:

- to minimise the risk of pancreatitis, the site of the puncture must be as close as possible to the cyst to reduce puncturing normal pancreas.
- to minimise the risk of bleeding, the presence of blood vessels on the needle track must be excluded by Doppler imaging.
- no more than one needle pass is recommended to decrease the risk of bleeding and infections.
- suction must be applied to the needle in order to empty the cyst as much as possible to prevent infection [185–189].

9d) Does ROSE (rapid on-site evaluation) of the material sampled increase safety of EUS-FNA of CPNs?

Statement

There are no data as to ROSE increasing the safety of EUS-FNA of CPNs.

Evidence level 5, Recommendation grade D, Agreement 92%

Comment

In the case of solid mural nodules of the cystic lesion, more than one passage can be necessary and, in this case, we can assume the same role for ROSE as for solid lesions.

10) What is the diagnostic role of ERCP in patients with CPNs?

Statement

Diagnostic ERCP for the evaluation of CPNs is indicated only if endoscopic views of the papillary area, pancreatoscopy, or intraductal ultrasound (IDUS) are still required at the end of the diagnostic work-up for a definite diagnosis in patients with suspected IPMNs.

Evidence level 4, Recommendation grade C, Agreement 93%

Comment

Duodenoscopy can display the highly specific finding of mucus extruding from a patulous papilla of Vater in 20–55% of IPMNs. It can also display duodenal invasion/stenosis and a pancreatic duodenal fistula extruding mucus (suggesting malignant evolution) in 2% of IPMNs [189–192].

Pancreatic juice and tissue sampling can also be obtained during ERCP, however, with conflicting results. The routine use of ERCP for analysing pancreatic juice, CEA or tissue sampling is no longer recommended in branch duct type IPMNs [193].

Pancreatoscopy permits precise sampling under the direct view of ductal filling defects or strictures, allowing a differential diagnosis among vegetations, mucus and stones [194–200].

Retrograde cholangiography can detect biliary obstructions which can develop during the course of IPMNs due to malignant infiltration or external compression [200,201].

IDUS can detect communication between CPN and the pancreatic duct, minute mural nodules in IPMNs or the precise extension of ductal vegetations which may have been missed by other imaging techniques [76,202]. Combining pancreatoscopy and IDUS in IPMNs increases the ability of differentiating benign from malignant disease with an accuracy of 88% [189,191].

2.5. Laboratory markers in cystic fluid

1) Is the determination of intracystic CEA useful in the differential diagnosis between benign and malignant CPNs?

Statement

Intracystic CEA is not accurate in differentiating malignant from non-malignant CPNs.

Evidence level 2a, Recommendation grade B, Agreement 95%

Comment

Individual CEA values overlap between benign and malignant mucinous CPNs [98,118,55,203].

2) Is determination of intracystic CEA useful in the differential diagnosis between mucinous and non-mucinous CPNs?

Statement

Increased CEA levels in the cystic fluid are helpful in distinguishing mucinous from non-mucinous CPNs.

Evidence level 2a, Recommendation grade B, Agreement 96%

Comment

Although a positive/negative threshold level of 192 ng/ml is frequently reported for the cystic fluid CEA level, the cut-off level required to best differentiate mucinous from serous lesions has not yet been established.

Fluid analysis with a CEA > 800 ng/ml is specific (98–100%) for mucinous cystic adenoma or carcinoma, with a PPV of 94%. Six percent of the CPNs having CEA level of < 5 ng/ml may be a mucinous cystic adenoma or a carcinoma [55,203,204,79,205].

3) Is determination of intracystic CA19.9 useful in the differential diagnosis between benign and malignant CPNs?

Statement

Intracystic CA19.9 is not accurate in differentiating malignant from non-malignant CPNs.

Evidence level 3c, Recommendation grade B, Agreement 96%

Comment

Individual CA19.9 values overlap between benign and malignant CPNs [42,55].

4) Is determination of intracystic CA19.9 useful in the differential diagnosis between mucinous and non-mucinous CPNs?

Statement

CA19.9 measured in the cystic fluid has been reported to provide additional information within the diagnostic work-up in CPNs in which the CEA level is indeterminate.

Evidence level 3c-2a, Recommendation grade C, Agreement 86%

Comment

In CPNs in which the CEA level (between 5 and 800 ng/ml) has not been determined, a CA 19-9 level lower than the cut-off level used in serum is associated with a serous type having a sensitivity, specificity, PPV, NPV and accuracy of 19%, 98%, 94%, 38% and 46%, respectively [55].

5) Is determination of intracystic pancreatic enzymes useful in the differential diagnosis between benign and malignant CPNs?

Statement

The determination of pancreatic enzymes in the cystic fluid is not useful in the differential diagnosis between benign and malignant CPNs [57,95,98,55,206].

Evidence level 3c, Recommendation grade B, Agreement 100%

Comment

Assaying the level of lipase in the cystic fluid is discouraged due to the unsatisfactory nature of lipase methods; an amylase assay is preferred [207].

6) Is determination of intracystic amylase useful in the differential diagnosis of CPNs?

Statement

The determination of amylase in the cystic fluid is helpful in determining the differential diagnosis among CPNs. High amylase levels are usually associated with communication between the pancreatic duct and the CPNs, as in the majority of IPMNs.

Evidence level 2c, Recommendation grade B, Agreement 96%

Comment

Increased amylase in the cystic fluid from MCN has been reported in two studies; thus, these findings suggest caution in interpreting the results of amylase determination in the cystic fluid [44,205].

7) Are any other intracystic tests recommended?

Statement

On the basis of the available evidence, no tests other than CEA, CA19.9 and amylase can be recommended.

Evidence level 2c-3, Recommendation grade C, Agreement 95%

Comment

Several molecular markers, such as mucins, DNA quantity, K-ras mutation and allelic imbalance mutations, have been investigated. It is currently unknown whether the results obtained can be reliably reproduced in other laboratories [208,209,38].

8) Can a combination of intracystic tests increase the quality of the results?

Statement

The determination of both CEA and amylase is recommended to help in differentiating mucinous from non-mucinous CPNs.

Evidence level 2c, Recommendation grade B, Agreement 98%

Comment

The association of CEA and amylase is to be recommended on an empirical basis since the two tests provide different information. Elevated CEA levels may indicate the presence of a mucinous lesion while increased cystic fluid amylase is usually associated with communication with the pancreatic ducts.

9) Are there specific recommendations for collecting and preserving cystic fluid for laboratory test analysis?

Statement

Samples must be collected according to the Good Clinical Practice guidelines and managed according to Good Laboratory Practice.

Evidence level 5, Recommendation grade D, Agreement 93%

Comment

Studies on the impact of the pre-analytical phase (specimen handling, sample preparation and storage) on laboratory test results are not available [210].

10) Are there specific recommendations for the standardisation of the assay method to be used in the "fluid cyst matrix"?

Statement

The analytical performance of the assay methods for measuring CEA and CA19.9 (including at least intra-assay precision, the dilution test and the recovery test) should be validated in a matrix comparable to cystic fluid.

Evidence level 5, Recommendation grade D, Agreement 100%

Comment

Assays of markers in the cystic fluid should be carried out in experienced reference laboratories with a workload sufficient for guaranteeing method validation and ad interim evaluation of the reliability of the methods [211].

11) Are there specific recommendations for the assessment of positive/negative cut-off points for CEA, amylase and CA19.9 in the cystic fluid?

Statement

No evidence exists regarding the cut-off values to be used in clinical practice. In addition, cut-off values are partially related to the assay method used.

Evidence level 5, Recommendation grade D, Agreement 96%

Comment

For the assessment of cut-off values, it is mandatory to establish a reference standard in order to properly classify true positive and true negative cases. Most of the data available regarding the accuracy of markers derive from retrospective studies which employed the histology obtained after surgery as the gold standard. Thus, the interpretation should be cautious when the data come from retrospective series and refer to patients without clear morphological indications for surgery.

Laboratories which intend to carry out marker assays on the cystic fluid should collaborate with clinicians in order to establish their own cut-off value on the basis of patient outcome.

2.6. Pathology

1) What are the best methods for obtaining material from CPNs for pathological examination?

Statement

With FNA for pancreatic CPNs, a single pass is recommended with aspiration of a minimum of 1 ml of liquid. For pathologists, the use of the 19G, 22G and 25G needles have similar diagnostic yields [162,212].

Evidence level 2a, Recommendation grade C, Agreement 91%

Comment

The cytopathology specimens can be procured either by EUS-guided FNA (EUS-FNA) or by US or CT-guided, percutaneous aspirates. However, ROSE can be used to limit the number of FNA passes needed for solid pancreatic lesions [213-215,55,216-218], a single pass is recommended for CPNs.

The protocols for optimising multimodal analysis (cytology, biochemistry, and molecular analysis) are volume dependent whereas the technical procedures for cytological analysis should be chosen by the individual laboratories, depending on their confidence with the methods available (smears, liquid based cytology, cell-blocks).

2) Can cytological examination differentiate between benign and malignant CPNs?

Statement

A cytological examination is useful in the differential diagnosis between benign and malignant CPNs.

Evidence level 2a, Recommendation grade B, Agreement 100%

Comment

A diagnosis of malignancy has a reported sensitivity ranging from 22 to 95%, a specificity of almost 100%, PPV of 100%, NPV of 47-95%, and a diagnostic accuracy of 85-90%. The adequacy and accuracy strongly depend on the overall institutional experience,

including pathologist experience, procedure-related factors, such as instrumentation, and endoscopist skill [208,219,220].

3) How can an MCN be differentiated from a non-MCN using cytological examination?

Statement

The presence of extracellular thick mucus and the recognition of an atypical epithelial cell component with intracytoplasmic mucin represent the diagnostic hallmark of MCNs [78,221].

Evidence level 2c, Recommendation grade B, Agreement 100%

Comment

The pooled sensitivity and specificity in diagnosing mucinous cystic neoplasms are 63% and 88%, respectively, and the positive and negative likelihood ratios are 4.46 and 0.46, respectively [222]. A diagnostic epithelial component is identifiable in a minority of cases and differentiating gastric contamination from low-grade gastric-type branch duct IPMNs can be impossible.

4) What is the diagnostic value of high-grade cellular atypia?

Statement

The presence of cells with high grade atypia is the best cytological marker of malignant CPNs.

Evidence level 2b, Recommendation grade B, Agreement 96%

Comment

Lowering the threshold of cytological atypia, from “positive” for malignancy to high-grade atypia increases the prediction of malignancy from 29 to 80%, although the specificity decreases from 100 to 85% [19,219].

5) Are there any molecular analyses (i.e. DNA, mucin, K-ras and other substances) which can be used in clinical practice for a differential diagnosis between benign and malignant CPNs?

Statement

At present, no molecular marker is available in clinical practice to differentiate benign from malignant CPNs.

Evidence level 5, Recommendation grade D, Agreement 98%

Comment

Molecular analyses on the cystic fluid may be helpful in differentiating benign from malignant CPNs. Cystic fluid levels of interleukin1 β [223], glycosylation variants of mucins [37], proteomic analysis [224] and microRNA expression profiles [87,225] are among the emerging tests under investigation which could potentially become biomarkers in cystic fluid samples.

6) Are there any molecular analyses (i.e. DNA, mucin, K-ras and other substances) which can be used in clinical practice for a differential diagnosis between mucinous and non-mucinous CPNs?

Statement

At present, no molecular markers are available in clinical practice to differentiate mucinous from non-mucinous CPNs.

Evidence level 5, Recommendation grade D, Agreement 96%

Comment

Although mutations in a set of genes have recently been discovered in the majority of frequent CPNs, there are no molecular-based tests which can be used in a clinical setting. The GNAS gene was only found in patients with IPMNs and may be a useful marker in the future for differentiating IPMNs from MCNs [226].

3. Future perspectives

Several areas require further investigation through specific studies. In particular, the natural history of CPNs should be elucidated as the available data are still limited; studies comparing the yield and impact of both EUS and transcutaneous imaging in

similar CPNs are still lacking; laboratory examination of CPN fluid still requires standardisation.

The scientific societies AIGO and AISP have made a commitment to validate the present guidelines with a prospective data collection; the aim will be to evaluate the improvement of both patient management and efficiency in the utilisation of resources.

Funding sources

The organisation of the Working group and Consensus meetings was supported by unconditioned grants from Wilson Cook Inc., Pentax, Olympus, and Abbott Italia SpA.

With respect to the voting process, 100% of the participants agreed that the sponsors had no influence whatsoever on their vote.

Conflict of interest

None declared.

Acknowledgements

Authors are extremely grateful to Dr. Ivana Truccolo, executive officer of the Scientific and Patient Library at the CRO-National Cancer Institute, Aviano, for her invaluable support in literature search.

Appendix A. Coauthor affiliations

^b Pancreas Unit, Department of Digestive Diseases and Internal Medicine, S.Orsola-Malpighi Hospital, Bologna, Italy

^c Gastroenterology Unit, CRO-National Cancer Institute, Aviano, Italy

^d Gastroenterology and Hepatology Department, A.O. San Giovanni Battista/Molinette, University of Turin, Turin, Italy

^e Department of Clinical Pathology, AULSS 12, Venice, Italy

^f Ospedale Cà Foncello, Treviso, Italy

^g Department of Pathology, University of Verona, Verona, Italy

^h Division of Gastroenterology and Gastrointestinal Endoscopy, Vita-Salute, Italy

ⁱ Department of Surgery, San Raffaele Scientific Institute, Milan, Italy

^j Gastroenterology and Endoscopy Unit, ISMETT, Palermo, Italy

^k Department of Laboratory Medicine, University Hospital, Padua, Italy

^l Gastroenterology Unit, Ospedale Sacro Cuore-Don Calabria, Negrar, Verona, Italy

^m Department of Radiology, S.Orsola-Malpighi Hospital, University of Bologna, Bologna, Italy

ⁿ Digestive and Liver Disease Unit, Faculty of Medicine and Psychology, Sapienza University of Rome at S. Andrea Hospital, Rome, Italy

^o Division of Pathology, CRO-National Cancer Institute, IRCCS, Aviano, Italy

^p Department of Surgery, University of Bologna, S. Orsola-Malpighi Hospital, Bologna, Italy

^q Department of Surgery, Pancreas Unit, Università Politecnica delle Marche, Ancona, Italy

^r Department of Radiology, University Hospital G.B. Rossi, University of Verona, Verona, Italy

^s Department of Surgical and Gastroenterological Sciences, University of Verona, Verona, Italy

^t Department of Clinical Medicine, University of Bologna, Bologna, Italy

^u Pathology Unit, A.O. San Giovanni Battista/Molinette, Turin, Italy

^v Surgery Unit IV, Department of Medical and Surgical Sciences, University of Padua, Padua, Italy

^w Gastroenterology Unit, Mauriziano Hospital, Turin, Italy

^x Department of Internal Medicine and Gastroenterology, Ben-tivoglio Hospital, Bologna, Italy

^y 2nd Pathology Section, Spedali Civili, Brescia, Brescia, Italy

^z Pancreatic Surgery, Department of Surgery, Humanitas Clinical and Research Center, Milan, Italy.

Appendix B. Cystic Pancreatic Neoplasm Study Group Collaborators

Luca Albarello, Division of Pathology, San Raffaele Hospital, Milan, Italy

Lorenzo Camellini, Endoscopy Unit, S. Maria Nuova Hospital, Reggio Emilia

Paolo Cantù, Gastroenterology Department, University of Milan, IRCCS Fondazione Policlinico, Milan

Rita Conigliaro, Endoscopy Unit, Baggiovara Hospital, Modena
Guido Costamagna, Endoscopic Surgery, Catholic University, Gemelli Hospital, Rome

Giuseppe Del Favero, Gastroenterology Unit, Hospital “Santa Maria della Misericordia”, Rovigo

Giovanna Del Vecchio Blanco, Gastroenterology Department, Tor Vergata University, Rome

Pierluigi Di Sebastiano, Surgery Department, IRCCS Casa Sollievo Sofferenza, San Giovanni Rotondo (FG)

Carlo Fabbri, Gastroenterology Unit, Bellaria Hospital, Bologna
Paolo Federici, Fondazione Italiana HHT, “Onilde Carini”, Milan
Nicola Funel, Unit of Experimental Surgical Pathology, University Hospital of Pisa, Pisa

Andrea Galli, Gastroenterology Unit, University of Florence, Hospital of Careggi, Florence

Armando Gabbriellini, Department of Surgical and Gastroenterological Sciences, University of Verona, Verona

Rossella Graziani, Radiology Department, Verona University, Verona

Tiziana Guadagnini, Pediatric Unit, Maggiore Hospital, Crema

Andrea Laghi, Department of Radiological Sciences, Oncology and Pathology Sapienza – Rome University, Polo Pontino, I.C.O.T. Hospital, Latina

Giampiero Macarri, Gastroenterology Unit, Public Hospital, Fermo

Fabrizio Magnolfi, Gastroenterology Unit, Public Hospital, Arezzo

Marco Marzioni, Department of Gastroenterology, Politechnic University of Marche, Ancona

Fabio Monica, Gastroenterology Unit, San Bassiano Hospital, Bassano del Grappa

Nicola Muscatiello, Gastroenterology Department, University of Foggia, Foggia

Massimiliano Mutignani, Endoscopy Unit, Niguarda Hospital, Milan

Antonio Pisani, Gastroenterology Unit, University of Bari
Enrico Scarano, Radiology Department, San Carlo Hospital, Potenza

Carla Serra, Department of Digestive Diseases and Internal Medicine, St Orsola-Malpighi Hospital, Bologna

Marco Spada, Surgery Unit, ISMETT, Palermo

Marco Visconti, General Practitioner, Crema

Alessandro Zambelli, Gastroenterology Unit, Maggiore Hospital, Crema

Appendix C. Supplementary data

Supplementary data associated with this article can be found, in the online version, at <http://dx.doi.org/10.1016/j.dld.2013.12.019>.

References

- [1] Bosman FT, Carneiro F, Hruban RH, Theise ND. WHO classification of tumours of the digestive system. 4th ed. Lyon: International Agency for Research on Cancer; 2010.
- [2] Laffan TA, Horton KM, Klein AP, et al. Prevalence of unsuspected pancreatic cysts on MDCT. *American Journal of Roentgenology* 2008;191:802–7.
- [3] Lee KS, Sekhar A, Rofsky NM, Pedrosa I. Prevalence of incidental pancreatic cysts in the adult population on MR imaging. *The American Journal of Gastroenterology* 2010;105:2079–84.
- [4] Zhang XM, Mitchell DG, Dohke M, et al. Pancreatic cysts: depiction on single-shot fast spin-echo MR images. *Radiology* 2002;223:547–53.
- [5] Kimura W, Nagai H, Kuroda A, et al. Analysis of small cystic lesions of the pancreas. *International Journal of Pancreatology* 1995;18:197–206.
- [6] Tanaka M, Fernandez-Del Castillo C, Adsay V, et al. International consensus guidelines 2012 for the management of IPMN and MCN of the pancreas. *Pancreatology* 2012;12:183–97.
- [7] Del Chiaro M, Verbeke C, Salvia R, et al. European experts consensus statement on cystic tumours of the pancreas. *Digestive and Liver Disease* 2013;45:703–11.
- [8] MacIntyre CR, Plant AJ, Hendrie D. Shifting the balance between in-patient and out-patient for tuberculosis results in economic savings. *The International Journal of Tuberculosis and Lung Disease* 2001;5:266–71.
- [9] Linstone HA, Turoff M, editors. *The Delphi method: techniques and applications*. 2002. ISBN 0-201-04294-0.
- [10] Centre for Evidence-based Medicine at the University of Oxford. <http://www.cebm.net>
- [11] Khannoussi W, Vullierme MP, Rebours V, et al. The long term risk of malignancy in patients with branch duct intraductal papillary mucinous neoplasms of the pancreas. *Pancreatology* 2012;12:198–202.
- [12] Weinberg BM, Spiegel BM, Tomlinson JS, Farrell JJ. Asymptomatic pancreatic cystic neoplasms: maximizing survival and quality of life using Markov-based clinical nomograms. *Gastroenterology* 2010;138:531–40.
- [13] Dewhurst CE, Morteel KJ. Cystic tumors of the pancreas: imaging and management. *Radiologic Clinics of North America* 2012;50:467–86.
- [14] Arlix A, Bournet B, Otal P, et al. Long-term clinical and imaging follow-up of nonoperated branch duct form of intraductal papillary mucinous neoplasms of the pancreas. *Pancreas* 2012;41:295–301.
- [15] Sahara S, Kawai N, Sato M, et al. Differentiation of pancreatic serous cystadenoma from endocrine tumor and intraductal papillary mucinous neoplasm based on washout pattern on multiphase CT. *Journal of Computer Assisted Tomography* 2012;36:231–6.
- [16] Kimura W, Moriya T, Hanada K, et al. Multicenter study of serous cystic neoplasm of the Japan pancreas society. *Pancreas* 2012;41:380–7.
- [17] Rossidis G, Arroyo MR, Abbitt PL, et al. Malignant transformation of a pancreatic serous cystadenoma. *The American Surgeon* 2012;78:260–3.
- [18] Kelly PJ, Shinagare S, Sainani N, et al. Cystic papillary pattern in pancreatic ductal adenocarcinoma: a heretofore undescribed morphologic pattern that mimics intraductal papillary mucinous carcinoma. *The American Journal of Surgical Pathology* 2012;36:696–701.
- [19] Genevay M, Mino-Kenudson M, Yaeger K, et al. Cytology adds value to imaging studies for risk assessment of malignancy in pancreatic mucinous cysts. *Annals of Surgery* 2011;254:977–83.
- [20] Malleo G, Bassi C, Rossini R, et al. Growth pattern of serous cystic neoplasms of the pancreas: observational study with long-term magnetic resonance surveillance and recommendations for treatment. *Gut* 2012;61:746–51.
- [21] Wu J, Matthaei H, Maitra A, et al. Recurrent GNAS mutations define an unexpected pathway for pancreatic cyst development. *Science Translational Medicine* 2011;20:3.
- [22] Venkatesh PG, Navaneethan U, Vege SS. Intraductal papillary mucinous neoplasm and acute pancreatitis. *Journal of Clinical Gastroenterology* 2011;45:755–8.
- [23] Khashab MA, Shin EJ, Amateau S, et al. Tumor size and location correlate with behavior of pancreatic serous cystic neoplasms. *The American Journal of Gastroenterology* 2011;106:1521–6.
- [24] Lv P, Mahyoub R, Lin X, et al. Differentiating pancreatic ductal adenocarcinoma from pancreatic serous cystadenoma, mucinous cystadenoma, and a pseudocyst with detailed analysis of cystic features on CT scans: a preliminary study. *Korean Journal of Radiology* 2011;12:187–95.
- [25] Schraibman V, Goldman SM, Ardengh JC, et al. New trends in diffusion-weighted magnetic resonance imaging as a tool in differentiation of serous cystadenoma and mucinous cystic tumor: a prospective study. *Pancreatology* 2011;11:43–51.
- [26] Al-Haddad M, Schmidt MC, Sandrasegaran K, Dewitt J. Diagnosis and treatment of cystic pancreatic tumors. *Clinical Gastroenterology and Hepatology* 2011;9:635–48.

- [27] Lee JH, Kim JK, Kim TH, et al. MRI features of serous oligocystic adenoma of the pancreas: differentiation from mucinous cystic neoplasm of the pancreas. *The British Journal of Radiology* 2012;85:571–6.
- [28] Fukasawa M, Maguchi H, Takahashi K, et al. Clinical features and natural history of serous cystic neoplasm of the pancreas. *Pancreatology* 2010;10:695–701.
- [29] Fatima Z, Ichikawa T, Motosugi U, et al. Magnetic resonance diffusion-weighted imaging in the characterization of pancreatic mucinous cystic lesions. *Clinical Radiology* 2011;66:108–11.
- [30] Sato M, Hiyama T, Kato K, et al. F-18 FDG accumulation in mucinous cystic neoplasm of pancreas. *Clinical Nuclear Medicine* 2011;36:45–8.
- [31] Yamao K, Yanagisawa A, Takahashi K, et al. Clinicopathological features and prognosis of mucinous cystic neoplasm with ovarian-type stroma: a multi-institutional study of the Japan pancreas society. *Pancreas* 2011;40:67–71.
- [32] Kang MJ, Jang JY, Kim SJ, et al. Cyst growth rate predicts malignancy in patients with branch duct intraductal papillary mucinous neoplasms. *Clinical Gastroenterology and Hepatology* 2011;9:87–93.
- [33] Thosani N, Thosani S, Qiao W, et al. Role of EUS-FNA-based cytology in the diagnosis of mucinous pancreatic cystic lesions: a systematic review and meta-analysis. *Digestive Diseases and Sciences* 2010;55:2756–66.
- [34] D'Onofrio M, Gallotti A, Salvia R, et al. Acoustic radiation force impulse (ARFI) ultrasound imaging of pancreatic cystic lesions. *European Journal of Radiology* 2011;80:241–4.
- [35] Correa-Gallego C, Ferrone CR, Thayer SP, et al. Incidental pancreatic cysts: do we really know what we are watching? *Pancreatology* 2010;10:144–50.
- [36] Roggin KK, Chennat J, Oto A, et al. Pancreatic cystic neoplasm. *Current Problems in Surgery* 2010;47:459–510.
- [37] Haab BB, Porter A, Yue T, et al. Glycosylation variants of mucins and CEACAMs as candidate biomarkers for the diagnosis of pancreatic cystic neoplasms. *Annals of Surgery* 2010;251:937–45.
- [38] Allen PJ, Qin LX, Tang L, et al. Pancreatic cyst fluid protein expression profiling for discriminating between serous cystadenoma and intraductal papillary mucinous neoplasm. *Annals of Surgery* 2009;250:754–60.
- [39] Sadakari Y, Ienaga J, Kobayashi K, et al. Cyst size indicates malignant transformation in branch duct intraductal papillary mucinous neoplasm of the pancreas without mural nodules. *Pancreas* 2010;39:232–6.
- [40] Kubo H, Nakamura K, Itaba S, et al. Differential diagnosis of cystic tumors of the pancreas by endoscopic ultrasonography. *Endoscopy* 2009;41:684–9.
- [41] Choi JY, Kim MJ, Lee JY, et al. Typical and atypical manifestations of serous cystadenoma of the pancreas: imaging findings with pathologic correlation. *American Journal of Roentgenology* 2009;193:136–42.
- [42] Leung KK, Ross WA, Evans D, et al. Pancreatic cystic neoplasm: the role of cyst morphology, cyst fluid analysis, and expectant management. *Annals of Surgical Oncology* 2009;16:2818–24.
- [43] King JC, Ng TT, White SC, et al. Pancreatic serous cystadenocarcinoma: a case report and review of the literature. *Journal of Gastrointestinal Surgery* 2009;13:1864–8.
- [44] Ferrone CR, Correa-Gallego C, Warshaw AL, et al. Current trends in pancreatic cystic neoplasms. *Archives of Surgery* 2009;144:448–54.
- [45] Woo SM, Ryu JK, Lee SH, et al. Branch duct intraductal papillary mucinous neoplasms in a retrospective series of 190 patients. *The British Journal of Surgery* 2009;96:405–11.
- [46] Yoon WJ, Ryu JK, Lee JK, et al. Extrapancreatic malignancies in patients with intraductal papillary mucinous neoplasm of the pancreas: prevalence, associated factors, and comparison with patients with other pancreatic cystic neoplasms. *Annals of Surgical Oncology* 2008;15:3193–8.
- [47] Tang RS, Weinberg B, Dawson DW, et al. Evaluation of the guidelines for management of pancreatic branch-duct intraductal papillary mucinous neoplasm. *Clinical Gastroenterology and Hepatology* 2008;6:815–9.
- [48] Petrone MC, Arcidiacono PG. Role of endoscopic ultrasound in the diagnosis of cystic tumours of the pancreas. *Digestive and Liver Disease* 2008;40:847–53.
- [49] Crippa S, Salvia R, Warshaw AL, et al. Mucinous cystic neoplasm of the pancreas is not an aggressive entity: lessons from 163 resected patients. *Annals of Surgery* 2008;247:571–9.
- [50] Kim HJ, Lee DH, Ko YT, et al. CT of serous cystadenoma of the pancreas and mimicking masses. *American Journal of Roentgenology* 2008;190:406–12.
- [51] Lee CJ, Scheiman J, Anderson MA, et al. Risk of malignancy in resected cystic tumors of the pancreas < or = 3 cm in size: is it safe to observe asymptomatic patients? A multi-institutional report. *Journal of Gastrointestinal Surgery* 2008;12:234–42.
- [52] Khalid A, Brugge W. ACG practice guidelines for the diagnosis and management of neoplastic pancreatic cysts. *The American Journal of Gastroenterology* 2007;102:2339–49.
- [53] Galanis C, Zamani A, Cameron JL, et al. Resected serous cystic neoplasms of the pancreas: a review of 158 patients with recommendations for treatment. *Journal of Gastrointestinal Surgery* 2007;11:820–6.
- [54] Tseng JF, Warshaw AL, Sahani DV, et al. Serous cystadenoma of the pancreas: tumor growth rates and recommendations for treatment. *Annals of Surgery* 2005;242:413–9.
- [55] van der Waaij LA, van Dullemen HM, Porte RJ. Cyst fluid analysis in the differential diagnosis of pancreatic cystic lesions: a pooled analysis. *Gastrointestinal Endoscopy* 2005;62:383–9.
- [56] Reddy RP, Smyrk TC, Zapiach M, et al. Pancreatic mucinous cystic neoplasm defined by ovarian stroma: demographics, clinical features, and prevalence of cancer. *Clinical Gastroenterology and Hepatology* 2004;2:1026–31.
- [57] Hammel PR, Vilgrain V, Terris B, et al. Pancreatic involvement in von Hippel-Lindau disease. The Groupe Francophone d'Etude de la Maladie de von Hippel-Lindau. *Gastroenterology* 2000;119:1087–95.
- [58] Fritz S, Klaus M, Bergmann F, et al. Small (Sendai negative) branch-duct IPMNs: not harmless. *Annals of Surgery* 2012;256:313–20.
- [59] Partelli S, Fernandez-Del Castillo C, Bassi C, et al. Invasive intraductal papillary mucinous carcinomas of the pancreas: predictors of survival and the role of lymph node ratio. *Annals of Surgery* 2010;251:477–82.
- [60] Crippa S, Fernández-Del Castillo C, Salvia R, et al. Mucin-producing neoplasms of the pancreas: an analysis of distinguishing clinical and epidemiologic characteristics. *Clinical Gastroenterology and Hepatology* 2010;8:213–9.
- [61] Rodriguez JR, Salvia R, Crippa S, et al. Branch-duct intraductal papillary mucinous neoplasms: observations in 145 patients who underwent resection. *Gastroenterology* 2007;133:72–9.
- [62] Schmidt CM, White PB, Waters JA, et al. Intraductal papillary mucinous neoplasms: predictors of malignant and invasive pathology. *Annals of Surgery* 2007;246:644–51.
- [63] Sohn TA, Yeo CJ, Cameron JL, et al. Intraductal papillary mucinous neoplasms of the pancreas: an updated experience. *Annals of Surgery* 2004;239:788–97.
- [64] Moriya T, Hashimoto Y, Traverso LW. The duration of symptoms predicts the presence of malignancy in 210 resected cases of pancreatic intraductal papillary mucinous neoplasms. *Journal of Gastrointestinal Surgery* 2011;15:762–70.
- [65] Waters JA, Schmidt CM, Pinchot JW, et al. CT vs MRCP: optimal classification of IPMN type and extent. *Journal of Gastrointestinal Surgery* 2008;12:101–9.
- [66] Pedrazzoli S, Sperti C, Pasquali C, et al. Comparison of International Consensus Guidelines versus 18-FDG PET in detecting malignancy of intraductal papillary mucinous neoplasms of the pancreas. *Annals of Surgery* 2011;254:971–6.
- [67] Berland LL, Silverman SG, Gore RM, et al. Managing incidental findings on abdominal CT: white paper of the ACR incidental findings committee. *Journal of the American College of Radiology* 2010;7:754–73.
- [68] Riall TS, Stager VM, Nealon WH, et al. Incidence of additional primary cancers in patients with invasive intraductal papillary mucinous neoplasms and sporadic pancreatic adenocarcinomas. *Journal of the American College of Surgeons* 2007;204:803–13.
- [69] Calculli L, Pezzilli R, Brindisi C, et al. Pancreatic and extrapancreatic lesions in patients with intraductal papillary mucinous neoplasms of the pancreas: a single-centre experience. *La Radiologia Medica* 2010;115:442–52.
- [70] Reid-Lombardo KM, Mathis KL, Wood CM, et al. Frequency of extrapancreatic neoplasms in intraductal papillary mucinous neoplasm of the pancreas: implications for management. *Annals of Surgery* 2010;251:64–9.
- [71] Baumgaertner I, Corcos O, Couvelard A, et al. Prevalence of extrapancreatic cancers in patients with histologically proven intraductal papillary mucinous neoplasms of the pancreas: a case-control study. *The American Journal of Gastroenterology* 2008;103:2878–82.
- [72] Ingkakul T, Sadakari Y, Ienaga J, et al. Predictors of the presence of concomitant invasive ductal carcinoma in intraductal papillary mucinous neoplasm of the pancreas. *Annals of Surgery* 2010;251:70–5.
- [73] Kawakubo K, Tada M, Isayama H, et al. Incidence of extrapancreatic malignancies in patients with intraductal papillary mucinous neoplasms of the pancreas. *Gut* 2011;60:1249–53.
- [74] Uehara H, Nakaizumi A, Ishikawa O, et al. Development of ductal carcinoma of the pancreas during follow-up of branch duct intraductal papillary mucinous neoplasm of the pancreas. *Gut* 2008;57:1561–5.
- [75] Tanno S, Nakano Y, Koizumi K, et al. Pancreatic ductal adenocarcinomas in long-term follow-up patients with branch duct intraductal papillary mucinous neoplasms. *Pancreas* 2010;39:36–40.
- [76] Fritz S, Hackert T, Hinz U, et al. Role of serum carbohydrate antigen 19-9 and carcinoembryonic antigen in distinguishing between benign and invasive intraductal papillary mucinous neoplasm of the pancreas. *The British Journal of Surgery* 2011;98:104–10.
- [77] Nehra D, Oyarvide VM, Mino-Kenudson M, et al. Intraductal papillary mucinous neoplasms: does a family history of pancreatic cancer matter? *Pancreatology* 2012;12:358–63.
- [78] Brugge WR, Lewandrowski K, Lee-Lewandrowski E, et al. Diagnosis of pancreatic cystic neoplasms: a report of the cooperative pancreatic cyst study. *Gastroenterology* 2004;126:1330–6.
- [79] Khalid A, Zahid M, Finkelstein SD, et al. Pancreatic cyst fluid DNA analysis in evaluating pancreatic cysts: a report of the PANDA study. *Gastrointestinal Endoscopy* 2009;69:1095–102.
- [80] Correa-Gallego C, Warshaw AL, Fernandez-del Castillo C. Fluid CEA in IPMNs: a useful test or the flip of a coin? *The American Journal of Gastroenterology* 2009;104:796–7.
- [81] Othman MO, Patel M, Dabizzi E, et al. Carcino Embryonic Antigen and long-term follow-up of mucinous pancreatic cysts including intraductal papillary mucinous neoplasm. *Digestive and Liver Disease* 2012;44:844–8.
- [82] Zhong N, Zhang L, Takahashi N, et al. Histologic and imaging features of mural nodules in mucinous pancreatic cysts. *Clinical Gastroenterology and Hepatology* 2012;10:192–8.
- [83] Bournet B, Kirzin S, Carrère N, et al. Clinical fate of branch duct and mixed forms of intraductal papillary mucinous neoplasia of the pancreas. *Journal of Gastroenterology and Hepatology* 2009;24:1211–7.
- [84] Rautou PE, Lévy P, Vullierme MP, et al. Morphologic changes in branch duct intraductal papillary mucinous neoplasms of the pancreas: a

- midterm follow-up study. *Clinical Gastroenterology and Hepatology* 2008;6: 807–14.
- [85] Jang JY, Kim SW, Lee SE, et al. Treatment guidelines for branch duct type intraductal papillary mucinous neoplasms of the pancreas: when can we operate or observe? *Annals of Surgical Oncology* 2008;15:199–205.
- [86] Salvia R, Crippa S, Falconi M, et al. Branch-duct intraductal papillary mucinous neoplasms of the pancreas: to operate or not to operate? *Gut* 2007;56:1086–90.
- [87] Matthaei H, Norris AL, Tsiatis AC, et al. Clinicopathological characteristics and molecular analyses of multifocal intraductal papillary mucinous neoplasms of the pancreas. *Annals of Surgery* 2012;255:326–33.
- [88] Maguchi H, Tanno S, Mizuno N, et al. Natural history of branch duct intraductal papillary mucinous neoplasms of the pancreas: a multicenter study in Japan. *Pancreas* 2011;40:364–70.
- [89] Gill KR, Pelaez-Luna M, Keaveny A, et al. Branch duct intraductal papillary mucinous neoplasm of the pancreas in solid organ transplant recipients. *The American Journal of Gastroenterology* 2009;104:1256–61.
- [90] Salvia R, Fernandez-del-Castillo C, Bassi C, et al. Main-duct intraductal papillary mucinous neoplasms of the pancreas: clinical predictors of malignancy and long-term survival following resection. *Annals of Surgery* 2004;239:678–87.
- [91] Rodriguez J. Branch-duct intraductal papillary mucinous neoplasms: observations in 145 patients who underwent resection. *Gastroenterology* 2007;133:72–9.
- [92] Pannala R, Leirness JB, Bamlet WR, et al. Prevalence and clinical profile of pancreatic cancer-associated diabetes mellitus. *Gastroenterology* 2008;134:981–7.
- [93] Ben Q, Cai Q, Li Z, et al. The relationship between new-onset diabetes mellitus and pancreatic cancer risk: a case–control study. *European Journal of Cancer* 2011;47:248–54.
- [94] Pannala R, Basu A, Petersen GM, Chari ST. New-onset diabetes: a potential clue to the early diagnosis of pancreatic cancer. *The Lancet Oncology* 2009;10:88–95.
- [95] Sperti C, Pasquali C, Guolo P, et al. Evaluation of cyst fluid analysis in the diagnosis of pancreatic cysts. *The Italian Journal of Gastroenterology* 1995;27:479–83.
- [96] Bassi C, Salvia R, Gumbs AA, et al. The value of standard serum tumor markers in differentiating mucinous from serous cystic tumors of the pancreas: CEA, Ca 19-9, Ca 125, Ca 15-3. *Langenbeck's Archives of Surgery* 2002;387: 281–5.
- [97] Wu H, Cheng NS, Zhang YG, et al. Improved early diagnosis of cystadenocarcinoma of the pancreas. *Hepatobiliary & Pancreatic Diseases International* 2007;6:87–91.
- [98] Javle M, Shah P, Yu J, et al. Cystic pancreatic tumors (CPT): predictors of malignant behavior. *Journal of Surgical Oncology* 2007;95:221–8.
- [99] Wu H, Yan LN, Cheng NS, et al. Role of cystic fluid in diagnosis of the pancreatic cystadenoma and cystadenocarcinoma. *Hepatogastroenterology* 2007;54:1915–8.
- [100] Goh B, Tan Y-M, Thang C-H, et al. How useful are clinical, biochemical, and cross-sectional imaging features in predicting potentially malignant or malignant cystic lesions of the pancreas? Experience with 220 surgically treated patients. Results from a single institution. *Journal of the American College of Surgeons* 2008;206:17–27.
- [101] Hirono S, Tani M, Kawai M, et al. Treatment strategy for intraductal papillary mucinous neoplasm of the pancreas based on malignant predictive factors. *Archives of Surgery* 2009;144:345–9.
- [102] Safi F, Roscher R, Bittner R, et al. High sensitivity and specificity of CA 19-9 for pancreatic carcinoma in comparison to chronic pancreatitis. Serological and immunohistochemical findings. *Pancreas* 1987;2:398–403.
- [103] Frebourg T, Bercoff E, Manchon N, et al. The evaluation of CA 19-9 antigen level in the early detection of pancreatic cancer: a prospective study of 866 patients. *Cancer* 1988;62:2287–90.
- [104] Steinberg W. The clinical utility of the CA19-9 tumor-associated antigen. *The American Journal of Gastroenterology* 1990;85:350–5.
- [105] Duffy MJ, Sturgeon C, Lamerz R, et al. Tumor markers in pancreatic cancer: a European Group on Tumor Markers (EGTM) status report. *Annals of Oncology* 2010;21:441–7.
- [106] Galli C, Basso D, Plebani M. CA 19-9: handle with care. *Clinical Chemistry and Laboratory Medicine* 2013:1–15.
- [107] Rickes S, Unkrodt K, Neye H, et al. Differentiation of pancreatic tumours by conventional ultrasound, unenhanced and echo-enhanced power Doppler sonography. *Scandinavian Journal of Gastroenterology* 2002;37: 1313–20.
- [108] Beyer-Enke SA, Hocke M, Ignee A, et al. Contrast enhanced transabdominal ultrasound in the characterisation of pancreatic lesions with cystic appearance. *Journal of the Pancreas* 2010;11:427–33.
- [109] D'Onofrio M, Barbi E, Dietrich CF, et al. Pancreatic multicenter ultrasound study (PAMUS). *European Journal of Radiology* 2012;81:630–8.
- [110] D'Onofrio M, Megibow AJ, Faccioli N, et al. Comparison of contrast-enhanced sonography and MRI in displaying anatomic features of cystic pancreatic masses. *American Journal of Roentgenology* 2007;189: 1435–42.
- [111] Kurihara N, Kawamoto H, Kobayashi Y, et al. Vascular patterns in nodules of intraductal papillary mucinous neoplasms depicted under contrast-enhanced ultrasonography are helpful for evaluating malignant potential. *European Journal of Radiology* 2012;81:66–70.
- [112] Sainani N, Saokar A, Deshpande V, et al. Comparative performance of MDCT and MRI with MR cholangiopancreatography in characterizing small pancreatic cysts. *American Journal of Roentgenology* 2009;193:722–31.
- [113] Sahani DV, Sainani NI, Blake MA, et al. Prospective evaluation of reader performance on MDCT in characterization of cystic pancreatic lesions and prediction of cyst biologic aggressiveness. *American Journal of Roentgenology* 2011;197:W53–61.
- [114] Lee HJ, Kim MJ, Choi JY, et al. Relative accuracy of CT and MRI in the differentiation of benign from malignant pancreatic cystic lesions. *Clinical Radiology* 2011;66:315–21.
- [115] Visser BC, Yeh BM, Qayyum A, et al. Characterization of cystic pancreatic masses: relative accuracy of CT and MRI. *American Journal of Roentgenology* 2007;189:648–56.
- [116] Procacci C, Carboggin G, Accordini S, et al. CT features of malignant mucinous cystic tumors of the pancreas. *European Radiology* 2001;11:1626–30.
- [117] Kim JH, Eun HW, Park HJ, et al. Diagnostic performance of MRI and EUS in the differentiation of benign from malignant pancreatic cyst and cyst communication with the main duct. *European Journal of Radiology* 2012;81:2927–35.
- [118] Kim YC, Choi JY, Chung YE, et al. Comparison of MRI and endoscopic ultrasound in the characterization of pancreatic cystic lesions. *American Journal of Roentgenology* 2010;195:947–52.
- [119] Sahani DV, Kadavigere R, Blake M, et al. Intraductal papillary mucinous neoplasm of pancreas: multi-detector row CT with 2D curved reformations – correlation with MRCP. *Radiology* 2006;238:560–9.
- [120] Ogawa H, Itoh S, Ikeda M, et al. Intraductal papillary mucinous neoplasm of the pancreas: assessment of the likelihood of invasiveness with multisection CT. *Radiology* 2008;248:876–86.
- [121] Song SJ, Lee JM, Kim YJ, et al. Differentiation of intraductal papillary mucinous neoplasms from other pancreatic cystic masses: comparison of multirow-detector CT and MR imaging using ROC analysis. *Journal of Magnetic Resonance Imaging* 2007;26:86–93.
- [122] Hong HS, Yun M, Cho A, et al. The utility of F-18 FDG PET/CT in the evaluation of pancreatic intraductal papillary mucinous neoplasm. *Clinical Nuclear Medicine* 2010;35:776–9.
- [123] Takanami K, Hiraide T, Tsuda M, et al. Additional value of FDG PET/CT to contrast-enhanced CT in the differentiation between benign and malignant intraductal papillary mucinous neoplasms of the pancreas with mural nodules. *Annals of Nuclear Medicine* 2011;25:501–10.
- [124] Tomimaru Y, Takeda Y, Tatsumi M, et al. Utility of 2-[¹⁸F] fluoro-2-deoxy-d-glucose positron emission tomography in differential diagnosis of benign and malignant intraductal papillary–mucinous neoplasm of the pancreas. *Oncology Reports* 2010;24:613–20.
- [125] Sperti C, Pasquali C, Decet G, et al. F-18-fluorodeoxyglucose positron emission tomography in differentiating malignant from benign pancreatic cysts: a prospective study. *Journal of Gastrointestinal Surgery* 2005;9:22–8.
- [126] Sainani N, Sahani DV, Blake M, et al. Morphological and functional characterization of mucinous lesions of pancreas: is the combination PET-CT better than MDCT or PET alone? *Journal of Nuclear Medicine Meeting Abstracts* 2008;49(Suppl. 1):273P.
- [127] Shah AA, Sainani NI, Kambadakone AR, et al. Predictive value of multi-detector computed tomography for accurate diagnosis of serous cystadenoma: radiologic–pathologic correlation. *World Journal of Gastroenterology* 2009;15:2739–47.
- [128] De Jong K, van Hooft JE, Nio CY, et al. Accuracy of preoperative workup in a prospective series of surgically resected cystic pancreatic lesions. *Scandinavian Journal of Gastroenterology* 2012;8/9:1056–63.
- [129] Pais SA, Attasaranya S, Leblanc JK, et al. Role of endoscopic ultrasound in the diagnosis of intraductal papillary mucinous neoplasms: correlation with surgical histopathology. *Clinical Gastroenterology and Hepatology* 2007;5:489–95.
- [130] Kubo H, Chijiwa Y, Akahoshi K, et al. Intraductal papillary-mucinous tumors of the pancreas: differential diagnosis between benign and malignant tumors by endoscopic ultrasonography. *The American Journal of Gastroenterology* 2001;96:1429–34.
- [131] Nakagawa A, Yamaguchi T, Ohtsuka M, et al. Usefulness of multidetector computed tomography for detecting protruding lesions in intraductal papillary mucinous neoplasm of the pancreas in comparison with single-detector computed tomography and endoscopic ultrasonography. *Pancreas* 2009;38:131–6.
- [132] Ohno E, Hirooka Y, Itoh A, et al. Intraductal papillary mucinous neoplasms of the pancreas: differentiation of malignant and benign tumors by endoscopic ultrasound findings of mural nodules. *Annals of Surgery* 2009;249: 628–34.
- [133] Oh HC, Kim MH, Hwang CY, et al. Cystic lesions of the pancreas: challenging issues in clinical practice. *The American Journal of Gastroenterology* 2008;103:229–39.
- [134] Sedlack R, Affi A, Vazquez-Sequeiros E, et al. Utility of EUS in the evaluation of cystic pancreatic lesions. *Gastrointestinal Endoscopy* 2002;56:543–7.
- [135] Koito K, Namieno T, Nagakawa T, et al. Solitary cystic tumor of the pancreas: EUS–pathologic correlation. *Gastrointestinal Endoscopy* 1997;45:268–76.
- [136] Hernandez LV, Mishra G, Forsmark C, et al. Role of endoscopic ultrasound (EUS) and EUS-guided fine needle aspiration in the diagnosis and treatment of cystic lesions of the pancreas. *Pancreas* 2002;25:222–8.
- [137] Frossard JL, Amouyal P, Amouyal G, et al. Performance of endosonography-guided fine needle aspiration and biopsy in the diagnosis of pancreatic cystic lesions. *The American Journal of Gastroenterology* 2003;98:1516–24.

- [138] Ahmad NA, Kochman ML, Brensinger C, et al. Interobserver agreement among endosonographers for the diagnosis of neoplastic versus non-neoplastic pancreatic cystic lesions. *Gastrointestinal Endoscopy* 2003;58:59–64.
- [139] Gerke H, Jaffe TA, Mitchell RM, et al. Endoscopic ultrasound and computer tomography are inaccurate methods of classifying cystic pancreatic lesions. *Digestive and Liver Disease* 2006;38:39–44.
- [140] Ahmad NA, Kochman ML, Lewis JD, Ginsberg GG. Can EUS alone differentiate between malignant and benign cystic lesions of the pancreas? *The American Journal of Gastroenterology* 2001;96:3295–300.
- [141] de Jong K, Verlaan T, Dijkgraaf MG, et al. Interobserver agreement for endosonography in the diagnosis of pancreatic cysts. *Endoscopy* 2011;43:579–84.
- [142] O'Toole D, Palazzo L, Hammel P, et al. Macrocystic pancreatic cystadenoma: the role of EUS and cyst fluid analysis in distinguishing mucinous and serous lesions. *Gastrointestinal Endoscopy* 2004;59:823–9.
- [143] Song MH, Lee SK, Kim MH, et al. EUS in the evaluation of pancreatic cystic lesions. *Gastrointestinal Endoscopy* 2003;57:891–6.
- [144] Adimoolam V, Sanchez MJ, Siddiqui UD, et al. Endoscopic ultrasound identifies synchronous pancreas cystic lesions not seen on initial cross-sectional imaging. *Pancreas* 2011;40:1070–2.
- [145] Dietrich CF, Ignee A, Braden B, et al. Improved differentiation of pancreatic tumors using contrast-enhanced endoscopic ultrasound. *Clinical Gastroenterology and Hepatology* 2008;6: 590–7.e1.
- [146] Janssen C, Alvarez-Sánchez MV, Napoléon B, Faiss S. Diagnostic endoscopic ultrasonography: assessment of safety and prevention of complications. *World Journal of Gastroenterology* 2012;18:4659–76.
- [147] Buscarini E, De Angelis C, Arcidiacono PG, et al. Multicentre retrospective study on endoscopic ultrasound complications. *Digestive and Liver Disease* 2006;38:762–7.
- [148] Bournet B, Miguères I, Delacroix M, et al. Early morbidity of endoscopic ultrasound: 13 years' experience at a referral center. *Endoscopy* 2006;38:349–54.
- [149] Rösch T, Dittler HJ, Fockens P, et al. Major complications of endoscopic ultrasonography: results of a survey of 42105 cases. *Gastrointestinal Endoscopy* 1993;39:370 [abstract].
- [150] Das A, Sivak MV, Chak A. Cervical esophageal perforation during EUS: a national survey. *Gastrointestinal Endoscopy* 2001;53:599–602.
- [151] Eloubeidi MA, Tamhane A, Lopes TL, et al. Cervical esophageal perforations at the time of endoscopic ultrasound: a prospective evaluation of frequency, outcomes, and patient management. *The American Journal of Gastroenterology* 2009;104:53–6.
- [152] Sebastian S, Byrne AT, Torreggiani WC, Buckley M. Endoscopic closure of iatrogenic duodenal perforation during endoscopic ultrasound. *Endoscopy* 2004;36:245.
- [153] Mortensen MB, Frstrup C, Holm FS, et al. Prospective evaluation of patient tolerability, satisfaction with patient information, and complications in endoscopic ultrasonography. *Endoscopy* 2005;37:146–53.
- [154] Lachter J. Fatal complications of endoscopic ultrasonography: a look at 18 cases. *Endoscopy* 2007;39:747–50.
- [155] Janssen J, König K, Knop-Hammad V, et al. Frequency of bacteremia after linear EUS of the upper GI tract with and without FNA. *Gastrointestinal Endoscopy* 2004;59:339–44.
- [156] Benson ME, Byrne S, Brust DJ, et al. EUS and ERCP complication rates are not increased in elderly patients. *Digestive Diseases and Sciences* 2010;55:3278–328.
- [157] Pitman MB, Michaels PJ, Deshpande V, et al. Cytological and cyst fluid analysis of small (< or =3 cm) branch duct intraductal papillary mucinous neoplasms adds value to patient management decisions. *Pancreatology* 2008;8:277–84.
- [158] Cizginer S, Turner B, Bilge AR, et al. Cyst fluid carcinoembryonic antigen is an accurate diagnostic marker of pancreatic mucinous cysts. *Pancreas* 2011;40:1024–8.
- [159] Moparty B, Logroño R, Nealon WH, et al. The role of endoscopic ultrasound and endoscopic ultrasound-guided fine-needle aspiration in distinguishing pancreatic cystic lesions. *Diagnostic Cytopathology* 2007;35:18–25.
- [160] Hong SK, Loren DE, Rogart JN, et al. Targeted cyst wall puncture and aspiration during EUS-FNA increases the diagnostic yield of premalignant and malignant pancreatic cysts. *Gastrointestinal Endoscopy* 2012;75:775–82.
- [161] Linder JD, Geenen JE, Catalano MF. Cyst fluid analysis obtained by EUS-guided FNA in the evaluation of discrete cystic neoplasms of the pancreas: a prospective single-center experience. *Gastrointestinal Endoscopy* 2006;64:697–702.
- [162] Rogart JN, Loren DE, Singu BS, Kowalski TE. Cyst wall puncture and aspiration during EUS-guided fine needle aspiration may increase the diagnostic yield of mucinous cysts of the pancreas. *Journal of Clinical Gastroenterology* 2011;45:164–9.
- [163] Shami VM, Sundaram V, Stelov EB, et al. The level of carcinoembryonic antigen and the presence of mucin as predictors of cystic pancreatic mucinous neoplasia. *Pancreas* 2007;34:466–9.
- [164] Walsh RM, Zuccaro G, Dumot JA, et al. Predicting success of endoscopic aspiration for suspected pancreatic cystic neoplasms. *Journal of the Pancreas* 2008;9:612–7.
- [165] Attasaranya S, Pais S, LeBlanc J, et al. Endoscopic ultrasound-guided fine needle aspiration and cyst fluid analysis for pancreatic cysts. *Journal of the Pancreas* 2007;8:553–63.
- [166] Repák R, Rejchrt S, Bártoš J, et al. Endoscopic ultrasonography (EUS) and EUS-guided fine-needle aspiration with cyst fluid analysis in pancreatic cystic neoplasms. *Hepatogastroenterology* 2009;56:629–35.
- [167] Garud SS, Willingham FF. Molecular analysis of cyst fluid aspiration in the diagnosis and risk assessment of cystic lesions of the pancreas. *Clinical and Translational Science* 2012;5:102–17.
- [168] Al-Haddad M, Gill KR, Raimondo M, et al. Safety and efficacy of cytology brushings versus standard fine-needle aspiration in evaluating cystic pancreatic lesions: a controlled study. *Endoscopy* 2010;42:127–32.
- [169] Thomas T, Bebb J, Mannath J, et al. EUS-guided pancreatic cyst brushing: a comparative study in a tertiary referral centre. *Journal of the Pancreas* 2010;11:163–9.
- [170] Lozano MD, Subtil JC, Miravalles TL, et al. EchoBrush may be superior to standard EUS-guided FNA in the evaluation of cystic lesions of the pancreas: preliminary experience. *Cancer Cytopathology* 2011;119:209–14.
- [171] Sendino O, Fernández-Esparrach G, Solé M, et al. Endoscopic ultrasonography-guided brushing increases cellular diagnosis of pancreatic cysts: a prospective study. *Digestive and Liver Disease* 2010;42:877–81.
- [172] Bruno M, Bosco M, Carucci P, et al. Preliminary experience with a new cytology brush in EUS-guided FNA. *Gastrointestinal Endoscopy* 2009;70:1220–4.
- [173] Levy MJ, Smyrk TC, Reddy RP, et al. Endoscopic ultrasound-guided trucut biopsy of the cyst wall for diagnosing cystic pancreatic tumors. *Clinical Gastroenterology and Hepatology* 2005;3:974–9.
- [174] Konda VJ, Aslanian HR, Wallace MB, et al. First assessment of needle-based confocal laser endomicroscopy during EUS-FNA procedures of the pancreas. *Gastrointestinal Endoscopy* 2011;74:1049–60.
- [175] Aparicio JR, Martínez J, Niveiro M, et al. Direct intracystic biopsy and pancreatic cystoscopy through a 19-gauge needle EUS. *Gastrointestinal Endoscopy* 2010;72:1285–8.
- [176] Fernández-Esparrach G, Ginès A, García P, et al. Incidence and clinical significance of hyperamylasemia after endoscopic ultrasound-guided fine-needle aspiration (EUS-FNA) of pancreatic lesions: a prospective and controlled study. *Endoscopy* 2007;39:720–4.
- [177] Carrara S, Arcidiacono PG, Mezzi G, et al. Pancreatic endoscopic ultrasound-guided fine needle aspiration: complication rate and clinical course in a single centre. *Digestive and Liver Disease* 2010;42:520–3.
- [178] de Jong K, Poley JW, van Hooft JE, et al. Endoscopic ultrasound-guided fine-needle aspiration of pancreatic cystic lesions provides inadequate material for cytology and laboratory analysis: initial results from a prospective study. *Endoscopy* 2011;43:585–90.
- [179] Wiersema MJ, Vilmann P, Giovannini M, et al. Endosonography-guided fine-needle aspiration biopsy: diagnostic accuracy and complication assessment. *Gastroenterology* 1997;112:1087–95.
- [180] Al-Haddad M, Wallace MB, Woodward TA, et al. The safety of fine-needle aspiration guided by endoscopic ultrasound: a prospective study. *Endoscopy* 2008;40:204–8.
- [181] Levy MJ, Norton ID, Wiersema MJ, et al. Prospective risk assessment of bacteremia and other infectious complications in patients undergoing EUS-guided FNA. *Gastrointestinal Endoscopy* 2003;57:672–8.
- [182] O'Toole D, Palazzo L, Arotçarena R, et al. Assessment of complications of EUS-guided fine-needle aspiration. *Gastrointestinal Endoscopy* 2001;53:470–4.
- [183] Siddiqui UD, Rossi F, Rosenthal LS, et al. EUS-guided FNA of solid pancreatic masses: a prospective, randomized trial comparing 22-gauge and 25-gauge needles. *Gastrointestinal Endoscopy* 2009;70:1093–7.
- [184] De Jong K, Bruno M, Fockens P. Epidemiology, diagnosis, and management of cystic lesions of the pancreas. *Gastroenterology Research and Practice* 2012:147465.
- [185] LeBlanc JK, Ciaccia D, Al-Assi MT, et al. Optimal number of EUS-guided fine needle passes needed to obtain a correct diagnosis. *Gastrointestinal Endoscopy* 2004;59:475–81.
- [186] Turner BG, Cizginer S, Agarwal D, et al. Diagnosis of pancreatic neoplasia with EUS and FNA: a report of accuracy. *Gastrointestinal Endoscopy* 2010;71:91–8.
- [187] Attasaranya S, Pais S, LeBlanc J. Endoscopic ultrasound-guided fine needle aspiration and cyst fluid analysis for pancreatic cysts. *Journal of the Pancreas* 2007;8:553–63.
- [188] Lai R, Stanley MW, Bardales R, et al. Endoscopic ultrasound-guided pancreatic duct aspiration: diagnostic yield and safety. *Endoscopy* 2002;34:715–20.
- [189] Vignesh S, Brugge WR. Endoscopic diagnosis and treatment of pancreatic cysts. *Journal of Clinical Gastroenterology* 2008;42:493–506.
- [190] Maeshiro K, Nakayama Y, Yasunami Y, et al. Diagnosis of mucin-producing tumor of the pancreas by balloon-catheter endoscopic retrograde pancreatography – compression study. *Hepatogastroenterology* 1998;45:1986–95.
- [191] Hara T, Yamaguchi T, Ishihara T, et al. Diagnosis and patient management of intraductal papillary-mucinous tumor of the pancreas by using peroral pancreatoscopy and intraductal ultrasonography. *Gastroenterology* 2002;122:34–43.
- [192] Maire F, Couvelard A, Hammel P, et al. Intraductal papillary mucinous tumors of the pancreas: the preoperative value of cytologic and histopathologic diagnosis. *Gastrointestinal Endoscopy* 2003;58:701–6.
- [193] Telford JJ, Carr-Locke DL. The role of ERCP and pancreatoscopy in cystic and intraductal tumors. *Gastrointestinal Endoscopy Clinics of North America* 2002;12:747–57.

- [194] Azar C, Van de Stadt J, Rickaert F, et al. Intraductal papillary mucinous tumours of the pancreas. Clinical and therapeutic issues in 32 patients. *Gut* 1996;39:457–64.
- [195] Kitagawa Y, Unger TA, Taylor S, et al. Mucis is a predictor of better prognosis and survival in patients with intraductal papillary mucinous tumor of the pancreas. *Journal of Gastrointestinal Surgery* 2003;7:12–8.
- [196] Yamao K, Nakamura T, Suzuki T, et al. Endoscopic diagnosis and staging of mucinous cystic neoplasms and intraductal papillary-mucinous tumors. *Journal of Hepato-Biliary-Pancreatic Surgery* 2003;10:142–6.
- [197] Rajman I, Kortan P, Walden D, et al. Mucinous ductal ectasia: cholangiopancreatographic and endoscopic findings. *Endoscopy* 1994;26:303–7.
- [198] Fernández-del Castillo C, Warshaw AL. Cystic tumors of the pancreas. *The Surgical Clinics of North America* 1995;75:1001–16.
- [199] Yamaguchi T, Hara T, Tsuyuguchi T, et al. Peroral pancreatoscopy in the diagnosis of mucin-producing tumors of the pancreas. *Gastrointestinal Endoscopy* 2000;52:67–73.
- [200] Kaneko T, Nakao A, Nomoto S, et al. Intraoperative pancreatoscopy with the ultrathin pancreatoscope for mucin-producing tumors of the pancreas. *Archives of Surgery* 1998;133:263–7.
- [201] Patel A, Lambiase L, Decarli A, Fazel A. Management of the mucin filled bile duct. A complication of intraductal papillary mucinous tumor of the pancreas. *Journal of the Pancreas* 2005;6:255–9.
- [202] Kobayashi G, Fujita N, Noda Y, et al. Lateral spread along the main pancreatic duct in branch-duct intraductal papillary mucinous neoplasms of the pancreas: usefulness of intraductal ultrasonography for its evaluation. *Digestive Endoscopy* 2011;23:62–8.
- [203] Testini M, Gurrado A, Lissidini G, et al. Management of mucinous cystic neoplasms of the pancreas. *World Journal of Gastroenterology* 2010;16:5682–92.
- [204] Brugge WR, Lauwers GY, Sahani D, et al. Cystic neoplasms of the pancreas. *The New England Journal of Medicine* 2004;351:1218–26.
- [205] Park WGU, Mascarenhas R, Palaez-Luna M, et al. Diagnostic performance of cyst fluid carcinoembryonic antigen and amylase in histologically confirmed pancreatic cysts. *Pancreas* 2011;40:42–5.
- [206] Brugge W, Lewandrowski K, Lee-Lewandrowski E, et al. Diagnosis of pancreatic cystic neoplasms: a report of the cooperative pancreatic cyst study. *Gastroenterology* 2004;126:1330–6.
- [207] Burtis CA, Edward R, editors. Tietz textbook of clinical chemistry. 3rd ed. Ashwood: WB Saunders Co.; 1999. p. 689–704.
- [208] Khalid A, McGrath KM, Zahid M, et al. The role of pancreatic cyst fluid molecular analysis in predicting cyst pathology. *Clinical Gastroenterology and Hepatology* 2005;3:967–73.
- [209] Sawhney MS, Devarajan S, O'Farrel P, et al. Comparison of carcinoembryonic antigen and molecular analysis in pancreatic cyst fluid. *Gastrointestinal Endoscopy* 2009;69:1106–10.
- [210] Ezzellea J, Rodriguez-Chavez IR, Dardenb JM, et al. Guidelines on good clinical laboratory practice: bridging operations between research and clinical research laboratories. *Journal of Pharmaceutical and Biomedical Analysis* 2008;46:18–29.
- [211] Wood WG. "Matrix effects" in immunoassays. *Scandinavian Journal of Clinical and Laboratory Investigation: Supplementum* 1991;205:105–12.
- [212] Yusuf TE, Ho S, Pavey DA, Michael H, Gress FG. Retrospective analysis of the utility of endoscopic ultrasound-guided fine-needle aspiration (EUS-FNA) in pancreatic masses, using a 22-gauge or a 25 gauge needle system: a multi-center experience. *Endoscopy* 2009;41:445–8.
- [213] Nasuti JF, Gupta PK, Baloch ZW. Diagnostic value and cost-effectiveness of on site evaluation of fine needle aspiration specimens: review of 5688 cases. *Diagnostic Cytopathology* 2002;27:1–4.
- [214] Eloubeidi MA, Tamhane A, Jhala N, et al. Agreement between rapid on-site and final cytological interpretation of EUS-guided FNA specimens: implications for the endosonographer and patient management. *The American Journal of Gastroenterology* 2006;101:2841–7.
- [215] Pellisé Urquiza M, Fernández-Esparrach G, Solé M, et al. Endoscopic ultrasound-guided fine needle aspiration: predictive factors of accurate diagnosis and cost-minimization analysis of on-site pathologist. *Gastroenterología y Hepatología* 2007;30:319–24.
- [216] Jhala NC, Jhala DN, Chhieng DC, et al. Endoscopic ultrasound-guided fine-needle aspiration. A cytopathologist's perspective. *American Journal of Clinical Pathology* 2003;120:351–67.
- [217] Olson MT, Ali SZ. Cytotechnologist on-site evaluation of pancreas fine needle aspiration adequacy: comparison with cytopathologists and correlation with the final interpretation. *Acta Cytologica* 2012;56:340–6.
- [218] Brugge RW. Pancreatic fine needle aspiration: to do or not to do? *Journal of the Pancreas* 2004;5:282–8.
- [219] Pitman MB, Genevay M, Yaeger K, et al. High-grade atypical epithelial cells in pancreatic mucinous cysts are a more accurate predictor of malignancy than "positive" cytology. *Cancer Cytopathology* 2010;118:434–40.
- [220] DeWitt JM. EUS-FNA of cystic pancreatic tumor. *Techniques in Gastrointestinal Endoscopy* 2005;7:181–7.
- [221] Jacobson BC, Baron TH, Adler DG, et al., American Society for Gastrointestinal Endoscopy. ASGE guideline: the role of endoscopy in the diagnosis and the management of cystic lesions and inflammatory fluid collections of the pancreas. *Gastrointestinal Endoscopy* 2005;61:363–70.
- [222] Bellizzi AM, Stelow EB. Pancreatic cytopathology: a practical approach and review. *Archives of Pathology & Laboratory Medicine* 2009;133:388–404.
- [223] Maker AV, Katabi N, Qin LX, et al. Cyst fluid interleukin-1beta (IL1beta) levels predict the risk of carcinoma in intraductal papillary mucinous neoplasms of the pancreas. *Clinical Cancer Research* 2011;17:1502–8.
- [224] Ke E, Patel BB, Liu T, et al. Proteomic analyses of pancreatic cyst fluids. *Pancreas* 2009;38:e33–42.
- [225] Habbe N, Koorstra JB, Mendell JT, et al. MicroRNA miR-155 is a biomarker of early pancreatic neoplasia. *Cancer Biology & Therapy* 2009;8:340–6.
- [226] Wu J, Jiao Y, Dal Molin M, et al. Whole-exome sequencing of neoplastic cysts of the pancreas reveals recurrent mutations in components of ubiquitin-dependent pathways. *Proceedings of the National Academy of Sciences of the United States of America* 2011;108:21188–93.