

R. Lione*, M. Buongiorno**, G. Laganà*,
P. Cozza***, L. Franchi****

*Research Fellow, Department of Clinical Sciences and Translational Medicine, University of Rome "Tor Vergata", Rome, Italy

**Research Fellow, Department of Surgery and Translational Medicine, University of Florence, Italy

***Professor and Department Chair,

Department of Clinical Sciences and Translational Medicine, University of Rome "Tor Vergata", Rome, Italy

****Assistant Professor, Department of Surgery and Translational Medicine, University of Florence, Florence, Italy

e-mail: lorenzo.franchi@unifi.it

Early treatment of Class III malocclusion with RME and facial mask: evaluation of dentoalveolar effects on digital dental casts

ABSTRACT

Aim To analyse the dental effects on digital dental casts in subjects with Class III malocclusion treated with bonded Rapid Maxillary Expansion and Facial Mask (RME/FM).

Materials and methods A study group sample (SG) of 29 subjects (13 females and 16 males) and mean age of 7.4 years (SD 1.2 years) was selected. A bonded RME was placed and activated 1/4 of a turn per day until overcorrection of the transverse width. At the end of expansion, patients were given FMs and treated at least to a positive overjet. The SG was compared with a control group (CG) of 21 prepubertal subjects (9 females; 12 males) presenting with normal occlusion and mean age of 7.9 years (SD 1.6 years). For each subject of the SG and CG initial (pretreatment, T1) and final (post-treatment, T2) digital dental casts were available. Significant in between-group differences were tested with the Student's t-test.

Results The transverse dimension of the upper arch was significantly greater in SG vs. CG (IMAW: +2.6 mm; ICAW: +3.1 mm). Anterior arch length and arch depth

were significantly smaller in SG when compared with CG (AAL: -3.2 mm, AD: -3.4 mm) at the end of therapy.

Conclusion The orthopaedic treatment with bonded RME/FM produced in subjects treated in the deciduous or early mixed dentition a significant expansion of the maxillary arch and mesialisation of the posterior teeth with a reduction of the arch depth.

Keywords Class III malocclusion; Dental effects; Digital dental casts; Early treatment.

Introduction

Early treatment of Class III malocclusion has been advocated to maximise the skeletal effects reducing the need of treatment in the permanent dentition, when orthodontic camouflage or surgery are the only options [Proffit et al., 2013]. For Class III malocclusion several treatment approaches can be found in the literature, such as rapid maxillary expansion and facial mask (RME/FM) [McNamara and Brudon, 2001]. Many studies focused on the skeletal changes induced by this therapy describing the favorable short- and long-term effects, such as the significant and stable improvement in the sagittal position of the mandible [Baccetti et al., 2000; Pavoni et al., 2009; Masucci et al., 2011]. Almost all of these studies analysed also the dentoalveolar modifications pointing out changes in overjet, overbite, and molar relationships. These dental variables have been investigated with the primary objective of describing the improvement in the maxillo-mandibular occlusal relationships at the end of the orthopaedic treatment [Ngan et al., 1996; Cozza et al., 2010].

There are few studies in the literature that focused on the mesialisation of the maxillary dentition related to the type of anchorage at the end of FM therapy in the early mixed dentition [Ngan et al., 1996; Cevitanes et al., 2010]. Moreover, the method of analysis used in these investigations was based exclusively on the cephalometric analysis. To our knowledge, no data are available with regard to the dentoalveolar modifications evaluated on maxillary dental casts at the end of RME/FM therapy [Ngan et al., 1996; Cevitanes et al., 2010].

The aim of the present study was to analyse the dentoalveolar changes, and in particular the loss of anchorage, on 3D digital dental casts in a group of subjects with Class III malocclusion treated with bonded RME and FM when compared with a control group of subjects with normal occlusion.

Patients and methods

A sample of 29 subjects (13 females and 16 males)

with a mean age of 7.4 years (SD 1.2 years) who sought orthodontic treatment at the Department of Orthodontics at the University of Rome "Tor Vergata" was selected. The inclusion criteria for the subjects of the study group (SG) were the following: European ancestry (white), anterior crossbite or edge-to-edge incisor relationship, Class III molar relationship, Wits appraisal of minus 2.0 mm or less, absence of CO-CR discrepancy (indicating pseudo-Class III malocclusion), prepubertal skeletal maturation (CS1 - CS2) [Baccetti et al., 2005], deciduous or early mixed dentition. Exclusion criteria were: late mixed dentition, previous orthodontic treatment, cleft lip and/or palate, and other genetic diseases. This project was approved by the Ethical Committee of the University of Rome "Tor Vergata" (Protocol number: 9314) and informed consent was obtained from the patients' parents. Treatment was initiated with the placement of a bonded RME anchored on deciduous molars and canines to which vestibular hooks were attached. Patients' parents were instructed to activate the palatal expander 1/4 of a turn per day until overcorrection of the transverse width was achieved (palatal cusps of the upper posterior teeth approximating the buccal cusps of the lower posterior teeth). At the end of active expansion, patients were given FMs with pads fitted to the chin and forehead for support. Elastics were attached from the soldered hooks on the expander to the support bar of the facemask in a downward and forward direction, producing orthopaedic force levels of 400-500 grams per side. Patients were asked to wear the FM for 14 hours per day. All patients were treated at least to a positive overjet before discontinuing treatment. Most patients were overcorrected toward Class II occlusal relationships. The average duration of RME/FM treatment was 1.1 years \pm 5 months.

The study group was compared with a control group (CG) of 21 prepubertal subjects (9 females and 12 males) presenting with normal occlusion and mean age of 7.9 years (SD 1.6 years). The CG matched the SG as to age, gender, stage of the dentition, skeletal maturation, and observation interval (Table 1).

For each subject of the study and control groups initial (pretreatment, T1) and final (post-treatment, T2) dental casts were taken. In order to analyse the maxillary dentoalveolar structures, the maxillary dental casts were scanned with a tridimensional scanner (D800, 3Shape A/S, Copenhagen K Denmark, Scan time 25 sec, Resolution 2 cameras 5.0 megapixels, Ultra high point accuracy <15 microns). Each cast was scanned from 10 or more views that were then combined and rendered into three-dimensions by using a specific software (3Shape-ScanItOrthodontics™ 2010 -2p3, 3Shape A/S, Copenhagen K, Denmark). The virtual three-dimensional models were measured with a specific software (3Shape-OrthoAnalyzer™ 2010, 3Shape A/S, Copenhagen K, Denmark). To analyse the transverse and the sagittal dimensions of the maxillary arch, a midpoint (MP) was identified on each digital cast as the tip of the incisive papilla [Nalcaci et al., 2010]. Subsequently, linear

Variables	Study Group (n=29, 13f, 16m)		Controls (n=21, 9f, 12m)	
	Mean	SD	Mean	SD
Age T1, y	7.4	1.2	7.9	1.6
Age T2, y	8.5	1.1	8.8	1.4

f=females; m=males; y=years

TABLE 1 Demographics of the treated and untreated groups.




FIG. 1 Horizontal plane passing through the cusp tips of right and left deciduous canines and the mesio-palatal cusp tips of right and left second deciduous molars.

measurements were performed at the level of a horizontal plane passing through the cusp tips of right and left deciduous canines and the mesio-palatal cusp tips of right and left second deciduous molars. The tip of the incisive papilla was projected on the horizontal plane (MP') (Fig. 1).

Transversal measurements (Fig. 2)

1. Intermolar Arch Width (IMAW): distance between the center of the distal marginal crests of right and left second deciduous molars.
2. Inter canine Arch Width (ICAW): distance between the cusp tips of right and left deciduous canines.

Sagittal measurements (Fig. 2)

1. Anterior Arch Length (AAL): the sum of the anterior right arch length (distance between MP' and the cusp of right deciduous canine) and the anterior left arch length (distance between MP' and the cusp of left deciduous canine).
3. Arch Depth (AD): distance from MP' to a line between the centers of the distal marginal crests of right and left second deciduous molars.

Statistical analysis

To determine the method error, measurements on the digital models were performed by one trained examiner (M.B.) and repeated after an interval of approximately two weeks. A paired t-test was used to compare the two measurements (systematic error). The magnitude of the random error was calculated by using the method of moments' estimator [Springate, 2012].

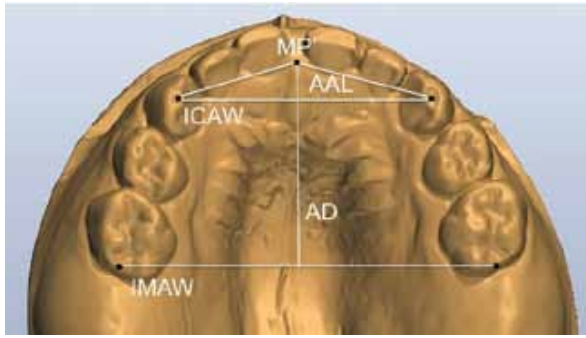


FIG. 2 Linear measurements in a treated subject at T1. Intermolar Arch Width (IMAW): distance between the center of the distal marginal crests of right and left second deciduous molars; Intercanine Arch Width (ICAW): distance between the cusp tips of right and left deciduous canine; Anterior Arch Length (AAL): the sum of the anterior right arch length (distance between MP' and the cusp of right deciduous canine) and the anterior left arch length (distance between MP' and the cusp of left deciduous canine); Arch Depth (AD): distance from MP' to a line between the centers of the distal marginal crests of right and left second deciduous molars.

Descriptive statistics were calculated for all the measurements in each group. Exploratory statistics revealed that all variables were normally distributed (Kolmogorov-Smirnov test) with equality of variances (Levene's test). Significant between-group differences were tested with the Student's t-test. The power of the study for the independent sample t test was calculated on the basis of the sample size of the 2 groups and an effect size [Cohen, 1992] equal to 0.9 for the variable arch depth. The power was 0.868 at an α level of 0.05. All statistical computations were performed by using a specific software (SigmaStat 3.5, Systat software, Point Richmond, CA).

Results

No systematic error was found between the repeated measurements. The p value for the paired t test ranged from 0.556 (ICAW) to 0.940 (AAL). The mean random error ranged from 0.02 mm (AAL) to 0.09 mm (ICAW).

Descriptive statistics for all variables at T1 for the SG and CG ("starting forms") are given in Table 2. The analysis of the starting forms did not show any significant between-group difference for any of the variables in SG when compared with CG. Descriptive statistics and statistical comparisons on the changes in the values of the variables in SG vs. CG during the T1-T2 observation period are given in Table 3. The SG showed significantly greater increments in both ICAW and IMAW when compared to the CG (+3.1 and +2.6 mm, respectively). The SG exhibited significantly greater decreases in AAL when compared with CG (-3.2 mm). Also the AD showed significantly greater decreases in the SG with respect to the CG (-3.4 mm).

Discussion

The aim of the present study was to analyze the loss of anchorage after treatment with bonded RME/FM by using digital dental casts. In the literature most studies [Takada et al., 1993; Kapust et al., 1998] that investigated the dental changes at the end of therapy with RME/FM by using cephalometric appraisal have limitations. Bilateral structures, as teeth in particular, cannot be evaluated individually and are susceptible to measurement errors if the patient's head is slightly rotated during film capture [Nguyen et al., 2011]. The 3D images of study casts can be used to assess linear and angular measurements to describe dentoalveolar

Measurements	Treated Group (n=29)		Control group (n=21)		Diff.	Statistical comparisons P values
	Mean	SD	Mean	SD		
IMAW (Intermolar Arch Width)	40.4	2.8	41.3	2.4	-0.9	0.130
ICAW (Intercanine Arch Width)	28.6	3.5	30.1	2.6	-1.5	0.092
AAL (Anterior Arch Length)	30.3	3.2	31.5	2.5	-1.2	0.154
AD (Arch Depth)	21.5	1.0	21.9	1.0	-0.4	0.237
SD=Standard Deviations; Diff.=Differences						

TABLE 2 Descriptive statistics and statistical comparisons at T1 (starting forms).

Measurements	Treated Group (n=29)		Control group (n=21)		Diff.	Statistical comparisons P values
	Mean	SD	Mean	SD		
IMAW (Intermolar Arch Width)	4.0	2.4	1.4	1.5	2.6	0.000
ICAW (Intercanine Arch Width)	4.3	2.4	1.2	0.7	3.1	0.000
AAL (Anterior Arch Length)	-1.6	1.2	1.6	0.8	-3.2	0.000
AD (Arch Depth)	-2.0	1.1	1.4	0.6	-3.4	0.000
SD=Standard Deviations; Diff.=Differences						

TABLE 3 Descriptive statistics and statistical comparisons of the T2-T1 changes. All measurements are in millimeters.

modifications [Sjögren et al., 2010; Primozic et al., 2013].

RME prior to maxillary protraction has been used by several authors in patients with Class III malocclusion to correct posterior crossbites and to disrupt the maxillary sutural system thus enhancing the orthopedic effect of FM [Ngan et al., 1996; Williams et al., 1997; Baccetti et al., 2000; Westwood et al., 2003]. In the present study the bonded palatal expander with occlusal splints was applied with the primary objective of facilitating the forward movement of the maxillary arch and of controlling the posterior mandibular rotation as unfavourable treatment outcome associated with maxillary protraction [Pavoni et al., 2009].

In the current investigation the SG showed significantly greater increases in the transverse dimension of the upper arch when compared with the CG and it was due to the RME phase of the treatment protocol (ICAW + 3.1 mm and IMAW + 2.6 mm). With reference to sagittal measurements, significant differences were found between the two groups showing a mesialisation of the maxillary posterior teeth with a reduction of anterior arch length (AAL = -3.2 mm) and arch depth (AD = -3.4 mm) in SG when compared with CG. The slight difference between the 2 measurements (AAL and AD) in the assessment of the mesialisation of the posterior teeth, is probably due to the fact that AAL measures the space loss in the anterior arch perimeter while AD measures a sagittal change in arch depth. In the literature the typical dental compensations associated with maxillary protraction, include maxillary incisor proclination, maxillary molar forward movement, and decreased inclination of the lower incisors [Kim et al., 1999]. Baik [1995] showed that after RME/FM therapy both upper molars and incisors moved forward by 2.2 mm and 2.1 mm, respectively. Ngan et al. [1996] using the same treatment protocol, pointed out a loss in anchorage despite the use of a fixed maxillary appliance. Forward movement of maxillary incisors and lingual tipping of mandibular incisors helped in correcting the overjet and contributed to 30% of the overjet changes. The maxillary molar came forward by an average of 1.6 mm [Ngan et al., 1996]. Also Kapust et al. [1998] observed in patients treated with the RME/FM protocol, a mean maxillary molar mesialisation of 2.4 mm while the upper incisor showed a forward movement of 1.8 mm. In particular, comparing maxillary orthopedic change to maxillary molar movement, the overall ratio approached 2:1 in the early treated group [Kapust et al., 1998]. It should be noted, however, that none of these studies compared the effects of RME/FM in the treated sample with respect to a control sample of untreated subjects. In the present study it was decided to measure the anterior arch length and the arch depth to assess the amount of loss of anchorage of the posterior teeth. The mesialisation of deciduous canines and molars determined a loss of space in the anterior region of the maxillary arch in SG when compared with CG. Since conventional treatment of Class III malocclusion involves the use of a protraction FM

with fixed anchorage as RME to advance the maxilla, new therapeutical methods using either skeletal anchorage [Cevitanes et al., 2010] or mixed skeletal and dental anchorage [Wilmes et al., 2014] should be considered to minimise the dentoalveolar compensations.

Conclusion

Orthopaedic treatment with bonded RME and FM determined in subjects treated in deciduous or early mixed dentition a significant expansion of the maxillary arch associated with a significant mesialisation of the posterior teeth and decrease in arch depth.

References

- › Baccetti T, Franchi L, McNamara JA. The cervical vertebral maturation (CMV) method for the assessment of optimal treatment timing in dentofacial orthopedics. *Semin Orthod* 2005;11:119-129.
- › Baccetti T, Franchi L, McNamara JA Jr. Treatment and post-treatment craniofacial changes after rapid maxillary expansion and facemask therapy. *Am J Orthod Dentofacial Orthop* 2000;118:404-413.
- › Baik HS. Clinical results of the maxillary protraction in Korean children. *Am J Orthod Dentofacial Orthop* 1995;108:583-592.
- › Cevitanes L, Baccetti T, Franchi L, McNamara JA Jr, De Clerck H. Comparison of two protocols for maxillary protraction: bone anchors versus face mask with rapid maxillary expansion. *Angle Orthod* 2010;80:799-706.
- › Cohen J. A power primer. *Psychol Bull* 1992;112:155-159.
- › Cozza P, Baccetti T, Mucedero M, Pavoni C, Franchi L. Treatment and post-treatment effects of a facial mask combined with a bite-block appliance in Class III malocclusion. *Am J Orthod Dentofacial Orthop* 2010;138:300-310.
- › Kapsut AJ, Sinclair PM, Turley PK. Cephalometric effects of face mask/expansion therapy in Class III children: a comparison of three age groups. *Am J Orthod Dentofacial Orthop* 1998;113:204-212.
- › Kim JH, Viana MA, Graber TM, Omerza FF, BeGole EA. The effectiveness of protraction face mask therapy: a meta-analysis. *Am J Orthod Dentofacial Orthop* 1999;115:675-685.
- › Masucci C, Franchi L, Defraia E, Mucedero M, Cozza P, Baccetti T. Stability of rapid maxillary expansion and facemask therapy: a long-term controlled study. *Am J Orthod Dentofacial Orthop* 2011;140:493-500.
- › McNamara JA Jr, Brudon WL. *Orthodontics and Dentofacial Orthopedics*, Needham Press, Ann Arbor, Michigan, 2001, pp. 1-3111.
- › Nalcaci R, Bicakci AA, Ozan F. Noncompliance screw supported maxillary molar distalization in a parallel manner. *Korean J Orthod* 2010;40:250-259.
- › Ngan P, Hägg U, Yiu C, Wei SH. Treatment response to maxillary expansion and protraction. *Eur J Orthod* 1996;18:151-168.
- › Nguyen T, Cevitanes L, Cornelis MA, Heymann G, de Paula LK, De Clerck H. Three-dimensional assessment of maxillary changes associated with bone anchored maxillary protraction. *Am J Orthod Dentofacial Orthop* 2011;140:790-798.
- › Pavoni C, Mucedero M, Baccetti T, Franchi L, Polimeni A, Cozza P. The effects of facial mask/bite block therapy with or without rapid palatal expansion. *Prog Orthod* 10:20-28.
- › Primozic J, Richmond S, Kau CH, Zhurov A, Ovsenik M. Three dimensional evaluation of early crossbite correction: a longitudinal study. *Eur J Orthod* 2013;35:7-13.
- › Proffit WR, Fields HW, Sarver DM, Ackerman JL. *Contemporary Orthodontics*. 5th edition, Elsevier Mosby, St. Louis, Missouri, 2013, pp. 480-487.
- › Sjögren AP, Lindgren JE, Huggare JA. Orthodontic study cast analysis-reproducibility of recordings and agreement between conventional and 3D virtual measurements. *J Digit Imaging* 2010;23:482-492.
- › Springate SD. The effect of sample size and bias on the reliability of estimates of error: a comparative study of Dahlberg's formula. *Eur J Orthod* 2012;34:158-163.
- › Takada K, Petdachai S, Sakuda M. Changes in dentofacial morphology in skeletal Class III children treated by a modified maxillary protraction headgear and a chin cup: a longitudinal cephalometric appraisal. *Eur J Orthod* 1993;15:211-221.
- › Westwood PV, McNamara JA Jr, Baccetti T, Franchi L, Sarver DM. Long-term effects of Class III treatment with rapid maxillary expansion and facemask therapy followed by fixed appliances. *Am J Orthod Dentofacial Orthop* 2003;123:306-320.
- › Williams MD, Sarver DM, Sadowsky PL, Sadowsky PL, Bradley E. Combined rapid maxillary expansion and protraction facemask in the treatment of Class III malocclusion in growing children: a prospective long-term study. *Semin Orthod* 1997;3:265-274.
- › Wilmes B, Ngan P, Liou EJ, Franchi L, Drescher D. Early class III facemask treatment with the hybrid hyrax and Alt-RAMEC protocol. *J Clin Orthod* 2014;48:84-93.