

An unusual complication after endovascular aneurysm repair for giant abdominal aortic aneurysm with aortocaval fistula: High bilirubin levels

Andrea Ascoli Marchetti^{ID}, Fabio Massimo Oddi^{ID},
Nicolò Diotallevi, Martina Battistini and Arnaldo Ippoliti

SAGE Open Medical Case Reports
Volume 8: 1–6
© The Author(s) 2020
Article reuse guidelines:
sagepub.com/journals-permissions
DOI: 10.1177/2050313X20984322
journals.sagepub.com/home/sco



Abstract

Abdominal aortic aneurysm has among its rare complications the aortocaval fistula. It is observed in less than 1% of all abdominal aortic aneurysms and represents 3%–7% of clinical presentation in case of rupture. A male patient was presented to the emergency department with pulsating mass with continuous vascular systo-diastolic bruit, located in the lower part of abdomen with the back pain radiating anteriorly in lower abdomen. After diagnosis of abdominal aortic aneurysm with aortocaval fistula, a trimodular Endurant endograft was placed. Migration of the endoprosthesis was treated with Endoanchor and endovascular aneurysm sealing device. In the postoperative course, the patient had jaundice due to high bilirubin levels, cholestasis and increased hepatocyte cytolysis: aspartate aminotransferase and alanine aminotransferase. The treatment with appropriate continuous filtration rapidly reduced bilirubin values and the patient gradually improved.

Keywords

Cardiovascular, Critical care/ emergency medicine, aortocava fistula, endovascular aneurysm repair, abdominal aortic aneurysm, jaundice, bilirubin, endovascular complication

Date received: 2 September 2020; accepted: 3 December 2020

Introduction

Abdominal aortic aneurysm (AAA) has among its rare complications the aortocaval fistula (ACF). It is observed in less than 1% of all AAAs and represents 3%–7% of clinical presentation in case of rupture.^{1,2} Some authors reported an early mortality, more than 67%, and a low frequency of correct preoperative diagnosis from 0% to 50%.^{2,3} Open surgery remains a possible option for relatively fit patients with American Society of Anesthesiologists (ASA) score I and II; in the emergency setting, endovascular treatment may represent an adequate, validated and viable option in alternative to conventional surgery especially in high-risk patient.^{4–6} However, a high incidence and persistence of endoleak with the endovascular AAA has among its rare complications the ACF. It is observed in less than 1% of all AAAs and represents 3%–7% of clinical presentation in case of rupture endovascular technique remains a significant problem with frequent complications as renal insufficiency or cardiac comorbidities, cerebral ischemia and pulmonary events.⁶

In this report, we describe a management of a case of ACF complications with giant ruptured AAA (rAAA). The postoperative period was characterized by jaundice with progressive increase in bilirubin.

Case report

A male patient aged 77 years was admitted to the emergency department with acute lower abdominal back pain radiating anteriorly and abdominal mass with continuous systo-diastolic vascular bruit at the lower abdomen. The patient's medical history revealed hypertension, dyslipidemia treated with Ramipril 5 mg and atorvastatina 40 mg, obesity (body mass

Vascular Surgery Unit, Department of Biomedicine and Prevention, University of Rome Tor Vergata, Rome, Italy

Corresponding Author:

Andrea Ascoli Marchetti, Vascular Surgery Unit, Department of Biomedicine and Prevention, University of Rome Tor Vergata, Viale Oxford 81, Rome 00133, Italy.
Email: ascolimarchetti@med.uniroma2.it



index (BMI) > 35), chronic obstructive pulmonary disease (COPD) treated by tiotropium bromide and previous three coronary artery bypass grafting 5 years before due to a coronary artery disease (CAD).

A preoperative computed tomographic angiography (CTA) in emergency department demonstrated a 140-mm rAAA, with ACF (Figure 1); the aneurysm had a 17 mm long and 30 mm diameter infrarenal neck.

The patient was frail and, due to the presence of comorbidities and advanced age, he was classified as ASA III and considered unfit for open surgery repair, due to a high anesthesiological risk. The most recent echocardiography revealed an ejection fraction (EF) < 40%. The dosage of creatinine was 1.7 mg/dL. For this reason, a detailed endovascular preoperative planning was carried out immediately with a dedicated workstation (Aquarius Intuition ver. 4.4.12, TeraRecon, Inc., San Mateo, CA, USA). The patient signed an informed consensus underwent urgent intervention in angi-suite with a fixed C-Arm (Allura Xper, Philips, Andover, MA, USA) under local anesthesia with mild sedation.

The percutaneous approach to common femoral arteries was performed using perclose technique with Perclose Proglide (Abbott Vascular, Santa Clara, CA, USA); then a 36-mm trimodular Endurant endograft (Medtronic, Santa Rosa, CA, USA) deployed below the more distal renal artery ostium, covering the ruptured aortic segment. Due to the large AAA diameter, a great subsequent remodeling of the aortic parietal pressure was observed, with early migration of the endoprosthesis. For this reason, it was necessary to implant aortic cuff, with 36 mm diameter and an overlapping of 1 cm. However, persistent type III endoleak between graft and aortic extension were confirmed after intra-operative angiography. While landing zones and device overlaps were ballooned again, the endoleak remained, so we finally solved it by implanting another aortic cuff with 36 mm and fixing

it with Aptus HeliFX EndoAnchors (Medtronic Vascular, Santa Rosa, CA, USA). Despite a correct implantation technique, a small endoleak remained in the final angiography.

In second postoperative day, the patient presented a deterioration of clinical state characterized by abdominal pain and jaundice due to high conjugated bilirubin levels (up to 20.86 mg/dL, Figure 2).

Abdominal ultrasound documented the absence of distention/obstruction of the bile ducts and gallbladder, with normal hepatic vein diameter; the complementary contrast-enhanced abdominal aorta ultrasound showed intra-sac flow.

The patient underwent second CTA fourth postoperative day which identified perfusion of the aneurysm sac caused

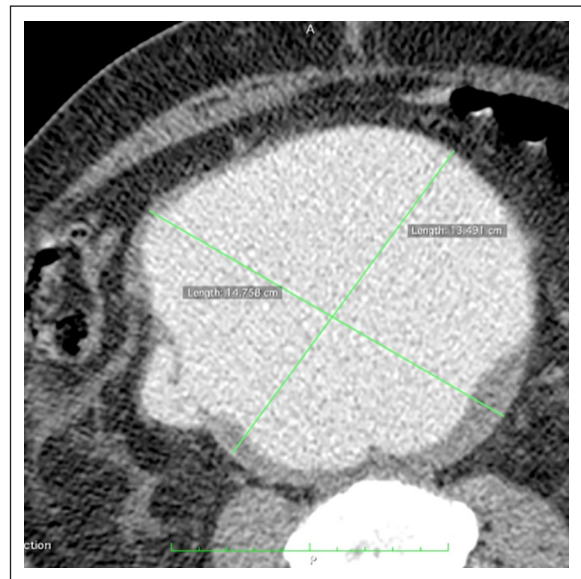


Figure 1. CTA demonstrated a 140-mm rAAA, with aorticocaval fistula.

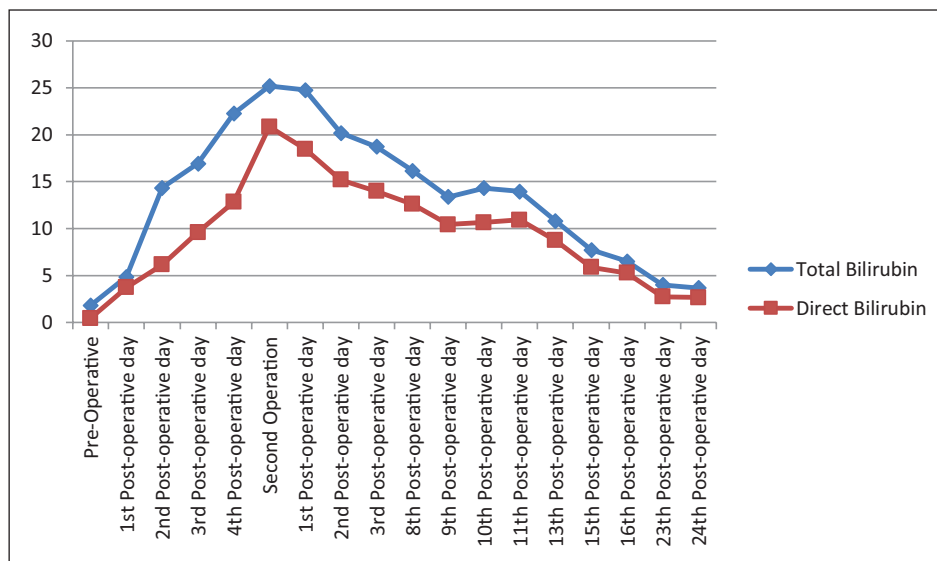


Figure 2. Bilirubin levels during the hospitalization. Note that the parallel levels increase. Hemolysis increased only indirect bilirubin.

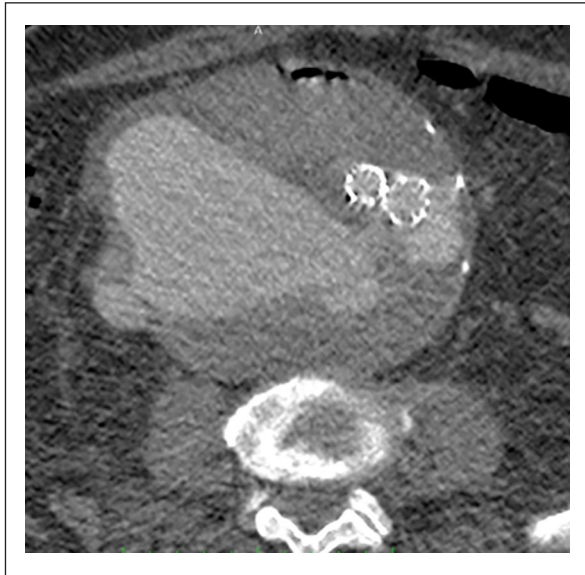


Figure 3. CTA identified perfusion of the aneurysm sac caused by type III endoleak with flow into the inferior cava vein through the aortocaval fistula.

by type III endoleak, between cuff and previous graft, with flow into the inferior vena cava through the ACF (Figure 3).

For these reasons, the patient underwent endovascular treatment again, 5 days after the previous one. We decided to use controlled-release coils to seal the area of leakage. Embolization of the endoleak was accomplished by placing a 5 Fr Bern[®] catheter between the endoprosthesis and the cuff. Then, a microcatheter was inserted through the first catheter and advancing it up to the site requiring embolization, where six Penumbra detachable coils (Penumbra, Inc., Alameda, CA, USA) were released into the sac very close to the graft, being careful not to release them near the fistula, in order to avoid embolism. The postoperative control angiography still showed leakage between the endoprosthesis and the cuff. Subsequently, two Nellix catheter (N-140) (Endologix, Inc., Irvine, CA, USA) were advanced into the previous endograft; deployment of Nellix catheter and the filling with polymer of the bags were performed (Figure 4). Complete angiography showed the complete resolution of the endoleak. Postoperative clinical finding was characterized by jaundice and laboratory investigations revealed high procalcitonin and deranged test values of renal and liver with clinical finding of oliguria. Continuous venovenous hemodiafiltration (CVVH) with a CytoSorb filter (CytoSorbents Corporation, Monmouth Junction, NJ) placed in the predialyzer position was started. The contemporary therapy of CVVH and CytoSorb continued for 4 days and determined a significant decrease in bilirubin levels (Figure 2), with improvement in urine output. He was discharged 40 days after surgery. The follow-up protocol consists of 1 and 12 months CT scan and an eco-duplex every 6 months. The patient is in good general condition after 2 years.

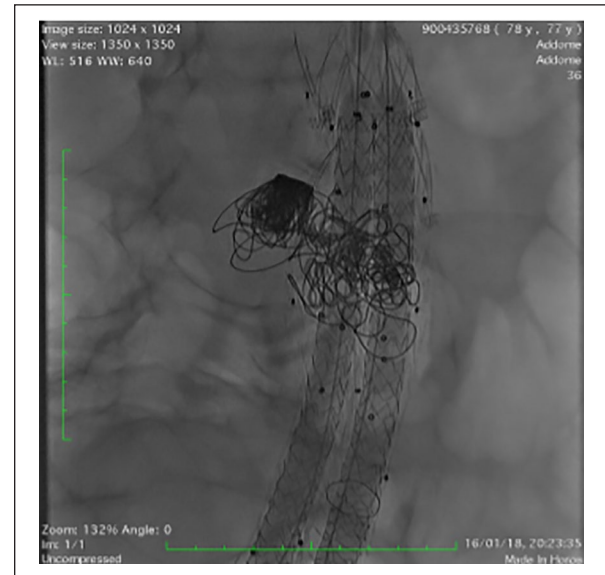


Figure 4. Deployment of Nellix catheter and the filling with polymer of the bags.

Discussion

Syme⁷ described the ACF in 1831 in a 22-year-old man with syphilitic aortitis and aneurysm. Cooley and colleagues⁸ performed the first successful repair of an AAA with ACF in 1958. The open surgery technique for rAAA with ACF consists of rapid suturing of the fistula from within the aneurysmal sac, followed by aortic reconstruction. This technique is associated with high morbidity and mortality. Calligaro et al. reviewed all reported open repairs of ACF up to 1990 and demonstrated a 30-day survival rate of 72%. Even in semi elective cases, the mortality rate is 30%, especially in patients with cardiac failure.⁹

Endovascular repair of an ACF represents a valuable option in alternative to open repair, especially in high-risk patient; it has been a good therapeutic option since 1998,¹⁰ also in Janczak et al.¹¹ and in our previously described experience.¹² However, the only case series relating endovascular treatment of ACF e showed a complicated clinical picture, with a mortality rate of 75%.⁴ Despite the invasiveness, endovascular aneurysm repair (EVAR), also in this particular circumstance, has compliance as hostile neck. Adjunctive maneuvers are required to reach proximal seal compared to the patients with friendly anatomy. In most cases, the procedures included aortic cuff insertion in these patients.⁵

EVAR complications include loss of seal with subsequent endograft migration with endoleak. In this case, endoanchors show the stability of a hand-sewn aortic anastomosis.¹³ Endoanchors reduce early and late endoleaks by affixing the aortic stent grafts firmly to the native aortic wall.¹⁴ Indications for use comprise primary implantation to secure the proximal or distal landing zone, in case of unfavorable anatomy or intra-operative endoleak or suboptimal apposition to the

Table 1. Liver function parameter during the hospitalization.

Days	Total bilirubin (mg/dL)	Direct bilirubin (mg/dL)	AST (U/L)	ALT (U/L)	ALP (Ui/L)	GGT (Ui/L)	Alb (g/dL)
Pre-operation	1.82	0.46	102	125	129	148	3.2
1st post-op day	4.85	3.73	228	117	98	118	2.7
2nd	14.35	6.15	222	82	87	96	2.5
3rd	16.93	9.60	206	81		107	
4th	22.26	12.82	196	91	94	113	2.4
Second operation	25.20	20.86		57		110	
1st	24.78	18.49	110	53	90	105	2.1
2nd	20.19	15.20	67	44	96	94	1.9
3rd	18.72	13.99	55	36	105	86	1.9
4th	16.12	12.81	52	32	102	72	1.6
6th	16.89	13.29	92	43	111	94	1.4
7th	16.39	13.11	86	42	111	99	1.3
8th	16.17	12.62	113	53	136	131	1.7
9th	13.37	10.43	88	45	114	96	1.6
10th	14.32	10.64	87	45	109	98	1.7
11th	13.97	10.92	91	46	157	160	1.7
12th	14.24	11.25	88	51		273	1.7
13th	10.81	8.74	76	50	250	301	1.6
14th			85	50		340	1.6
15th	7.74	5.88	86	56	306	433	2
16th	6.52	5.28	88	65	307	459	2.1
17th	4.70	3.68	66	68		408	
18th			63	72		424	1.9
19th			67	76		354	
20th	4.63	3.31	50	66		245	
21st			43	62		187	1.9
22nd	4.21	3	38	55		148	1.8
23rd	4.02	2.74	47	55		121	2.1
24th	3.68	2.65	55	57		99	2
25th	3.47	2.46	66	70		87	
27th	3.58	2.48	91	99		74	

AST: aspartate aminotransferase; ALT: alanine aminotransferase; ALP: alkaline phosphatase; GGT: gamma-glutamyl transpeptidase.

Note: the AST/ALT levels are significantly increased only at the beginning.

aortic wall, as well as secondary use for the treatment of endoleaks and stent-graft migration often in conjunction with a proximal or distal extension of the stent graft.¹³ In our case, the aim of endoanchors was to fix the second cuff with first implanted graft. Many authors reported cases of use of coils for endoleak types I, II and III with successful embolization.^{15,16}

Regarding the postoperative course after coils implantation, type III endoleak is defined as the presence of leakage between two parts of the stent graft, as in our case. Endovascular relining is the most suitable choice when an open conversion is not indicated, but a real correction of the endoleak is not always possible, because of the lack of dedicated materials.¹⁶ A valuable choice for type III endoleak treatment is relining of the entire stent graft using a new stent graft or endovascular aneurysm sealing (EVAS) procedure. In our experience, the EVAS procedure was considered only as a last endovascular option before the open conversion, as

in Youssef and coll. experience.^{17,18} For this reason, no negligible risk of dislodgment with the use of coils was assumed.

The Nellix device (Endologix, Inc., Irvine, CA, USA) seems to be a balanced choice for this kind of surgical conditions. The endobag conformation prevents the gutter formation by gaining a relining of all primary endograft segments.¹⁸

Bilirubin levels may be elevated due to hematological disorders, impaired liver function and cholestasis. Bilirubin is a fundamental metabolic ultimate product of heme degradation and its increase can be caused by hemolysis.¹⁹ In our case, the increase in bilirubin levels, as shown in Table 1, was probably caused by the degradation of the aneurysmal thrombus that was in communication with the inferior vena cava, but this does not explain the greater increase in the direct bilirubin. Until the hemolysis caused by the communication between the aneurysm sac and the vena cava was stopped, the bilirubin levels increased, demonstrating the

ineffectiveness of the procedures undertaken. Only after the complete interruption of this communication, we did see a decrease in bilirubin, assisted by the use of CytoSorb. Higher levels of the conjugated bilirubin were caused by hepatitis, gallstones or inflammation, but all these causes have been ruled out with blood and instrumental tests. In our opinion, this elevation of bilirubin level may be explained by a multi-factor etiology: inflammation state, high and prolonged hemolysis, and coagulopathy disorder was not identified due to continued turbulence flow; a specific risk factor for this condition was not identified.

Kyuragi et al.²⁰ described a case of an EVAR for AAA and a ruptured common iliac artery aneurysm (rCIAA) in a patient complicated by severe liver deterioration due to obstructive jaundice resulting from hepatocellular carcinoma, but a case similar to ours has never been described in literature.

The scope of adsorption technique in liver care is to take out these albumin-bound materials.

An in vitro analysis revealed the efficacy of CytoSorb in eliminating bilirubin, with marginal loss of albumin.^{21,22} CytoSorb is a promising liver support device, due to its capacity to adsorb bilirubin and its confirmed capability to modulate the cytokines involved in hepatic dysfunction. In patients with multiorgan failure after surgery, the system is a promising therapeutic choice for critically ill and may help in cytokine reduction, improving organ function.^{21,23}

Conclusion

Several endovascular techniques are available in case of postoperative complication after EVAR in emergency setting. We report also a correction of dangerous hepatic dysfunction in a patient with rAAA after EVAR: an unusual successful treatment of jaundice. The cause in our case probable is due to the hemolysis, but the etiology is not yet clear. Other evidences in the literature confirm the absence of similar observations. CytoSorb could be a promising support to adsorb bilirubin, as in our case.

Author contributions

A.A.M., F.M.O. and A.I. were involved in study concept or design; A.A.M., N.D., F.M.O. and M.B. were involved in data collection; A.A.M., F.M.O., N.D. and A.I. were involved in data analysis or interpretation; all authors were involved in writing the article and approve final revision.

Declaration of conflicting interests

The author(s) declared no potential conflicts of interest with respect to the research, authorship and/or publication of this article.

Funding

The author(s) received no financial support for the research, authorship and/or publication of this article.

Ethical approval

It is exempt for case reports by our institution. Our institution does not require ethical approval for reporting individual cases or case series

Informed consent

Written informed consent was obtained from the patient(s) for their anonymized information to be published in this article.

Consensus statement

The patient gave the consensus to the procedure. Written informed consent was obtained from the patient for publication of this case report and accompanying images. A copy of the written consent is available for review by the Editor-in-Chief of this journal on request.

Registration of research studies

This publication is free from Registration of Research Studies, because it does not use a new technology.

ORCID iDs

Andrea Ascoli Marchetti  <https://orcid.org/0000-0001-9229-0495>

Fabio Massimo Oddi  <https://orcid.org/0000-0001-8081-807X>

References

1. Fenster MS, Dent JM, Tribble C, et al. Aortocaval fistula complicating abdominal aortic aneurysm: case report and literature review. *Cathet Cardiovasc Diagn* 1996; 38(1): 75–79.
2. Nakazawa S, Mohara J, Takahashi T, et al. Aortocaval fistula associated with ruptured abdominal aortic aneurysm. *Ann Vasc Surg* 2014; 28(7): 1793.e5–9.
3. Maeda H, Umezawa H, Goshima M, et al. Surgery for ruptured abdominal aortic aneurysm with an aortocaval and iliac vein fistula. *Surg Today* 2007; 37(6): 445–448.
4. Akwei S, Altaf N, Tennant W, et al. Emergency endovascular repair of aortocaval fistula—a single center experience. *Vasc Endovascular Surg* 2011; 45(5): 442–446.
5. Liu M and Wang H. Endovascular stent-graft repair of spontaneous aorto-caval fistula secondary to a ruptured abdominal aortic aneurysm: an emergency management of hostile anatomy. *SAGE Open Med Case Rep* 2016; 4: 2050313X16646526.
6. Orion KC, Beaulieu RJ and Black JH 3rd. Aortocaval fistula: is endovascular repair the preferred. *Ann Vasc Surg* 2016; 31: 221–228.
7. Syme J. Case of spontaneous varicose aneurism. *Edimb Med J* 1831; 36: 104–105.
8. Debakey ME, Cooley DA, Morris GC Jr, et al. Arteriovenous fistula involving the abdominal aorta: report of four cases with successful repair. *Ann Surg* 1958; 147(5): 646–658.
9. Calligaro KD, Savarese RP and DeLaurentis DA. Unusual aspects of aortovenous fistulas associated with ruptured abdominal aortic aneurysms. *J Vasc Surg* 1990; 12(5): 586–590.
10. Beveridge CJ, Pleass HCC, Chamberlain J, et al. Aortoiliac aneurysm with arteriocaval fistula treated by a bifurcated endovascular stent-graft. *Cardiovasc Intervent Radiol* 1998; 21(3): 244–246.

11. Janczak D, Chabowski M, Szydelko T, et al. Endovascular exclusion of a large spontaneous aortocaval fistula (ACF) in a patient with a ruptured aortic aneurysm. *Vascular* 2014; 22(3): 202–205.
12. Gandini R, Ippoliti A, Pampana E, et al. Emergency endograft placement for recurrent aortocaval fistula after conventional AAA repair. *J Endovasc Ther* 2002; 9(2): 208–211.
13. Oikonomou K, Kasprzak P, Schierling W, et al. Indikationen für den Einsatz von endoanchors: state of the art indications for the use of endoanchors: state of the art einföhrung endoanchors bei EVAR. *Zentralbl Chir* 2018; 143(5): 503–509.
14. Galiñanes EL, Hernandez-Vila EA and Zvonimir K. *Endoanchors minimize endoleaks in chimney-graft endovascular repair. Tex Heart Inst J* 2019; 46(3): 183–188.
15. Matsuo J, Omura A, Matsuda H, et al. Surgery for a late type IIIb endoleak from a fabric tear of an excluder stent graft. *Ann Vasc Surg* 2019; 59: 309.e1–309.e4.
16. Faries PL, Cadot H, Agarwal G, et al. Management of endoleak after endovascular aneurysm repair: cuffs, coils, and conversion. *J Vasc Surg* 2003; 37(6): 1155–1161.
17. Youssef M, Zerwes S, Jakob R, et al. Endovascular aneurysm sealing (EVAS) and chimney EVAS in the treatment of failed endovascular aneurysm repairs. *J Endovasc Ther* 2017; 24(1): 115–120.
18. Saitta GM, Gennai S, Munari E, et al. New conception of relining in EVAS' era: a monocentric case series study. *Ann Vasc Surg* 2019; 56: P351.E1–351.E7.
19. Maruhashi T, Kihara Y and Higashi Y. Bilirubin and endothelial function. *J Atheroscler Thromb* 2019; 26(8): 688–696.
20. Kyuragi R, Matsumoto T, Okadome J, et al. Endovascular aneurysm repair for an abdominal aortic aneurysm and a left ruptured common iliac artery aneurysm in a patient with hepatocellular carcinoma: report of a case. *Surg Today* 2014; 44(8): 1548–1551.
21. Singh A, Mehta Y and Trehan N. Bilirubin removal using CytoSorb filter in a cardiac surgical patient. *J Cardiothorac Vasc Anesth* 2019; 33(3): 881–883.
22. Gemelli C, Cuoghi A, Magnani S, et al. Removal of bilirubin with a new adsorbent system: in vitro kinetics. *Blood Purif* 2019; 47(1–3): 10–15.
23. Falthäuser A and Kullmann F. Use of hemoadsorption in a case of severe hepatic failure and hyperbilirubinemia. *Blood Purif* 2017; 44(2): 98–99.