



Contents lists available at ScienceDirect

## International Journal of Surgery Case Reports

journal homepage: [www.casereports.com](http://www.casereports.com)

## Ante situm liver resection with inferior vena cava replacement under hypothermic cardiopulmonary bypass for hepatoblastoma: Report of a case and review of the literature



Roberta Angelico<sup>a</sup>, Annalisa Passariello<sup>b,c</sup>, Michele Pilato<sup>d</sup>, Tommaso Cozzolino<sup>b</sup>, Marcello Piazza<sup>e</sup>, Roberto Miraglia<sup>f</sup>, Paolo D'Angelo<sup>g</sup>, Mariella Capasso<sup>c</sup>, Maria Cristina Saffioti<sup>a</sup>, Daniele Alberti<sup>h</sup>, Marco Spada<sup>a,\*</sup>

<sup>a</sup> Department of Abdominal Transplantation and Hepatobiliary and Pancreatic Surgery, Bambino Gesù Children's Hospital IRCCS, Rome, Italy

<sup>b</sup> Department of Translational Medical Science, University of Naples "Federico II", Naples, Italy

<sup>c</sup> Department of Pediatric Oncology, Ospedale Santobono- Pausilipon, Naples, Italy

<sup>d</sup> Cardiac Surgery and Heart Transplantation Unit, Department for the Treatment and Study of Cardiothoracic Diseases and Cardiothoracic Transplantation, IRCCS – ISMETT (Mediterranean Institute for Transplantation and Advanced Specialized Therapies), Palermo, Italy

<sup>e</sup> Department of Anesthesia and Intensive Care, IRCCS – ISMETT (Mediterranean Institute for Transplantation and Advanced Specialized Therapies), Palermo, Italy

<sup>f</sup> Radiology Service, Department of Diagnostic and Therapeutic Services, IRCCS – ISMETT (Mediterranean Institute for Transplantation and Advanced Specialized Therapies), Palermo, Italy

<sup>g</sup> "Giovanni Di Cristina" Children's Hospital, Pediatric Hematology and Oncology, Palermo, Italy

<sup>h</sup> Department of Pediatric Surgery, "Spedali Civili" Children's Hospital, Brescia, Italy

## ARTICLE INFO

## Article history:

Received 13 February 2017

Received in revised form 4 June 2017

Accepted 5 June 2017

Available online 13 June 2017

## Keywords:

Hepatoblastoma

Inferior vena cava tumoral thrombi

Ante situm liver resection

Hypothermic cardiopulmonary bypass

## ABSTRACT

**INTRODUCTION:** Hepatoblastoma with tumour thrombi extending into inferior-vena-cava and right atrium are often unresectable with an extremely poor prognosis. The surgical approach is technically challenging and might require major liver resection with vascular reconstruction and extracorporeal circulation. However, which is the best surgical technique is yet unclear.

**PRESENTATION OF CASE:** A 11-months-old boy was referred for a right hepatic lobe mass (90 × 78 mm) suspicious of hepatoblastoma with tumoral thrombi extending into the inferior-vena-cava and the right atrium, bilateral lung lesions and serum alpha-fetoprotein level of 50.795 IU/mL. After 8 months of chemotherapy (SIOPEL 2004-high-risk-Protocol), the lung lesions were no longer clearly visible and the hepatoblastoma size decreased to 61 × 64 mm. Thus, *ante situm* liver resection was planned: after hepatic parenchymal transection, hypothermic cardiopulmonary bypass was started and *en bloc* resection of the extended-right hepatic lobe, the retro/suprahepatic cava and the tumoral thrombi was performed with concomitant cold perfusion of the remnant liver. The inferior-vena-cava was replaced with an aortic graft from a blood-group compatible cadaveric donor. The post-operative course was uneventful and after 8 months of follow-up the child has normal liver function and an alpha-fetoprotein level and is free of disease recurrence with patent vascular graft.

**CONCLUSIONS:** We report for the first time a case of *ante situ* liver resection and inferior-vena-cava replacement associated with hypothermic cardiopulmonary bypass in a child with hepatoblastoma. Herein, we extensively review the literature for hepatoblastoma with tumoral thrombi and we describe the technical aspects of *ante situm* approach, which is a realistic option in otherwise unresectable hepatoblastoma.

© 2017 The Authors. Published by Elsevier Ltd on behalf of IJS Publishing Group Ltd. This is an open access article under the CC BY-NC-ND license (<http://creativecommons.org/licenses/by-nc-nd/4.0/>).

**Abbreviations:** HLB, hepatoblastoma; IVC, inferior vena cava; FAP, familial adenomatous polyposis; LT, liver transplantation; PV, portal vein; TVE, total hepatic vascular exclusion; UVC, upper vena cava; PRE-TEXT, pre treatment extent of disease; POST-TEXT, post treatment extent of disease; SIOPEL, Société Internationale d'Oncologie Pédiatrique-Epithelial Liver Tumor Study Group.

\* Corresponding author at: Department of Abdominal Transplantation and Hepatobiliary and pancreatic Surgery, Bambino, Gesù Children's Hospital IRCCS, Piazza Sant'Onofrio 4, 00146 Rome, Italy.

**E-mail addresses:** [Roberta.angelico@gmail.com](mailto:Roberta.angelico@gmail.com) (R. Angelico), [Annalisa.passariello@unina.it](mailto:Annalisa.passariello@unina.it) (A. Passariello), [mpilato@ismett.edu](mailto:mpilato@ismett.edu) (M. Pilato), [Tom.cozzolino@gmail.com](mailto:Tom.cozzolino@gmail.com) (T. Cozzolino), [mpiazza@ismett.edu](mailto:mpiazza@ismett.edu) (M. Piazza), [rmiraglia@ismett.edu](mailto:rmiraglia@ismett.edu) (R. Miraglia), [oncoematoped@arnascivico.it](mailto:oncoematoped@arnascivico.it) (P. D'Angelo), [Mariellacapasso1969@gmail.com](mailto:Mariellacapasso1969@gmail.com) (M. Capasso), [Mcristina.saffioti@opbg.net](mailto:Mcristina.saffioti@opbg.net) (M.C. Saffioti), [daniele.alberti@unibs.it](mailto:daniele.alberti@unibs.it) (D. Alberti), [marco.spada@opbg.net](mailto:marco.spada@opbg.net) (M. Spada).

<http://dx.doi.org/10.1016/j.ijscr.2017.06.008>

2210-2612/© 2017 The Authors. Published by Elsevier Ltd on behalf of IJS Publishing Group Ltd. This is an open access article under the CC BY-NC-ND license (<http://creativecommons.org/licenses/by-nc-nd/4.0/>).

## 1. Introduction

Hepatoblastoma (HBL) is the most common paediatric liver tumour and it occurs usually in the first 3 years of life. The incidence of HBL has increased in the recent years up to 1.5 cases per million, and it is frequently associated with low birth weight or genetic anomalies. The management of HBL has impressively improved due to combined neoadjuvant chemotherapy and liver resection or liver transplantation (LT), increasing the overall 5-years survival rate up to 75% [1]. The risk stratification with the pre-treatment extent of disease (PRE-TEXT) system, the worldwide multicentre trials experience and the multidisciplinary management, improved HBL prognosis and surgical resectability [2]. However, HBL with tumour thrombi extended into the inferior vena cava (IVC), with or without the involvement of the right atrium, may result challenging to define the best surgical technique.

Different surgical procedures, mainly reported in adults, have been proposed for liver tumour with IVC infiltration, including total hepatic vascular exclusion (TVE) [3]. These techniques are effective to control haemorrhage and air embolism during liver resection, but may cause severe hepatic ischemia/reperfusion injury, hemodynamic instability and potential renal injury. Recently, liver resection under hypothermic liver perfusion with cytoprotective solution (including *in situ*, *ex situ* or *ante situm* techniques) has been proposed for preventing ischemic liver injury [4]. Yet, no experience of *ante situm* liver perfusion associated with hypothermic cardiopulmonary bypass has been reported in children.

Herein we report a successful case of *ante situ* liver resection and IVC replacement under hypothermic cardiopulmonary bypass (CPB), performed in a 21 months-old male with HBL and tumour thrombi into the IVC and right atrium.

The current case has been reported in line with the SCARE criteria [5].

## 2. Case report

The patient was a 11-months old child referred for right upper quadrant abdominal mass. He was born on term (birth weight of 2.470 kg) and had a familial history of adenomatous polyposis (FAP). At the time of admission, the patient was asymptomatic with normal vital signs, but physical examination revealed hepatomegaly, abdominal bloating and umbilical hernia. The ultrasonography (US) showed a large hepatic mass (10 cm in diameter) in the right liver. Serum alpha-fetoprotein (AFP) level was 50.795 IU/mL. Liver function, coagulation, serum B-human chorionic gonadotropin, blood cell count, thyroid function were within normal limits, except for the evidence of thrombocytosis (805.000/UL). Computed tomography (CT) showed a mass of the right hepatic lobe, 90 × 78 mm in size extending in segment IV, with dyshomogeneity and calcifications. The tumour displaced posteriorly the right kidney, dislocated the aorta and the IVC to the left side, stretching the celiac trunk and the superior mesenteric artery (Fig. 1). Tumoral thrombi was present, extending from the right hepatic vein into the IVC up to the right atrium. Bilateral lung lesions, suspicious for HBL metastases, were found as well. Heart involvement was confirmed by echocardiography, which detected a 2.6 cm echoic mass through the tricuspid valve.

A PRE-TEXT III staging (P0, V3, M1) with lung and atrium-cava metastasis at the outset was defined. The child underwent neoadjuvant chemotherapy (SIOPEL 2004 high risk protocol; cycles A1-3 and cycle B) for 8 months: 3 cycles with cisplatin (70 mg/m<sup>2</sup>, 9 doses administered) and doxorubicin (30 mg/m<sup>2</sup>, 6 doses); 4 cycles with carboplatin (6 mg/Kg, 4 doses) and doxorubicin (0.83 mg/Kg, 10 doses); and 2 cycles with carboplatin (25 mg/Kg, 2 doses), vincristine (0.05 mg/Kg, 5 doses) and 5-fluorouracil (33 mg/Kg, 6

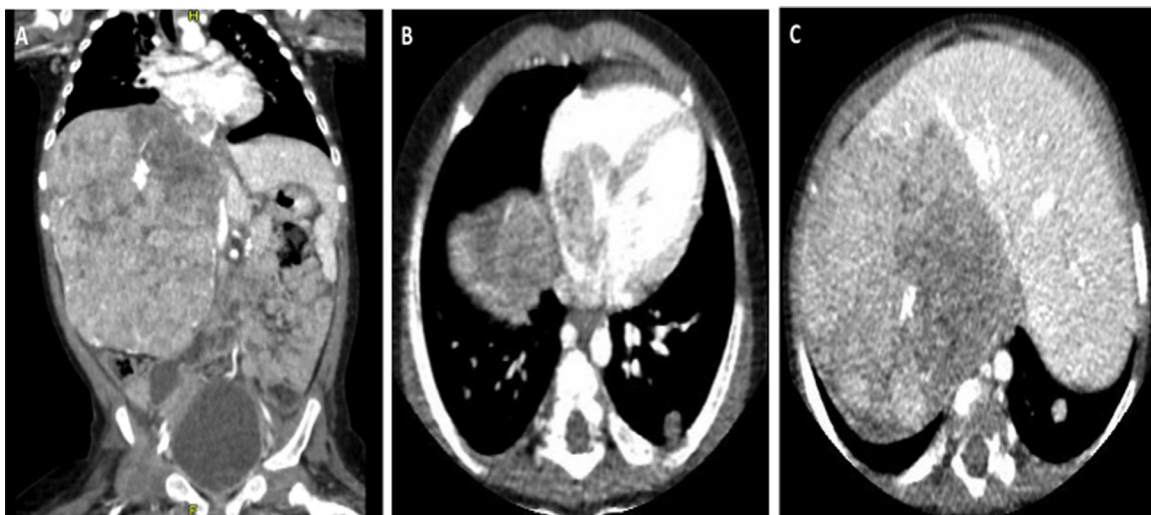
doses). During the treatment, the child presented transient severe thrombocytopenia and one episode of sepsis successfully treated with antibiotics. After neoadjuvant therapy AFP decreased to 879 IU/mL. CT scan showed size reduction of the HBL (61 × 64 mm), still involving the IVC as the right and middle hepatic vein. A left accessory hepatic artery from the left gastric artery and a replaced right hepatic artery arising from the superior mesenteric artery were documented; lung lesions were no longer clearly visible. Cavography documented retrohepatic IVC infiltration by HBL (Fig. 2). After multidisciplinary team meeting (involving surgeons, oncologist, anaesthesiologist and radiologist), the small patient was proposed for an extended right liver resection, with IVC and intracardiac thrombus removal, which was performed by a senior liver transplantation and hepato-biliary-pancreatic surgeon.

### 2.1. Surgical procedure

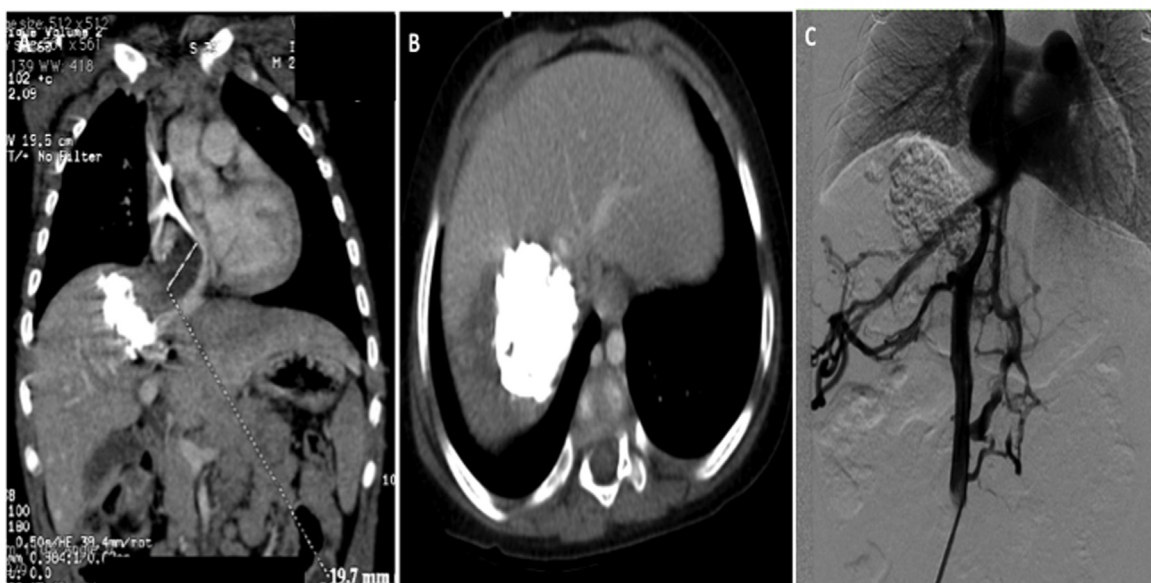
The patient was placed in supine position and the abdomen was explored through a bilateral sub-costal incision with xyphoid extension. There was no evidence of ascites or peritoneal metastasis and intraoperative US documented that the tumour did not involve the left lateral segment of the liver. The Arantius' ligament was dissected and the left hepatic vein was looped. After cholecystectomy, the common bile duct, the right hepatic artery and the anterior and posterior branches of the right portal vein (PV) were ligated and divided. The left PV and the left hepatic arteries were identified and looped. The Rex recess was then exposed and vessels for segment IV were divided. Parenchymal transection, along the line of the falciform ligament, was performed via an anterior approach, using the hanging manoeuvre with "no touch approach" of the tumour. Biliary and vascular structures were divided between clips or tie. Pringle manoeuvre was not used. A vessel loop around the IVC above the renal veins was then placed.

The xiphoid incision was extended up to the jugulum with a median sternotomy and the pericardial sac was opened. After systemic heparinization, the ascending aorta, the upper vena cava (UVC) and the infra-renal IVC were cannulated and clamped, and the extracorporeal circulation with CPB was started. Body temperature was reduced to 28 °C, in order to protect the organs. The diaphragm was incised vertically down toward the suprahepatic IVC and the diaphragmatic veins were divided. After clamping the left hepatic arteries and the PV, the left PV was cannulated through the right PV stump. The left hepatic vein was divided and *ante situ* hypothermic liver perfusion with Celsior solution (4 °C) was started. The liver was further cooled with ice on his surface. After division of the right triangular ligament, an *en-bloc* resection of the extended-right hepatic lobe (segments I + IV-VIII), of the retro- and supra-hepatic IVC and of the neoplastic thrombus (extending from the right hepatic vein to the right atrium) was performed (Fig. 3).

The IVC was reconstructed with a fresh aortic graft from cadaveric donor with identical blood group. The aortic conduit was end-to-end anastomosed with the right atrium (through the diaphragmatic ostium) and inferiorly with the supra-renal IVC by 5/0 prolene continuous running sutures. The neo-IVC was opened immediately below the diaphragmatic ostium and end-to-side triangular anastomosis was performed between the left hepatic vein and the neo-IVC by 6/0 prolene. After 40 min of hypothermic liver perfusion, the portal flush was interrupted. UVC, IVC, aorta, left hepatic arteries and PV were de-clamped, and the left lateral segment was reperfused. The patient was gradually rewarmed and, once hemodynamic stability and good haemostasis were confirmed, the CPB was weaned off, after a total time of 71 min. Roux-and-Y end-to-side hepaticojejunostomy with 6/0 PDS was performed for biliary reconstruction. Before thoraco-abdominal closure, Doppler-US established a good flow through the neo-IVC, left hepatic vein, left hepatic arteries, and PV. The total operation time was 8 h and



**Fig. 1.** Computer Tomography imaging at presentation. Computer Tomography imaging at diagnosis showing: A) right hepatic lobe mass with calcifications (90 × 78 mm); B) lung metastasis and tumoral thrombi invading the inferior vena cava and the right atrium trough the right hepatic vein; c) tumour mass in the right extended lobe of the liver.



**Fig. 2.** Tumoral staging after neoadjuvant chemotherapy and preoperative assessment. Imaging of hepatoblastoma (HBL) after neoadjuvant chemotherapy (SIOPEL 2004 HR protocol): A-B) CT scan showing HBL in the extended-right lobe of liver with tumoral thrombi into the right hepatic vein and the right atrium; C) cavography showing tumoral thrombi infiltrating and compressing the retrohepatic inferior vena cava and retroperitoneal collaterals.

10 min, with a blood loss of 200 ml (video of the surgical technique can be found in supplementary materials).

The resected liver specimen weighted 210 g. The tumour measured 8 × 9 cm. Histological diagnosis was HBL, mixed epithelial and mesenchymal type, with teratoid features, invading the hepatic venous system extensively. The surgical margins were clear from tumour.

**2.2. Post-operative outcome**

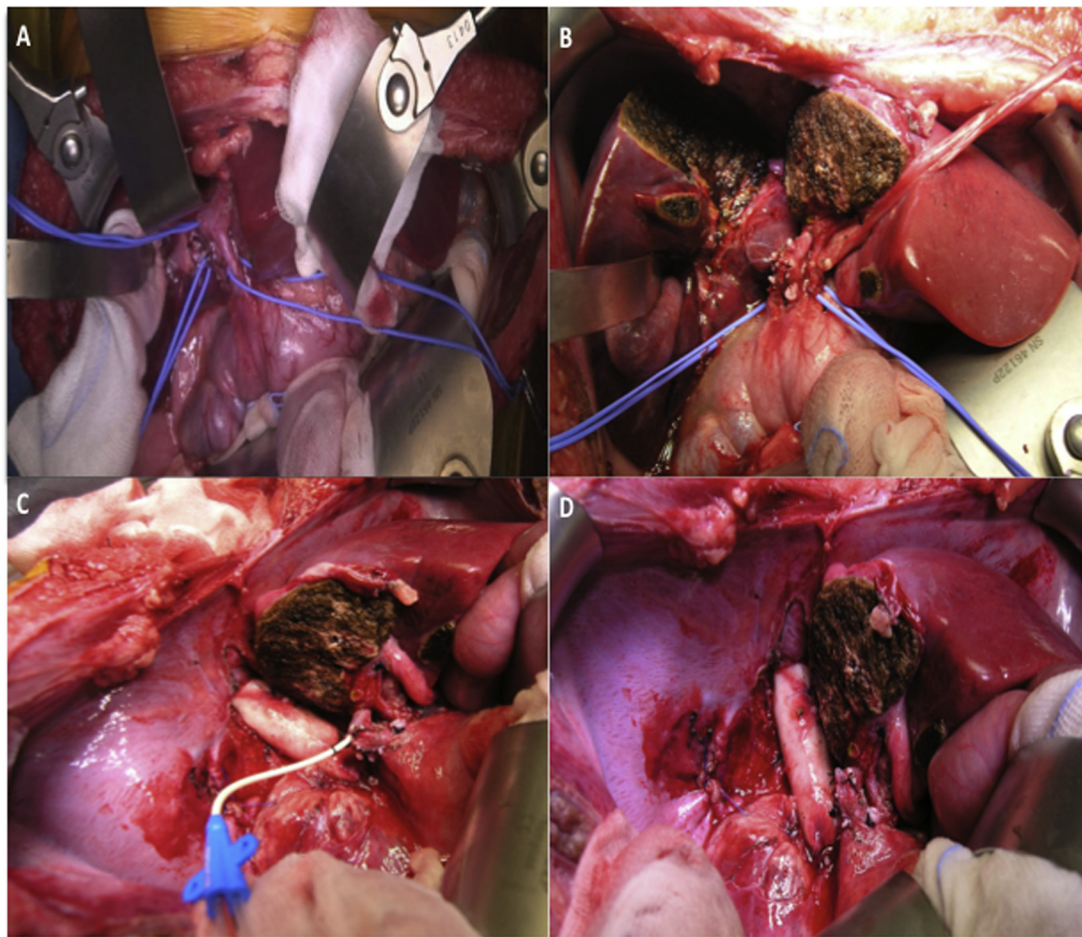
The child had an uneventful post-operative course and was discharged after 23 days from surgery.

After 4 months, a staging CT scan showed absence of disease recurrence and good liver perfusion, with patent aortic graft (Fig. 4). After 12 months of follow-up the child is in good clinical condition with normal liver function test and an AFP level of 1.1 UI/mL.

**3. Discussion**

HBL is the most common primary paediatric liver tumour, with greater frequency among males. The main symptoms include discomfort due to the abdominal mass and loss of appetite, associated with generalized fatigue secondary to anaemia. Most HBLs are sporadic, but some are associated with genetic abnormalities and malformations, such as trisomy 18, Beckwith-Wiedemann syndrome, or FAP [1]. HBL should be suspected in patients aging between 6 months and 3 years old in the presence of an hepatic tumour with thrombocytosis and high AFP levels, which were all present in our case. Histologically, HBL has been classified in the epithelial type, which is the most common and presents with a combination of mixed embryonal and fetal patterns, and in the mesenchymal type, which occurs with or without teratoid features. Yet, most HBLs are extremely heterogenous, often with mixed





**Fig. 3.** Technical aspects of *ante situm* liver resection and inferior vena cava replacement.

Intraoperative view of A) hepatic hilum dissection; B) parenchymal transection, on the line of the falciform ligament via anterior approach; C) *ante situ* hypothermic liver perfusion with Celsior solution (4 °C) through the right portal vein stump and inferior vena cava replacement with donor aortic conduit (note the diaphragmatic ostium resected and reconstructed); D) final view of *en-bloc* resection of the extended-right hepatic lobe (segments I+IV-VIII), the inferior vena cava with tumoral thrombi and the diaphragmatic ostium.

histological components, and only rarely composed of a single histological type. Mesenchymal elements have been associated with an improved prognosis in patients with advanced disease, as it was in our case [2].

The PRE-TEXT system allows to stage and stratify the risk of HBL and to define its prognosis and surgical resectability. Although 60% of tumours are unresectable at presentation, HBL is highly chemosensitive and up to 85% of cases become operable after neoadjuvant chemotherapy [2].

The best chemotherapy for advanced tumours is still controversial. The platinum-based chemotherapeutic regimens have been essential in improving patient survival in advanced HBL. The Children's Oncology Group (COG) recommends cisplatin, 5-fluorouracil and vincristine, associated with doxorubicin for intermediate and high-risk patients, while the Société Internationale d'Oncologie Pédiatrique-Epithelial Liver Tumor Study Group (SIOPEL) recommends in very high-risk patients cisplatin intensification therapy (SIOPEL-4 protocol) [2].

In the current case the SIOPEL 4 protocol was used accordingly with presence of metastatic disease and major vascular invasion. Since tumour remained unresectable at the first CT re-evaluation with high AFP levels, he received additional pre-operative chemotherapy before surgery was attempted (data not shown).

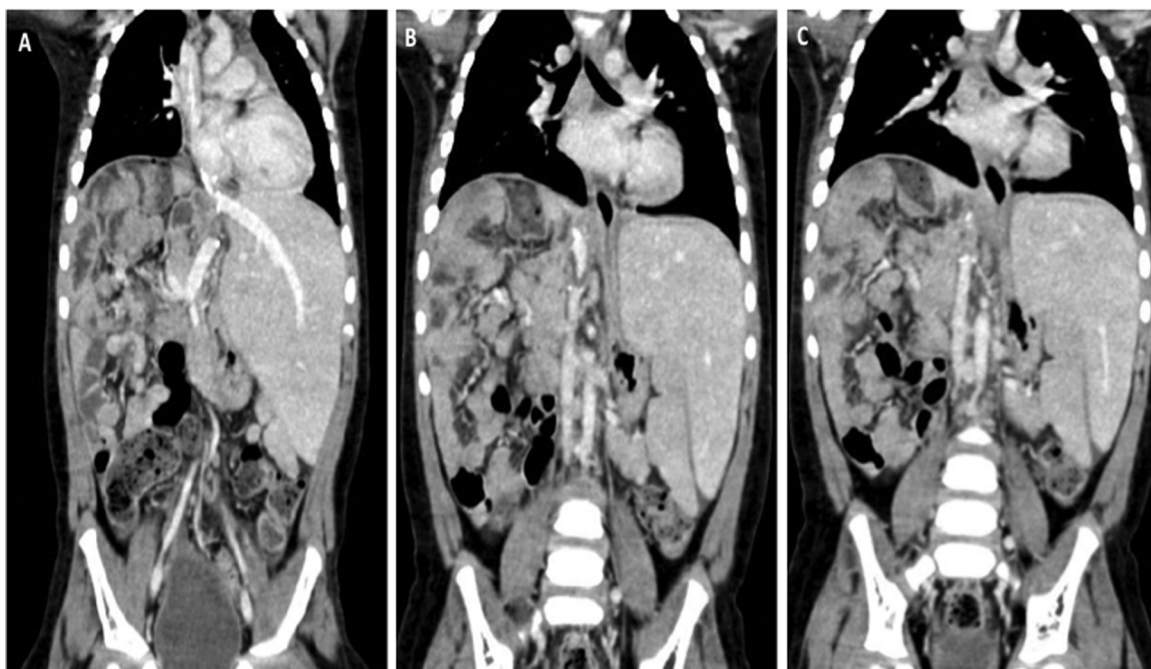
Complete surgical removal of HBL, by resection or LT, remains the only treatment achieving long-term survival. LT plays a key

role in the management of children with large and multifocal HBL, but equivalent long-term disease-free survival have been recently achieved with large non-anatomic or extended liver resection, provided that complete macro- and micro-scopic tumour resection can be achieved [6].

Although it must be carefully considered on a case-by-case basis, multidisciplinary post treatment extent of disease (POST-TEXT) tumour evaluation and intraoperative liver inspection are essential to define the best therapeutic management. In this sense, prompt referral to a center with expertise in both paediatric LT and extreme resection must be considered the gold standard in care giving. POST-TEXT tumours that spare at least 1 branch of the portal vein and 1 hepatic vein should always be evaluated for liver resection. When venous obstruction, encasement, and/or invasion of the main portal vein or bifurcation or the IVC or all 3 hepatic veins are present, the tumour is classified unresectable and intended to transplantation [2].

In this case we opted for a major liver resection with IVC reconstruction because of evidence of lung metastasis and presence of left lateral liver free of disease with adequate remnant liver volume. Hepatic resection avoided exposing the young boy to long-term immunosuppression.

Tumour thrombi in the hepatic veins and IVC with an extension up to the atrium are associated with high risk of pulmonary embolism, occlusion of the tricuspid valve (ball valve syndrome),



**Fig. 4.** Computer Tomography imaging after surgery. Computer Tomography scan after 4 months from surgery showing patent left hepatic vein anastomosis (A) and retrohepatic cava replacement with aortic graft from cadaveric donor (B,C).

congestive heart failure and spread of systemic metastasis and are mainly reported in adults with hepatocellular carcinoma [3].

Despite surgical treatment seems to remain the only effective therapeutic option, there is no established management for such cases. In 1966, Heaney et al. firstly proposed the TVE of the liver [7]. TVE is effective in controlling haemorrhage and air embolism, but causes severe hemodynamic disturbances characterized by >30% decrease in mean arterial pressure, >50% decrease of cardiac index and severe ischemic liver damage, in particular in small remnant liver after neoadjuvant chemotherapy [3]. Even it is not mandatory, it is advisable to use TVE in combination with CPB in order to reduce hemodynamic instability and potential renal injury, in particular when prolonged TVE is required.

In 1981, Ein et al. described the first successfully use of CPB associated with hypothermic cardiocirculatory arrest in 6 children with right atrial tumoral thrombi [8]. However, the procedures were associated with high post-operative haemorrhage and microscopic residual tumour (R1). Later, further reports of major HBL resections using the CPB have been reported, as summarized in Table 1. Many cases have been associated with major complications such as post-operative death for pulmonary embolism (possibly related to tumoral thrombi spreading during liver mobilization) [9]; ischemic cholangiopathy requiring subsequent LT [10]; residual tumoral thrombi in major vessels [6].

To reduce ischemic damage related to TVE and cellular metabolism during this phase, the concept of hypothermic preservation, by liver perfusion with cytoprotective solutions combined with cooling of the organ's surface, has been investigated. In 1974, Forner et al. described the first *in situ* hypothermic liver perfusion during major liver resection, where hypothermia was induced by liver perfusion via the arterial and portal system with cold Ringer's solution (4 °C) [11]. However, in case of tumours located on the posterior side of the liver and invading the IVC, *in situ* hypothermic liver preservation may not be sufficient to expose the retro-hepatic vena cava. Consequently, in 1990 Pichlmayr et al. proposed the *ex situ* liver perfusion [12], where the liver is completely removed from the patient, cooled with ice and perfused with cold solu-

tion on the backtable; after the bench surgery the remnant liver is reimplanted orthotopically. Later, in 1991 Hannoun et al. [13] introduced the *ante situm* liver resection characterized by no hepatoduodenal ligament division, cold liver perfusion, TVE and division of the supra-hepatic IVC, which allows the rotation of the liver around the coronary axis with optimal exposure of the hepatic veins confluence and the retro-hepatic IVC. Belghiti et al. described the modified *ante situm* technique in which the IVC is cut above and below the liver, permitting a better mobilization of the liver [14]. A recent review of hypothermic *ante situ* resection in tumour of the hepatocaval confluence suggests that this approach is easier and safer than the *ex situ* technique, with an acceptable morbidity and mortality rate [4].

To the best of our knowledge, the current report is the first case of *ante situm* liver resection and IVC replacement with hypothermic CPB for HBL in a young child. Since the tumour was involving the extended right lobe of the liver with the retro-hepatic IVC and the right atrium, the CPB was needed. Anterior approach to the liver was adopted performing parenchymal transection with “no touch technique” of the lesion, to avoid tumoral embolization. Moreover, to reduce the risk of bleeding during this phase, liver resection was completed before eparinization and CPB, differing from previous reports. The modified *ante situm* technique permitted to expose optimally the retro-hepatic cava by cutting the IVC above and below the liver, to mobilize the liver anteriorly and to reduce the ischemia liver injury of the remnant segments by PV perfusion. Furthermore, we didn't divide the liver hilum, avoiding the risk of hepatic artery thrombosis.

So far, the largest series of the *ante situm* liver resection was reported by Raab et al.: out of 24, one adult patient had HBL [15]. Authors adopted a normothermic vein bypass and IVC reconstruction was performed with autologous saphenous; however, details regarding the outcome of the HBL patient are not available.

In the current report a simple thrombectomy was not feasible since the tumoral thrombi infiltrated the IVC wall. Therefore, retro-hepatic IVC resection and interposition of graft were needed to achieve R0 resection. The options to reconstruct the IVC include pri-

**Table 1**  
Literature reports of liver resection and cardiopulmonary bypass for hepatoblastoma with inferior vena cava tumoral thrombi.

Report	Year	Cases	Age (months)/(Gender)	Type of vascular infiltration	Metastatic disease*	Neoadjuvant chemotherapy	Adjuvant chemotherapy	Type of liver resection	IVC reconstruction	CPB (type, min)	Outcome
Ein et al. [8]	1981	6**	8–15 yrs/4M, 2F	NA	None	None	Yes (5/6)	NA	None	Hypothermic 20 °C, 43–75 min	2 died/2 Alive NED, 2 alive with lung metastasis
Mestres et al. [9]	1991	1	36/M	RA	None	DOXO + CIS	None	Right hepatectomy	Transatrial trombectomy	Hypothermic 20 °C, 146 min	Died for polmonary embolism (day 23)
Lautz et al. [10]	2011	1	96/F	RA	None	VCR, CIS, 5FU	VCR, CIS, 5FU	Non anatomical resection	Transatrial trombectomy	Yes	Alive, NED (LT for ischemic cholangiopathy)
Fuchs et al. [6]	2016	2	NA	IVC-RA	None	Platinum-based	Yes	NA	1:prothesis;1:pericardial patch	Yes	Died for tumoral thrombi recurrence
Current case	2016	1	11/M	IVC-RA	Lungs	CBCDA, 5FU, VCR, DOXO	-	Ante situm liver resection (right hepatectomy)	Fresh aortic graft from cadaveric compatible donor	Hypothermic, 71 min	Alive, NED

**Abbreviations:** CBCDA, Carboplatin; CIS, Cisplatin; CPB, cardiopulmonary bypass; DOXO, doxorubicin; IVC, inferior vena cava; NA, non available; NED, non evidence of disease; RA, right atrium; VCR, vincristine; 5FU, F-fluoro-uracil.

\*Distant metastatic disease with the exception of vascular infiltration of IVC and right atrium.

\*\*In this case series, indications for surgery included: hepatoblastoma (n=4), rhabdomyosarcoma (n=1), hepatocarcinoma (n=1).

mary repair or patching with bovine's pericardium or autologous peritoneum in case of limited IVC involvement. Extensive venous involvement requires substitution with synthetic, autologous or heterologous fresh or criopreserved graft conduit. No definitive data exists in favour of one technique compared to the others [16]. In our young patient, we preferred the interposition of a graft from a compatible cadaveric donor to reduce the risk of vessel collapse and to avoid long-term anticoagulation.

In conclusion, although the significance of our data is limited by the case-report nature of our surgical practice, the current case suggests that *ante situm* liver resection is feasible in children with liver tumours considered unresectable by conventional surgery or when LT is contraindicated or considered as a second line-treatment. The use of hypothermic CPB is safe and allows expanding surgical indications when prolonged TVE with complex vessel reconstruction are needed. Patient selection, preoperative evaluation of the liver function and anatomy as well as intraoperative assessment are essential to achieve good outcome. Our findings justify further investigations to identify the optimal surgical management for children with large and centrally located liver tumours.

**Conflicts of interest**

No conflicts of interest

**Funding**

This research did not receive any specific grant from the founding agencies in the public, commercial, or not-for-profit sectors.

**Ethical approval**

Not applicable

**Consent declaration**

Written informed consent was obtained from the patient for publication of this case report and accompanying images. A copy of the written consent is available for review by the Editor-in-Chief of this journal on request.

**Author contribution**

- Roberta Angelico – Data collection, analysis, review of the literature and wrote manuscript
- Annalisa Passariello – Oncological management, intellectual content, review of the literature
- Pilato Michele – Performed the cardiothoracic surgery, intellectual content
- Cozzolino Tommaso – Oncological management, data collection, review of the literature
- Piazza Marcello – Oncological management, analysis and interpretation, intellectual content
- Miraglia Roberto – Data collection, analysis and interpretation
- D'Angelo Paolo – Oncological management, analysis and interpretation
- Capasso Mariella – Analysis and interpretation, intellectual content
- Saffiotti Maria Cristina – Data collection, analysis and interpretation
- Alberti Daniele – Planning of surgical strategy, intellectual content
- Spada Marco – Performed the abdominal surgery, draft the work, intellectual content, senior author



**Guarantor**

Marco Spada.

**Appendix A. Supplementary data**

Supplementary data associated with this article can be found, in the online version, at <http://dx.doi.org/10.1016/j.ijscr.2017.06.008>.

**References**

- [1] D.C. Aronson, R.L. Meyers, Malignant tumors of the liver in children, *Semin. Pediatr. Surg.* 25 (5) (2016) 265–275.
- [2] P. Czauderna, B. Haeberle, E. Hiyama, A. Rangaswami, M. Krailo, R. Maibach, et al., The Children's Hepatic tumors International Collaboration (CHIC): novel global rare tumor database yields new prognostic factors in hepatoblastoma and becomes a research model, *Eur. J. Cancer* 52 (2016) 92–101.
- [3] A.W. Hemming, K.L. Mekeel, I. Zendejas, R.D. Kim, J.K. Sicklick, A.I. Reed, Resection of the liver and inferior vena cava for hepatic malignancy, *J. Am. Coll. Surg.* 217 (1) (2013) 115–124 (Discussion 124–125).
- [4] A. Mehrabi, H. Fonouni, M. Golriz, S. Hofer, M. Hafezi, N.N. Rahbari, et al., Hypothermic ante situm resection in tumors of the hepatocaval confluence, *Dig. Surg.* 28 (2) (2011) 100–108.
- [5] R.A. Agha, A.J. Fowler, A. Saetta, I. Barai, S. Rajmohan, Orgill DP and the SCARE group. the SCARE statement: consensus-based surgical case report guidelines, *Int. J. Surg.* 34 (2016) 180–186.
- [6] J. Fuchs, S. Cavdar, G. Blumenstock, M. Ebinger, J.F. Schäfer, B. Sipos, et al., POST-TEXT III and IV hepatoblastoma: extended hepatic resection avoids liver transplantation in selected cases, *Ann. Surg.* (August (5)) (2016) (Epub ahead of print).
- [7] J.P. Heaney, W.K. Stanton, D.S. Halbert, J. Seidel, T. Vice, An improved technique for vascular isolation of the liver: experimental study and case reports, *Ann. Surg.* 163 (1966) 237–241.
- [8] S.H. Ein, B. Shandling, W.G. Williams, G. Trusler, Major hepatic tumor resection using profound hypothermia and circulation arrest, *J. Pediatr. Surg.* 16 (3) (1981) 339–342.
- [9] C.A. Mestres, K. Prabhakaran, O.A. Adebo, C.K. Kum, C.N. Lee, Combined resection of hepatoblastoma and intracaval right atrial extension with profound hypothermia and circulatory arrest, *Eur. J. Cardiothorac. Surg.* 5 (12) (1991) 657–659.
- [10] T.B. Lutz, T. Ben-Ami, N. Tantemsapya, Y. Gosiengfiao, R.A. Superina, Successful nontransplant resection of POST-TEXT III and IV hepatoblastoma, *Cancer* 117 (9) (2011) 1976–1983.
- [11] J.G. Fortner, M.H. Shiu, D.W. Kinne, D.K. Kim, E.B. Castro, R.C. Watson, et al., Major hepatic resection using vascular isolation and hypothermic perfusion, *Ann. Surg.* 180 (1974) 644–652.
- [12] R. Pichlmayr, H. Grosse, J. Hauss, G. Gubernatis, P. Lamesch, H.J. Bretschneider, Technique and preliminary results of extracorporeal liver surgery (bench procedure) and of surgery on the in situ perfused liver, *Br. J. Surg.* 77 (1990) 21–26.
- [13] L. Hannoun, Y. Panis, P. Ballardur, E. Delva, J. Honiger, E. Levy, et al., Ex situ in-vivo liver surgery, *Lancet* 337 (1991) 1616–1617.
- [14] J. Belghiti, B. Dousset, A. Sauvanet, E. Lipinska, J. Aschehoug, F. Fekete, Preliminary results with 'ex situ' surgery for hepatic tumors: an alternative between palliative treatment and liver transplantation? *Gastroenterol. Clin. Biol.* 15 (1991) 449–453.
- [15] R. Raab, H.J. Schlitt, K.J. Oldhafer, A. Bornscheuer, H. Lang, R. Pichlmayr, Ex-vivo resection techniques in tissue-preserving surgery for liver malignancies, *Langenbecks Arch. Surg.* 385 (3) (2000) 179–184.
- [16] N.N. Vladov, V.I. Mihaylov, N.V. Belev, V.M. Mutafchiiski, I.R. Takorov, S.K. Sergeev, et al., Resection and reconstruction of the inferior vena cava for neoplasms, *World J. Gastrointest. Surg.* 27 (4) (2012) 96–101 (4).

**Open Access**

This article is published Open Access at [sciedirect.com](http://sciedirect.com). It is distributed under the [IJSCR Supplemental terms and conditions](#), which permits unrestricted non commercial use, distribution, and reproduction in any medium, provided the original authors and source are credited.