

Cardiac Amyloidosis Detected by Tc-99m (V) DMSA Myocardial Uptake

CARLO MANNI, M.D.,† GIUSEPPE SANGIORGI, M.D.,* SERGIO BOEMI, M.D.,†
DOMENICO DE NARDO, M.D.,* CESIDIO CIPRIANI, M.D.,† AND DARIO CANNATA, M.D.*

Technetium-99m (V) DMSA scintigraphy was performed in a patient with histologically proven systemic amyloidosis associated with multiple myeloma. The patient had manifestations of cardiac congestive failure. Radionuclide angiocardiology showed a normal left ventricular ejection fraction, but with a typical restrictive pattern of diastolic filling. Myocardial imaging was performed 4 hours after an intravenous dose of 740 MBq of Tc-99m (V) DMSA. The scans obtained in the 45° and 70° left anterior oblique and anterior views showed a marked and homogeneous accumulation of Tc-99m (V) DMSA in the left ventricular walls with the left ventricular cavity clearly visualized as a central cold area.

References

1. Ohta H, Endo K, Fujita T, et al: Clinical evaluation of tumour imaging using ⁹⁹Tc (V)m dimercaptosuccinic acid; a new tumour-seeking agent. *Nucl Med Commun* 9:105, 1988.
2. Ohta H, Endo K, Kanoh T, et al: Technetium-99m (V) DMSA uptake in amyloidosis. *J Nucl Med* 30:2049, 1989.
3. Ohta H, Okada T, Furukawa Y, et al: Tc-99m (V) DMSA uptake in cardiac amyloidosis. *Clin Nucl Med* 16:673, 1991.
4. Kobayashi H, Sakahara H, Itoh T, et al: Technetium 99-m (V) dimercaptosuccinic acid uptake in intra-abdominal massive deposit of amyloid protein. *J Nucl Med* 34:815, 1993.
5. Simons M, Isner JM: Assessment of relative sensitivities of non-invasive tests for cardiac amyloidosis in documented cardiac amyloidosis. *Am J Cardiol* 69:425, 1992.
6. Fournier C, Grimon G, Rinaldi JP, et al: Usefulness of technetium-99m pyrophosphate myocardial scintigraphy in amyloid polyneuropathy and correlation with echocardiography. *Am J Cardiol* 72:854, 1993.
7. Cohen A, Skinner M: New frontiers in the study of amyloidosis. *N Engl J Med* 323:542, 1990.
8. Hawkins PN, Lavender JP, Pepys MB: Evaluation of systemic amyloidosis by scintigraphy with ¹²³I-labeled serum amyloid P component. *N Engl J Med* 323:508, 1990.
9. Lekakis J, Nanas J, Moustafellou C, et al: Cardiac amyloidosis detected by indium-111 antimony imaging. *Am Heart J* 124:1630, 1992.

Received for publication August 11, 1993; revision accepted December 6, 1993.

Reprint requests: Domenico De Nardo, M.D., Clinica Medica, Department of Internal Medicine, University of Rome Tor Vergata, S. Eugenio Hospital, 10 P. le dell'Umanesimo, Rome 00144-Italy.

From the Clinica Medica, Department of Internal Medicine,* University of Rome Tor Vergata, and the Nuclear Medicine Service,† S. Eugenio Hospital, Rome, Italy

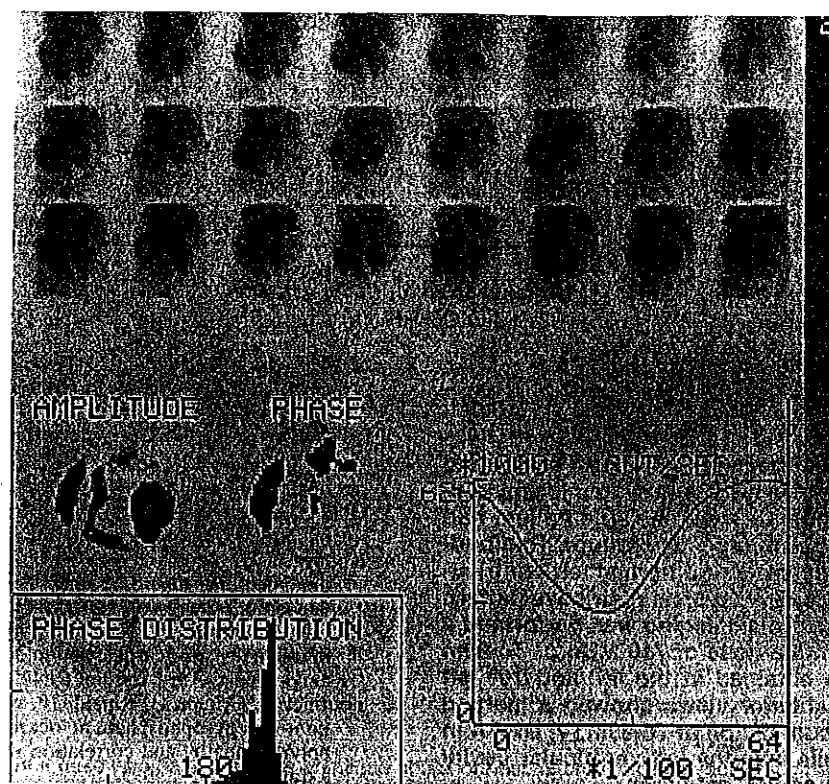


Fig. 1. An 80-year-old man with a history of multiple myeloma (stage IIA diagnosed three years earlier) was treated with melphalan and prednisone with low M-component production of IgG λ light chains. He was admitted for the evaluation of exertional and nocturnal dyspnea associated with ankle edema and nocturia. Physical examination revealed distended jugular veins, hepatojugular reflux, and congestive hepatomegaly. The heart examination showed no significant findings and blood pressure was normal. The electrocardiogram showed low-voltage QRS complexes in limb leads and left anterior hemiblock. The echocardiogram demonstrated the presence of increased thickness of the left ventricular walls (interventricular septal thickness 17 mm, posterior wall thickness 16 mm), and normal sized ventricular cavities with enlarged atria. The left ventricular volume curve, derived from the equilibrium radionuclide angiographic study, demonstrated an ejection fraction of 52% and a typical restrictive pattern of constant slow filling for the entire diastolic period with poor atrial filling contribution. An abdominal fat biopsy was performed and the histochemical studies confirmed the definitive diagnosis of systemic amyloidosis in a patient with multiple myeloma.

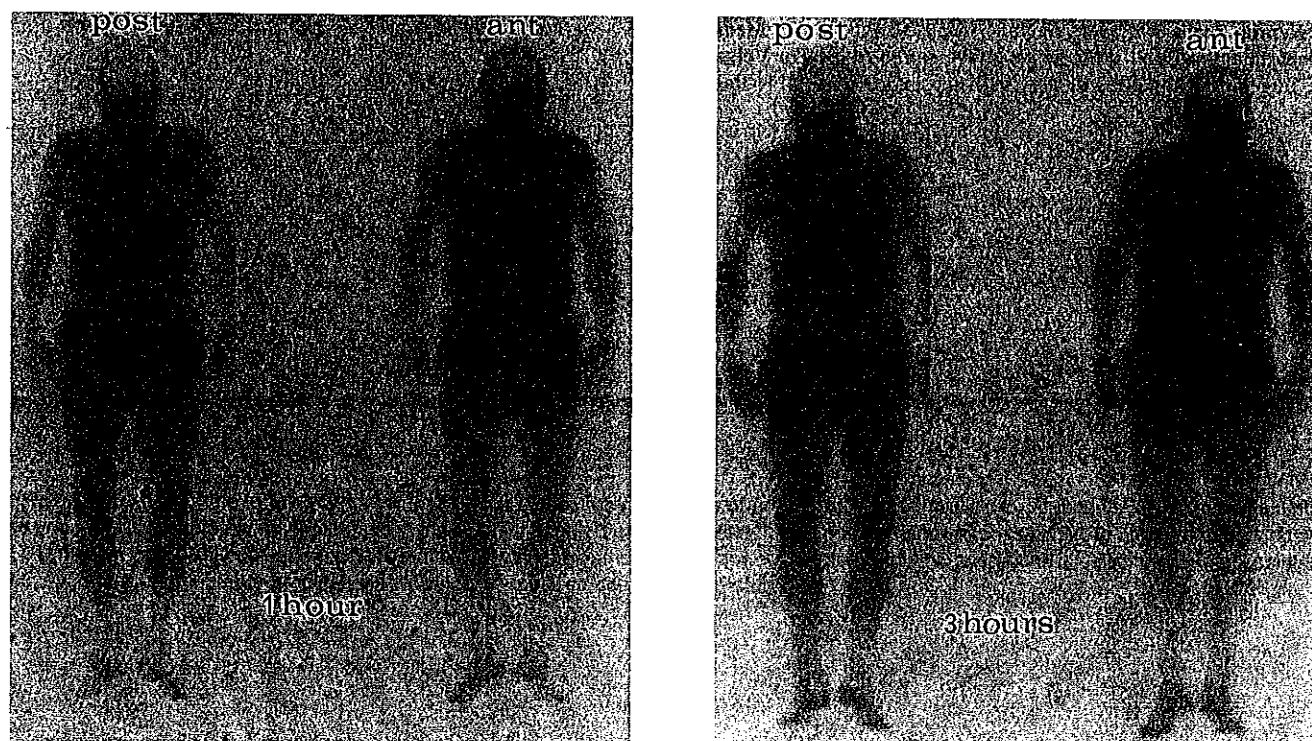


Fig. 2. The posterior (left) and anterior (right) views of the whole body scan were acquired 1 and 3 hours after the intravenous injection of 740 MBq of ^{99m}Tc (V) DMSA. A light blood pool activity was recorded only at the early scan. The pattern of early and late distribution of the activity included the nasal mucosa, salivary glands, and urinary tract, which is considered normal for DMSA (1,2). Moreover, areas of intense activity were demonstrated at the level of cardiac silhouette and in the soft tissue of the gluteal regions.




Fig. 3. Immediately after the latest whole body scan was performed, planar myocardial scintigrams were acquired in the 45° and 70° left anterior oblique and anterior views using a matrix of 128×128 with a 2 zoom factor. The intense cardiac activity was exclusively because of radiotracer myocardial uptake representing the whole left ventricle wall. The left ventricular cavity was clearly visualized as a centrally located cold area, thus excluding an artifact because of blood pool activity. In our patient with multiple myeloma, the abdominal fat biopsy provided the final diagnosis of systemic amyloidosis. Cardiac involvement was suggested by clinical, electrocardiographic, echocardiographic findings and strongly supported by the restrictive pattern of cardiomyopathy, characteristic of cardiac amyloidosis, demonstrated by radionuclide angiocardigraphy. Myocardial uptake of Tc-99m (V) DMSA represents a pathological finding (3). Previous authors have reported Tc-99m (V) DMSA localization in both the amyloid depositions in the head and neck region in plasmocytoma patient (2), in the intra-abdominal amyloid massive deposits of primary amyloidosis (4) and in medullary thyroid carcinoma (1-2) which is characterized by conspicuous amyloid depositions, and suggested the usefulness of Tc-99m (V) DMSA scintigraphy for diagnosing the presence and the distribution of the amyloid deposits (1-4).

Our data confirm the usefulness of Tc-99m (V) DMSA as an imaging agent for amyloid deposits and suggest that Tc-99m (V) DMSA myocardial uptake could be considered as a useful index in the diagnosis of cardiac amyloidosis. Radionuclide imaging with Tc-99m pyrophosphate has been used for several years in the diagnosis of cardiac amyloidosis. However, in previous studies, detection of amyloid deposits in the heart through myocardial uptake of pyrophosphate labeled with Tc-99m gave varying degrees of effectiveness. Thus, the clinical relevance of this imaging procedure remains to be defined (5-7).

Scintigraphy after the injection of purified human serum amyloid P component labeled with I-123 has been proposed for diagnostic imaging and monitoring of organ involvement of systemic amyloidosis. This test appears promising and capable of identifying amyloid deposits in most organ systems, although a relative insensitivity in cardiac tissue has been reported. Moreover, this method involves the use of a human blood product, as radionuclide carrier, binding to amyloid fibrils (7,8).

Diffuse and intense uptake of In-111 labeled antimyosin monoclonal antibodies has been observed in both ventricles in one patient with cardiac amyloidosis (9). Indium-111 antimyosin imaging has proved useful in detecting myocyte necrosis in patients with myocardial infarction, myocarditis, heart transplant rejection, and doxorubicin cardiotoxicity. This test involves the injection of murine monoclonal antibody Fab fragment, as radionuclide carrier, binding to damaged myocytes or possibly to amyloid deposits. A simple, safe, and reliable procedure for diagnostic radionuclide imaging of cardiac amyloidosis would be clinically attractive. Further evaluation of Tc-99m (V) DMSA scintigraphy is needed in view of the use of this agent for the noninvasive diagnosis of cardiac amyloidosis.