

31st EACTS Annual Meeting
Vienna, Austria 7-11 October 2017



Preserving aortic root function in David reimplantation technique

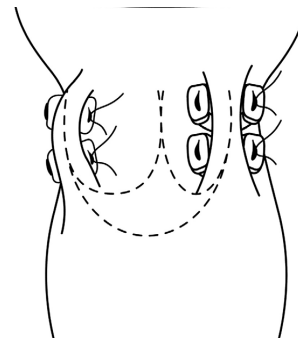
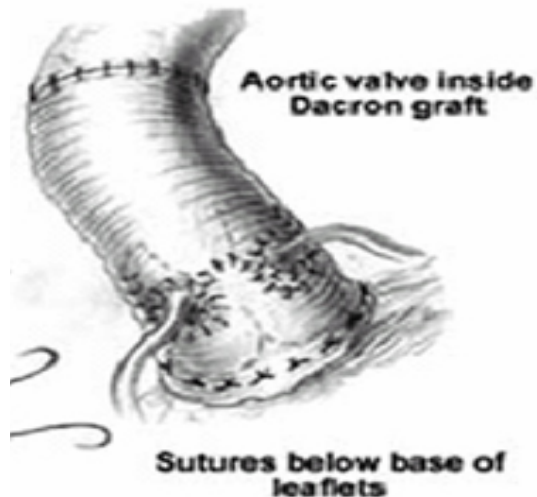
C. Pisano, L. Asta, V. Mangerini, S. Territo, OF. Triolo, A. Ricasoli, V. Argano
Unit of Cardiac Surgery, University of Palermo, Palermo, Italy

No disclosure




Reimplantation technique

- ✓ The original reimplantation technique proposed by David includes securing a cylindrical Dacron tube at the level of the ventriculoaortic junction; the preserved native valve is then sutured within the Dacron graft following their scalloped shape in a fashion similar to that used for implanting a stentless aortic valve.
- ✓ Compared to the remodelling technique, this operation has the clear advantage of being utterly haemostatic, offering a good support to the aortic wall, but more importantly preventing any further dilatation of the aortic annulus.
- ✓ However, it is described a loss of function for the annulus and sinuses of Valsalva with a possible impact on leaflet mobility leading to reduced long term stability of the repair.

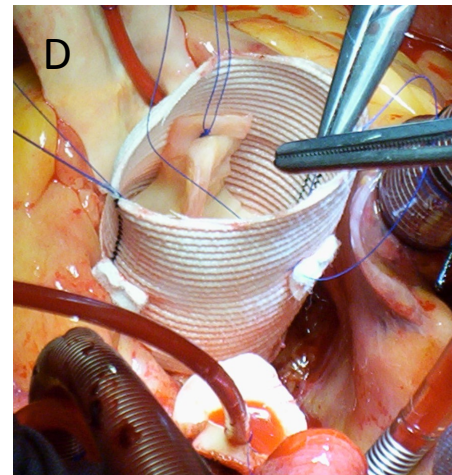
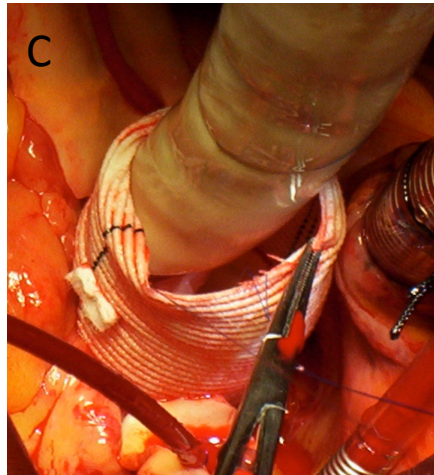
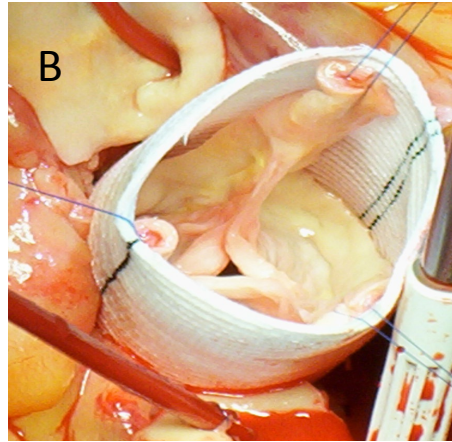
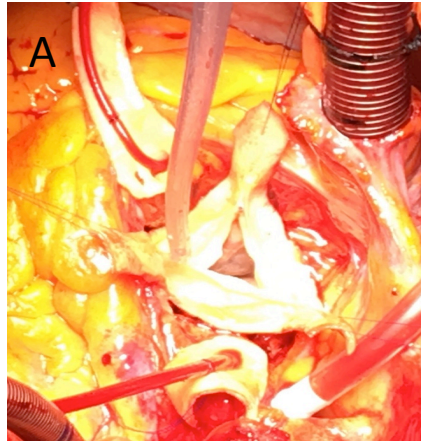


Kollar Technique



Valsalva Graft

Our technique



When the valve was deemed acceptable for preservation (*healthy aortic valve*), the aneurysm was excised, leaving ~5 mm rim of aortic tissue around the native valve and around the coronary ostia.(A)

Next, horizontal mattress sutures were placed circumferentially under the aortic valve annulus from inside to out and across a Dacron graft, measuring at least 4 mm larger than the annulus .The Dacron graft was seated such that the valve was contained within the graft. The sutures were tied over the appropriate size Hegar dilator placed across the aortic valve in order to avoid constriction of the annulus and left ventricular outflow tract or overplication of the graft.(B)

Without stretching the Dacron graft, the 3 commissures were pulled up and fixed at the same height using 4-0 polypropilene double ended sutures placed horizontally from inside to outside. Care is taken, with these externally pledgeted sutures, in narrowing the tube graft creating a new sinotubular junction measuring the same diameter of the annulus(C).

The valve was then attached to the wall of the Dacron graft using the same three sutures starting from each commissure running down to the nadir of the cusps (D).

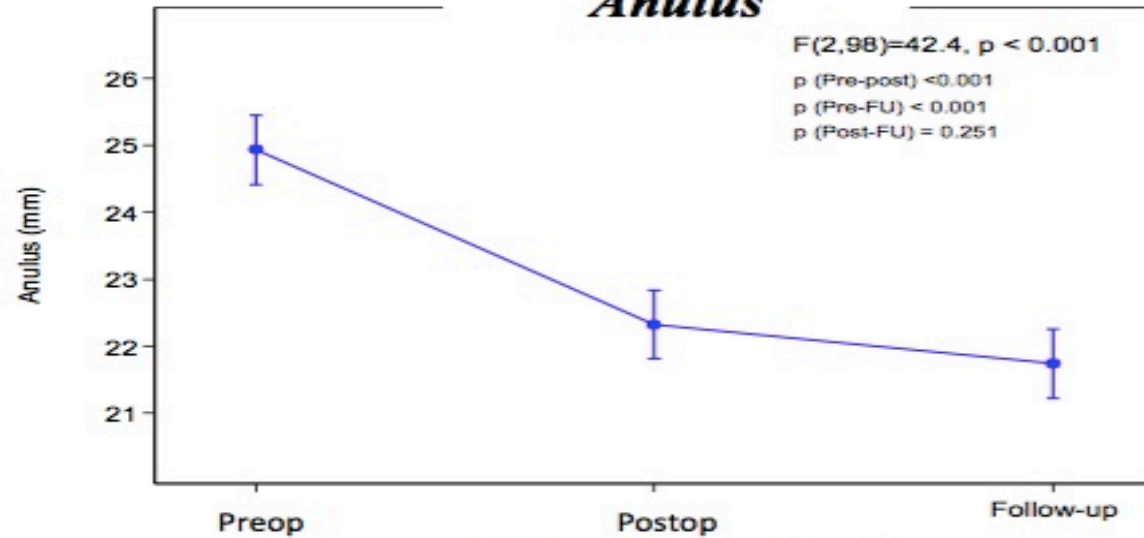


Results

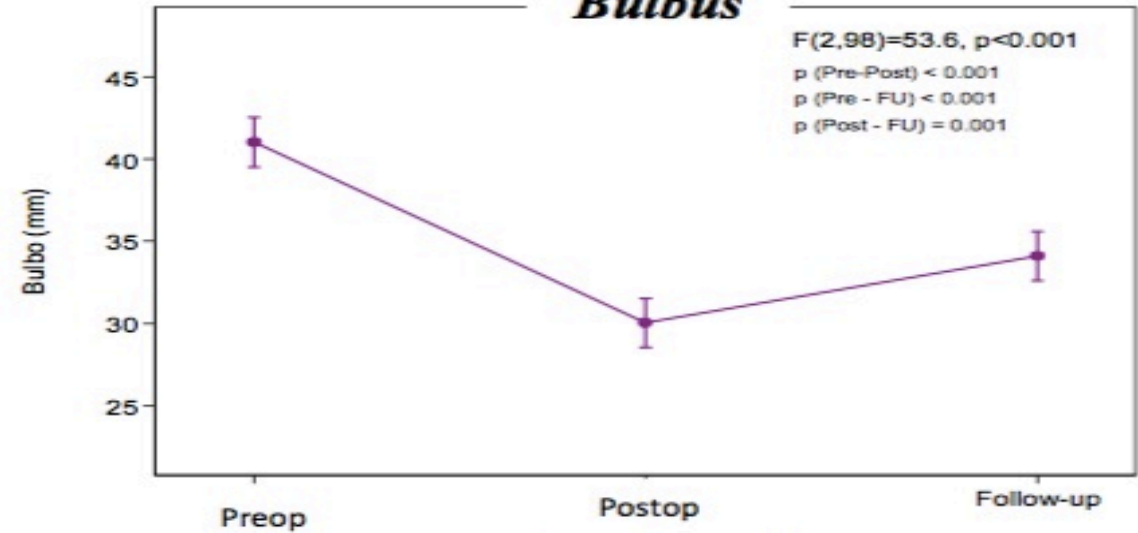
Total population 102 patients
Mean Age population 66,1±13,6

Follow-up 46,7±38 months

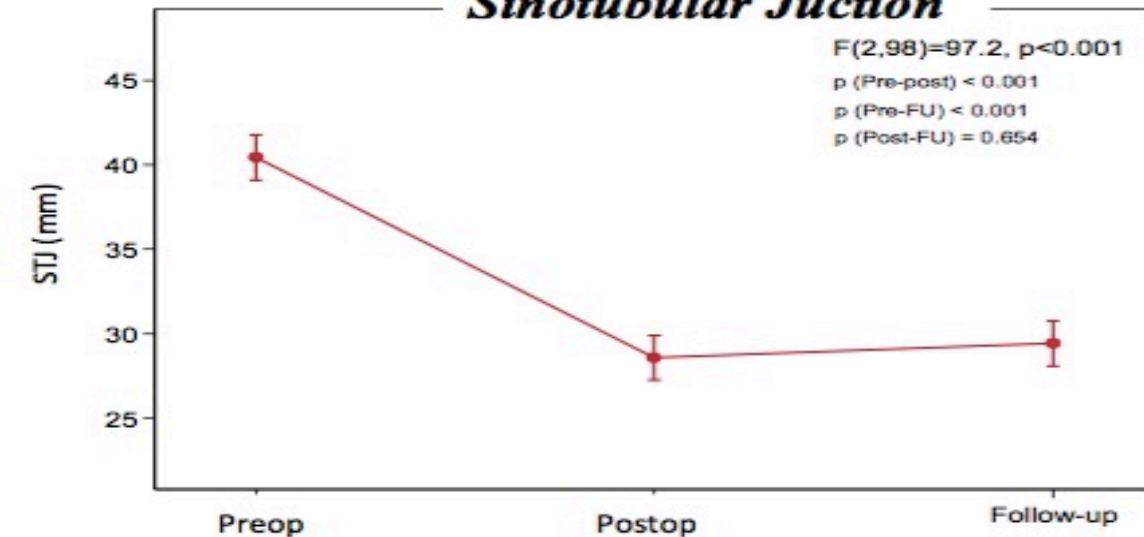
Anulus



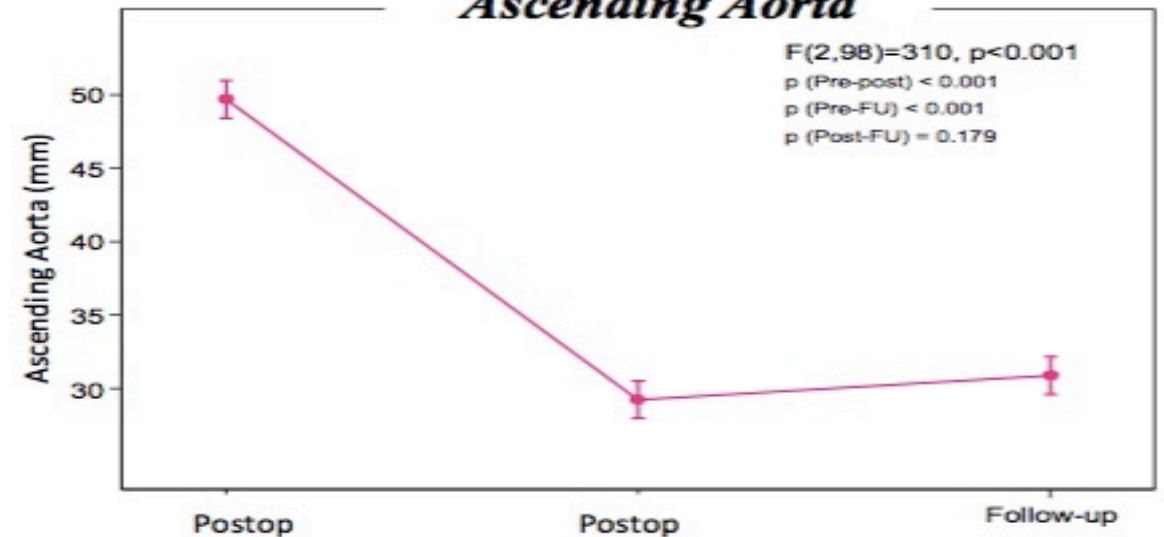
Bulbus



Sinotubular Junction



Ascending Aorta



Conclusions

- ✓ Preserving aortic root function is one of the most important factors influencing long term results in patients undergoing valve sparing operation.
- ✓ The sinuses of Valsalva play a key role in optimizing the aortic root haemodynamics during systole, minimizing energy losses during ejection.
- ✓ Our technique, by fixing the distance between the annulus and the commissures together with intercuspidal trigones, allows the tube graft to stretch vertically only between commissures and reimplanted leaflets with a greater degree at the nadir creating new sinuses.



Thank you !!!!!

