

TREATMENT OF SEVERE ATROPHIC MAXILLA WITH ZYGOMATIC IMPLANTS: A CASE SERIES

I. BALAN¹, M. DI GIROLAMO², D. LAURITANO³, F. CARINCI⁴

¹ Private practice in Israel

² Department of Clinical Sciences and Translational Medicine, University of Rome "Tor Vergata", Rome, Italy

³ Department of Medicine and Surgery, University of Milan-Bicocca, Milan, Italy

⁴ Department of Morphology, Surgery and Experimental Medicine, University of Ferrara, Ferrara, Italy

SUMMARY

Treatment of severe maxillary atrophy with implants has achieved important successes in recent years. The limit of implant insertion is related to inadequate bone quantity (i.e. height and width). Alveolar bone grafting, sinus lifting and major grafting via Le Fort I osteotomy have been used in the past to restore bone volume prior of implant insertion. However successes do not always occur and a second stage surgery is necessary in most cases. Immediate loading cannot be performed in all grafted bone. In recent years a new treatment approach has been proposed by using zygomatic implants. This new technique can provide a better stability to the prosthesis and less morbidity for patient. Here a cases series of eighteen patients rehabilitated with zygomatic together with standard implants and immediate loading is reported.

Key words: zygomatic implants, bone atrophy, severe resorbed maxilla, implant dentistry, bone.

Introduction

Treatment of severe maxillary atrophy with implants has achieved important successes in recent years (1, 2). The limit of implant rehabilitation is represented by inadequate bone height and width for which the treatment of severe atrophy shows still difficulties from the surgical and functional point of view (3-11). The severe atrophy of both maxilla and mandible causes further difficulties related to an inverse relationship between two jaws. Therefore, the correction of improper relationship of the bony bases is more complicated than a simple alveolar atrophy. When an edentulous maxilla is reabsorbed, the retention area of the total denture becomes narrower and shorter, since the anterior surface moves superiorly and dorsally, creating a form of the alveolar bone crest similar to a knife blade. The resorption of the edentulous maxilla determines a progressive loss of bone height,

thus reducing the volume of bone available for fixture placement and decreasing the bone quality, consequently increasing the risk of implant failure. When these phenomena happen, the vertical resorption of alveolar bone increases the inter-arch space. As the projection of the maxilla decreases in the sagittal plane, the spatial relationship between the maxilla and mandible changes, thus creating a pseudo-prognathism. This discrepancy between the two jaws creates problems both in the rehabilitation with removable or fixed prostheses. The jaws are resorbed till the muscle insertion causes a dislocation of the prosthesis and inhibit an adequate insertion of the implants. The combination of the loss of sagittal projection of the maxilla and a decrease in vertical height, results in a collapse of the soft tissues of the lower third of the face, therefore the patient experiences an aged expression, and the quantity of residual bone is unfavourable to the retention of the denture. Various processes have been designed to increase the volume of the

alveolar ridges and allow an adequate reconstruction of the dentition. Orthodontic surgical techniques have just been developed to restore the jaws in a correct skeletal position when a malocclusion occurs in dentate patients. The same procedures, such as the maxillary Le Fort I osteotomy, can be used in edentulous patients to correct the discrepancies between the jaws and restore an implant-supported dentition. Bone grafting procedures are frequently used to increase bone volume and place the implants in the same surgical time (12, 13). Sinus lifting and alveolar bone grafting are minor and well known techniques in oral surgery.

In recent years a new treatment has been proposed with zygomatic implants. This new technique can provide a better stability to the prosthesis and less morbidity for patient. Here a series of 18 patients treated with zygomatic implant in combination with standard fixture (Noris Medical, Israel) are reported and clinical outcome discussed.

Materials and methods

A series of eighteen patients with severe atrophy of maxilla were admitted at the Balan Clinic (Kiryat Yam, Israel) in the period between August and December 2013. There were 10 females and 8 males with a median age of 62 (min-max 36-86) all with general advanced periodontitis, most with complete edentulness. Half of patients had good general health and none was pregnant. Three patients had hypothyroidism, five have diabetes, one was affected by prostate cancer and one by cervical cancer.

The protocol is similar to that previously reported (14).

The surgery was performed under local anaesthesia with intravenous conscious sedation after antibiotic prophylaxis with amoxicillin and clavulanic acid (2 g) two hours before surgery.

Pre-operative medication protocol

One hour prior to dental surgery: 1 g Augmentin (amoxicillin and clavulanate potassium) for patients who are allergic to penicillin - 600 mg Dalacin (clindamycin); 12 mg dexamethasone (not for diabetics); 20 mg vaben (oxazepam); 100 mg Otarex (hydroxyzine hydrochloride); 2 tab narocin 275 mg (naproxen); 1 cap Losec 20 mg (omeprazole); probiotic.

Surgical protocol (Figures 1-6)

A palatal incision is made in the maxillary crest with a bilateral vertical posterior releasing incisions (like Le Fort I exposure). A muco-periosteal flap was reflected to expose the alveolar crest, the piriform opening, the central and posterior part of the zygomatic complex, the infraorbital nerve emergence and the lateral wall of the maxillary sinus. The retractor was then placed to separate the cheek, to guide the osteotomy and to protect the soft tissue from drilling. The compression of the infraorbital nerve with retractor must be avoided as well as the invasion of the orbit. Implant sites were prepared and guided positioning of the pterygoid and standard implants. Corticotomy of the anterolateral wall of the maxillary sinus was done. The antrostomy was performed with a diamond ball drill with a progressive diameter preserving and slightly detaching the sinus membrane. Following the inclination predisposed by the slot, the zygomatic implant beds were prepared under visual control using progressive-diameter drills with extra-oral access and alveolar zygomatic arch direction. Then zygomatic implants (Noris Medical, Israel) were then screwed manually. Afterwards standard implants were inserted in premaxilla. The definitive prosthesis was screwed using preformed abutments. Haemostasis control was followed by suturing of the surgical field.

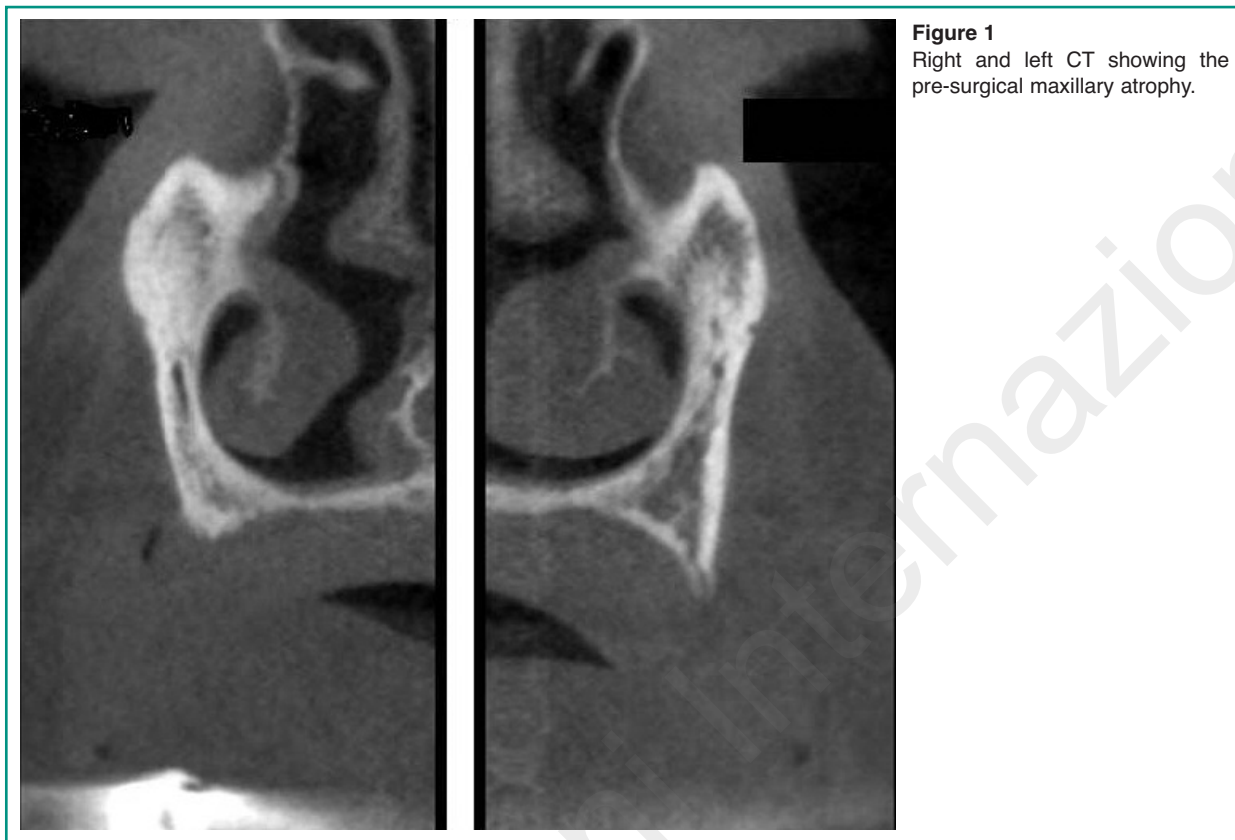


Figure 1
Right and left CT showing the pre-surgical maxillary atrophy.

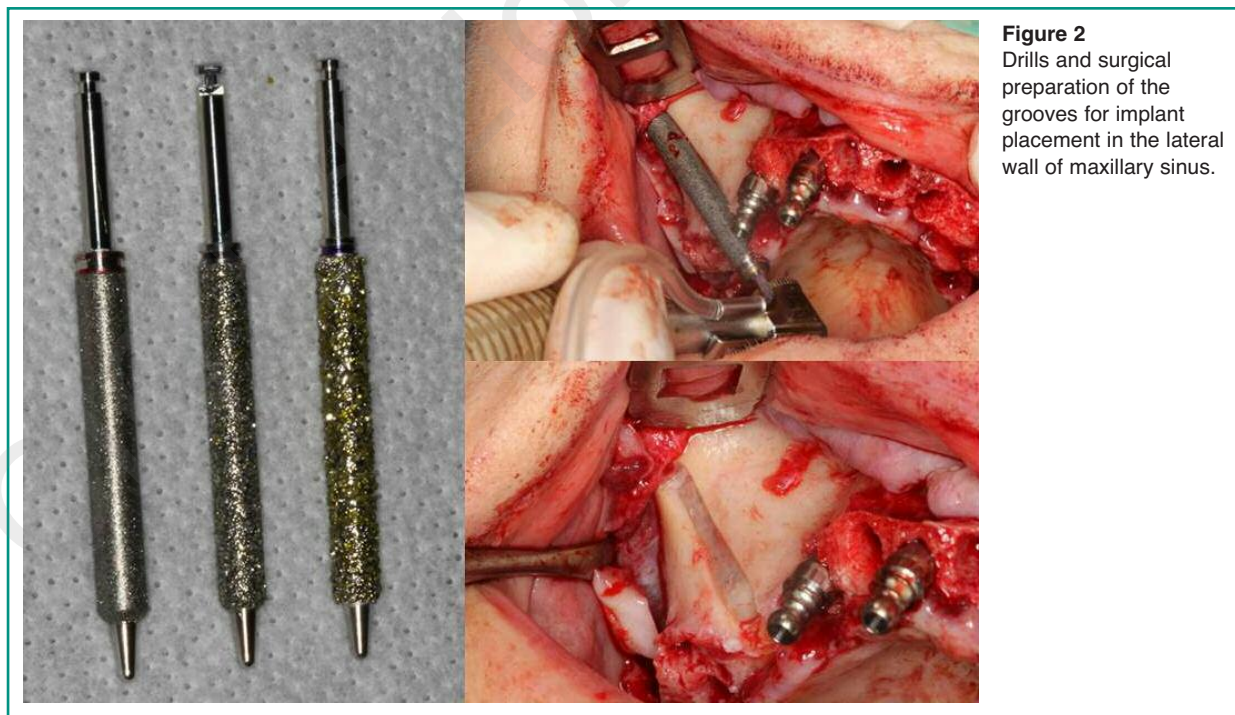


Figure 2
Drills and surgical preparation of the grooves for implant placement in the lateral wall of maxillary sinus.

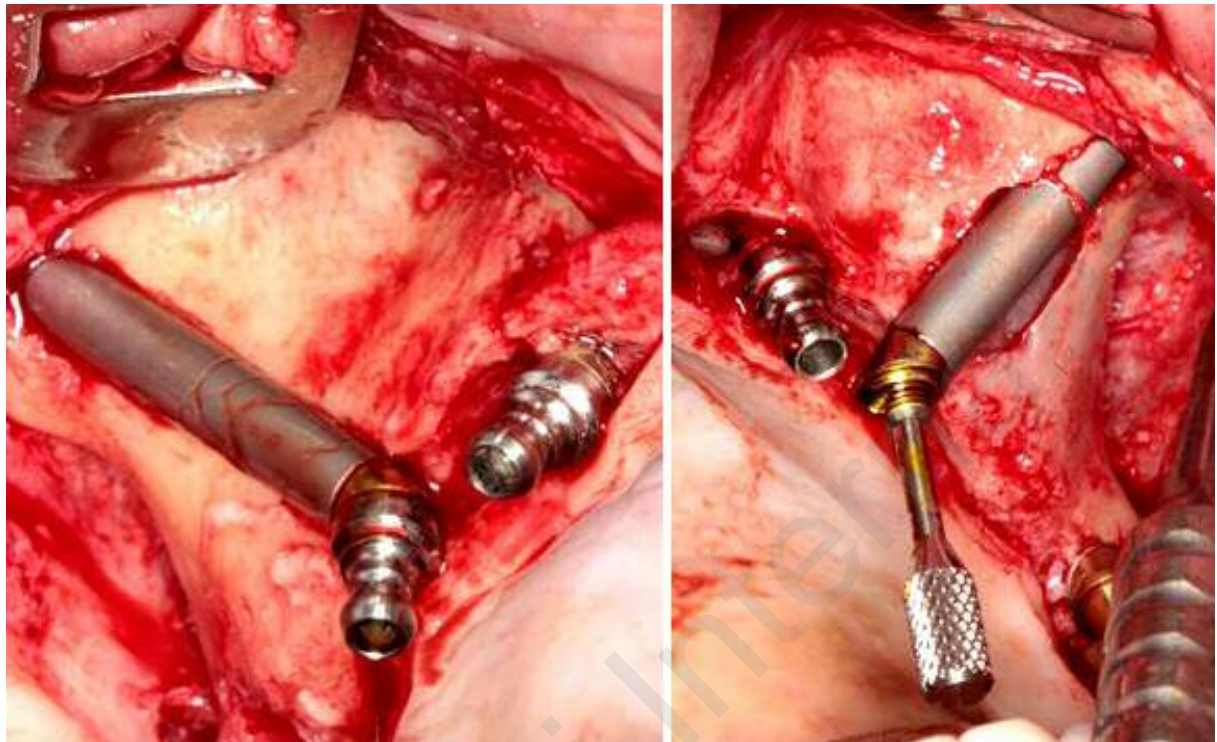


Figure 3
Right and left zygomatic implants inserted.

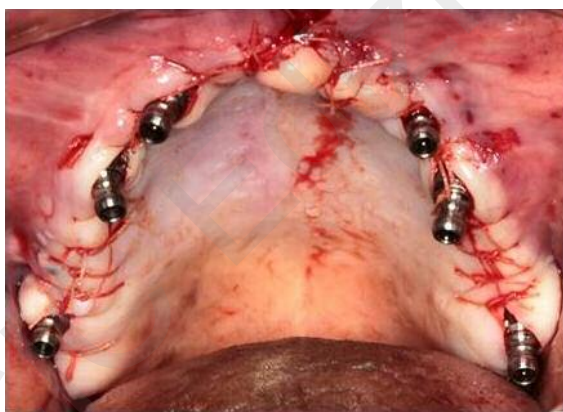

Figure 4
The operation field at the end of suture stitching.

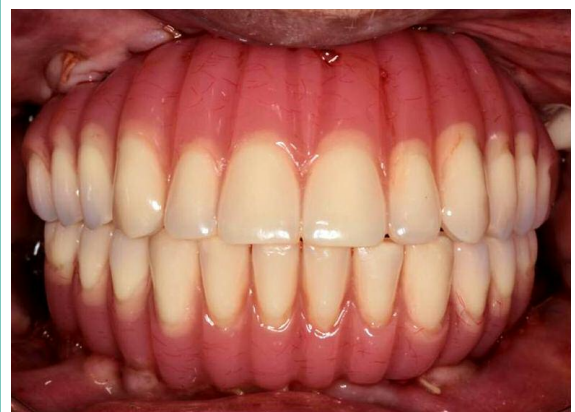


Figure 5
Fixed dentures in place.

Post-operative medication protocol: Antibiotics: Moxypen (amoxicillin) 500 mg 3 times a day/Augmentin 500/875 3 or 2 times a day/ Dalacin 300 mg

3 times a day, for 7 days; 0.12% chlorhexidine rinse for a month; 400 mg ibuprofen every 4 hours, if needed; dexamethasone, starting with 12 mg daily

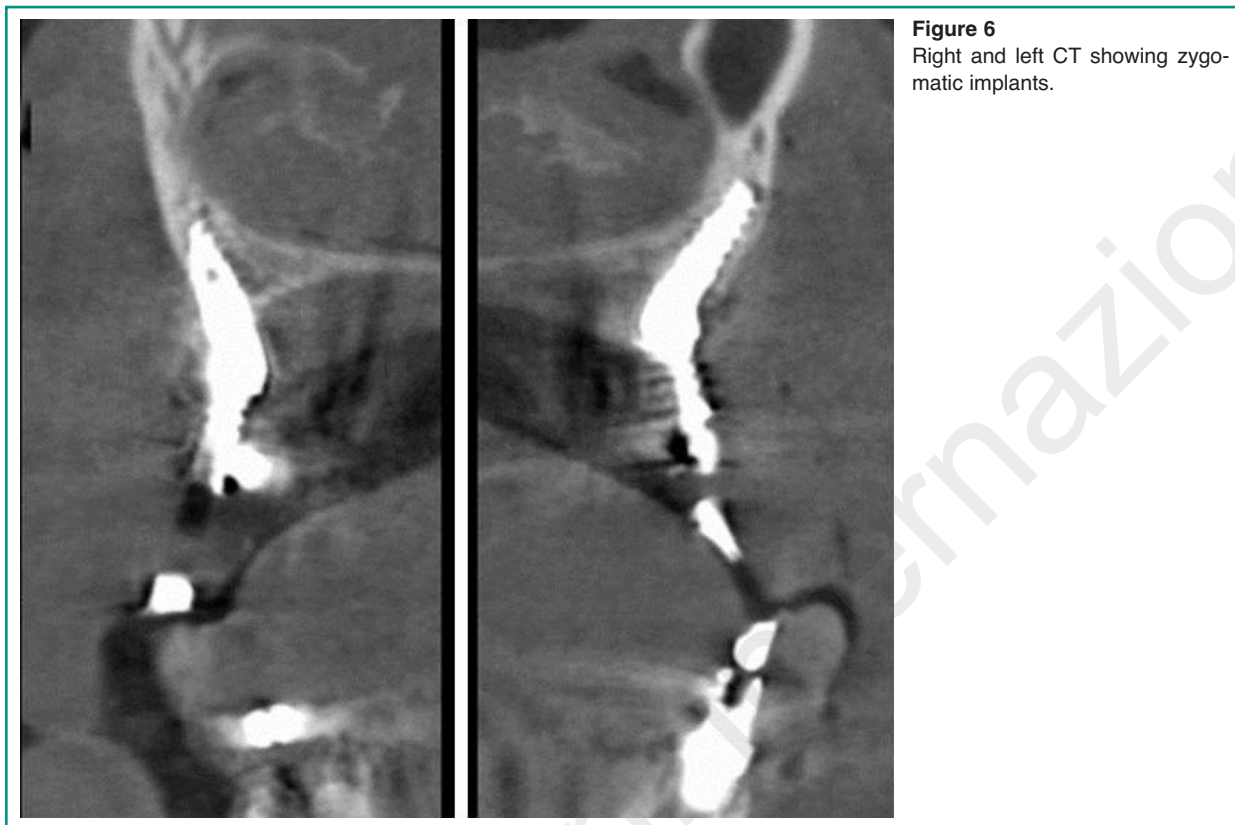

Figure 6
Right and left CT showing zygomatic implants.

and reducing 2 mg each following day, Botox (dilute according to manufacturer's instructions, divide to 6 doses, inject to the Masseter muscle in 3 points along the muscle, in each side).

By using the above mentioned technique a total of 29 zygomatic implants were inserted in the second pre-molar area of upper (left and/or right) maxilla. Additional 99 standard implants were inserted to restore the upper jaw (mean 5.5 implants per patient).

All patients agree to follow a strict oral hygiene protocol and recall. The post-operative period was uneventful and no soft tissue down-growth to interfere with the bone healing. The rehabilitation was successfully completed on all the implants with no adverse event reported by the patient.

Results

There were 10 females and 8 males with a medi-

an age of 62 (min-max 36-86). Half of them have a systemic diseases or major illness. A total of 29 zygomatic implants (Noris Medical, Italy) was inserted. In six cases ZI were single and place only in one side of upper maxilla. No one implant were lost after 12 months of follow-up. Provisional prosthesis was delivered the same day of surgery and patients have a great improvement in their quality of life.

Discussion

Maxillary atrophy is a hot topic of current implantology. Several different options were proposed over time, starting from simpli alveolar grats and sinus lifting to Le Fort I osteotomy combined with inlay bone block.

Zygomatic implants, introduced by Branemark in 1997 for the prosthetic rehabilitation of patients with serious and extended defects of the

jaws caused by post-oncological resections, trauma or congenital malformations, have proven over the years a valid alternative in the treatment of atrophy of the jaws, presenting high success rates (96% in 10 years) (15). The technique used in our study, implies the insertion of implants in the frontal portion of zygomatic bone, and the residual alveolar-basal bone as anchorage of standard implants, decreasing the biological cost of surgery, and improving the post-operative morbidity and the healing time. In the majority of cases, it is possible a rehabilitation of the maxilla with a denture, with 2 zygomatic implants in adjunction to traditional implantology of the pre-maxilla. Besides the success rate of zygomatic implants is above 80%, peri-implantitis may occurs in zygomatic rehabilitations also (16-21). Peri-implantitis and periodontal disease spring from bacterial infection that activates a cytokines cascade leading to inflammation and bone loss (22-25). In addition, the patient-related susceptibility is a critical factor for disease onset. So, every factor favouring oral biofilm formation (poor oral hygiene), host defence capability (smoking habit, excessive alcohol consumption, genetic traits, history of periodontitis, use of bisphosphonates), might favour developing of peri-implantitis and periodontal disease in zygomatic implants, which diagnosis and treatment require dentist's engagement (26, 27). Recently zygomatic implant solution has become popular since patients ask for therapies that offer a good final result while at the same time reduce costs, healing time and the temporary inability to work, as is the case of major grafting surgeries. So this procedure, that avoid big surgical field both for collecting and grafting bone, reduces the morbidity of treatment especially if one consider the advanced age of patients that request this treatment or type of pathology that determines the surgical indications such post-traumatic sequelae, post-oncological resections and severe malformations. In addition, bone grafting usually requires some time before fixtures and prosthesis can be loaded with consequent discomfort and limitation to social life.

In the recent literature there are few studies describing zygomatic implants to restore severe atrophic maxilla based on a large case series. Early publications on zygomatic implants were presented as case reports (28-38).

By considering our large case series, it became evident that the reconstruction of an atrophic jaw with zygomatic implants provide a good fine prosthetic solution while reduce the disadvantages related to a major surgery. In fact, it not only allow an immediate loading prosthetic rehabilitation but also restore the correct maxillary relationships and improve the aesthetics of the face. Among the most important advantages in using zygomatic implants are a more retentive denture-bearing ridge and a correct relationship between the two jaws. The use of zygomatic implants prevents problems related to potential bone resorption which usually happen after grafting.

In conclusion, oral rehabilitation of the maxilla with zygomatic implants can be used in selected patients, significantly shortened the time of rehabilitation with a reduction of adverse effects.

References

1. Schwartz JS, Tajudeen BA, Adappa ND, et al. Modified endoscopic medial maxillectomy for zygomatic implant salvage. *Allergy Rhinol (Providence)*. 2016;7: 147-150.
2. Atalay B, Doganay O, Saracoglu BK, et al. Clinical Evaluation of Zygomatic Implant-Supported Fixed and Removable Prosthesis. *J Craniofac Surg*. 2017;28:185-189.
3. Baj A, Trapella G, Lauritano D, et al. An overview on bone reconstruction of atrophic maxilla: success parameters and critical issues. *J Biol Regul Homeost Agents*. 2016;30:209-215.
4. Grecchi F, Perale G, Candotto V, et al. Reconstruction of the zygomatic bone with smartbone®: Case report. *Journal of Biological Regulators and Homeostatic Agents*. 2015;29:42-47.
5. Lauritano D, Avantaggiato A, Candotto V, et al. Insulin activity on dental pulp stem cell differentiation: An in vitro study. *Journal of Biological Regulators and Homeostatic Agents*. 2015;29:48-53.
6. Tettamanti L, Andreasi Bassi M, Trapella G, et al. Applications of biomaterials for bone augmentation of

- jaws: Clinical outcomes and in vitro studies. *ORAL and Implantology*. 2017;10:37-44.
7. Baj A, Sollazzo V, Lauritano D, et al. Lights and shadows of bone augmentation in severe resorbed mandible in combination with implant dentistry. *Journal of Biological Regulators and Homeostatic Agents*. 2016;30:177-182.
 8. Lauritano D, Avantaggiato A, Candotto V, et al. Effect of somatostatin on dental pulp stem cells. *Journal of Biological Regulators and Homeostatic Agents*. 2015; 29:54-58.
 9. Baj A, Muzio LL, Lauritano D, et al. Success of immediate versus standard loaded implants: A short literature review. *Journal of Biological Regulators and Homeostatic Agents*. 2016;30:183-188.
 10. Calcaterra R, Di Girolamo M, Mirisola C, et al. Effects of Repeated Screw Tightening on Implant Abutment Interfaces in Terms of Bacterial and Yeast Leakage in Vitro: One-Time Abutment Versus the Multiscrewing Technique. *Int J Periodontics Restorative Dent*. 2016;36:275-280.
 11. Calcaterra R, Pasquantonio G, Vitali LA, et al. Occurrence of *Candida* species colonization in a population of denture-wearing immigrants. *Int J Immunopathol Pharmacol*. 2013;26:239-246.
 12. Wang F, Monje A, Lin GH, et al. Reliability of four zygomatic implant-supported prostheses for the rehabilitation of the atrophic maxilla: a systematic review. *Int J Oral Maxillofac Implants*. 2015;30:293-298.
 13. Wen H, Guo W, Liang R, et al. Finite element analysis of three zygomatic implant techniques for the severely atrophic edentulous maxilla. *J Prosthet Dent*. 2014;111: 203-215.
 14. Grecchi F, Busato A, Grecchi E, et al. Surgically-guided zygomatic and pterygoid implants - a no-grafting rehabilitation approach in severe atrophic maxilla -A case report 2013;1.
 15. Tolman DE, Desjardins RP, Jackson IT, et al. Complex craniofacial reconstruction using an implant-supported prosthesis: case report with long-term follow-up. *Int J Oral Maxillofac Implants*. 1997;12:243-251.
 16. Lopez MA, Andreasi Bassi M, Confalone L, et al. Clinical outcome of 215 transmucosal implants with a conical connection: a retrospective study after 5-year follow-up. *J Biol Regul Homeost Agents*. 2016;30:55-60.
 17. Andreasi Bassi M, Lopez MA, Confalone L, et al. Clinical outcome of a two-piece implant system with an internal hexagonal connection: a prospective study. *J Biol Regul Homeost Agents*. 2016;30:7-12.
 18. Lopez MA, Andreasi Bassi M, Confalone L, et al. Retrospective study on bone-level and soft-tissue-level cylindrical implants. *J Biol Regul Homeost Agents*. 2016;30:43-48.
 19. Lopez MA, Andreasi Bassi M, Confalone L, et al. The influence of conical plus octagonal internal connection on implant survival and success rate: a retrospective study of 66 fixtures. *J Biol Regul Homeost Agents*. 2016;30:49-54.
 20. Andreasi Bassi M, Andrisani C, Lopez MA, et al. Endoscopically controlled hydraulic sinus lift in combination with rotary instruments: one-year follow-up of a case series. *J Biol Regul Homeost Agents*. 2016;30 (S2):21-28.
 21. Brunelli G, Carinci F, Zollino I, et al. Peri-implantitis. A case report and literature review. *European Journal of Inflammation*. 2012;10:1-5.
 22. Carinci F, Lauritano D, Cura F, et al. Prevention of bacterial leakage at implant-Abutment connection level: An in vitro study of the efficacy of three different implant systems. *Journal of Biological Regulators and Homeostatic Agents*. 2016;30:69-73.
 23. Scapoli L, Girardi A, Palmieri A, et al. Quantitative Analysis of Periodontal Pathogens in Periodontitis and Gingivitis. *J Biol Regul Homeost Agents*. 2015;29:101-110.
 24. Lauritano D, Martinelli M, Mucchi D, et al. Bacterial load of periodontal pathogens among Italian patients with chronic periodontitis: A comparative study of three different areas. *Journal of Biological Regulators and Homeostatic Agents*. 2016;30:149-154.
 25. Lauritano D, Cura F, Candotto V, et al. Periodontal Pockets as a Reservoir of *Helicobacter Pylori* Causing Relapse of Gastric Ulcer: A Review of the Literature. *J Biol Regul Homeost Agents*. 2015;29:123-126.
 26. Lauritano D, Muzio LLO, Gaudio RM, et al. The ecological catastrophe of oral diseases: A possible link between periodontitis and protozoa. *Journal of Biological Regulators and Homeostatic Agents*. 2016;30: 143-147.
 27. Lauritano D, Muzio LL, Gaudio RM, et al. Why should patients with systemic disease and tobacco smokers go to the dentist? *Journal of Biological Regulators and Homeostatic Agents*. 2016;30:135-141.
 28. Hinze M, Vrielinck L, Thalmair T, et al. Zygomatic implant placement in conjunction with sinus bone grafting: the "extended sinus elevation technique." a case-cohort study. *Int J Oral Maxillofac Implants*. 2013;28: e376-385.
 29. Bothur S, Kindberg H, Lindqvist J. The positions of implant heads in relation to the fixed dental prosthesis: a comparison of multiple zygomatic implants with standard implants for the reconstruction of the atrophic maxilla. *Int J Oral Maxillofac Implants*. 2012;27:664-670.
 30. Penarrocha M, Garcia B, Marti E, et al. Rehabilitation of severely atrophic maxillae with fixed implant-supported prostheses using zygomatic implants placed using the sinus slot technique: clinical report on a series of 21 patients. *Int J Oral Maxillofac Implants*. 2007; 22:645-650.
 31. Bedrossian E, Rangert B, Stumpel L, et al. Immediate function with the zygomatic implant: a graftless solution for the patient with mild to advanced atrophy of the

- maxilla. *Int J Oral Maxillofac Implants.* 2006;21:937-942.
32. Farzad P, Andersson L, Gunnarsson S, et al. Rehabilitation of severely resorbed maxillae with zygomatic implants: an evaluation of implant stability, tissue conditions, and patients' opinion before and after treatment. *Int J Oral Maxillofac Implants.* 2006;21:399-404.
33. Balshi TJ, Wolfinger GJ, Petropoulos VC. Quadruple zygomatic implant support for retreatment of resorbed iliac crest bone graft transplant. *Implant Dent.* 2003; 12:47-53.
34. Gasparini G, Boniello R, Lafori A, et al. Navigation System Approach in Zygomatic Implant Technique. *J Craniofac Surg.* 2017;28:250-251.
35. Gonzalez-Garcia R, Monje A, Moreno-Garcia C, et al. Endoscopically-Assisted Zygomatic Implant Placement: A Novel Approach. *J Maxillofac Oral Surg.* 2016;15:272-276.
36. Dawood A, Collier J, Darwood A, et al. The reverse zygomatic implant: a new implant for maxillofacial reconstruction. *Int J Oral Maxillofac Implants.* 2015; 30:1405-1408.
37. Camargos Gde V, Do Prado CJ, Saad PA, et al. Zygomatic Implant Options for the Atrophic Maxilla: Case Report. *Dent Today.* 2015;34:64-65.
38. Pia F, Aluffi P, Crespi MC, et al. Intraoral transposition of pedicled temporalis muscle flap followed by zygomatic implant placement. *J Craniofac Surg.* 2012; 23:e463-465.

Correspondence to:

Dorina Lauritano, DDS
Department of Medicine and Surgery
University of Milano Bicocca
Via Cadore 48
20052 Monza, Italy
Phone: +39.0392332301
Fax: +39. 03923329892
E-mail: dorina.lauritano@unimib.it