

Prolactin Secreting Pituitary Microadenoma: Results of Transsphenoidal Surgery After Medical Therapy With Dopamine Agonist

Mario Francesco Fraioli, PhD,* Giuseppe Umana, MD,* Andrea Pagano, MD,*
Bernardo Fraioli, PhD,* and Pierpaolo Lunardi, PhD[†]

Abstract: Medical therapy with dopamine agonist is very effective in controlling prolactin serum levels and it usually represents the first therapeutic choice for prolactin secreting pituitary adenomas. However, many patients present increase of prolactinemia after withdrawal of medical therapy which consequently should be taken for long time; other present intolerance to medical therapy; women with pregnancy need to withdraw dopamine agonists with consequent potential related problems: in these patients transsphenoidal surgery can be requested. The presented study concerns the efficacy of transsphenoidal surgery in patients affected by microprolactinoma after treatment with medical therapy for different periods of time. Different postsurgical results were achieved in 2 groups of 24 (group 1) and 25 (group 2) patients affected by microprolactinoma who had taken medical therapy for a period of time respectively longer or shorter than 1 year. In summary, the authors observed in group 1 a rate of hormonal remission of 33.3% and an overall prolactinemia improvement with possibility of medical therapy withdrawal in 49.9% of patients. In group 2, the authors observed a rate of hormonal remission of 84% and an overall rate of improvement with no necessity of medical therapy of 92%. Therefore, the authors' experience showed that the surgical option for the therapy of microprolactinomas should be indicated within 1 year from the beginning of medical therapy with dopamine agonist, to achieve a high rate of hormonal remission and possibility to withdraw medical therapy. The authors' protocol for microprolactinoma treatment is presented.

Key Words: Dopamine agonists, microprolactinomas, pituitary gland, transsphenoidal surgery

(*J Craniofac Surg* 2017;00: 00–00)

Medical therapy with dopamine agonist is very effective in controlling prolactin serum levels and it usually represents the first therapeutic choice for prolactin-secreting pituitary

adenomas.^{1–6} However, many patients treated by medical therapy present increase of prolactinemia after withdrawal of medical therapy,^{7,8} which consequently has to be administered for long time.⁹ We present the different postsurgical results of 2 groups of patients affected by pituitary microprolactinoma, who had performed previous medical therapy for a period of time respectively shorter or longer than 1 year. According to the achieved results, our therapeutic protocol for pituitary prolactin-secreting microadenoma is indicated.

METHODS

Two groups of 24 and 25 patients affected by microprolactinoma operated by transsphenoidal approach from 2000 through to 2010 in the same Institute (Department of Neurosciences, Neurosurgery, University of Rome Tor Vergata), by the first author (MFF) and the senior author (BF), are presented. Prolactin assay concerned exclusively the basal prolactin (ng/mL). In all patients pretreatment and preoperative basal prolactin level was higher than 100 ng/mL and less than 200 ng/mL. Size of the microadenomas was included between 3 and 9 mm of maximum diameter; extension was purely intrasellar without invasion of cavernous sinus: this aspect was considered very important, because when cavernous sinus is invaded, in our experience the neurosurgeon should not take the risks of very important neurological deficits for the removal of intracavernous tumour component, but medical therapy and radiosurgery should be considered. All the patients present a clear magnetic resonance imaging (MRI) finding suggestive for microadenoma (Fig. 1). Only young patients were considered, between 17 and 48 years old (average 32.1 years). Postoperative results were evaluated according to the postoperative prolactin serum levels, which were the most important parameter to define clinical-hormonal remission, because postoperative MRI presented the common postsurgical findings that did not allow certainly identifying an eventual postoperative tumoral remnant. All the patients had performed previous medical treatment with dopamine agonist, cabergoline in 39 and bromocriptine in 10 patients. Patients who had performed medical therapy for more than 1 year and less than 1 year were included in group 1 and group 2 respectively. In all patients therapy with dopamine agonists was discontinued from 2 to 3 months before surgery.

Surgery was performed in all patients through a minimally invasive submucosal microsurgical endoscope-assisted approach through 1 nostril. Suprasellar cisternal plane was not damaged in any patient so that no intraoperative cerebrospinal fluid fistula occurred. We selected a homogeneous cohort of patients with initial prolactin levels less than 200 ng/mL; in fact, it is known that high preoperative prolactin levels, over 200 ng/mL according to some authors,^{10–13} are an important factor that inhibits hormonal remission, while our study was focused on assessing as well as possible the influence of the previous medical therapy alone on prolactin levels.

No significant differences were found in patients treated with cabergoline or bromocriptine.

From the *Department of Neurosciences, Neurosurgery, University of Rome Tor Vergata; and †Department of Diagnostic for Imaging and Radiotherapy, CIRAD of Rome, Rome, Italy.

Received November 14, 2016.

Accepted for publication January 7, 2017.

Address correspondence and reprint requests to Mario Francesco Fraioli, Department of Neurosciences, Neurosurgery, University of Rome Tor Vergata, via Oxford 81, 00133, Rome, Italy; E-mail: mff77@libero.it

The authors report no conflicts of interest.
Copyright © 2017 by Mutaz B. Habal, MD
ISSN: 1049-2275

DOI: 10.1097/SCS.0000000000003663

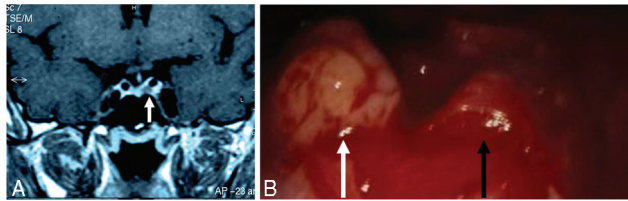


FIGURE 1. (A) T1-weighted magnetic resonance image of microprolactinoma in the left side of pituitary gland (white arrow); microadenoma appears hypointense in the context of pituitary gland. (B) Intraoperative microsurgical view of the same prolactinoma of (A) (white arrow), well distinguished from the pituitary gland (black arrow).

Group 1

Represented by 24 patients, 19 females and 5 males, of age between 18 and 45 years (average 34.8 years) who had taken medical therapy (cabergoline or bromocriptine in 18 and 6 patients respectively) for a period longer than 1 year. Two patients were submitted to transsphenoidal surgery after 16 and 19 months respectively because of intolerance to the drug; 12 other patients were operated after a period of medical treatment between 27 and 48 months, other 8 in a period between 5 and 7 years, and the 2 last patients after a period of medical therapy of 9 and 10 years respectively. Patients or endocrinologists requested surgery after prolonged time of medical therapy because of prevision of pregnancy in 10 patients and need to withdraw cabergoline, because of onset of intolerance in 7 other, because of reduced therapeutic effectiveness in the last 7 patients. At surgery, in 20 (83.3%) patients the microadenoma presented fibrous consistence and it was not removable by suction; differently, it presented soft consistency and was removable by suction in 4 patients (16.7%) who had taken medical therapy respectively for 16, 27, 34, and 41 months.

Group 2

Represented by 25 patients, 22 females and 3 males, with age between 17 and 48 years (average 37.6 years), who had all taken medical therapy for a period shorter than 11 months: in 8 patients medical therapy had been suspended because of side effects occurring after few weeks, in the other 17 it was suspended in accordance with the endocrinologist and the patient, to achieve higher rate of success of surgical intervention and so withdrawal of medical therapy. At surgery, the microadenoma presented fibrous consistency in only 2 patients (8%).

RESULTS

Histological examination revealed prolactin (PRL) adenoma cells in 44 patients (group 1: 22 patients; group 2: 22 patients), while PRL hyperplasia cells resulted in the other 5 (group 1: 2 patients; group 2: 3 patients). Prolactin controls were performed after 1, 3, and 6

months after surgery; PRL levels after 1 month were not significantly different from PRL controls after 3 and 6 months.

Group 1

In all 24 patients total removal was accomplished according to operator’s opinion (microscopic/endoscopic operative view). Post-operative prolactin blood levels, performed after 1, 3, and 6 months, resulted in the normal range in 8 patients (33.3%) who had taken medical therapy respectively for an average period of 29.1 months (range 16–41 months) (Table 1). Recurrence of hyperprolactinemia occurred in 1 patient (4.1%) after 4.5 years, during an average follow-up period of 7.3 years, and the patient was submitted again to medical therapy. Improvement of hyperprolactinemia with postoperative prolactin levels less than 70 ng/mL and no necessity to restart medical therapy because of regression of related symptoms, was registered in 4 patients (16.6%) who had taken medical therapy for an average period of 39.7 months (range 19–48 months); during an average follow-up period of 6.2 years, increase of prolactinemia did not occur. Ten patients (41.6%) who had taken medical therapy for an average period of 68.6 months (range 39–108 months) presented improvement of hyperprolactinemia and improvement of related symptoms, but in all patients resumption of medical therapy was necessary, although at a lower dosage than in the preoperative period. No improvement was achieved in the last 2 patients (8.3%) who had taken medical therapy for 6, 9, and 10 years respectively; they were submitted again to medical therapy that maintained blood prolactin dosage under 100 ng/mL with satisfactory symptoms control.

Group 2

In 21 patients (84%) postoperative prolactinemia was in the normal range and in other 2 (8%) it was less than 45 ng/mL (Table 2) with absence of related disturbances; no increase of prolactinemia occurred during an average follow-up period of 4.2 years. In the last 2 patients (8%) postoperative prolactinemia was less than 78 ng/mL and only 1 of them required resumption of medical therapy although at a reduced dosage than the preoperative period.

DISCUSSION

Prolactin Secreting Pituitary Macroadenomas

Young patients affected by macroprolactinomas were not considered in this study because in these patients we propose transsphenoidal surgery, as other authors,¹⁴ because with this miniminvasive operation we can remove the tumor and decompress optic chiasm and the residual pituitary gland that could be (or could become) hypofunctioning because of the compression by the tumor,¹⁵ and in young women seeking fertility the problem of potential tumor enlargement during pregnancy can be avoided.¹⁶

TABLE 1. Group 1 of 24 Patients

	Hormonal Remission	Improvement and Withdrawal of Medical Therapy	Improvement but Necessity of Medical Therapy	No Improvement	Evidence of Total Resection at MRI
Medical therapy < 2 y	1	1			0
Medical therapy for 2 to 4 y	7	3	2		5
Medical therapy for 5 to 7 y			7	1	1
Medical therapy for 9 to 10 y			1	1	0

Results of transsphenoidal surgery after medical therapy with dopamine agonist for a period longer than 1.5 y. MRI, magnetic resonance imaging.

TABLE 2. Group 2 of 25 Patients

	Hormonal Remission	Improvement and Withdrawal of Medical Therapy (Postop PRL Less Than 45 ng/mL)	Improvement but Necessity of Medical Therapy (Postop PRL Less Than 78 ng/mL)	No Improvement	Evidence of Total Resection at MRI
Medical therapy < 1 y	21	3	1	—	18

Results after transsphenoidal surgery in 25 patients affected by microprolactinomas who had assumed medical therapy less than 1 y.
MRI, magnetic resonance imaging.

Pregnancy

Surgery is very useful in female patients affected by prolactinomas who planned to have a pregnancy; in this condition, it is usually indicated to withdraw cabergoline, although some authors reported no side effects during pregnancy but these authors themselves¹⁷ reported the necessity of results on a larger number of pregnancies. Moreover, withdrawal is recommended by the production pharmaceutical company. During pregnancy and lactation, the adenoma could grow (as well as the physiologic growth of the pituitary gland during pregnancy), it could present hemorrhagic event with acute optic nerves compression or pituitary apoplexy or cranial nerve deficits with necessity of emergency operations.¹⁶

Analysis of Results

On the basis of our results, it is clear that, after surgery, hormonal remission occurred in 84% of group 2 patients, while it was achieved only in 33% of group 1 patients. Moreover, in group 2 patients we observed that persistence of hyperprolactinemia, even if improved, without necessity of taking again medical therapy because of absence of related symptoms, occurred in 3 of 4 patients (75%). Conversely, in group 1 only 4 of 14 patients (28.57%) who presented persistence of hyperprolactinemia had no necessity to restart medical therapy, while 10 of 14 patients (71.4%) were submitted again to medical therapy after surgery, although prolactin serum level improvement had occurred after surgery.

Moreover, it is evident that a longer presurgical medical treatment corresponded to a higher persistency of hyperprolactinemia (Table 1) and to a higher necessity to restart medical therapy. It is evident that protracted medical therapy modifies consistency of the adenoma which progressively becomes fibrous and difficult to remove.

Therapeutic Protocol for Microprolactinoma

Our results show that transsphenoidal surgery allows very good results on hormonal remission when previous medical therapy has been taken for a period of time less than 1 year, and it presents progressive lower effectiveness when medical therapy has been protracted for a period longer than 1 year. So, our indications for the treatment of microprolactinomas in young patients plan to take medical therapy for a period of 6 to 8 months and to control serum prolactin levels after 1 and 4 months; afterward, 1 month after withdrawal of medical therapy, MRI and serum prolactin levels controls are performed: if reduction or disappearance of the microadenoma at the MRI and hormonal remission are evident, serial serum prolactin levels control and MRIs are performed. If microadenoma is unchanged or increased, and there is again hyperprolactinemia, 2 strategies are indicated to the patients: the first one, suggested in our Institute, plans to perform transsphenoidal surgery with a very high rate of hormonal remission and very low rate of recurrence; the second strategy plans to continue medical therapy that probably should be performed for many years, and the patient is

informed that a successive surgical operation, after 1 year and more, presents a progressive lower rate of hormonal remission.

In conclusion, the presented study showed that the surgical option for the therapy of microprolactinomas should be indicated within 1 year from the beginning of medical therapy with dopamine agonist, to achieve major rate of hormonal remission and possibility to withdraw medical therapy; hormonal remission after transsphenoidal surgery is strictly related to the length of period of preoperative medical therapy; better results were achieved when dopamine agonists had been taken less than 12 months.

REFERENCES

- Colao A, Savastano S. Medical treatment of prolactinomas. *Nat Rev Endocrinol* 2011;7:267–278
- Gökalp HZ, Deda H, Attar A, et al. The neurosurgical management of prolactinomas. *J Neurosurg Sci* 2000;44:128–132
- Hamilton DK, Vance ML, Boulos PT, et al. Surgical outcomes in hyporesponsive prolactinomas: analysis of patients with resistance or intolerance to dopamine agonists. *Pituitary* 2005;8:53–60
- Molitch ME. Prolactin-secreting tumors: what's new? *Expert Rev Anticancer Ther* 2006;6(suppl 9):S29–S35
- Vance ML. Medical treatment of functional pituitary tumors. *Neurosurg Clin N Am* 2003;14:81–87
- Zacur HA. Indications for surgery in the treatment of hyperprolactinemia. *J Reprod Med* 1999;44(12 suppl):1127–1131
- Anagnostis P, Adamidou F, Polyzos SA, et al. Long term follow-up of patients with prolactinomas and outcome of dopamine agonist withdrawal: a single center experience. *Pituitary* 2011;15:22–29
- Kharlip J, Salvatori R, Yenokyan G, et al. Recurrence of hyperprolactinemia after withdrawal of long-term cabergoline therapy. *J Clin Endocrinol Metab* 2009;94:2428–2436
- Wolfsberger S, Czech T, Vierhapper H, et al. Microprolactinomas in males treated by transsphenoidal surgery. *Acta Neurochir (Wien)* 2003;145:935–940
- Abe T, Lüdecke DK. Transnasal surgery for prolactin-secreting pituitary adenomas in childhood and adolescence. *Surg Neurol* 2002;57:369–379
- Nomikos P, Buchfelder M, Fahlbusch R. Current management of prolactinomas. *J Neurooncol* 2001;54:139–150
- Tyrrell JB, Lamborn KR, Hannegan LT, et al. Transsphenoidal microsurgical therapy of prolactinomas: initial outcomes and long-term results. *Neurosurgery* 1999;44:254–263
- Watanabe S, Takano S, Akutsu H, et al. Prolactinoma treatment status in the cabergoline era. *No Shinkei Geka* 2011;39:1045–1054
- Acquati S, Pizzocaro A, Tomei G, et al. A comparative evaluation of effectiveness of medical and surgical therapy in patients with macroprolactinoma. *J Neurosurg Sci* 2001;45:65–69
- Sibal L, Ugwu P, Kendall-Taylor P, et al. Medical therapy of macroprolactinomas in males: I. Prevalence of hypopituitarism at diagnosis. II. Proportion of cases exhibiting recovery of pituitary function. *Pituitary* 2002;5:243–246
- Klibanski A. Prolactinomas: clinical practice. *N Engl J Med* 2010;362:1219–1226
- Lebbe M, Hubinont C, Bernard P, et al. Outcome of 100 pregnancies initiated under treatment with cabergoline in hyperprolactinaemic women. *Clin Endocrinol (Oxf)* 2010;73:236–242