

Surgical repair of isolated triceps tendon rupture using a suture anchor technique: a case report

FEDERICO MANCINI, GABRIELE BERNARDI, VINCENZO DE LUNA, COSIMO TUDISCO

Department of Orthopaedics and Traumatology, Policlinico Tor Vergata, Rome, Italy

Abstract

Rupture or avulsion of the distal triceps tendon is one of the least common tendon injuries. The most common clinical presentation of the injury is avulsion from the olecranon. The diagnosis of acute triceps tendon rupture may be missed and this can result in prolonged disability.

We report the case of a 42-year-old man with isolated triceps rupture treated by an open surgical repair technique involving the use of bone suture anchors.

Keywords: triceps, tendon, repair, rupture, suture anchor.

Introduction

Rupture of the triceps tendon is rare and it is the least common of all tendon injuries. In a review of 1,014 tendon ruptures, less than 1% affected the triceps tendon (1). According to an English literature search of the PubMed and OVID databases, partial and complete triceps tendon ruptures (TTRs) have been reported in 39 and 40 cases, respectively (2).

Various factors can alter the structural integrity of the triceps tendon and decrease its load capacity; however, ruptures can occur spontaneously in patients with healthy tissue and no predisposing conditions (2, 3). The principal mechanism of triceps tendon injury is falling on an outstretched hand, although direct poste-

rior force on the elbow and weightlifting are also common injury mechanisms. Leaving aside direct trauma, the biomechanics of the injury are similar for each mechanism: uncoordinated contraction of the triceps against a flexed elbow, combined with a deceleration-type impact, eccentrically overloads the tendon (3, 4). These ruptures can be complete or incomplete and can involve different anatomical regions. Some occur proximally at the origin of the lateral head of the triceps, some occur through the triceps muscle belly, musculotendinous junction, or tendon per se, while others consist of an avulsion from the olecranon. Reports of musculotendinous junction and intramuscular tears are, in fact, rare and TTRs typically occur at the insertion point on the olecranon; most full ruptures also include a bony avulsion of the olecranon (3, 4). The best treatment for partial TTRs is still debated and healing of the rupture can be achieved conservatively or through surgical repair. Instead, complete TTRs (but also partial TTRs in high functional demand patients) should always be treated surgically, as reported in the literature (5).

We report a case of solitary triceps rupture treated with an open surgical repair technique involving the use of bone suture anchors.

Case report

A 42-year-old man presented to the emergency department of our hospital with pain and functional impairment in his left elbow after landing on it while playing football (as a goalkeeper). Clinical examination revealed diffuse swelling, tenderness and ecchymosis in the region of the left elbow. A definite gap was palpable just above the olecranon and absence of active elbow extension was clearly evident. A lateral radiograph of the elbow showed a small flake fragment

Corresponding Author:

Gabriele Bernardi, MD
Department of Orthopaedics and Traumatology,
Policlinico Tor Vergata
Viale Oxford 81, 00133 Rome, Italy
E-mail: bernardi_gab@libero.it

posterior to the olecranon fossa (**Fig. 1**). Considering the presence of the bone flake on the lateral X-ray, the palpable gap and the ecchymosis in the posterior elbow, together with the complete elbow extension deficit, we were able to diagnose complete TTR, and magnetic resonance imaging (MRI) was not deemed necessary. Six hours after the trauma surgery was undertaken. With the patient under regional anesthesia and a tourniquet applied, a straight posterior incision was made.

A complete rupture of the distal insertion of the triceps tendon was found. The tendon was soft, and degenerated at its extremity with some bone fragments embedded in it. After debridement of the distal aspect of the tendon and olecranon cortex and removal of the bone flakes, the rupture was repaired by placing two 2.9 mm soft anchors (Jugger Knot Soft Anchor; Biomet Sports Medicine, Warsaw, IN, USA) in the olecranon and using a transosseous suture of the tendon with a # 2 permanent braided suture (Ethibond; Ethicon, Somerville, NJ, USA) (**Fig. 2**).

The elbow was immobilized at 45° of flexion with a brachial plaster splint. Isometric exercises were allowed up until the third postoperative day, and were followed by three weeks of progressive active flexion with a brace to control mobility.

After 4 months of passive and active motion exercises, full range of motion of the elbow was obtained, the brace was discontinued and active contraction of the triceps began. After six months, full range of painless joint mobility and complete recovery of muscle strength were observed. Even though no therapy to

prevent heterotopic ossification was prescribed, at the most recent radiographic follow-up (nine months post-op), no ossification was observed around the site of the rupture.

Discussion

The diagnosis of acute TTR is difficult and can easily be missed because of the low degree of suspicion of triceps rupture. In addition, the pain in the acute injury

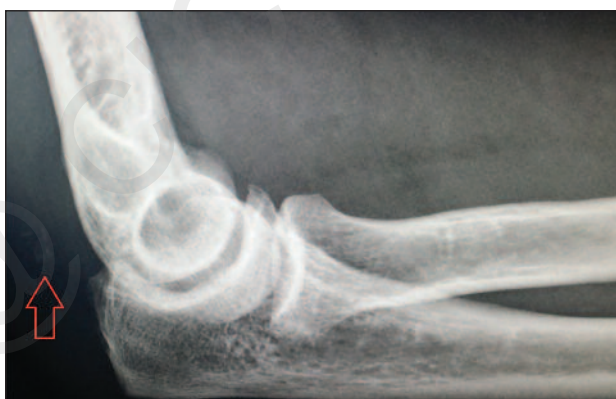

Figure 1. Radiograph of the elbow on admission shows a flake-like fragment proximal to the tip of the olecranon on lateral view (red arrow).

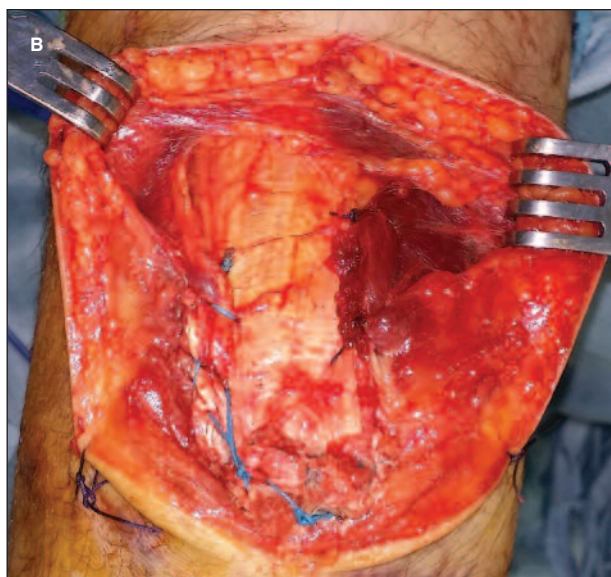
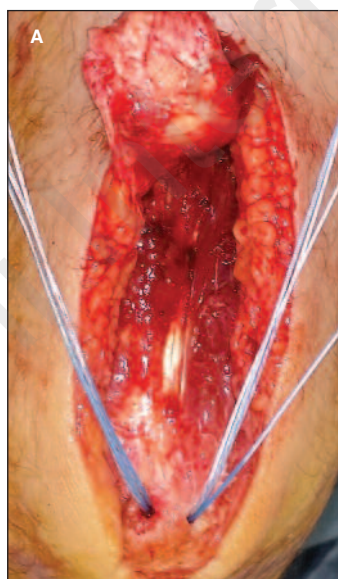


Figure 2. The rupture was repaired by placing two soft anchors at the tip of the olecranon (A) and the repair was reinforced by an osseous/periosteal suture with number 2 Ethibond (B).

prevents appropriate physical examination, such as active elbow extension. TTRs may be partial or complete, with or without associated fractures. The common differential diagnoses of elbow injuries include elbow sprain, radial head fracture, olecranon bursitis and fractures around the elbow joint (3). Likewise, swelling could impede palpation of the gap.

Furthermore, in a busy emergency room, it is easy to miss tiny avulsed flecks of bone, and TTR may be overlooked during the initial examination in 45% of cases (6). In doubtful cases, the use of MRI or ultrasound scanning (US) of the elbow is recommended to confirm the lesion.

In our case, active elbow extension was absent and TTR was suspected due to the presence of extensive swelling and ecchymosis of the elbow together with a palpable gap in the posterior elbow, which complied with descriptions in the literature (2). When incomplete ruptures occurred, the central portion was involved occasionally leaving medial and/or lateral peripheral attachments intact. In view of the presence of a palpable gap and the local ecchymosis present on physical examination, the bone flake revealed by the lateral X-ray and the loss of elbow extension, it was not considered necessary to perform an MRI or US scan. We preferred to take the patient directly to the operating room, rather than waiting to perform radiological examinations, which could not be done in the emergency department.

Generally, primary repair should be performed within two weeks of the injury, although successful repairs performed several months after injury have been reported (5). The most common surgical method of treating a TTR is to anchor the triceps tendon to the tip of the olecranon with non-absorbable/absorbable or wire suture materials passed through tunnels drilled in the bone (3, 5, 6). The suture anchor technique is less commonly used for primary repair and, when described, suture anchors are placed in the middle of the tendon footprint and tied to locking stitches made on each side of the tendon. Yeh et al. (7) recently described a modified “anatomic” technique combining suture anchors and transosseous tunnels made in the olecranon. The results indicated greater anatomical footprint coverage, resistance to cyclic loading, and prevention of tendon breakdown when compared with the transosseous or anchor methods alone. In the current case, surgical treatment included transosseous

repair of the triceps tendon with two 2.9 mm non-absorbable Juggerknot soft anchors drilled in the top of the olecranon thereby allowing the tendon to be anchored at its original insertion. Anchors of this type require much smaller drill holes and they are as strong as, or stronger than, much longer anchors. Thus, these anchors necessitate less bone removal and allow multiple points of fixation when anchoring soft tissue to bone, and they also provide high pullout strength. Consisting of a soft tissue system, they do not have rigid components internally, they avoid the possibility of loose bodies in the joint, they allow blood to repair the rupture, they do not interfere with MRI, and they facilitate revision surgery. Their use resulted in a very stable repair, allowing the achievement of an intraoperative range of motion from full extension to 90° of flexion. Six months after the surgery, the patient had recovered completely and regained full strength of his left triceps.

Conclusions

Although good results have been reported with the use of metallic hardware to reinsert the avulsed triceps tendon, the use of much smaller, soft anchors can decrease the likelihood of postoperative complications, such as symptomatic hardware needing to be removed; furthermore, these anchors do not interfere with possible subsequent MRI scans.

References

1. Anzel SH, Covey KW, Weiner AD, et al. Disruption of muscle and tendons: an analysis of 1,014 cases. *Surgery*. 1959;45:406-414.
2. Tom JA, Kumar NS, Cerynik DL, et al. Diagnosis and treatment of triceps tendon injuries: a review of the literature. *Clin J Sport Med*. 2014;24:197-204.
3. Harris PC, Atkinson D, Moorehead JD. Bilateral partial rupture of triceps tendon: case report and quantitative assessment of recovery. *Am J Sports Med*. 2004;32:787-792.
4. Vidal AF, Drakos MC, Allen AA. Biceps tendon and triceps tendon injuries. *Clin Sports Med*. 2004;23:707-722, xi.
5. van Riet RP, Morrey BF, Ho E, et al. Surgical treatment of distal triceps ruptures. *J Bone Joint Surg Am*. 2003;85-A:1961-1967.
6. Farrar EL 3rd, Lippert FG 3rd. Avulsion of the triceps tendon. *Clin Orthop Relat Res*. 1981;(161):242-246.
7. Yeh PC, Stephens KT, Solovyova O, et al. The distal triceps tendon footprint and a biomechanical analysis of 3 repair techniques. *Am J Sports Med*. 2010;38:1025-1033.