

HPV AND ORAL LESIONS: PREVENTIVE POSSIBILITIES, VACCINES AND EARLY DIAGNOSIS OF MALIGNANT LESIONS

D. TESTI¹, M. NARDONE², P. MELONE¹, P. CARDELLI³, L. OTTRIA³, C. ARCURI³

¹ Graduate School in Materials for Health, Environment and Energy, University of Rome "Tor Vergata", Rome, Italy

² Medical Director of the Health Professions, Ministry of Health, Rome, Italy

³ Department of Clinical Sciences and Translational Medicine, University of Rome "Tor Vergata", Rome, Italy

SUMMARY

The importance of HPV in world healthy is high, in fact high-risk HPV types contribute significantly to viral associated neoplasms.

In this article we will analyze vary expression of HPV in oral cavity both benign and malignant, their prevalence and the importance in early diagnosis and prevention. The classical oral lesions associated with human papillomavirus are squamous cell papilloma, condyloma acuminatum, verruca vulgaris and focal epithelial hyperplasia.

Overall, HPV types 2, 4, 6, 11, 13 and 32 have been associated with benign oral lesions while HPV types 16 and 18 have been associated with malignant lesions, especially in cancers of the tonsils and elsewhere in the oropharynx.

Transmission of the virus can occur with direct contact, genital contact, anal and oral sex; latest studies suggest a salivary transmission and from mother to child during delivery. The number of lifetime sexual partners is an important risk factor for the development of HPV-positive head-neck cancer. Oral/oropharyngeal cancer etiologically associated with HPV having an increased survival and a better prognostic (85%-90% to five years). There is no cure for the virus. There are two commercially available prophylactic vaccines against HPV today: the bivalent (16 and 18) Cervarix® and the tetravalent (6, 11, 16 and 18) Gardasil® and new vaccine Gardasil 9 (6, 11, 16, 18, 31, 33, 45, 52, 58) was approved in the United States. To be effective, such vaccination should start before "sexual puberty".

The vaccine could be an important preventive strategy, in fact the scientific community is in agreement on hypothesis that blocking the contagion it may also limit the distance complications as the oropharyngeal cancer.

Key words: HPV, vaccines, oral lesions, cancer, papilloma virus.

Introduction

Human Papilloma Virus (HPV) was been widely studied in genital infections conquering the first place in etiology of uterine cervix cancer.

Wide diffusion of HPV, caused by its simplicity of transmission had determinated the necessity of deep study of papilloma virus and its identification in other body district, also oral cavity.

The importance of HPV in world health is high, in fact high-risk HPV types contribute significantly to viral associated neoplasms, accounting for approximately 600,000 cases (5%) of cancers

worldwide annually (1).

Differently from cervix cancer, HPV plays pathogenic role only in a small part of oral cancer through the continue expression of viral oncogene necessary for the histopathologic progression of malignant cancer HPV associated.

Two proteins of HPV (E6 and E7) are the main responsible for cell transformation and malignant progression of cancer and so they are defined oncogene proteins (2). The action of oncogenic E6 and E7 proteins resides in the ability to inactivate two important tumor suppressor proteins, p53 and the retinoblastoma protein, pRb (3, 4).

A systematic meta-analysis reviewed the current

available literature in the field to determine the worldwide prevalence of HPV in Head and Neck Squamous Cell Carcinoma (HNSCC). Researchers analyzed 60 relevant studies using PCR detection from 26 countries. In all, 5,046 cases of SCCs (squamous cell carcinoma), 2,642 oral cancers, 969 oropharyngeal cancers, and 1,435 laryngeal cancers were studied. HPV prevalence was 35.6% in oropharyngeal cancers, 23.5% in oral cancers, and 24.0% in laryngeal cancers. The overall estimated prevalence of HPV in HNSCC was 26% (5).

In French retrospective multicenter study involved 12 centres located throughout the country it were included 185 histological samples collected from year 2000 to 2009 with a validated diagnosis of tonsil invasive carcinomas: HPV prevalence was 57% in tonsil cancers (6). Among the many high-risk HPV types, HPV-16 is the most common, found in almost 90% of the HPV(+) oropharyngeal cancers. At present, HPV-16 remains the only HPV type that is classified as cancer-causing in the head and neck (7).

For fairness, the Authors want to emphasize that results about the presence of HPV in Oral Squamous Cell Carcinoma (OSCC) were not the same in all studies, in fact in some studies the prevalence of HPV in OSCC was between 2-7% (8, 9).

The Human Papillomaviruses (HPVs) can be broadly grouped into cutaneous and mucosotropic types. The mucosotropic HPVs are typically found in the anogenital mucosa and oral mucosa. Genital infection with HPV can be transmitted to oral mucosa through autoinoculation, oral sex, or oral contact.

The virion is composed of a double-stranded, circular, 8,000-base pair DNA genome encased in a naked icosahedral capsid about 55 nm in diameter that comprise a heterogeneous family consisting of more than 130 different HPV types and 16 categories (10-13).

In this article we will analyze vary expression of HPV in oral cavity both benign and malignant, their prevalence and the importance in early diagnosis and prevention.

Diagnosis

Diagnosis of papillomavirus lesions is based on the histopathological appearance.

Characteristic features include koilocytosis, acanthosis and papillomatosis which, coupled to the clinical appearance, suggest the infection (14).

The classical oral lesions associated with human papillomavirus are squamous cell papilloma, condyloma acuminatum, verruca vulgaris and focal epithelial hyperplasia (15, 16).

Squamous cell papilloma is a cauliflower-like lesion with a narrow base. It is a small, pink exophytic growth of the oral mucosa (Figure 1).

The lesion of condyloma acuminatum is similar, presenting multiple small, soft, pale lesions with a cauliflower-like surface (Figure 2).

Histologically, both lesions have the same appearance, and human papillomavirus types 6 and 11 are involved. Verruca vulgaris or the common wart is a narrow exophytic growth, wider at the base, sessile and firm (Figure 3).

The lesion is usually found on the gingiva, labial mucosa, commissure, hard palate or tongue. Human papillomavirus types 2 and 57 have been identified in the lesions. Treatment is by surgical excision.

Focal epithelial hyperplasia (Heck's disease) usu-

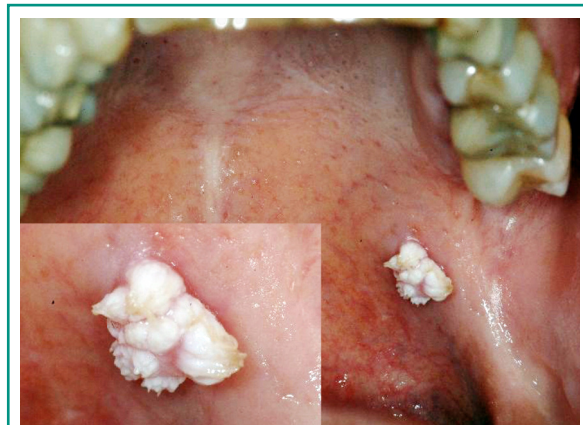

Figure 1
Squamous cell papilloma is a cauliflower-like lesion with a narrow base. It is a small, pink exophytic growth of the oral mucosa.

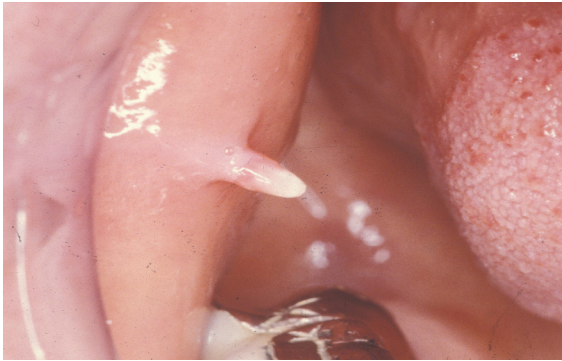


Figure 2
Condyloma acuminatum, presenting multiple small, soft, pale lesions with a cauliflower-like surface.

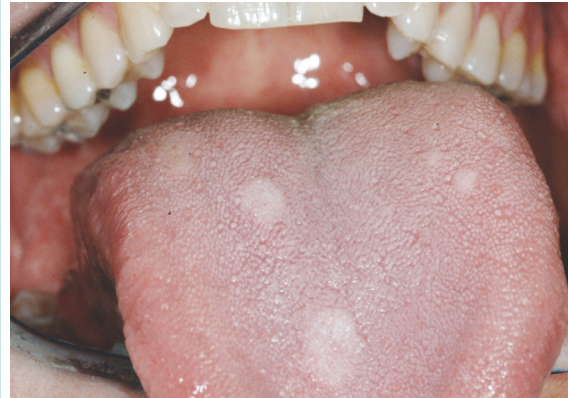

Figure 4
Focal epithelial hyperplasia (Heck's disease) usually presents as multiple plaque-like or papular lesions, flat or convex; the color may vary from red to gray to white.

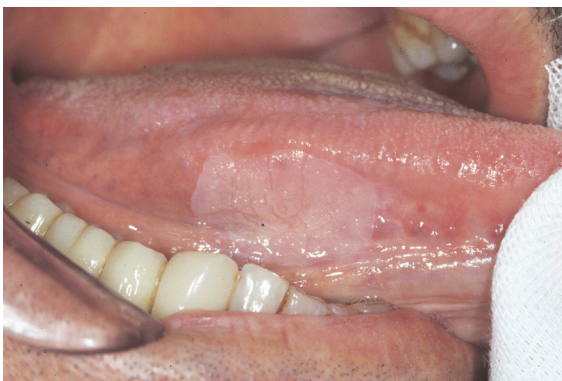

Figure 3
Verruca vulgaris or the common wart is a narrow exophytic growth, wider at the base, sessile and firm.

ally presents as multiple plaque-like or papular lesions, flat or convex, in the mucosa mostly of children. The color may vary from red to gray to white. Lesions occur on oral mucosa exclusively. The lesions are benign and may resolve spontaneously (Figure 4) (17, 18).

Other oral lesions that have been associated with human papillomavirus include erythroplakia (HPV-16), proliferative verrucous leukoplakia (HPV-16), candidal leukoplakia, oral squamous cell carcinoma (HPV-16 and HPV-19) and lichen planus (HPV-6, HPV-11 and HPV-16). Overall, HPV types 2, 4, 6, 11, 13 and 32 have been associated with benign oral lesions while HPV types

16 and 18 have been associated with malignant lesions.

It is now clear that high-risk human papillomavirus genotypes, particularly human papillomaviruses 16 and 18, are important co-factors, especially in cancers of the tonsils and elsewhere in the oropharynx.

A meta-analysis by the Fifth World Workshop on Oral Medicine reviewed 1,121 published studies of oral lesions. The odds ratio for association with high-risk human papillomaviruses and oral cancer was 4.0 (2.62-6.02) and that for oral potentially. The odds ratio for tobacco or heavy drinker and oral cancer was in a range between 3 and 9, so the odd ration of HPV underlines as it is an important risk factor.

Oral cancer shows highly variable clinical features. The most frequent appearance is a white lesion or red or ulcerative area. The clinical morphology is a function of the tumor growth, so you can observe exophytic lesions of papillary or warty appearance or growth endophytic lesions that take the form of penetrating ulcers (Figure 5). Oral cancer signs and symptoms list below considers both oral cancers from HPV and those from tobacco and alcohol: an ulcer or sore that does not heal within 2-3 weeks, difficult or painful swallowing, pain when chewing, a persistent sore

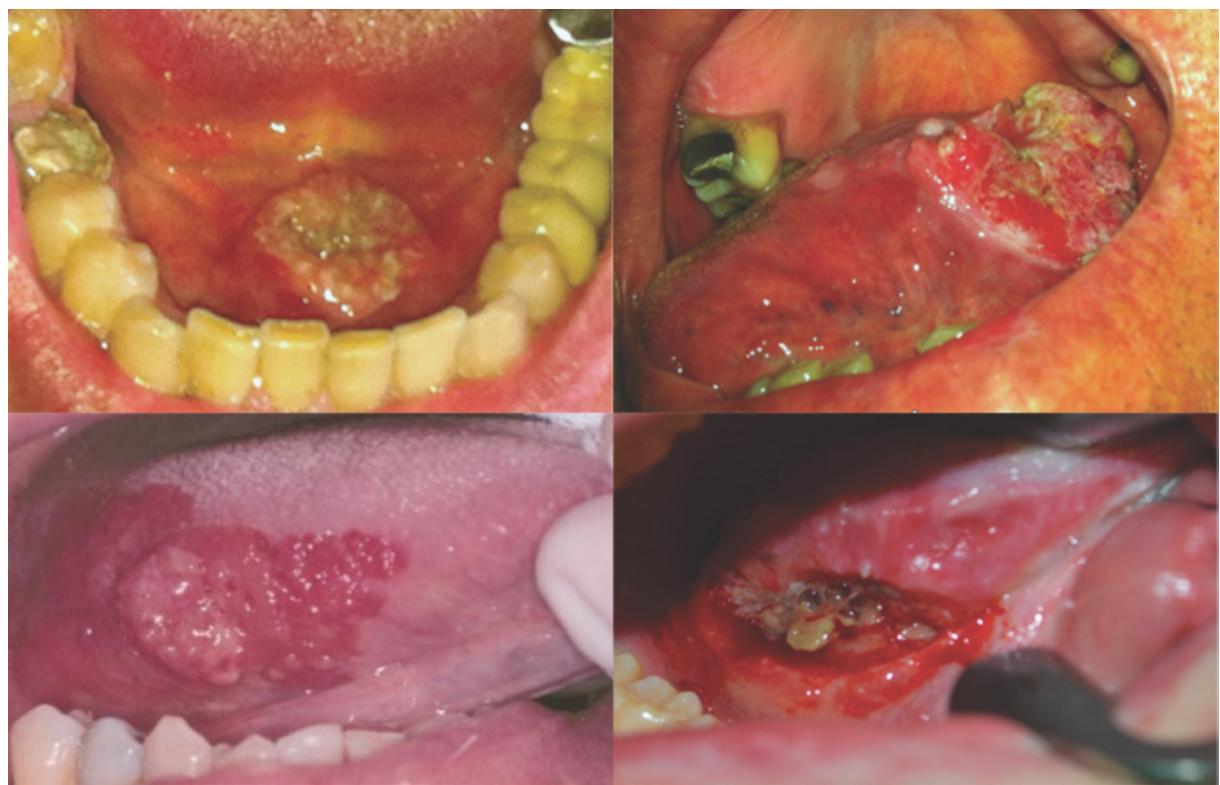


Figure 5

Oral cancer HPV +, shows highly variable clinical features. The most frequent appearance is a white lesion or red or ulcerative area. The clinical morphology is a function of the tumor growth, so you can observe exophytic lesions of papillary or warty appearance or growth endophytic lesions that take the form of penetrating ulcers.

throat or hoarse voice, a swelling or lump in the mouth, a painless lump felt on the outside of the neck, which has been there for at least two weeks, a numb feeling in the mouth or lips, constant coughing, an ear ache on one side (unilateral) which persists for more than a few days (19-21).

HPV contraction, and course

Transmission of the virus can occur with direct contact, genital contact, anal and oral sex, latest studies suggest a salivary transmission and from mother to child during delivery.

The number of lifetime sexual partners is an important risk factor for the development of HPV-positive head-neck cancer. In case-control studies,

the odds of HPV-positive throat cancer doubled in individuals who reported between one and five lifetime oral sexual partner. The risk increased five-fold in those patients with six or more oral sexual partners compared with those who have not had oral sex.

The virus may be inactive for weeks, months and for some people possibly even years after infection. There is no cure for the virus. Most of the time, HPV goes away by itself within two years and does not cause health problems. It is only when HPV stays in the body for many years that it might cause these oral cancers. Even then, it is a very small number of people that will have an HPV infection cascade all the way into an oral malignancy, though that number is increasing every year by about 10%. It is not known why HPV goes away in most, but not all cases. For

unknown reasons there is a small percentage of the population whose immune system does not recognize this as a threat and it is allowed to prosper (22-27).

Fortunately there is a difference between oropharyngeal cancer HPV + and HPV -, the loss of the P16 expression by deletion, hypermethylation or mutation is common in OSCCs caused by alcohol and tobacco, producing injuries with a worse prognosis as they do not respond to chemotherapy or radiotherapy in the same way. E6 HPV's oncoprotein can inactivate P53 too, although in these cases it would be a functional inactivation, not a mutation as it happens in cancer associated with tobacco and alcohol intake. In fact, the rate of P53 mutations due to HPV is very low.

All this would support the existing evidence of oral/oropharyngeal cancer etiologically associated with HPV having an increased survival and a better prognostic (85-90% to five years), but due to the transmission mode, patients with HPV associated HNSCC are younger (30-50 years old) (28-31).

Vaccine

HPV vaccine is the first explicitly designed to prevent virus induced cervix cancer (32, 33). HPVs 16 and 18 are the main targets of the currently approved vaccines and the available data confirm the success in the incidence reduction of pre-cancerous cervical injuries for these types (34).

The vaccine's efficacy is limited by two factors since not all cancers are caused by HPVs 16 and 18; and there seems to be a requirement of vaccinating young women before they get infected by these two types. To be effective, such vaccination should start before "sexual puberty". There are two commercially available prophylactic vaccines against HPV today: the bivalent (VPHs 16 and 18) Cervarix® and the tetravalent (VPHs 6,11,16 and 18) Gardasil®. Theoretically, there is no reason for these vaccines to fail to

work against these same viruses in different localizations (such as oral cavity, pharynx, larynx or the anogenital region). Proving that the vaccine also prevents oropharyngeal cancer would mean not only a landmark in the prevention of these diseases, but it would also provide the missing link in the chain of evidences with the ultimate proof of HPV induced viral etiology of these tumors.

Vaccination is approved in females aged 9 to 26. The vaccination primary target population should be females aged 11 and 12. However the vaccine can also be administered to females up to 9 years old and to those aged between 13 and 26 who have been sexually active (35-37).

Last December 2014 new vaccine Gardasil 9 (VPHs 6, 11, 16, 18, 31, 33, 45, 52, 58) was approved in the United States, while it is still being considered by the European authorities that need to evaluate the efficacy and safety profile.

Conclusions

Considering the importance of HPV in influencing both the risk and the course of oral cancer, it assumes a fundamental importance the preventive diagnosis of HPV. In particular, the clinical examination of precancerous or cancerous lesions is not sufficient, but it is necessary an instrumental analysis. In addition to more traditional histological techniques performed on biopsies, you can now search for the viral DNA in skin cells flaking. It is thus evident the importance of early detection and dentists, rather than to other medical specialties, have a key responsibility of timely diagnostic classification of potentially malignant oral lesions.

The vaccine could be an important preventive strategy, in fact the scientific community is in agreement on hypothesis that blocking the contagion it may also limit the distance complications as the oropharyngeal cancer so in our opinion HPV is an important risk factor of sure future impact on world healthy.

References

- Moore PS, Chang Y. Why do viruses cause cancer? Highlights of the first century of human tumour virology. *Nat Rev Cancer*. 2010;10:878-89.
- Klaes R, Woerner SM, Ridder R, Wentzensen N, Duerst M, Schneider A, Lotz B, Melsheimer P, von Knebel Doeberitz M. Detection of high-risk cervical intraepithelial neoplasia and cervical cancer by amplification of transcripts derived from integrated papillomavirus oncogenes. *Cancer Res*. 1999;59:6132-6.
- Scheffner M, Werness BA, Huibregtse JM, Levine AJ, Howley PM. The E6 oncoprotein encoded by human papillomavirus types 16 and 18 promotes the degradation of p53. *Cell*. 1990;21:1129-36.
- Munger K, Phelps WC, Bubbs V, Howley PM, Schlegel R. The E6 and E7 genes of the human papillomavirus type 16 together are necessary and sufficient for transformation of primary human keratinocytes. *J Virol*. 1989;63:4417-21.
- Kreimer AR, Clifford GM, Boyle P, Franceschi S. Human papillomavirus types in head and neck squamous cell carcinomas worldwide: a systematic review. *Cancer Epidemiol Biomarkers Prev*. 2005;14:467-75.
- St Guily JL, Clavel C, Okais C, Prétet JL, Beby-Defaux A, Agius G, Birembaut P, Jacquard AC, Léocmach Y, Soubeyrand B, Riethmuller D, Denis F, Mouglin C. Human papillomavirus genotype distribution in tonsil cancers. *Head Neck Oncol*. 2011;3(1):6. doi: 10.1186/1758-3284-3-6.
- Bouvard V, Baan R, Straif K, Grosse Y, Secretan B, El Ghissassi F, Benbrahim-Tallaa L, Guha N, Freeman C, Galichet L, Cogliano V. A review of human carcinogens-Part B: biological agents. *Lancet Oncol*. 2009;10:321-2.
- Scapoli L, Palmieri A, Rubini C, Martinelli M, Spinelli G, Ionna F, Carinci F. Low prevalence of human papillomavirus in squamous-cell carcinoma limited to oral cavity proper. *Mod Pathol*. 2009;22(3):366-72.
- Cao J, Jin JQ, Deng DJ, Liu HW. Determination of human papillomavirus in oral leukoplakia, oral lichen planus and oral squamous cell carcinoma. *Beijing Da Xue Xue Bao*. 2016;48(1):84-8.
- Kurose K, Terai M, Soedarsono N, et al. Low prevalence of HPV infection and its natural history in normal oral mucosa among volunteers on Miyako Island, Japan. *Oral Surg Oral Med Oral Pathol Oral Radiol Endod*. 2004;98:91-6.
- Kellokoski J, Syrjänen S, Yliskoski M, Syrjänen K. Dot blot hybridization in detection of human papillomavirus (HPV) infections in the oral cavity of women with genital HPV infections. *Oral Microbiol Immunol*. 1992;7:19-23.
- Horewicz V, Feres M, Rapp G, Yasuda V, Cury P. Human Papillomavirus-16 Prevalence in Gingival Tissue and Its Association With Periodontal Destruction: A Case-Control Study. *J Periodontol*. April 2010.
- Zur Hausen H. Papillomaviruses and cancer: from basic studies to clinical application. *Nat Rev Cancer*. 2002;2:342-50.
- Dhariwal SK, Cubie HA, Southam JC. Detection of human papillomavirus in oral lesions using commercially developed typing kits. *Oral Microbiol Immunol*. 1995;10:60-3.
- Garlick JA, Taichman LB. Human papillomavirus infection of the oral mucosa. *Am J Dermatopathol*. 1991;13:386-95.
- Reichart PA. Oral manifestations of recently described viral infections. *Curr Opin Dent*. 1991;1:377-83.
- Praetorius E. HPV-associated diseases of oral mucosa. *Clin Dermatol*. 1997;15:399413.
- Zeuss MS, Miller CS, White DK. In situ hybridization analysis of human papillomavirus DNA in oral mucosal lesions. *Oral Surg Oral Med Oral Pathol Oral Radiol Endod*. 1991;71:714-20.
- Newell W, Johnson, Prasanna Jayasekara & AA Hemantha K, Amarasinghe. Squamous cell carcinoma and precursor lesions of the oral cavity: epidemiology and aetiology. *Periodontology*. 2000. 2011;57:19-37.
- Mao EJ, Schwartz SM, Daling JR, Oda D, Tickman L, Beckmann AM. Human papilloma viruses and p53 mutations in normal pre-malignant and malignant oral epithelia. *Int J Cancer*. 1996;69:152-8.
- Wen S, Tsuji T, Li X, Mizugaki Y, Hayatsu Y, Shinozaki E. Detection and analysis of human papillomavirus 16 and 18 homologous DNA sequences in oral lesions. *Anticancer Res*. 1997;17: 211-307.
- Puranen M, Yliskoski M, Saarikoski S, Syrjänen K, Syrjänen S. Vertical transmission of human papillomavirus from infected mothers to their newborn babies and persistence of the virus in childhood. *Am J Obstet Gynecol*. 1996;174:694-9.
- Gillison ML, D'Souza G, Westra W, Sugar E, Xiao W, Begum A. Distinct risk factor profiles for human papillomavirus type-16 positive and human papillomavirus type-16 negative head and neck cancers. *J Natl Cancer Inst*. 2008;100:407-20.
- D'Souza G, Kreimer AR, Viscidi R, Pawlita M, Fakhry C, Koch WM. Case-control study of human papillomavirus and oropharyngeal cancer. *N Engl J Med*. 2007;356:1944-56.
- D'Souza G, Agrawal Y, Halpern J, Bodison S, Gillison ML. Oral sexual behaviors associated with prevalent oral human papillomavirus infection. *J Infect Dis*. 2009;199:1263-9.
- Heck JE, Berthiller J, Vaccarella S, Winn DM, Smith EM, Shan'gina O. Sexual behaviours and the risk of head and neck cancers: a pooled analysis in the International Head and Neck Cancer Epidemiology (IHANCE) consortium. *Int J Epidemiol*. 2010;39:166-81.
- Martín-Hernán F, Sánchez-Hernández JG, Cano J, Campo J, del Romero J. Oral cancer, HPV infection and

- evidence of sexual transmission. *Med Oral Patol Oral Cir Bucal*. 2013; 18(3):e439-e444.
28. Ritchie JM, Smith EM, Summersgill KF, Hoffman HT, Wang D, Klusmann JP. Human Papillomavirus infection as a prognostic factor in carcinomas of the oral cavity and oropharynx. *Int J Cancer*. 2003;104:336.
 29. Weinberger PM, Yu Z, Haffty BG, Kowalski D, Harigopal M, Brandsma J. Molecular classification identifies a subset of human papillomavirus-associated oropharyngeal cancers with favorable prognosis. *J Clin Oncol*. 2006;24:736-47.
 30. Kumar B, Cordell KG, Lee JS, Worden FP, Prince ME, Tran HH. EGFR, p16, HPV Titer, Bcl- x1 and p53, sex and smoking as indicators of response to therapy and survival in oropharyngeal cancer. *J Clin Oncol*. 2008; 26:3128-37.
 31. Fakhry C, Westra WH, Li S, Cmelak A, Ridge JA, Pinto H. Improved survival of patients with human papillomavirus-positive head and neck squamous cell carcinoma in a prospective clinical trial. *J Natl Cancer Inst*. 2008;100:261-9.
 32. Forster A, Wardle J, Stephenson J, Waller J. Passport to promiscuity or lifesaver: press coverage of HPV vaccination and risky sexual behavior. *J Health Commun*. 2010;15:205-17.
 33. Baden LR, Curfman GD, Morrissey S, Drazen JM. Human Papillomavirus Vaccine- Opportunity and Challenge. *N Engl J Med*. 2007;356:1990-1.
 34. Schiller JT, Castellsagué X, Villa LL, Hildesheim A. An update of prophylactic human papillomavirus L1 virus-like particle vaccine clinical trial results. *Vaccine*. 2008;26 Suppl 10:53-61.
 35. Syrjänen S. The role of human papillomavirus infection in head and neck cancers. *Ann Oncol*. 2010;21Suppl 7:243-5.
 36. Ljubojevia S. The human papillomavirus vaccines. *Acta Dermatovenerol Croat*. 2006;14:208.
 37. Lugarini J, Maddalo F. Results of a vaccination campaign against human papillomavirus in the province of La Spezia, Liguria, Italy, March-December 2008. *Euro Surveill*. 2009;14:19342.

Correspondence to:

Dr. Davide Testi
 Graduate School in Materials for Health, Environment
 and Energy
 University of Rome "Tor Vergata", Rome, Italy
 E-mail: davide_testi@hotmail.it