

- toxic T-cell phenotype. *J Invest Dermatol* 1997; 109: 636–640.
7. El Shabrawi-Caelen L, Cerroni L, Kerl H. The clinicopathologic spectrum of cytotoxic lymphomas of the skin. *Semin Cutan Med Surg* 2000; 19: 118–123.
 8. Boulland ML, Wechsler J, Bagot M, Pulford K, Kanavaros P, Gaulard P. Primary CD30-positive cutaneous T-cell lymphomas and lymphomatoid papulosis frequently express cytotoxic proteins. *Histopathology* 2000; 36: 136–144.
 9. Kikuchi A, Sakuraoka K, Kurihara S, Akiyama M, Shimizu H, Nishikawa. CD8+ cutaneous anaplastic large-cell lymphoma: report of two cases with immunophenotyping, T-cell-receptor gene rearrangement and electron microscopic studies. *Br J Dermatol* 1992; 126: 404–408.
 10. Berti E, Tomasini D, Vermeer MH, Meijer CJ, Alessi E, Willemze R. Primary cutaneous CD8-positive epidermotropic cytotoxic T cell lymphomas. A distinct clinicopathological entity with an aggressive clinical behavior. *Am J Pathol* 1999; 155: 483–492.
 11. Felgar RE, Salhany KE, Macon WR, Pietra GG, Kinney MC. The expression of TIA-1+ cytolytic-type granules and other cytolytic lymphocyte-associated markers in CD30+ anaplastic large cell lymphomas (ALCL): correlation with morphology, immunophenotype, ultrastructure, and clinical features. *Hum Pathol* 1999; 30: 228–236.

Disseminated Pagetoid Reticulosis Presenting as Cytotoxic CD4/CD8 Double Negative Cutaneous T-cell Lymphoma

G. Pagnanelli¹, L. Bianchi¹, M. Cantonetti², A. Orlandi³, M. C. Fargnoli⁴, L. M. Muscardin⁵ and S. Chimenti¹

¹Departments of Dermatology, ²Hematology and ³Pathology, University of Tor Vergata, Osp. S. Eugenio, P. le dell'Umanesimo, 10, IT-00144 Rome, Italy, ⁴Department of Dermatology, University of L'Aquila, L'Aquila, and ⁵San Galliciano Institute, IRCCS, Rome, Italy. E-mail: chimenti@uniroma2.it

Accepted April 30, 2002.

Sir,

Disseminated pagetoid reticulosis (DPR) is a rare form of cutaneous T-cell lymphoma (CTCL) originally described by Ketrion & Goodman in 1931 (1). This lymphoproliferative disorder usually presents as multiple erythematous, squamous patches, plaques, nodules, ulcerated skin tumours and, not infrequently, runs an aggressive course with dissemination of the lesions and progression to a fatal outcome (1, 2).

Cytotoxic cutaneous lymphomas are uncommon and usually express a CD8 and/or CD56 positive phenotype. They represent a heterogeneous group of lymphomas showing various features with regard to clinicopathologic profile, immunophenotypic features, clinical course and prognosis (3). All cytotoxic lymphocytes express a set of toxic proteins, e.g. perforins, granzymes A (GrA) and B (GrB), and the T-cell intracellular antigen-1 (TIA-1) (4), which are reliable markers of cells with activated cytotoxic function (2).

Gemcitabine is a nucleoside antimetabolite with established activity against several solid tumours showing promising results in the treatment of lymphoproliferative malignancies. Gemcitabine is a cytosine analogue that causes less myelosuppression as well as immunosuppression compared with other available nucleoside analogues (5).

We describe here a 35-year-old patient with a primary cutaneous T-cell lymphoma presenting with clinicopathologic features of DPR and showing a CD4/CD8 double negative, TIA-1/granzyme B cytotoxic positive phenotype. Furthermore, we report the efficacy of gemcitabine treatment in this aggressive lymphoproliferative disorder.

CASE REPORT

A 35-year-old man presented with a 1-year history of generalized, painful, erythematous, some ulcerated and exudative patches, plaques and nodules (Fig. 1). No hepatosplenomegaly or lymphadenopathy was detected. Past medical history and physical examination were unremarkable, and laboratory investigations were within normal limits. Staging procedures (total computed tomographic scans and bone marrow aspirate) showed no abnormalities. The patient's serum was negative for anti-HTLV-1 and anti-EBV antibodies and the levels of sIL-2 receptor and sTNF- α were within normal limits. Biopsy specimens from lesional skin were routinely processed for formalin fixation and paraffin embedding. Histopathologic examination showed a dense intraepidermal infiltrate of medium/large neoplastic lymphoid cells with clear, abundant cytoplasm, hyperchromatic nucleus and prominent nucleoli, scattered in the basal and suprabasal layers of the epidermis (Fig. 2). A few atypical lymphoid cells were also present around the blood vessels of the papillary dermis. The phenotypic profile of the intraepidermal lymphocytes was as fol-

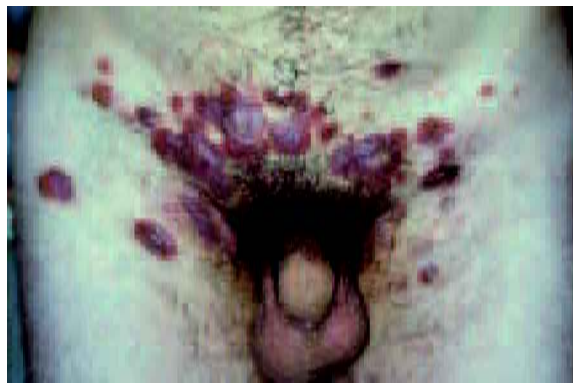

Fig. 1. Erythematous-violaceous plaques and nodules at time of presentation.

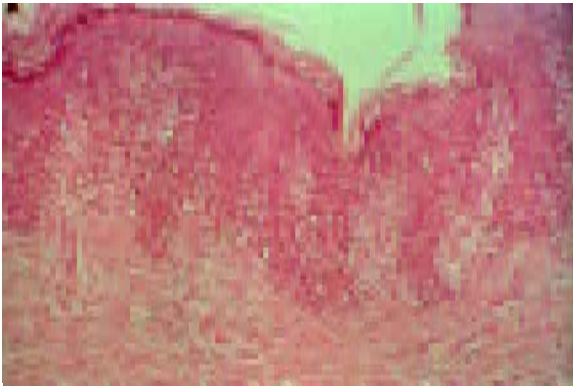


Fig. 2. A dense intraepidermal pagetoid infiltrate of medium/large neoplastic lymphoid cells scattered in the basal and suprabasal layers of the epidermis. (Haematoxylin-eosin stain; original magnification $\times 50$.)

lows: $\beta F-1+$ (T-cell Sciences, Cambridge, USA), $CD3+$ (Ylem, L'Aquila, Italy), $TIA-1+$ (Immunotech, Marseille, France) (Fig. 3), $GrB+$ (Chemicon, Temecula, USA), $CD4-$, $CD8-$, and $CD-56-$, (Neomarkers, Fremont, USA), $CD30-$ (Dako, Glostrup, Denmark), $CD34-$, $TdT-$, $CD20-$ (Ylem). Based on the clinicopathological findings, primary cutaneous cytotoxic T-cell lymphoma was diagnosed. The patient was initially treated with $IFN-\alpha$ 3,000,000 I.U. 3 times weekly, subcutaneously, and etretinate 25 mg/day for 3 months, but without benefit. The patient then underwent chemotherapy with dexamethasone, cytarabine and cisplatin (DHAP) for 3 cycles each, every 28 days, but again with no improvement. Therefore, therapy with slow intravenous infusion of gemcitabine at a dosage of $1,250 \text{ mg/m}^2$ on days 1, 8 and 15 of a 28-day schedule (8) was started. Initial improvement of the lesions was observed after the second cycle of treatment and a complete response was obtained after 6 courses. However, the cutaneous lesions worsened 3 months after the last gemcitabine cycle and the patient refused any further therapy. He died of systemic disease 18 months after the initial diagnosis.

DISCUSSION

Few studies on DPR have been reported so far and most of them include only a few patients, short-term follow-

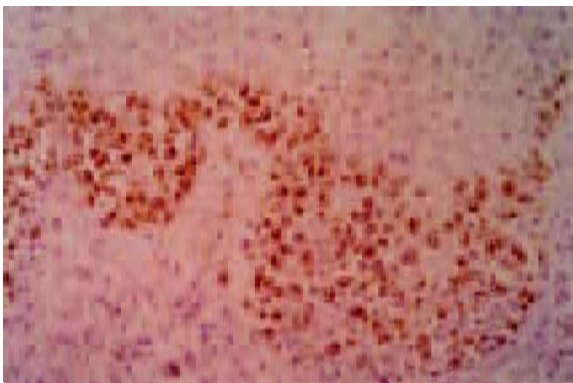


Fig. 3. The cytotoxic phenotype of the neoplastic cells is demonstrated by the expression of T-cell intracellular antigen-1. (Haematoxylin counterstain; original magnification $\times 400$.)

up or limited genotypic and/or phenotypic characterization (2, 6, 7–12). In the past, there had been debate concerning the origin of the atypical cells in pagetoid reticulosis, up until their T-lymphocytic nature was definitively established through immunophenotypic and genotypic studies (13). Another controversial aspect of DPR concerns its association with mycosis fungoides based on their clinical and histopathologic similarities. Therefore many authors consider DPR as an aggressive variant of mycosis fungoides (11). Nevertheless, there are several clinical, histopathologic and immunophenotypic features that distinguish these two entities (14). DPR seems to be an aggressive clonal CTCL with distinctive clinicopathological findings and heterogeneous immunophenotype including $CD4+$ T-helper, or $CD8+$ cytotoxic/suppressor or $CD4/CD8$ double-negative phenotype together with $\alpha\beta$ or $\gamma\delta$ TCR expression (6–8). Our patient's neoplastic cells clearly expressed the above-mentioned cytotoxic proteins, strongly suggesting their origin from an activated cytotoxic T-cell subset, although they did not express $CD8$ antigen on their cell surface. Furthermore, they did not express markers characteristic of natural killer cells or $\gamma\delta$ T cells. The negative staining for TdT and $CD34$ rules out their derivation from a T-lymphocyte precursor lineage. According to the EORTC classification, our patient should fit the diagnosis of $CD30$ negative pleomorphic large T-cell cutaneous lymphoma (15). Lack of $CD8$ antigen does not allow us strictly to classify our case among the so-called cytotoxic CTCLs (2), which are characterized by a distinctive combination of clinical, histopathological and immunophenotypical features ($\beta F1+$, $CD3+$, $CD8+$, $CD7+$, $CD45RA+$, $TIA-1/GMP-17+$) and which usually run an aggressive clinical course (2).

Our patient was unresponsive to $IFN-\alpha$ in association with etretinate and DHAP therapies and because no effective standardized cure is available for DPR, we started treatment with gemcitabine while waiting for a bone marrow transplant. Gemcitabine led to a rapid improvement of the skin lesions in our patient, although it did not prevent relapse of the disease 3 months after the end of therapy.

In conclusion, we believe that our case could contribute to the knowledge on the relationship between DPR, cytotoxic cutaneous lymphomas and other CTCLs. Furthermore, we believe that our experience in the use of gemcitabine could contribute to new modalities in the treatment of cytotoxic cutaneous lymphomas, since aggressive therapeutical approaches are often ineffective and therefore new strategies are needed.

REFERENCES

1. Ketron LW, Goodman MH. Multiple lesions of the skin apparently of epithelial origin resembling clinically mycoses fungoides. *Arch Dermatol Syph* 1931; 24: 758–785.

2. Berti E, Tomasini D, Vermeer MH, Meijer CJ, Alessi E, Willemze R. Primary cutaneous CD8-positive epidermotropic cytotoxic T-cell lymphomas. *Am J Pathol* 1999; 155: 483–492.
3. Santucci M, Pimpinelli N, Massi D, Kadin ME, Meijer CJLM, Muller-Hermelink HK, et al. Cytotoxic/natural killer cell cutaneous lymphomas: a clinicopathological study of 48 cases from the EORTC cutaneous lymphoma study group. *Blood* 2002; in press.
4. Krenacs L, Wellmann A, Sorbara L, Himmelmann AW, Bagdi E, Jaffe ES, et al. Cytotoxic cell antigen in anaplastic large cell lymphomas of T- and null-cell type and Hodgkin's disease: evidence for distinct cellular origin. *Blood* 1997; 89: 980–989.
5. Zinzani PL, Baliva G, Magagnoli M, Bendandi M, Modugno G, Gherlinzoni F, et al. Gemcitabine treatment in pretreated cutaneous T-cell lymphoma: experience in 44 patients. *J Clin Oncol* 2000; 18: 2603–2606.
6. Haghighi B, Smoller BR, LeBoit PE, Warnke RA, Sander CA, Kohler S. Pagetoid reticulosis (Woringer-Kolopp disease): an immunophenotypic, molecular, and clinicopathologic study. *Mol Pathol* 2000; 13: 502–510.
7. Mielke V, Wolff HH, Winzer M, Sterry W. Localized and disseminated pagetoid reticulosis: diagnostic immunophenotypical findings. *Arch Dermatol* 1989; 125: 402–406.
8. Berti E, Cerri A, Cavicchini S, Delia G, Soligo D, Alessi E, et al. Primary cutaneous gamma/delta T-cell lymphoma presenting as disseminated pagetoid reticulosis. *J Invest Dermatol* 1991; 96: 718–723.
9. Ralfkiaer E, Thomsen K, Agdal N, Hou-Jensen K, Wantzin GL. The development of a Ki-1-positive large cell non-Hodgkin's lymphoma in pagetoid reticulosis. *Acta Derm Venereol* 1989; 69: 206–211.
10. Luther H, Bacharach-Buhles M, Schultz-Ehrenburg U, Altmeyer P. Pagetoide retikulose von typ Ketron-Goodman. *Hautarzt* 1989; 40: 530–535.
11. Lacour JP, Juhlin L, El Baze P, Baretty M, Ortonne JP. Disseminated pagetoid reticulosis associated with mycosis fungoides: immunomorphologic study. *J Am Acad Dermatol* 1986; 5: 898–901.
12. Bukulmez G, Atakan N, Taskin M, Bilezikci B, Uner A. Disseminated pagetoid reticulosis: plaques and tumoral lesions occurring simultaneously in the same patient. *J Eur Acad Dermatol Venereol* 2001; 15: 59–61.
13. Slater D, Goepel J, Walker A, Corbett P. Lymphocyte subsets in pagetoid reticulosis. *Br J Dermatol* 1984; 11: 244–246.
14. Woringer FR, Kolopp P. Lésion érythémato-squameuse polycyclique de l'avant-bras évoluant depuis 6 ans chez un garçonnet de 13 ans: histologiquement infiltrat intra-épidermique d'apparence tumorale. *Ann Dermatol Syph* 1939; 10: 945–948.
15. Willemze R, Kerl H, Sterry W, Berti E, Cerroni L, Chimenti S, et al. EORTC classification for primary cutaneous lymphomas: a proposal from the cutaneous lymphoma study group of the European Organization for Research and Treatment of Cancer. *Blood* 1997; 90: 354–371.

Eosinophilic Pustular Folliculitis Induced by Allopurinol and Timepidium Bromide

Hideki Maejima¹, Hideki Mukai² and Eto Hikaru¹

¹Department of Dermatology, St. Luke's International Hospital, 9-1 Akashi-cho, Chuo-ku Tokyo, Japan 104-8560, and the

²Division of Dermatology, Yokohama Rosai Hospital, Yokohama, Japan. E-mail hidemae@luke.or.jp

Accepted April 22, 2002.

Sir,

We describe a woman with numerous papules and pustules on her face and upper trunk induced by allopurinol and timepidium bromide. The histopathology showed the destruction of hair follicles and the infiltration of eosinophils, which we diagnosed as eosinophilic pustular folliculitis.

CASE REPORT

A 57-year-old Japanese woman was treated with oral allopurinol and timepidium bromide for ureterolith since April 1998. One month later, she presented with an eruption on her face, followed by numerous rice-sized papules and pustules on her face and upper trunk, a fever and bilateral cervical lymphadenopathy were also present (Fig. 1). The woman visited our hospital for examination in June 1998. Laboratory studies revealed eosinophilia (white blood cell, 7,400/mm³; eosinophile, 25%, 1,850/mm³), mild liver dysfunction (glutamic oxaloacetic transaminase, 36 IU/ml; glutamic pyru-

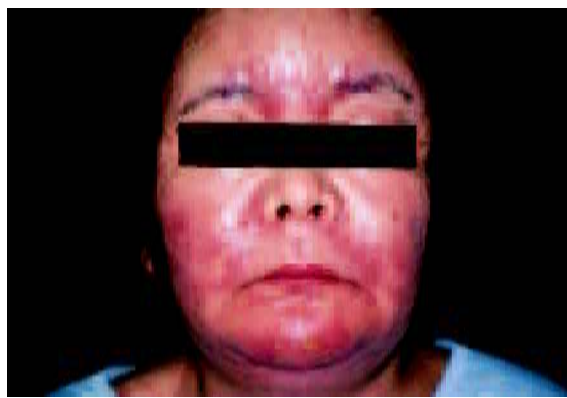

Fig. 1. Clinical findings at first examination: numerous papules and pustules on the patient's face.

vic transaminase, 65 IU/ml; gamma-glutamyl-transpeptidase, 159 IU/ml; alkaline phosphatase, 436 IU/ml) and a strong inflammatory reaction (C-reactive protein, 8.3 mg/dl). No elevations were found in her serum viral titers (human herpes simplex virus, Epstein-Barr virus