

CASE REPORT

SILENT DELTOID ATROPHY IN BEACH VOLLEYBALL PLAYERS: A REPORT OF TWO CASES AND LITERATURE REVIEW

Giovanni Monteleone, MD^{1,2,5}Marco Gismant, MD³Giorgio Stevanato, MD⁴Alessandra Tiloca, DAT⁵

ABSTRACT

While examining the shoulders of 91 professional and semi-professional beach volleyball players, the authors observed two cases of grave atrophy of the deltoid muscle following painless axillary neuropathy, not resulting from any trauma. The causes, the clinical history and the untreated history of the entrapment of the axillary nerve in the quadrilateral space in sportsmen, are discussed on the basis of the presentation of the two cases illustrated and from existing literature.

Keywords: axillary nerve entrapment; quadrilateral space syndrome; sport related axillary neuropathy

Level of Evidence: 4

CORRESPONDING AUTHOR

Giovanni Monteleone, MD
University of Rome "Tor Vergata", Rome,
Italy
Via Montpellier n. 1
00133-Rome - Italy
Phone/fax: 0039-06-72596061
E-mail: giovanni.monteleone@uniroma2.it

¹ Department of Biomedicine and Preventative Medicine, Faculty of Medicine and Surgery, University of Rome "Tor Vergata", Rome, Italy

² C.O.N.I. - Italian Olympic Committee, Sardinia, Italy

³ S.I.U.M.B. - Italian Society for Ultrasound in Medicine and Biology, Rome, Italy

⁴ Neurosurgery Unit, Dell'Angelo Hospital, Mestre (Ve), Italy

⁵ School of Sport and Exercise Sciences, University of Rome "Tor Vergata", Rome, Italy

INTRODUCTION

There is a high prevalence of cases of atrophy of the infraspinatus muscle of the hitting shoulder (30%) in athletes playing beach volleyball at the competitive level, arising from the damage to the suprascapular nerve.¹ On the contrary, non-traumatic atrophy of deltoid muscle consequent to axillary neuropathy in overhead sports is a rare event.²

Some authors³ associate a compressive axillary nerve injury with the neuropathy of quadrilateral/quadrangular space (or Velpeau space).^{4,5} A space delimited superiorly by the inferior margin of the subscapularis, inferiorly by the superior margin of the teres major, medially by the external margins of the long head of the triceps, externally by the humerus surgical neck and the inferior portion of the glenohumeral joint.

The axillary nerve runs through the quadrilateral space together with the posterior circumflex humeral artery, and in its most common conformation it innervates the anterior, middle and posterior deltoid with its anterior branch, and the teres minor and the lateral skin of the arm and the posterior deltoid with its posterior branch.⁶ Axillary nerve compression causes Quadrilateral space syndrome (QSS), which usually causes disabling, painful symptoms causing the athlete to suspend any sport activity for long periods.⁷ Duparc et al⁸ observed many anatomical variants of the axillary nerve related to different origins of collateral nervous branches, and this anatomical inconsistency may be a reason for frequent dissociation between sensitive and motor deficiency.

In the current case report series, the authors report two cases of deltoid muscle atrophy, caused by painless non-traumatic neuropathy of the axillary nerve, found while examining 91 professional and semi-professional beach volleyball players.

CASE 1

A 49-year old player, who had been playing beach volleyball for over 15 years, presented a severe atrophy of the right deltoid (the hitting shoulder) (Figure 1). The athlete reported having noticed the localized loss of muscular volume approximately 12 years before, but had not considered the necessity to interrupt sport competition nor the necessity to have therapy because of the lack of shoulder pain.

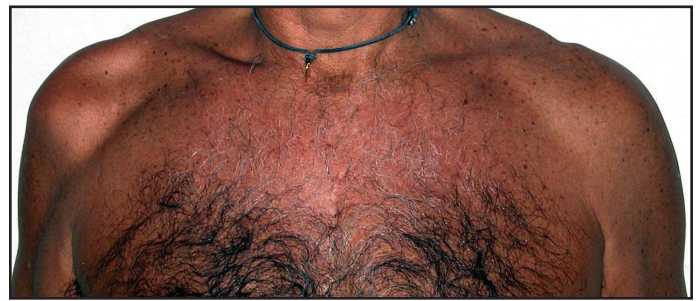

Figure 1. Subject 1: Clinical presentation at the examination.

At physical examination, rotator cuff tests, including the “hornblower’s” sign and the power of external rotation in 90° of abduction in the scapular plane exam for the teres minor,⁹ were negative. The Neer’s sign and the sulcus sign^{10,11} were also negative. Digital pressure caused no pain at any point. A considerable reduction of strength in forward flexion of the shoulder, grade 4 Medical Research Council (MRC) scale with slight resistance, was observed.

The results of electromyography (EMG) and electro-neurography (ENG) (Table 1) highlighted stabilized neurogenic damage of the right deltoid muscle; the Motor Unit Potential (MUP) were of increased average amplitude and duration in the deltoid muscle, with reduced voluntary recruitment of an intermediate/simple type. The compound Motor Action Potential (cMAP) of the right deltoid muscle for the stimulus of the axillary nerve at the point of Erb, showed symmetrical latency and amplitude in comparison with the contralateral.

At the time of the evaluation, this athlete was among the top twenty players in the final phase of the Italian championship.

CASE 2

The second subject was a 26-year old female player, who had been playing competitive volleyball since

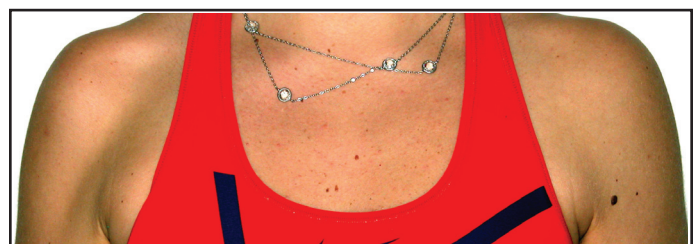


Figure 2. Subject 2: Clinical presentation at the examination.

Table 1.

CASE	MNCV	Site/Segment	Latency (m/s)	Amplitude (mV)	Duration (ms)	Area (mVms)
1	Axillary R	deltoid/Erb	3.4	1.6	20.9	10.4
	Axillary L	deltoid/Erb	3.1	2.1	21.6	11.2
	EMG	Spontaneous activity		Fasciculation	Amplitude MUP	Recruitment
	Anterior deltoid R	absent		absent	+	intermediate/simple
	MNCV	Site/Segment	Latency (m/s)	Amplitude (mV)	Duration (ms)	Area (mVms)
2	Axillary R	Deltoid/Erb	4.6	4.8	17.8	20.4
	Axillary L	Deltoid/Erb	4.0	8.8	12.8	34.5
	EMG	Spontaneous activity		Fasciculation	Amplitude MUP	Recruitment
	Anterior deltoid R	absent		absent	+	interferential

MNCV= motor nerve conduction velocity; EMG= electromyography; R= right; L= left; MUP= Motor Unit Potential.

the age of 13, and for six years as a professional beach volleyball player who had noticed a hollow corresponding to the right shoulder (the hitting shoulder) approximately two years before. The shoulder was completely without pain and therefore she had considered it unnecessary to seek medical advice. Palpation of the shoulder showed no painful points; all rotator cuff tests and the sulcus sign were negative. The articular excursion was symmetrical to the contralateral on all planes. A severe reduction in the strength in forward flexion of the arm, Grade 4 MRC scale with slight resistance, was observed. EMG highlighted no spontaneous activity at rest in deltoid muscle (anterior/posterior); average amplitude and duration MUP increased, with normal interferential type voluntary recruitment, explainable as an expression of neurogenic damage of the deltoid muscle. The ENG indicated demyelination axonal damage of the axillary nerve with deltoid muscle cMAP asymmetric and slightly reduced amplitude compared to the contralateral for the stimulus of the axillary nerve at the point of Erb (amplitude right 4.8- left 8.8) (Table 1). The Musculoskeletal Ultrasound scan (US) of the shoulder highlighted a marked reduction in the volume with an increase in the echogenicity of the deltoid muscle and a reduction in the thickness, associated with a finely hyperechoic structure of the teres minor muscle (Figures 3 and 4). At the

time of the first evaluation, the athlete had qualified for the quarterfinals of the second phase of the Italian championship.

DISCUSSION

Causes of QSS

When described initially, the compression of the axillary nerve in the quadrilateral space was related to the presence of fibrous transverse bands. These bands were proposed to reduce the quadrilateral space, constrict the nerve, and sometimes the axillary artery. Mc Clelland et al¹² reconsidered this etiological hypothesis, when during the dissection of 16 shoulders they identified fibrous bands between the teres major and the long head of the triceps in 14 cases, which would reduce the volume of the quadrilateral space during both internal and external rotation of the glenohumeral joint.

Other authors⁶ have suggested that friction or irritation of the axillary nerve occurs during its passage around the posterior glenoid or by compression by the hypertrophied portion of the subscapularis, which inserts itself on the humerus just under the lesser tuberosity. Chen et al¹³ have identified a dense fibrous tissue which envelopes the axillary nerve making it adhere to the long head of the triceps muscle. Ischima et al,¹⁴ in one case, identified

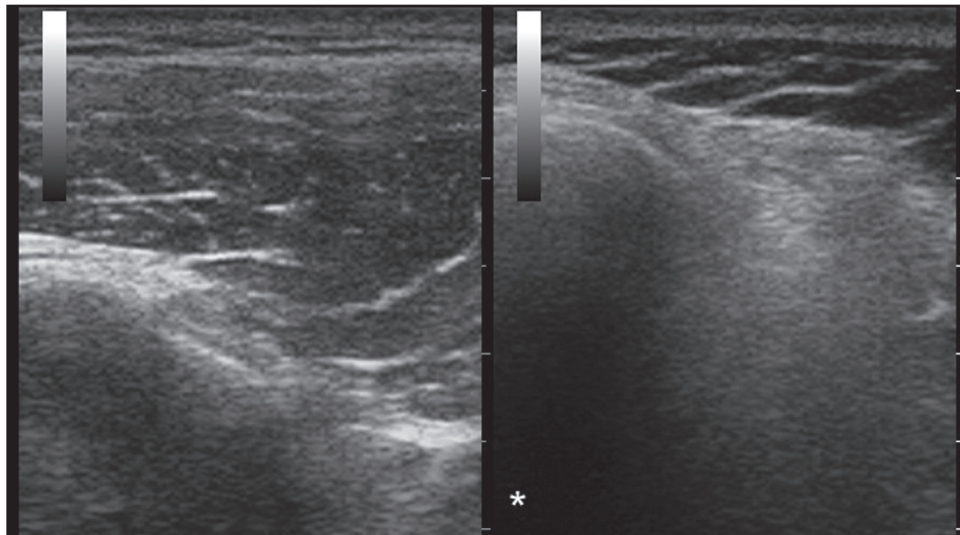


Figure 3. Musculoskeletal Ultrasound scan. Subject 2: transverse scan (patient seated, probe placed laterally to shoulder convexity) showing the increase in the echogenicity of the right anterior deltoid muscle (*) with reduction of the thickness with respect to the contralateral.

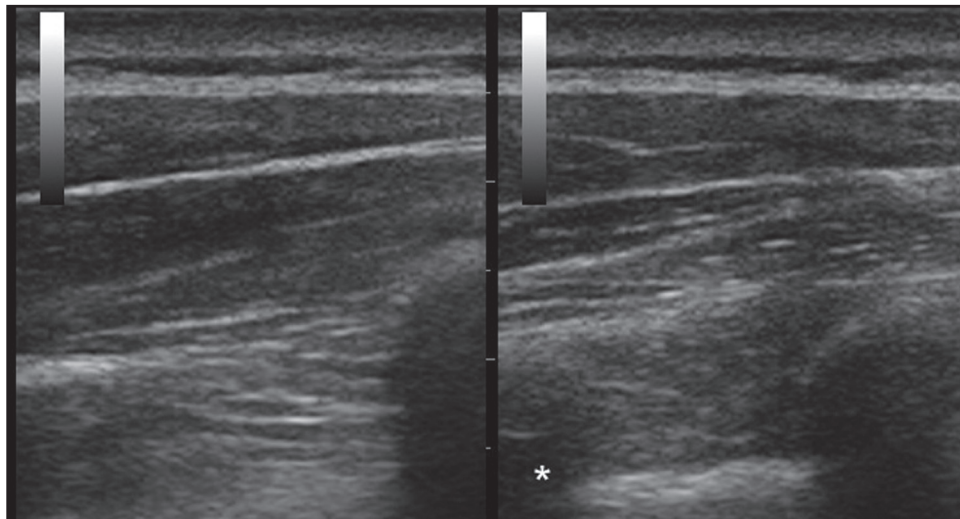


Figure 4. Musculoskeletal Ultrasound scan, Subject 2: transverse scan (patient seated, probe placed posteriorly at the course of the teres minor muscle) comparing the right and left teres minor, showing the reduced thickness of the right teres minor (*), which seems to have a finely hyperechoic echostucture.

a ganglion cyst originating from the joint capsule as the cause of the nervous compression. Furthermore, a dilated vein may provoke QSS.¹⁵

Clinical Presentation in QSS

Poorly localized pain in the upper limb, sometimes persisting overnight, is a typical symptom of axillary neuropathy from entrapment in the quadrilateral space. Other times the pain has a prevalent anterior or posterior presentation with unusual forearm and hand distribution of paresthesia. Sometimes, flexion and external rotation or abduction of the shoulder with

or without external rotation, makes the symptoms worse, either immediately or after a few minutes.^{16,17} However, more frequently, the pain is undefined, or rather vague.^{18,19,20}

Paladini et al⁷ describe two cases of volleyball players with initial symptoms of hypoesthesia in the region of the axillary nerve, or of dysesthesia, painful during abduction, associated with progressive atrophy of the deltoid.

Granted that the physical and neurological examinations may be completely within the norm,²¹ Manske

et al²² underlined the importance of examining for tenderness with digital pressure in the area corresponding to the quadrilateral space. In their clinical observation, baseball pitchers frequently have a thick band along the margin between the teres minor muscle and the infraspinatus muscle, which may be attributed to the hypertrophic connective tissue of the musculature of these athletes. Therefore, they report this thickening is frequently associated to QSS.

For QSS diagnosis McClelland et al¹² suggest a provocative test carried out by putting the arm to be examined in abduction at 90° and rotating it internally and externally in order to attempt to reproduce the symptoms. Chautems et al,²³ in one case report, reproduced the QSS with the Falconer maneuver. This test is performed asking the patient to retract and then depress the shoulder and to hold this position for one minute.

However, in all QSS cases reported in literature, there are descriptions of more or less disabling symptoms of which pain, and not atrophy of the deltoid muscle, is the predominant aspect in the array of symptoms: resulting in patients usually resorting to medical treatment and suspending sport activity for many months.

In the cases described herein, pain was completely absent in both subjects, however, the deltoid atrophy and the consequent reduction of strength in forward flexion of the shoulder were the only clear clinical manifestations of the axillary neuropathy.

Instrumental Diagnosis of QSS

In QSS, the electrodiagnostic exams are often completely normal. Other times, the EMG and ENG identify damage to the axillary nerve of various seriousness with axonal involvement and/or long period persistent denervation.²⁴ In order to confirm QSS diagnosis, some authors have suggested studying the posterior circumflex artery with angiography or NMR angiography in order to identify its obliteration when the limb is placed in abduction and extrarotation.^{3,20} Mochizuki et al²⁵ however, have shown that, with the limb in this position, the occlusion of the posterior circumflex humeral artery is frequent even in completely asymptomatic patients.

Linker et al¹⁹ recognize an important diagnostic element of the syndrome with regard to the atrophy of

the teres minor which is examined using a nuclear magnetic resonance (NMR) scan, whether there is any alteration of the deltoid or not. Cothran et al²⁶ state the extreme rarity of the isolated lesion of the teres minor, and in 2436 NMR examination scans of the shoulder, they identified 0.8% of the cases as atrophy or an abnormal sign of this muscle, attributable to QSS.

In a clinical case of QSS, Brestas et al²⁷ observed limited volume reduction and increased echogenicity of teres minor using Musculoskeletal US. Data was confirmed by the EMG, NMR scan and by surgery. Similarly, the US scan described in case two highlighted a reduction in the volume and a finely hyperechoic structure of the teres minor.

Course of QSS

The course of the neuropathy does not always have the same characteristics and while surgical neurolysis is sometimes indispensable to treat a severe syndrome, in other cases the painful symptomatology may cease after a period of rest and conservative treatment; in one case, the sportive arm movement was modified to decrease symptoms.¹⁷

Sometimes the dysfunction of the deltoid, even if only partial, causes a serious and non-tolerable loss of function of the shoulder, and therefore requires correction with a palliative surgical operation such as a tendinous transfer.²⁸ According to Resch et al,²⁹ the dysfunction of just the anterior portion may preclude any overhead activity, especially when this is associated with a damage to the rotator cuff. By activating alternative biomechanical mechanisms, some subjects are able to raise their arm quite well despite the complete paralysis of the deltoid;³⁰ young athletes can compensate for the complete paralysis of the deltoid in their daily activities with limited disability.³¹

The subjects presented in these case reports demonstrated the athlete's remarkable ability to compensate unconsciously for the serious deltoid atrophy, in order to maintain their competitive athletic performance. Therefore, axillary neuropathy in some athletes may represent a clinical event similar to that frequently occurring due to suprascapular nerve lesions. As reported by several authors, in the majority of cases, this neuropathy is asymptomatic

and causes no perception of any functional disability in athletes.^{32,33}

This does not mean that the complete or partial loss of the deltoid muscle capacity can be ignored. Harmful effects on physical function of the limb may appear over a lifetime. For this reason, the medical and athletic staff who look after the players should pay particular attention to the earliest possible identification of QSS.

Early Diagnosis and Treatment in Silent Deltoid Atrophy

With the absence of the standard symptomatological pattern, the suspicion of an axillary nerve injury may be due to a sudden reduction in the forward arm flexion ability or power; that may be perceptible but not considered disabling by the athlete. Meanwhile, medical and athletic staff should conduct a thorough examination, which can lead to proper diagnostic protocols that may include electrodiagnostic exam, and an NMR and/or US examination to evaluate the volume and structural changes present in the deltoid and teres minor muscles. US could be used even to monitor the pathology progression.³⁴

Treatment must take into consideration the suspension of sport activity and drug administration with physical therapy in order to support nerve and muscles regeneration. As reported by Steinmann et al,³⁰ in axillary injury surgical treatment may be considered if no evidence of recovery is noted on physical examination or electrodiagnostic studies after a course of three months.

In volleyball disciplines, considering QSS multi form clinical expression, the authors cannot exclude the possibility that axillary neuropathy is more frequent than expected. Thus, considering the difficulty in making this diagnosis, QSS is often confused with other common pathologies of the shoulder and therefore may be subject to incongruous treatment.¹⁵

CONCLUSIONS

The two cases presented demonstrate the presence of deltoid atrophy in two of 91 competitive level beach volleyball athletes, representing a prevalence of 2.2% occurring from presumed neuropathy of the axillary nerve. This report presents the first epidemiological data related to this syndrome in athletes

who participate in volleyball. The cases were identified exclusively using physical examination of the shoulder and the athletes' medical history, which was not selectively focused on the research of this neuropathy. The authors cannot exclude the possibility of finding a higher percentage of cases of silent or symptomatic axillary neuropathy in similar athletes in clinical epidemiological studies, considering that it is common for this type of athlete to compete despite pain or dysfunction that may be present in their shoulder.³⁵

REFERENCES

1. Lajtai G, Pfirrmann C W A, Aitzetmüller G, et al. The shoulders of professional beach volleyball players; high prevalence of infraspinatus muscle atrophy. *Am J Sports Med.* 2009; 37: 1375-82
2. Hoskins WT, Pollard HP, McDonald AJ. Quadrilateral space syndrome: a case study and review of the literature. *Br J Sports Med.* 2005; 39(2):e9
3. Cahill BR, Palmer RE. Quadrilateral space syndrome. *J Hand Surg Am.* 1983; 8: 65-9
4. Drez DJ Jr. Re: Surgical decompression of the quadrilateral space in overhead athletes. *Am J Sports Med.* 2008; 36: E8
5. Testut L, Laterjet A: Treaty of human anatomy. [Trattato di anatomia umana]. Trans. Bianchi L, (Original title: *Traité d'anatomie humaine*, 9e édition). Ed. Unione Tipografico Editrice Torinese, Torino 1971, 4: 73-75
6. Safran MR. Nerve injury about the shoulder in athletes, part 1: suprascapular nerve and axillary nerve. *Am J Sports Med.* 2004; 32: 803-19
7. Paladini D, Dellantonio R, Cinti A, et al. Axillary neuropathy in volleyball players: report of two cases and literature review. *J Neurol Neurosurg Psychiatry.* 1996; 60: 345-7
8. Duparc F, Bocquet G, Simonet J, et al. Anatomical basis of the variable aspects of injuries of the axillary nerve (excluding the terminal branches in the deltoid muscle). *Surg Radiol Anat.* 1997; 19: 127-32
9. Walch G, Boulahia A, Calderone S, et al. The 'dropping' and 'hornblower's' signs in evaluation of rotator-cuff tears. *J Bone Joint Surg [Br].* 1998; 80-B: 624-8
10. Andrews J R, Wilk KE. The athlete's shoulder. New York, Edimburgh, London. Madrid, Melbourne, Tokyo: Churchill Livingstone, 1994, 47-56
11. Clarnette RG, Miniaci A. Clinical exam of the shoulder. *Med Sci Sports Exerc.* 1998; 30 (4Suppl): S1-6
12. McClelland D, Paxinos A. The anatomy of the quadrilateral space with reference to quadrilateral

- space syndrome. *J Shoulder Elbow Surg.* 2008; 17: 162-4
13. Chen D, Cai P, Lao G, et al. Quadrilateral space syndrome. *Chin Med J (Engl).* 1995; 108: 109-12
 14. Ishima T, Usui M, Satoh E, et al. Quadrilateral space syndrome caused by a ganglion. *J Shoulder Elbow Surg.* 1998; 7: 80-2
 15. McAdams TR, Dillingham MF. Surgical decompression of the quadrilateral space in overhead athletes. *Am J Sports Med.* 2008; 36: 528-32
 16. Cormier PJ, Matalon TA, Wolin PM. Quadrilateral space syndrome: a rare cause of shoulder pain. *Radiology.* 1988; 167: 797-8
 17. Redler MR, Ruland LJ 3rd, McCue FC 3rd. Quadrilateral space syndrome in a throwing athlete. *Am J Sports Med.* 1986; 14: 511-3
 18. Duralde XA. Neurologic Injuries in the Athlete's Shoulder. *J Athl Train.* 2000; 35: 316-28
 19. Linker CS, Helms CA, Fritz RC: Quadrilateral space syndrome: findings at MR imaging. *Radiology.* 1993; 188: 675-6
 20. McKowen HC, Voorhies RM. Axillary nerve entrapment in the quadrilateral space. Case report. *J Neurosurg.* 1987; 66: 932-4
 21. Baker CL Jr1, Liu SH. Neurovascular injuries to the shoulder. *J Orthop Sports Phys Ther.* 1993; 18: 360-4
 22. Manske R C, Sumler A, Runge J: Quadrilateral Space Syndrome. *ATT.* 2009; 14: 45-47
 23. Chautems RC, Glauser T, Waeber-Fey MC, et al. Quadrilateral space syndrome: case report and review of the literature. *Ann Vasc Surg.* 2000; 14: 673-6
 24. Turker H, Sarica M, Bilgici A, et al. Axillary neuropathy mimicking quadrilateral space syndrome and its follow up for one year. *Neurosciences (Riyadh).* 2008; 13: 79-83
 25. Mochizuki T, Isoda H, Masui T, et al. Occlusion of the posterior humeral circumflex artery: detection with MR angiography in healthy volunteers and in a patient with quadrilateral space syndrome. *AJR Am J Roentgenol.* 1994; 163: 625-7
 26. Cothran RL Jr1, Helms C. Quadrilateral space syndrome: incidence of imaging findings in a population referred for MRI of the shoulder. *AJR Am J Roentgenol.* 2005; 184: 989-92
 27. Brestas PS, Tsouroulas M, Nikolakopoulou Z, et al. Ultrasound findings of teres minor denervation in suspected quadrilateral space syndrome. *J Clin Ultrasound.* 2006; 34: 343-7
 28. Groh GI, Simoni M, Rolla P, et al. Loss of the deltoid after shoulder operations: An operative disaster. *J Shoulder Elbow Surg.* 1994; 3: 243-53
 29. Resch H, Povacz P, Maurer H, et al. Pectoralis major inverse plasty for functional reconstruction in patients with anterolateral deltoid deficiency. *J Bone Joint Surg Br.* 2008; 90: 757-63
 30. Leffert RD: Neurologic problems, in Rockwood C A, Matsen III FA: *The Shoulder* 2nd Ed, 2 Volume. Philadelphia: WB Saunders, 1998, 982
 31. Steinmann SP, Moran EA. Axillary nerve injury: diagnosis and treatment. *J Am Acad Orthop Surg.* 2001; 9: 328-35
 32. Ferretti A, Cerullo G, Russo G. Suprascapular neuropathy in volleyball players. *J Bone Joint Surg Am.* 1987; 69: 260-3
 33. Holzgraefe M, Kukowski B, Eggert S. Prevalence of latent and manifest suprascapular neuropathy in high level volleyball players. *Br J Sports Med.* 1994; 28: 177-179
 34. Bailey LB, Beattie PF, Shanley E, et al. Current Rehabilitation Applications for Shoulder Ultrasound Imaging. *J Orthop Sports Phys Ther.* 2015 Jan 27:1-44. In press
 35. Monteleone G, Tramontana A, Mc Donald K, Sorge R, et al. Ultrasonographic evaluation of the shoulder in elite italian beach volleyball players. *J Sports Med Phys Fitness.* 2014 May 27. In press