

# A COMPLICATION FOLLOWING TOOTH EXTRACTION: CHRONIC SUPPURATIVE OSTEOMYELITIS

B. LORÈ<sup>1</sup>, M. GARGARI<sup>2</sup>, E. VENTUCCI<sup>1</sup>, A. CAGIOLI<sup>1</sup>, G. NICOLAI<sup>1</sup>, L. CALABRESE<sup>1,3,4</sup>

<sup>1</sup>Department of Oral and Maxillofacial Surgery, University of Rome "Tor Vergata", Rome, Italy

<sup>2</sup>Department of Dentistry "Fra G.B. Orsenigo Ospedale San Pietro F.B.F.", Rome, Italy

<sup>3</sup>Director of the Chair of Maxillofacial Surgery, University of Rome "Tor Vergata", Rome, Italy

<sup>4</sup>Director of the Chair of Oral Surgery, University of Rome "Tor Vergata", Rome, Italy

## SUMMARY

**A complication following tooth extraction: a case report of chronic suppurative osteomyelitis.**

**Objective.** This article presents a case report about the surgery treatment of chronic suppurative osteomyelitis following a tooth extraction.

**Methods.** Cone beam computed tomography revealed a sequestrum bone formation that required the sequestrectomy and the debridement of the involved area. The prescription of oral penicillin and metronidazole were necessary after and before the surgery. Also 20 sessions of hyperbaric oxygen therapy were important for the healing of the marrow space.

**Results.** The histologic test confirmed the diagnosis of "Chronic suppurative osteomyelitis". Clinically the post-operative course showed no complications but a good healing of the bone tissue. Culture reports revealed two microorganisms, streptococcus viridans and staphylococcus, that are sensitive to penicillin.

**Conclusions.** Clinical results confirmed the validity of the sequestrectomy and the debridement of the involved area for the treatment of chronic suppurative osteomyelitis. Such approach has always to be preferred because it guarantees the healing of bone tissue.

**Key words:** bone sequestrum, chronic osteomyelitis, sequestrectomy, complication tooth extraction.

## Introduction

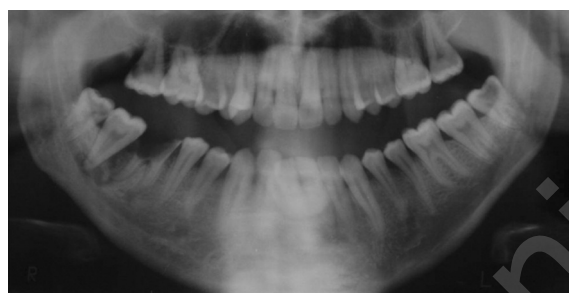Osteomyelitis can be defined as an inflammatory condition of the bone, which begins as an infection of the medullary cavity, rapidly involves the haversian systems and extends to involve the periosteum of the affected area (1). It can be classified as acute, subacute, or chronic, depending on the clinical presentation. The decline in prevalence can be attributed to the increased availability of antibiotics and the progressively higher standards of oral and dental health (2). Acute osteomyelitis, compared to chronic osteomyelitis, is differentiated arbitrarily based on time: an acute process occurs up to one month after the onset of symptoms and the chronic

process occurs for longer than one month (3, 4). Chronic osteomyelitis may be suppurative with abscess or fistula formation and sequestration at some stage of disease. The symptoms and clinical presentation may be less severe than those of an acute form, but most patients still present jaw pain, swelling and suppuration (5). Usually the bone undergoes sequestra formation and demonstrates significant changes radiographically.

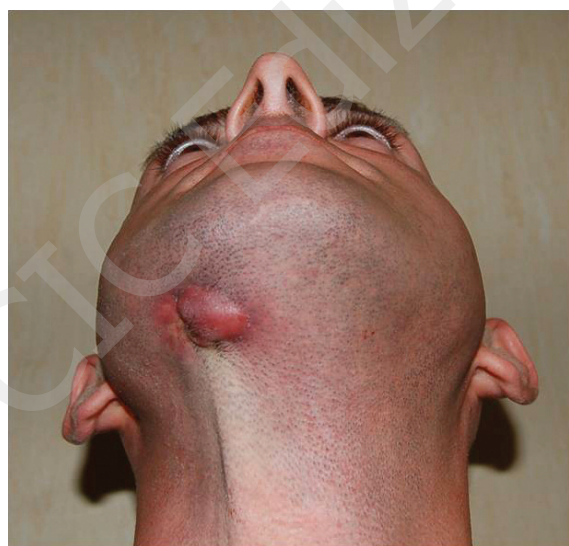
## Methods

A healthy 30-year-old man reported to the Department of Maxillofacial Surgery, Rome Tor Vergata, with long-standing pain, swelling and strain in the

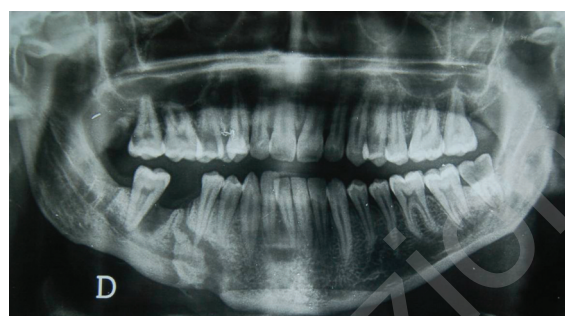submandibular and submasseteric region right for 2 months after the extraction of his tooth 46 (Figs. 1, 2). He had undergone treatment to his general dentist because of an incomplete healing during the post-extractive period, but there was no relief. Although the swelling was intermittent, the nature of pain was constant, extending to the mandible from the posterior region to the chin and, inferiorly, to the lower border which aggravated on eating food. On general examination, the patient was pale and weak also because of his poor nutrition. The cone beam computed tomography revealed the sequestrum formation that required surgical treatment (Figs. 3, 4); an extra-oral examination of the right side emphasized a mobile swelling which



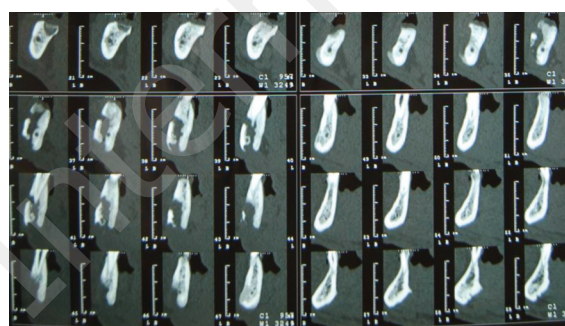
**Figure 1**  
Panoramic view before the extraction of tooth 46.



**Figure 2**  
Extraoral photograph of the patient showing swelling on right side of mandible.



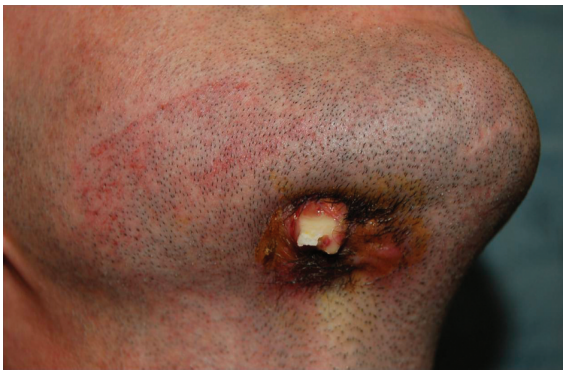**Figure 3**  
Panoramic view after the extraction of tooth 46.



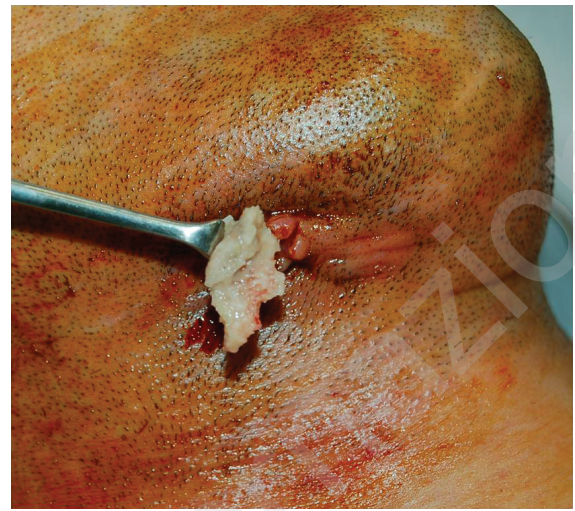
**Figure 4**  
CBCT revealing the bone sequestrum.

was hard in consistency, and the overlying skin color was erythematous likely infectious origin. Based on the history and radiographic/clinical examination, the diagnosis was chronic suppurative osteomyelitis. While waiting the surgery, the patient was prescribed a 1-month course of oral penicillin and metronidazole and 20 sessions of hyperbaric oxygen therapy (HBOT). Although the pain diminished considerably, right submandibular and submasseteric swelling was still apparent. After these medications, the patient was referred for surgery to remove sequestrum bone (Fig. 5) and to debride the involved area; also the teeth 45 and 47 were extracted because they were in contact with the infectious area (Figs. 6-8). Fresh bleeding was induced in the affected zone, and the tissue was sutured back. The necrotic bone was sent for histopathology, which confirmed the diagnosis of “chronic suppurative osteomyelitis”. The patient did very well postoperatively, showing immediate improvement in all infection-related symptoms.

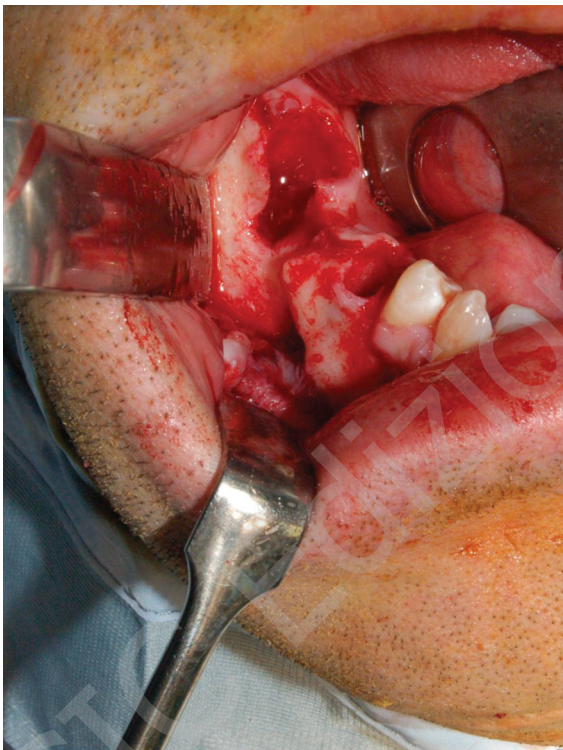




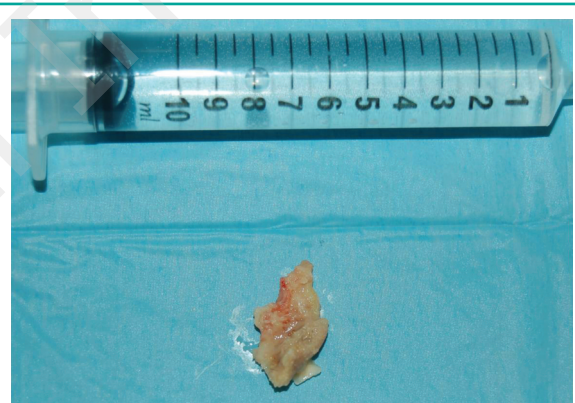
**Figure 5**  
Extra oral photograph of the patient showing the expulsion of bone sequestrum.



**Figure 7**  
Bone sequestrum removed.



**Figure 6**  
Intra operative photograph after extraction of teeth 45 and 47.



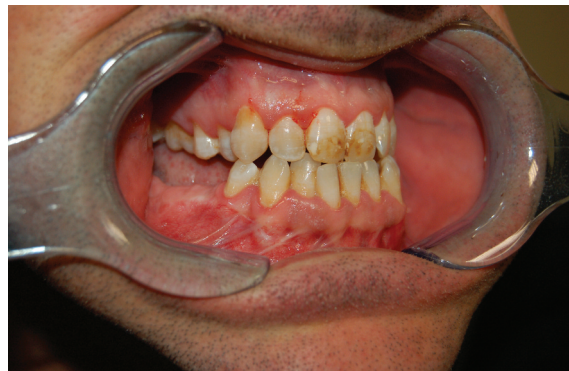**Figure 8**  
Bone sequestrum removed.

after every 3 days was kept for a period of 2 weeks and then weekly for a period of 3 months. The affected area showed complete healing clinically (Fig. 9) and a panoramic radiograph was taken. The radiograph showed healing in the area where previously sequestrum bone was present (Fig. 10).

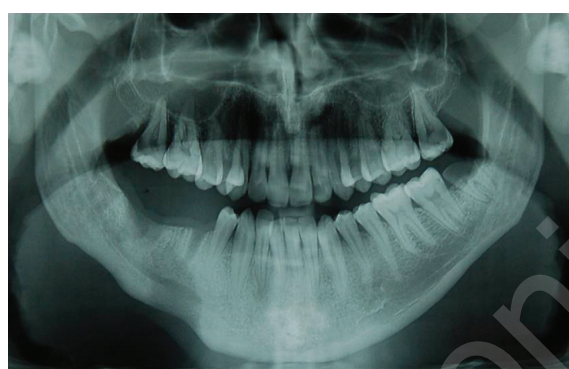## Discussion

Osteomyelitis of the jaw is a relatively uncommon inflammatory disease in developed countries (6).

Culture reports revealed two microorganism, streptococcus viridans and staphylococcus that are sensitive to penicillin. So the patient started intravenous penicillin each day and therapy was continued for five weeks. Analgesics and clorexidine 0,2% mouth wash were prescribed. A regular recall



**Figure 9**  
Clinic healing after 3 months from surgery.



**Figure 10**  
Panoramic view showing healing of bone tissue.

Marx and Mercuri (1991) were the first and only authors to define the duration of an acute osteomyelitis until it should be considered as chronic. They set an arbitrary time limit of 4 weeks after the onset of diseases (4). Acute and chronic osteomyelitis are much more relevant in the mandible than in the maxilla because of its poor vascularization and also because the dense mandibular cortical bone is more prone to damage and, therefore, to infection at the time of tooth extraction (7). The overall incidence of mandibular pyogenic osteomyelitis is up to 3 to 19 times greater than maxillary cases (8). In the mandible, the most common sites of the osteomyelitis are the body followed by the symphysis, angle, ascending ramus and condyle (9). Both sexes are affected almost equally based on overall data from demographic studies (8). Chronic osteomyelitis

cases are more frequent after the second decade of life peaking and this may correlate with changes of the immune and vascular health of the adult and aging patient (10).

The pathophysiology involves the accumulation of an inflammatory exudate in the bony medullary cavity and beneath the periosteum, causing compression of the central and peripheral blood supply to the bone. So there is a reduced supply of nutrients and oxygen because of the osseous bloody supply is compromised. This condition has the consequence of the necrotic bone. Necrotic tissue promotes the proliferation of bacteria, which, without an appropriate intervention, will result in incomplete healing and progression of the osteomyelitis. Also antibiotic cannot penetrate in this area so a surgery intervention is necessary. The aetiology can include bacterial infection (dental or bacteraemia from distant foci), vascular deficiency (localised endarteritis), autoimmune disease or trauma (11, 12).

The four primary factors which are responsible for deep bacterial invasion into the medullary cavity and cortical bone and hence the establishment of the infection are as follows: A) number of pathogens, B) virulence of pathogens, C) local and systemic host immunity, and D) local tissue perfusion. There are some conditions altering the vascularity of the bone and that predispose to osteomyelitis such as radiation, malignancy, osteoporosis, osteopetrosis, and Paget's disease. The differential diagnosis to diagnose chronic osteomyelitis includes benign (ossifying and non-ossifying fibroma, infection of the salivary glands and non-specific chronic lymphadenitis) and malignant (Ewing's sarcoma, osteosarcoma, chondrosarcoma, non-Hodgkin's lymphoma and metastatic disease) entities involving jaws by bone biopsy and culture (5, 13). The jaws are different from other bones' body in that the presence of the teeth creates a direct pathway for infectious and inflammatory agents to invade bone by caries and periodontal disease. The bacteria associated with infected dentition, such as periodontal pathogens including *Staphylococcus aureus*, *Staphylococcus epidermidis*, *Actinomyces*, *Prevotella* species and *Eikenella* species have been noted to be present in most chronic cases (10). Last two groups of bac-



teries become more prevalent in refractory forms of osteomyelitis of the jaws (14). While osteomyelitis in mandibula is considered a polymicrobial disease, in long bones it is attributed to *Staphylococcus Aureus* (6). *Candida* infections were also noted in some of the cases of osteomyelitis (10). In chronic forms of osteomyelitis, the inflammatory infiltrate is composed of plasma cells, lymphocytes and macrophages.

## Conclusions

The case described above demonstrates the typical features of chronic suppurative osteomyelitis. In the management of this patient, antibiotics and nonsurgical measures were used without success. Broad-spectrum antibiotics are important to combat *Staphylococcus*, *Actinomyces* and other bacteria. Adjunctive HBOT was used as an adjunct early in the management of this patient and it provided temporary pain relief. The goal of HBOT is to improve oxygen tension in hypoxic wounds, which in turn enhances vascular proliferation and fibroblastic activity and stimulates osteoclastic activity (15, 16). Furthermore, the ability of leukocytes to kill bacteria is improved at higher tissue oxygen tensions. In general, the benefits of HBOT validate its use as an adjunct to surgical and antimicrobial therapy in the management of refractory, chronic sclerosing and chronic suppurative osteomyelitis (17). Initial surgical treatment consisted of sequestrectomy and decortication in conjunction with intravenous antimicrobial therapy. These are valid procedures that are in agreement with protocols published by other authors (17).

## References

- Topazian RG. Osteomyelitis of jaws. In Topazian RG, Goldberg MH (eds). *Oral and maxillofacial infections*, 3rd ed. pp 251-286. Philadelphia, PA: Saunders, 1994.
- Yeoh SC, Mac Mahon S, Schifter M. Chronic suppurative osteomyelitis of the mandible: Case report. *Aust Dent J* 2005; 50:200-3.
- Marx RE. Chronic osteomyelitis of the jaws. *Oral Maxillofac Surg Clin North Am* 1991; 3:367.
- Mercuri LG. Acute osteomyelitis of the jaws. *Oral Maxillofac Surg Clin North Am* 1991; 3:355.
- Baltensperger M, Eyrich G. Osteomyelitis of the Jaws: definitions and classification. In: Baltensperger M, Eyrich G, editors. *Osteomyelitis of jaws*. Berlin: Springer 2009; p. 5-56.
- Scolozzi P, Lombardi T, Edney T, Jaques B. Enteric bacteria mandibular osteomyelitis. *Oral Surg Oral Med Oral Pathol Oral Radiol Endod* 2005; 99:E42-46.
- Krakowiak P. Alveolar Osteitis and Osteomyelitis of the jaws. *Oral Maxillofac Surg Clin N AM* 23 2011; 401-413.
- Koorbusch GF, Fotos P, Gool KT. Retrospective assessment of osteomyelitis: etiology, demographics risk factors and management in 35 cases. *Oral Surgery Oral Med Oral Pathol* 1992; 74:149-54.
- Baltersperger MA. Retrospective analysis of 290 osteomyelitis cases treated in the past 30 years at the department of craniomaxillofacial surgery Zurich with special recognition of the classification. *Med Dissertation Zurich* 2003; 1:1-35.
- Uche C, Mogyoros R, Chang A, et al. Osteomyelitis of the jaw: a retrospective analysis. *Int J Infect Dis* 2009; 7:2.
- Bevin CR, Inwards CY, Keller EE. Surgical management of primary chronic osteomyelitis: a long-term retrospective analysis. *J Oral Maxillofac Surg* 2008; 66:2073-2085.
- Lucchesi L, Kwok J. Long term antibiotics and calcitonin in the treatment of chronic osteomyelitis of the mandible: case report. *Br J Oral Maxillofac Surg* 2008; 46:400-402.
- Waldvogel FA, Medoff G, Swartz MN. Osteomyelitis: a review of clinical features, therapeutic considerations and unusual aspects ( parts 1 and 2 ). *N Engl J Med* 1970; 282:198-206.
- Marx RE, Carlson ER, Smith BR, Toraya N. Isolation of *Actinomyces* species and *Eikenella corrodens* from patients with chronic diffuse sclerosing osteomyelitis. *J Oral Maxillofac Surg* 1994; 52(1):26-33.
- Triplett RG, Branham GB, Gillmore JD, Lorber M. Experimental mandibular osteomyelitis: therapeutic trials with hyperbaric oxygen. *J Oral Maxillofac Surg* 1982; 40(10):640-6.
- Gill AL, Bell CN. Hyperbaric oxygen: its uses, mechanisms of action and outcomes. *QJM* 2004; 97(7):385-95.
- van Merkesteyn JP, Groot RH, van den Akker HP, Bakker DJ, Borgmeijer-Hoelen AM. Treatment of chronic suppurative osteomyelitis of the mandible. *Int J Oral Maxillofac Surg* 1997; 26(6):450-4.

Correspondence to:  
Alessandro Cagioli  
E-mail: dott.alessandrocagioli@hotmail.it