

Short-term effects produced by rapid maxillary expansion and facemask therapy in Class III patients with different vertical skeletal relationships

Chiara Pavoni^a; Caterina Masucci^b; Silvia Cerroni^c; Lorenzo Franchi^d; Paola Cozza^e

ABSTRACT

Objective: To evaluate the dentoskeletal short-term effects of rapid maxillary expansion and facemask therapy (RME/FM) in a sample of Class III patients showing different vertical skeletal relationships.

Materials and Methods: Seventy-nine patients (35 females and 44 males) having Class III malocclusion were consecutively treated using RME/FM therapy with application of the protraction force in a downward and forward direction and inclination of about 30° to the occlusal plane. All patients were evaluated at the beginning (T1; mean age, 7.7 years) and at the end (T2; mean age, 9.2 years) of orthopedic therapy and divided into three groups according to their vertical skeletal relationships: normal group (NG), hypodivergent group (HypoG), and hyperdivergent group (HyperG). Statistical comparisons between the three groups were performed on the starting forms (T1), the final forms (T2), and the treatment changes (T1–T2) using the ANOVA with Tukey's post hoc tests.

Results: Favorable modification in terms of maxillary advancement (changes in SNA ranging from 1.4° to 1.8°) and intermaxillary sagittal skeletal relationships (changes in Wits appraisal ranging from 2.5 mm to 3.5 mm) were recorded in all groups. The three groups showed no statistically significant differences in changes in either sagittal or vertical skeletal variables.

Conclusions: The various vertical skeletal features do not influence the short-term outcomes of RME/FM therapy. (*Angle Orthod.* 2014;87:000–000.)

KEY WORDS: Class III malocclusion; Orthopedic treatment; Facemask

INTRODUCTION

Several orthopedic treatment approaches for patients presenting with Class III dentoskeletal disharmony have

^a Research Fellow, Department of Clinical Sciences and Translational Medicine, University of Rome "Tor Vergata," Italy.

^b Research Fellow, Department of Surgery and Translational Medicine, University of Florence, Florence, Italy.

^c Graduate Student, Department of Clinical Sciences and Translational Medicine, University of Rome "Tor Vergata," Italy.

^d Assistant Professor, Department of Surgery and Translational Medicine, University of Florence, Florence, Italy, and Thomas M. Graber Visiting Scholar, Department of Orthodontics and Pediatric Dentistry, School of Dentistry, University of Michigan, Ann Arbor, Mich.

^e Professor and Chair, Department of Clinical Sciences and Translational Medicine, University of Rome "Tor Vergata," Rome, Italy.

Corresponding author: Dr Lorenzo Franchi, Department of Surgery and Translational Medicine, University of Florence, Via del Ponte di Mezzo, 46-48, Florence, Italy 50127 (e-mail: lorenzo.franchi@unifi.it)

Accepted: December 2013. Submitted: July 2013.

Published Online:

© 2014 by The EH Angle Education and Research Foundation, Inc.

been reported in the literature.¹ Maxillary protraction with the facemask (FM) with^{2–5} or without^{6–7} rapid maxillary expansion (RME) has gained popularity among clinicians during the last 30 years for the correction of Class III malocclusion.

Most of the studies^{2–5} on the effects of posteroanterior traction of the maxillary complex in Class III patients have demonstrated that improvement in intermaxillary sagittal skeletal relationships was associated with an increase in vertical skeletal relationships, which can be particularly unfavorable in hyperdivergent Class III patients. Tanne et al.,⁸ using finite element analysis applied to a dry skull, found that upward displacement of the maxillary complex during protraction can be counteracted by a downward force of approximately 30°. Clinical studies shown that the application of a protraction force in a downward and forward direction with an inclination of 15°–30° to the occlusal plane produces a counterclockwise rotation of the palatal plane ranging from –1.4°^{3,5} to –0.9°² and is associated with a clockwise rotation of the mandibular plane ranging from 1.0°⁴ to 2.3°.³ Only the study by Westwood et al.³ reported a clockwise rotation of the

Table 1. Sample Demographics

	Total (n = 79)		NG ^a (n = 29)		HypoG ^a (n = 25)		HyperG ^a (n = 25)	
	Mean	SD	Mean	SD	Mean	SD	Mean	SD
Age at T1 (y)	7.7	1.9	7.9	1.8	7.1	1.5	8.3	2.3
Age at T2 (y)	9.2	1.9	9.4	0.5	8.6	0.4	9.7	0.5
T1–T2 interval (y)	1.5	0.5	1.5	0.5	1.5	0.4	1.4	0.5

^a NG indicates normal group; HypoG, hypodivergent group; HyperG, hyperdivergent group.

palatal plane (of 2.0°). There is currently a lack of data in the literature about the response of various vertical skeletal types to Class III orthopedic therapy.

Yoshida et al.⁹ evaluated a sample of 42 Japanese girls with Class III malocclusion (mean age, 10.1 years) who were previously divided into two groups according to different vertical craniofacial features (low and high mandibular plane angle groups). All patients were treated with chin cap and maxillary protraction. Statistically significant differences were found between the two groups, with the low mandibular plane angle group showing a greater forward maxillary displacement and a larger increment of the maxillary body than did the high mandibular plane angle group. However, the sample size in the two groups was small and they included only female patients with the low mandibular plane angle group comprising both hypodivergent subjects and subjects with normal vertical skeletal relationships. No study evaluated the response of different vertical skeletal types to Class III orthopedic therapy with RME/FM.

The present retrospective study, therefore, was designed to evaluate the dentoskeletal short-term effects produced by RME/FM therapy in a large sample of Class III patients showing different vertical skeletal relationships.

MATERIALS AND METHODS

Sample size determination was calculated on the basis of an effect size of 0.9 for the variable Wits appraisal,¹⁰ an alpha level of 0.05, and a power of 0.80. The minimum sample size for the three groups was 25 patients (SigmaStat 3.5, Systat Software, Point Richmond, Calif). This study was approved by the Ethics Committee of the University of Florence, (75.14, April 29, 2014).

A sample of 79 patients (35 females and 44 males) with Class III dentoskeletal disharmony were treated consecutively with RME/FM therapy at the Department of Orthodontics of the University of Florence. All patients presented with the following features before therapy (T1) when the pretreatment lateral cephalogram was taken: European ancestry, anterior crossbite or edge-to-edge incisor relationship, Class III molar relationship, Wits appraisal¹¹ of –2.0 mm or less, no discrepancy between centric occlusion and centric

relation (indicating no pseudo Class III malocclusion), and prepubertal skeletal maturation (CS1–CS3).¹² Exclusion criteria were craniofacial anomalies, psychosocial impairment, congenitally missing permanent teeth, and extracted permanent teeth.

The mean age of the patients at T1 was 7.7 ± 1.9 years, and they were divided into three groups according to their vertical skeletal relationships:¹³

- NG, consisting of 29 patients (12 females and 17 males; 89.7% at CS1, 6.9% at CS2, and 3.4% at CS3) with SN to mandibular plane between 32° and 38°
- HypoG, comprising 25 patients (15 females and 10 males; 92.0% at CS1, 4.0% at CS2, and 4.0% at CS3) with SN to mandibular plane less than 32°
- HyperG, consisting of 25 patients (8 females and 17 males; 88.0% at CS1, 8.0% at CS2, and 4.0% at CS3) with SN to mandibular plane more than 38°.

All patients were reevaluated with a lateral cephalogram at the end of active treatment (T2).

The three groups were matched as to skeletal maturation at the various time periods, gender distribution, and duration of treatment intervals. Skeletal maturation was assessed by means of the cervical vertebral maturation (CVM) method. Twelve CVM stages for each headfilm were assessed by two calibrated observers (L.F. and C.M.). The mean ages at the two observation times and the duration of the observation intervals for the three groups are given in Table 1.

Treatment Protocol

The three components of the RME/FM therapy used in this study were a maxillary expansion appliance, an FM, and heavy elastics.¹⁴ Treatment started with the placement of a bonded or banded maxillary expander (Leone A2620, Leone Orthodontic Products, Sesto Fiorentino, Florence, Italy) to which vestibular hooks were soldered in the canine region (Figures 1 and 2). The patients' parents were instructed to activate the expander once or twice daily until overcorrection of the transverse width was achieved (palatal cusps of the maxillary posterior teeth approximating the buccal cusps of the mandibular posterior teeth).¹⁴ In patients not requiring expansion, the expansion screw was not

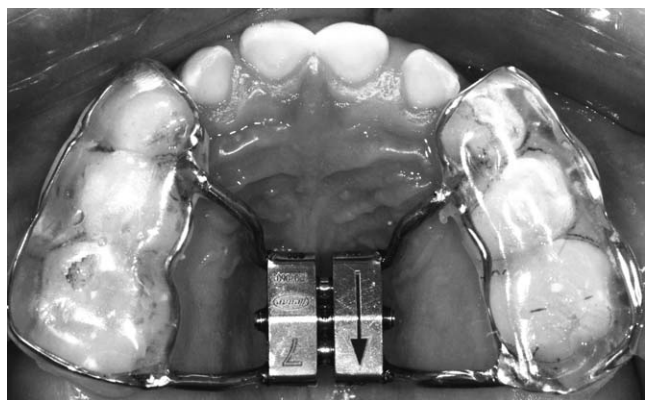


Figure 1. Occlusal view of bonded maxillary expander.

activated. During FM treatment, a lower removable bite-block was used on all patients treated with a banded maxillary expander. The use of a lower removable bite-block facilitates correction of occlusal relationships in the presence of anterior or posterior crossbites. Moreover, it has been shown¹⁵ that both the bite-block and the splinted RME limit the posterior rotation of the mandible typically produced by FM therapy.

At the end of the expansion phase, the patients were fitted with an FM (Dynamic Facemask, Leone Orthodontic Products, Sesto Fiorentino, Florence, Italy) with pads fitted to the chin and forehead for support (Figure 3). Elastics were attached from soldered hooks on the expander to the support bar of the FM in a downward and forward direction, producing orthopedic force levels up to 400 g–500 g per side. Inclination of the extraoral elastics was at about 30° to the occlusal plane in order to counteract the counterclockwise rotation of the maxilla.⁸ Patients were instructed to wear the FM for a minimum of 14 hours per day. All patients were treated to at least a positive dental overjet before discontinuing treatment; most patients

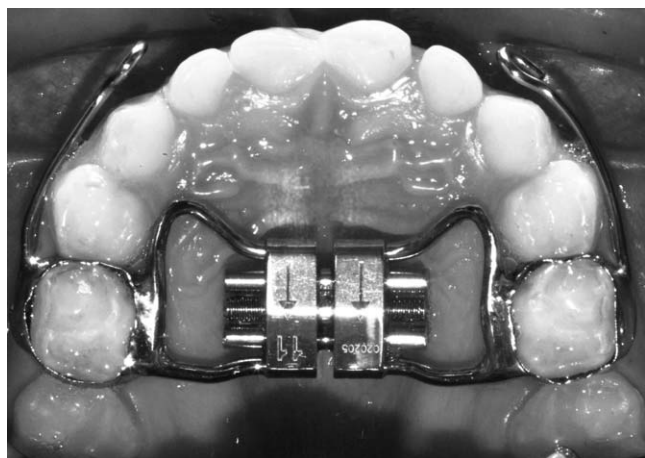


Figure 2. Occlusal view of banded maxillary expander.

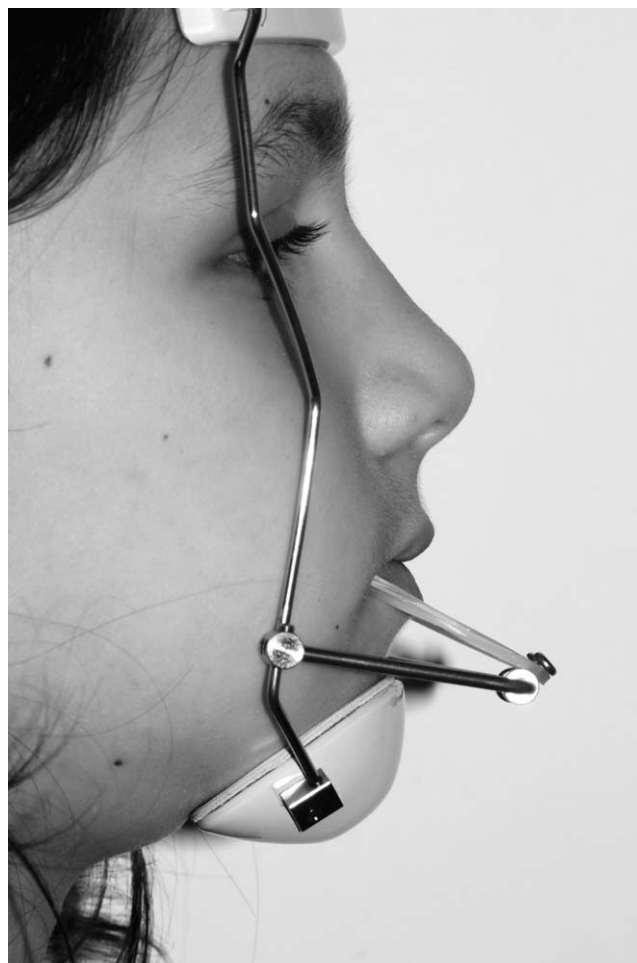


Figure 3. Extraoral lateral view of facemask.

were overcorrected toward a Class II occlusal relationship. Average duration of the RME/FM treatment was 1.1 years \pm 5 months.

Cephalometric Analysis

A customized digitization regimen and cephalometric analysis provided by Viewbox (version 3.0, dHAL Software, Kifissia, Greece) was used for all cephalograms examined in this study. The customized cephalometric analysis included 13 variables, 7 angular and 6 linear, for each tracing. Magnification was 10% for all cephalograms in all treated samples. 4

Method Error

Twenty lateral headfilms, selected randomly, were traced and measured twice within a week by the same operator (C.M.). The measurements at both times for each patient were analyzed with the paired *t*-test for assessment of the systematic error and with the method of moments' estimator (MME)¹⁶ for assessing the random error. No systematic error was detected for

Table 2. Descriptive Statistics and Statistical Comparisons of Starting Forms (ANOVA with Tukey's Post Hoc Tests)

Variables	NG (1) (n = 29)		HypoG (2) (n = 25)		HyperG (3) (n = 25)		P	1vs2	2vs3	1vs3
	Mean	SD	Mean	SD	Mean	SD				
Sagittal skeletal										
SNA (°)	80.7	3.2	81.2	3.9	79.2	3.0	0.100	NS	NS ^b	NS
A to NPerp ^a (mm)	1.0	2.7	0.2	2.4	0.3	2.8	0.417	NS	NS	NS
SNB (°)	79.4	2.8	81.1	3.2	77.1	2.7	0.000	NS	***	*
Pg to NPerp (mm)	-0.5	4.4	0.5	3.8	-3.4	5.7	0.014	NS	*	NS
ANB (°)	1.3	1.4	0.1	2.0	2.1	2.1	0.001	NS	***	NS
WITS (mm)	-6.3	2.3	-5.1	2.1	-6.4	3.2	0.149	NS	NS	NS
Co-Gn (mm)	106.8	6.7	103.7	5.6	106.7	6.2	0.122	NS	NS	NS
Vertical skeletal										
SN to palatal plane (°)	8.0	3.9	7.1	2.7	9.9	3.4	0.015	NS	*	NS
SN to mandibular plane (°)	35.6	1.3	30.0	2.0	41.2	2.4	0.000	***	***	***
Palatal plane to mandibular plane (°)	27.5	3.6	22.8	3.5	31.3	3.7	0.000	***	***	***
Co-Go (mm)	48.7	4.2	48.6	3.3	46.8	3.2	0.121	NS	NS	NS
Co-Go-Me (°)	129.8	4.0	126.5	3.9	133.4	4.3	0.000	**	***	**
Interdental molar relationship (mm)										
	3.0	1.7	2.9	1.4	3.4	1.7	0.587	NS	NS	NS

^a NPerp indicates nasion perpendicular.

^b NS indicates not significant; * P <0.05; ** P <0.01; *** P <0.001.

any of the variables, with *P* values ranging from a minimum of 0.062 (SN to palatal plane) to a maximum of 0.871 (palatal plane to mandibular plane). Values for the MME ranged from a minimum of 0.21° (SN to palatal plane) to a maximum of 0.95° (Co-Go-Me).

Statistical Analysis

Descriptive statistics were calculated for chronologic age at T1, T2, and for the T1–T2 observation intervals in all groups. Differences in distribution of gender and the CVM stages between the three groups were tested with the chi-square test.

5 The preliminary assessment of data at T1, T2, and T2–T1 changes revealed the presence of both normal distribution (Kolmogorov-Smirnov test) and equality of variances (Levene's test) for all the variables. Between-group comparisons on the starting forms, final forms, and treatment changes (T1–T2) were assessed using the ANOVA with Tukey's post hoc tests.

All statistical computations were performed with statistical software (SPSS version 12.0, SPSS, Chicago, Ill; and SigmaStat 3.5, Systat Software, Point Richmond, Calif).

RESULTS

No significant differences between the three groups were found for gender distribution (chi-square, 2.993; *P* = 0.224) or for distribution of the CVM stages (chi-square, 0.377; *P* = 0.984).

At T1 (Table 2), the three groups showed statistically significant differences in craniofacial vertical relationships. The inclination of palatal plane to the

cranial base (SN to palatal plane) was significantly greater (2.8°) in the HyperG than in the HypoG. The mandibular plane angle (SN to mandibular plane) and the intermaxillary divergency angle (palatal plane to mandibular plane) were significantly larger in the HyperG than in the other two groups (vs NG, 5.6° and 3.8°, respectively; vs HypoG, 11.2° and 8.5°, respectively) and in the NG with respect to the HypoG (5.6° and 4.7°, respectively). The Co-Go-Me angle was significantly greater in the HyperG compared with the other two groups (vs NG, 3.6°; vs HypoG, 6.9°) and in the NG with respect to the HypoG (3.3°). Consistent with the vertical skeletal features, the SNB angle was significantly smaller in the HyperG with respect to both the NG (-2.3°) and the HypoG (-4.0°), and Pg point to nasion perpendicular (Nperp) was significantly smaller in the HyperG than in the HypoG (-3.9 mm). The ANB angle was significantly smaller in the HypoG compared with the other two groups (vs NG, -1.2°; vs HyperG, -2.0°).

At the end of active treatment (T2), statistically significant differences between the three groups were found (Table 3). The HyperG showed a significantly greater inclination of palatal plane to cranial base than did the HypoG (2.6°). The mandibular plane angle and the palatal plane to mandibular plane angle were significantly larger in the HyperG compared with the other two groups (vs NG, 5.7° and 3.9°, respectively; vs HypoG, 11.0° and 8.5°, respectively), and in the NG with respect to the HypoG (5.3° and 4.6°, respectively). The HyperG presented with a significantly greater Co-Go-Me angle than did the other two groups (vs NG, 3.7°; vs HypoG, 7.6), while the NG showed a significantly larger Co-Go-Me angle than did the

Table 3. Descriptive Statistics and Statistical Comparisons of Final Forms (ANOVA with Tukey's Post Hoc Tests)

Variables	NG (1) (n = 29)		HypoG (2) (n = 25)		HyperG (3) (n = 25)		P	1 vs 2	2 vs 3	1 vs 3
	Mean	SD	Mean	SD	Mean	SD				
Sagittal skeletal										
SNA (°)	82.1	3.7	83.0	4.1	80.7	3.2	0.095	NS	NS	NS
A to NPerp (mm)	2.3	2.9	1.9	2.8	2.2	3.3	0.891	NS	NS	NS
SNB (°)	78.5	3.1	79.7	3.2	76.1	2.6	0.000	NS	***	*
Pg to NPerp (mm)	-1.7	4.5	-1.4	3.8	-4.4	5.1	0.040	NS	*	NS
ANB (°)	3.6	1.5	3.3	2.3	4.6	2.5	0.071	NS	NS	NS
WITS (mm)	-3.8	2.6	-2.5	2.8	-2.9	3.8	0.308	NS	NS	NS
Co-Gn (mm)	110.2	6.9	106.7	6.1	110.4	6.9	0.085	NS	NS	NS
Vertical skeletal										
SN to palatal plane (°)	7.1	4.2	6.5	3.5	9.1	3.2	0.036	NS	*	NS
SN to mandibular plane (°)	36.6	2.0	31.3	2.9	42.3	2.8	0.000	***	***	***
Palatal plane to mandibular plane (°)	29.3	3.9	24.7	3.7	33.2	3.5	0.000	***	***	***
Co-Go (mm)	50.5	4.1	50.4	3.4	49.3	3.5	0.418	NS	NS	NS
Co-Go-Me (°)	127.8	4.3	123.9	4.7	131.5	3.9	0.000	**	***	**
Interdental molar relationship (mm)										
	-0.6	2.3	-0.9	2.2	0.0	2.6	0.410	NS	NS	NS

^a NS indicates not significant; * *P* < 0.05; ** *P* < 0.01; *** *P* < 0.001.

HypoG (3.9°). The SNB angle was significantly smaller in the HyperG with respect to the other two groups (vs HypoG, -3.6°; vs NG, -2.4°). As for the sagittal position of Pg (Pg to NPerp), HyperG showed a more retruded Pg point than did HypoG (-3.0 mm).

As for the T1-T2 changes shown in Table 4, no statistically significant differences were found between the three groups for any of the cephalometric variables.

DISCUSSION

Skeletal effects of orthopedic treatment of Class III malocclusion in growing subjects still represents a

controversial topic in orthodontics. Several authors²⁻⁵ who investigated the effects of RME/FM therapy applied the FM protraction force in a downward and forward direction with an inclination of 15°-30° to the occlusal plane in order to limit the increase in vertical skeletal relationships associated with maxillary protraction with FM.²⁻⁷ Results provided by most of the studies^{2-3,5} carried out on this topic are quite consistent. However, these data refer to samples of Class III patients who were examined regardless of their vertical skeletal features.

The present study, therefore, was designed to evaluate the dentoskeletal short-term effects produced by RME/FM therapy in a large sample of Class III

Table 4. Descriptive Statistics and Statistical Comparisons of T1-T2 Changes (ANOVA with Tukey's Post Hoc Tests)

Variables	NG (1) (n = 29)		HypoG (2) (n = 25)		HyperG (3) (n = 25)		P	1 vs 2	2 vs 3	1 vs 3
	Mean	SD	Mean	SD	Mean	SD				
Sagittal skeletal										
SNA (°)	1.4	1.8	1.8	1.3	1.5	1.7	0.661	NS ^a	NS	NS
A to NPerp (mm)	1.3	1.8	1.8	1.6	1.9	2.4	0.485	NS	NS	NS
SNB (°)	-0.9	1.5	-1.4	1.9	-1.0	1.2	0.482	NS	NS	NS
Pg to NPerp (mm)	-1.2	2.8	-1.9	2.4	-1.1	3.0	0.511	NS	NS	NS
ANB (°)	2.3	1.4	3.2	1.8	2.5	2.0	0.163	NS	NS	NS
WITS (mm)	2.5	2.6	2.6	2.3	3.5	3.5	0.375	NS	NS	NS
Co-Gn (mm)	3.3	2.2	3.0	2.1	3.7	1.7	0.511	NS	NS	NS
Vertical skeletal										
SN to palatal plane (°)	-0.9	2.2	-0.6	1.7	-0.8	2.3	0.860	NS	NS	NS
SN to mandibular plane (°)	1.0	1.5	1.3	2.2	1.1	1.8	0.788	NS	NS	NS
Palatal plane to mandibular plane (°)	1.8	1.6	1.8	2.4	1.9	2.3	0.969	NS	NS	NS
Co-Go (mm)	1.9	2.2	1.9	1.7	2.5	2.3	0.454	NS	NS	NS
Co-Go-Me (°)	-2.0	2.2	-2.6	2.5	-1.9	3.5	0.666	NS	NS	NS
Interdental										
Molar relationship (mm)	-3.6	2.1	-3.8	2.3	-3.4	2.6	0.802	NS	NS	NS

^a NS indicates not significant.

patients showing different vertical skeletal relationships. The study sample, including 79 patients (35 females and 44 males; mean age, 7.7 ± 1.9 years) with Class III dentoskeletal disharmony, was divided into three groups (normal group [NG], HypoG, and HyperG) according to the vertical skeletal features at the beginning of treatment (T1). The statistically significant differences between the three groups at T1 confirmed the various vertical skeletal characteristics of each group.

At the end of active therapy (T2), between-group differences were consistent with those shown by the three groups at T1, excepting the ANB angle, which did not show statistically significant differences between the three groups. As for the skeletal vertical variables at T2, HyperG presented with significantly greater vertical skeletal relationships than did the other two groups. Similarly, NG exhibited significantly greater vertical skeletal relationships than did HypoG. HyperG presented with significantly greater mandibular retrusion than did the other two groups. These differences in mandibular sagittal relationships, as at T1, were consistent with the different vertical skeletal pattern shown by the three groups.

As for the T1–T2 changes, favorable modifications in terms of maxillary advancement (changes in SNA ranging from 1.4° to 1.8°) and intermaxillary sagittal skeletal relationships (changes in Wits Appraisal, ranging from 2.5 mm to 3.5 mm) were recorded in all groups. These results are consistent with the outcomes of several studies that evaluated the effects of RME/FM therapy in growing patients.^{2–5} In the present study, no statistically significant differences between the three groups were found for changes in the maxillary sagittal position or in the intermaxillary sagittal relationships. These findings differ from those reported by Yoshida et al.,⁹ who evaluated a sample of 10-year-old Japanese females treated with a chin cap and maxillary protraction appliance and divided into two groups according to their vertical skeletal features (low mandibular angle group and high mandibular angle group). The authors found a greater forward maxillary displacement (SNA, 2.5° ; A to Nperp, 2.6 mm), a larger increase in maxillary body size (A-Ptm, 2.2 mm) and a greater improvement in intermaxillary sagittal relationships (ANB, 4.1°) in the low mandibular angle group than in the high mandibular angle group (SNA, 1.7° ; A to Nperp, 1.6 mm; A-Ptm, 1.3 mm; ANB, 2.8°).

In the present study, no statistically significant differences in changes produced by RME/FM therapy in terms of either sagittal position of the mandible (SNB) or control of mandibular growth (Co-Gn) were found between the three groups. These findings are similar to those reported by Yoshida et al.⁹

The three groups showed no statistically significant differences regarding changes in the vertical skeletal variables. A counterclockwise rotation of the maxilla (SN to palatal plane), although less than 1° , was registered in the present investigation. These results are consistent with the data reported in the other studies^{2,3,5} that applied the FM protraction force in a downward a forward direction at 15° – 30° to the occlusal plane. Only Westwood et al.⁴ reported a clockwise rotation of the maxilla (FH to palatal plane, 1.0°).

Our study reported an increase in the mandibular plane angle smaller than 1.5° and an increase in intermaxillary skeletal relationships smaller than 2.0° during the active phase of orthopedic treatment with the RME/FM. These findings are consistent with those found by other investigators who analyzed the short-term effects of RME/FM therapy^{2,3,5} and with those reported by Yoshida et al.⁹ In this latter study,⁹ the authors did not report any significant differences for vertical skeletal modifications between the two examined groups (low mandibular angle group and high mandibular angle group).

The results of our investigation indicate that the use of a correct downward and forward inclination of the extraoral elastics of the FM (30° to the occlusal plane) limited the negative side effects of RME/FM treatment in terms of bite opening tendency in the treated groups regardless of the vertical skeletal relationships at T1.

The present study analyzed the skeletal effects produced by RME/FM therapy in three groups of patients with different skeletal vertical relationships in the short term. It is interesting to note that the HyperG did not show more unfavorable skeletal outcomes than did the other groups in the short-term evaluation. The correct direction and inclination of the extraoral elastics applied to the FM limited the negative side effects of RME/FM treatment in terms of bite opening in all three groups. Reestablishment of the unfavorable Class III growth pattern during the pubertal growth spurt,¹⁷ along with the presence of a hyperdivergent facial type, might play an important role in the stability of treatment effects long-term. A long-term study on the predictive variables of RME/FM treatment effects by Baccetti et al.¹⁸ reported that orthopedic therapy of Class III malocclusion can lead to less favorable craniofacial changes when at the start of treatment the patient shows a long mandibular ramus associated with a large posterior cranial base angle and a high mandibular plane angle. The important role of vertical skeletal relationships in determining the long-term stability of the effects of early orthopedic treatment in Class III malocclusion still needs to be elucidated.

CONCLUSIONS

- The various vertical skeletal features do not influence the short-term outcomes of RME/FM therapy.
- All three groups exhibited the same amount of maxillary advancement and correction of the intermaxillary sagittal relationship along with similar changes in mandibular size and position.
- The three groups showed no differences in the vertical skeletal effects of RME/FM therapy.

REFERENCES

1. Toffol L, Pavoni C, Baccetti T, Franchi L, Cozza P. Orthopedic treatment outcomes in Class III malocclusion; a systematic review. *Angle Orthod*. 2008;78:561–573.
2. Ngan P, Yiu C, Hu A, Hägg U, Wei SHY, Gunel E. Cephalometric and occlusal changes following maxillary expansion and protraction. *Eur J Orthod*. 1998;20:237–254.
3. Macdonald KE, Kapust AJ, Turley PK. Cephalometric changes after the correction of Class III malocclusion with maxillary expansion/facemask therapy. *Am J Orthod Dentofacial Orthop*. 1999;116:13–24.
4. Westwood PV, McNamara JA Jr, Baccetti T, Franchi L, Sarver DM. Long-term effects of Class III treatment with rapid maxillary expansion and facemask therapy followed by fixed appliances. *Am J Orthod Dentofacial Orthop*. 2003;123:306–320.
5. Vaughn GA, Mason B, Moon HB, Turley PK. The effects of maxillary protraction therapy with or without rapid palatal expansion: a prospective, randomized clinical trial. *Am J Orthod Dentofacial Orthop*. 2005;128:299–309.
6. Kilikoglu H, Kirlic Y. Profile changes in patients with Class III malocclusion after Delaire mask therapy. *Am J Orthod Dentofacial Orthop*. 1998;113:453–462.
7. Cozza P, Baccetti T, Mucedero M, Pavoni C, Franchi L. Treatment and posttreatment effects of a facial mask combined with a bite-block appliance in Class III malocclusion. *Am J Orthod Dentofacial Orthop*. 2010;138:300–310.
8. Tanne K, Hiraga J, Sakuda M. Effects of directions of maxillary protraction forces on biomechanical changes in craniofacial complex. *Eur J Orthod*. 1989;11:382–391.
9. Yoshida I, Shoji T, Mizoguchi I. Effects of treatment with a combined maxillary protraction and chin cap appliance in skeletal Class III patients with different vertical skeletal morphologies. *Eur J Orthod*. 2007;29:126–133.
10. Cohen J. A power primer. *Psychol Bull*. 1992;112:155–159.
11. Jacobson A. Application of the “Wits” appraisal. *Am J Orthod*. 1976;70:179–189.
12. Baccetti T, Franchi L, McNamara JA Jr. The cervical vertebral maturation (CVM) method for the assessment of optimal treatment timing in dentofacial orthopedics. *Semin Orthod*. 2005;11:119–129.
13. Tollaro I, Baccetti T, Franchi L. Cephalometric “floating norms” for Italian subjects in the deciduous and mixed dentition. *Ortognatodonzia Italiana*. 1997;6:513–524.
14. McNamara JA Jr, Brudon WL. *Orthodontics and Dentofacial Orthopedics*. Ann Arbor, Mich: Needham Press. 2001: 375–385.
15. Pavoni C, Mucedero M, Baccetti T, Franchi L, Polimeni A, Cozza P. The effects of facial mask/bite block therapy with or without rapid palatal expansion. *Prog Othod*. 2009;10: 20–28.
16. Springate SD. The effect of sample size and bias on the reliability of estimates of error: a comparative study of Dahlberg’s formula. *Eur J Orthod*. 2012;34:158–163.
17. Baccetti T, Franchi L, McNamara JA Jr. Growth in the untreated Class III subject. *Semin Orthod*. 2007;13: 130–142.
18. Baccetti T, Franchi L, McNamara JA Jr. Cephalometric variables predicting the longterm success or failure of combined rapid maxillary expansion and facial mask therapy. *Am J Orthod Dentofacial Orthop*. 2004;126: 16–22.

Authors QueriesJournal: **Angle Orthodontist**Paper: **angl-87-02-12**Title: **Short-term effects produced by rapid maxillary expansion and facemask therapy in Class III patients with different vertical skeletal relationships**

Dear Author

During the preparation of your manuscript for publication, the questions listed below have arisen. Please attend to these matters and return this form with your proof. Many thanks for your assistance

Query Reference	Query	Remarks
1	Author: This article has been lightly edited for grammar, style, and usage. Please compare it with your original document and make changes on these pages. Please limit your corrections to substantive changes that affect meaning. If no change is required in response to a question, please write "OK as set" in the margin. Copy editor	
2	Author: Please define CS1, CS2, and CS3. Copy editor	
3	Author: Please explain significance of red numbers. Copy editor	
4	Author: It might be helpful to include a glossary of cephalometric points and planes. Copy editor	
5	Author: Do you mean "T1-T2"? Copy editor	