

C. Pavoni, M. Mucedero, V. Paoloni, P. Cozza

Department of Orthodontics, University of Rome Tor Vergata,  
Rome, Italy

e-mail: chiarapavoni@libero.it

# Interceptive management for multiple eruption disturbances: a follow-up evaluation

## ABSTRACT

**Aim** The aim of this report was to show the management of a case with an impacted central maxillary incisor caused by odontoma in a young patient with two mesiodentes in the region of the nasal floor.

**Case Report** A 9-year-old girl was seen in the Department of Orthodontics of the University of Rome "Tor Vergata". Radiographic images showed intraosseous impaction of the maxillary right central incisor due to an odontoma. The treatment plan consisted of three stages: removal of the odontoma; rapid maxillary expansion (RME) in order to improve the intraosseous tooth position; surgical exposure and orthodontic traction of the impacted central incisor to its right position. At the end of the treatment the patient showed stable occlusal, functional, and periodontal results. In our therapeutic strategy the application of RME may improve the intraosseous position of incisor, minimizing space loss and surgical intervention to recover the impacted tooth. A three-year follow-up of the stability and periodontal health showed that the tooth placed in the occlusion maintained both esthetics and function.

**Keywords** Interceptive orthodontics; Maxillary expansion; Tooth impaction.

## Introduction

Failure of eruption of the permanent maxillary incisors is an infrequent condition of the early mixed dentition, with a prevalence of 0.2-1% [Jones, 1999].

The primary treatment goal in case of displaced maxillary incisors is to reposition the tooth in the dental arch whenever it is possible [Hitchin, 1970; Bishara, 1971; Vanarsdall and Corn, 1977]. Several techniques have been developed, so a careful planning is required when moving an impacted tooth and the mechanics of the treatment can be modified according to the individual requirements.

Treatment alternatives for an impacted central incisor caused by odontoma or supernumerary teeth include surgical removal of obstacle followed by monitoring or orthodontic traction [Frank, 2000]. Spontaneous eruption of impacted maxillary incisors occurs in 54-76% of cases when the obstacle is removed and there is enough space in the dental arch within an average time of 16 months [Cozza et al., 2004].

Aim of this report was to show the management, surgical and orthodontic, of a case with an impacted central maxillary incisor caused by odontoma in a young patient with two mesiodentes in the region of the nasal floor.

## Case report

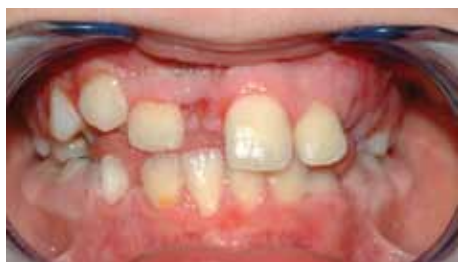A 9-year-old Caucasian girl was referred by her general dentist to the Department of Orthodontics of the University of Rome "Tor Vergata" for evaluation. The chief complaint concerned about a series of eruption disturbances, which had resulted in an unaesthetic appearance. Her dental history did not reveal a traumatic injury to the primary maxillary dentition.

The patient had balanced facial pattern with a good profile, but an asymmetric smile. Intraoral clinical examination showed a mixed dentition, an altered sequence of eruption and the absence of the maxillary right central incisor.

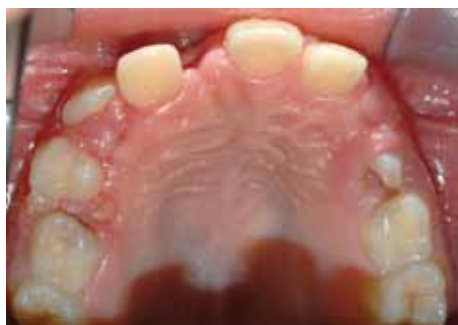Occlusal analysis revealed a molar Class I and not evaluable canine relationship. The maxillary right central incisor was absent, and the adjacent teeth had drifted into the unoccupied space. There was significant dental crowding in the upper arch with lack of space for the right central incisor in the line of the arch. Mandibular arch form was well shaped. Overjet and overbite were 2 mm. A lateral open bite was evident in right side of the mouth caused by eruption disturbances (Fig. 1, 2).

The panoramic radiograph showed a series of eruption problems: an odontoma located in the eruption path of the permanent maxillary right central incisor, two conical mesiodentes placed on the bisplanal plane, agenesis of teeth 3.5, and tooth 2.3 retained. It was not possible to exactly define the place of the impacted incisor.

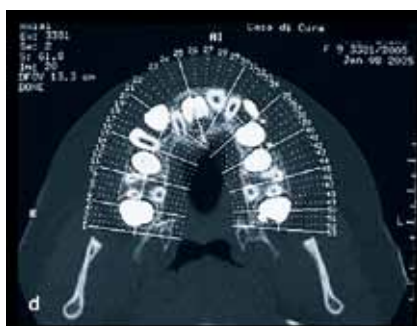
The measurements proposed by Bryan et al. [2005] and by Smaliene et al. [2006] were performed on the initial (T1) panoramic radiograph to evaluate the



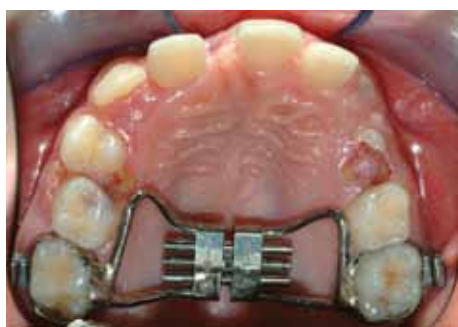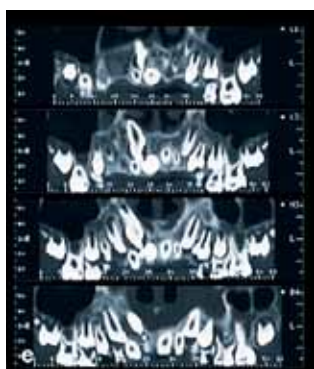
**FIG. 1**  
Pretreatment  
intraoral  
photograph:  
frontal view.



**FIG. 2**  
Pretreatment  
intraoral  
photograph:  
occlusal  
view.



**FIG. 3** Pretreatment CT  
dentascan.



**FIG. 4**  
Occlusal  
view during  
maxillary  
expansion.

intraosseous displacement of the delayed incisor.  
The angle of the long axis of the unerupted

permanent incisor to the mid-sagittal plane was appraised according to Bryan et al. [2005] in order to evaluate the angulation of the impacted incisor. In this case the angle was 28.5°.

The vertical position of the impacted permanent incisor, analysed in relation to the thirds of the root length of the contralateral erupted central incisor [Smailiene et al., 2006], showed V3 position, at the level of the apical third of the root.

TC-Dentascan evaluation confirmed the presence of a composite odontoma in the body of the premaxilla, near the crown of the impacted incisor, and two conical shaped mesiodentes in a horizontal inverted position in the region of the nasal floor. They were not in contact with other teeth, and they had no apical reaction. The impacted tooth was localised with the crown at the level of the root's apical third of the right lateral incisor, and the root apex was closing (Fig. 3).

Cephalometric analysis on the lateral cephalogram revealed a skeletal Class I malocclusion (ANB T1: 3°) and a dolichofacial pattern (FMA T1: 31°). Lower incisor showed good inclination on mandibular plane (IMPA T1: 92°).

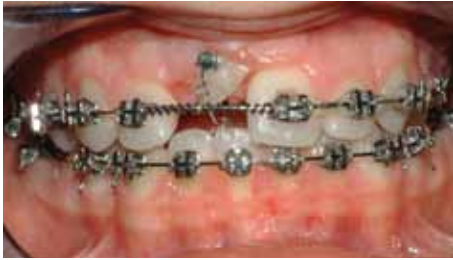**Treatment objectives**

The following treatment objectives were established: surgical removal of obstacle, orthopedic maxillary expansion to recover space for the eruption of the incisor and to improve the intraosseous position of the delayed maxillary incisor, recovery of the impacted tooth, and fixed appliance to create a stable functional occlusion.

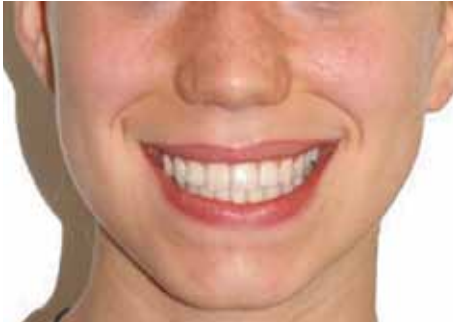**Treatment plan**

After discussing the possible treatment alternatives for mesiodentes, and studying the literature about this controversial topic, the orthodontist and the surgeon chose not to extract the supernumerary teeth [Kuroi, 2002]. The parents were informed about this decision and they were appraised to monitor the teeth with panoramic radiograph every year. The odontoma was removed, then a palatal expander was bonded in maxillary arch to recover space for the delayed incisor (Fig. 4). Moreover, the expansion of the upper arch permitted to obtain good correction of the interarch relationship to help teeth alignment, dental intercuspation and functional movements, and to improve intraosseous incisor position.

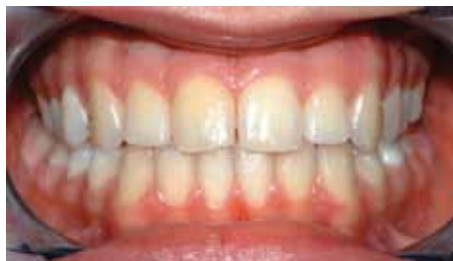The patient underwent RME with a rapid maxillary expander soldered to bands placed on the first permanent molars. Activation of the screw was continued until the palatal cusps of the maxillary posterior teeth were in contact with the buccal cusps of the mandibular posterior teeth [Cozza et al., 1999]. After expansion, the patient underwent a retention period with the expander in place for 6 months [Cozza et al., 2001]. Following the retention period the expander was removed and the patient underwent



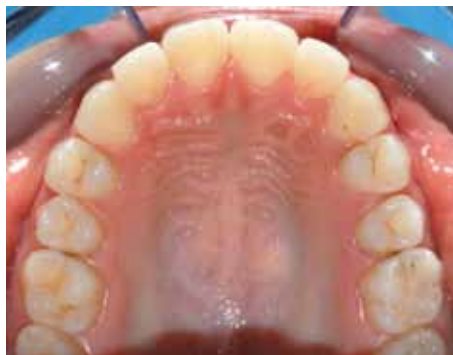**FIG. 5**  
Frontal view of the orthodontic traction stage.



**FIG. 6** Post treatment extraoral photograph.



**FIG. 7** Post treatment intraoral photograph: frontal view.



**FIG. 8** Post treatment intraoral photograph: occlusal view.

clinical examination and radiographs (T2) to monitor the intraosseous position of the delayed incisor.

On the panoramic radiograph the right central incisor showed an improvement of the initial vertical position, it moved from sector V3 to V2. Concerning the intraosseous angulation of the delayed incisor, it changed from 28.8° to 22°. Moreover after expansion the retained tooth 2.3 erupted spontaneously.

Molar bands and brackets were placed on all teeth. Once the upper and lower arches were in a relatively rigid stabilising wire (0.017 x 0.025-in stainless steel in a 0.018-in slot anterior and 0.022-in slot posterior), a coil spring was used to create adequate space for aligning the impacted incisor.

Sixteen months after odontoma removal a surgical

exposure and traction of the impacted right central incisor were planned. Surgical exposure was performed using a closed eruption technique, in which the raised flap that incorporates the attached gingiva is fully replaced to its former position. In fact the gingival flap was sutured back in such a way that a minimal portion of the crown was exposed into the oral cavity. Special care was given to preserve the bone, mucoperiosteum and gingival tissues around the crown. The patient returned two weeks later, after soft tissue healing, and the elastomeric chain (60-90 g) was tied with tension to the open coil. The patient was seen every three weeks (Fig. 5).

Once the impacted tooth had erupted, a bracket was bonded to the crown and tied to an archwire (0.016 x 0.022-in multibraid stainless steel). In the mandibular arch, alignment and leveling were achieved with a sequence of 0.016 x 0.022-in multibraid stainless steel archwires, later replaced by 0.016 x 0.022-in, and by 0.017 x 0.025-in stainless steel archwires. The second deciduous inferior molars were not banded: the left one because 3.5 was agenetic and the right one because tooth 4.5 was in delayed eruption.

Interim radiographs were taken to verify the root positioning and the progress in eruption of the lower second right premolar.

Active treatment took 26 months. Retention was accomplished with removable acrylic retainers. The patient was instructed to wear the retainers only at night. She is currently on routine patient recall.

## Results

The patient showed an attractive smile (Fig. 6) and a balanced profile. Good intercuspation was achieved and midlines were coincident. There was a good dental alignment in the upper arch, which showed a well-shaped form. The impacted maxillary right central incisor was brought into proper alignment with the adjacent teeth. The final aesthetic result was good, with gingival margins at the same level and with similar crowns sizes and shape (Fig. 7, 8). The tooth responded well to vitality test. From a periodontal point of view a band of labial keratinized gingiva measuring 4 mm was present, and pocket depth ranged from 1 to 2 mm.

The final radiographs indicated intact roots, proper root alignment, and no root disease. The mesiodentes remained in stable position without interference with teeth eruption, and occlusal development.

A skeletal Class I (ANB T1:3°, T2:3°) was maintained. An ideal overbite (T1: 3 mm, T2: 2 mm) and overjet (T1: 2 mm, T2: 2 mm) were established and a Class I molar and canine relationships were exhibited. Good control of vertical dimension (FMA T1: 31°, T2: 30°). Upper and lower incisors showed good inclination (IMPA T1: 92°, T2: 91°; U1^FH T1: 108°, T2: 113°).

### Long-term evaluation

The patient was recalled for check-up every 6 months. Thirty-six months after the end of the orthodontic treatment, the smile was improved, the extruded extruded central incisor remained asymptomatic and the follow up of the stability and periodontal health showed that the tooth placed in the occlusion maintained both esthetics and function. The follow-up records showed the stability of proper root alignment, and the absence of root disease.

## Discussion

An impacted maxillary central incisor in a child poses a disturbing aesthetic dilemma because of its prominent location [Baccetti et al., 2009].

Aim of our protocol was to suggest an early therapeutic strategy for delayed incisors able to allow spontaneous tooth eruption or to improve its intraosseous position.

Our treatment strategy included obstacle (odontoma) elimination. Many authors, in fact, reported that if the odontoma that interfered with tooth eruption was removed early, the impacted tooth would normally form and sometimes erupt [Morning, 1980; Becker, 2002]. Becker stated that this resolution is far from adequate in most cases and it is therefore necessary to treat impacted maxillary incisors with an orthodontic appliance [Becker, 2002].

Immediately after surgical removal a rapid maxillary expander was applied. In literature maxillary expansion was proposed as an alternative interceptive treatment for impacted incisors as a means to facilitate eruption of the teeth after removal of the obstacles [Hitchin, 1970; Cozza et al., 1999; Cozza et al., 2001]. According to Becker [2002], in our patient the early diagnosis and treatment did not allow the spontaneous eruption process of the maxillary central incisor. However this strategy allowed to increase the anterior segment of maxillary arch allowing an improvement of incisor

intraosseous vertical and angular position, and a recovery of space in the arch.

In this case, in order to minimise the trauma of surgery, the tissues around the unerupted tooth were not removed. The surgical flap was repositioned and sutured in place according to what is called "closed eruption technique"; only the ligature wire attached to the button on the impacted tooth was exposed into the oral cavity. This technique induces natural gingival margins of the extruded tooth and therefore it should be preferred to the conventional apically positioned flap [Becker, 2002].

## References

- › Baccetti T, Mucedero M, Leonardi M, Cozza P. Interceptive treatment of palatal impaction of maxillary canines with rapid maxillary expansion: A randomized clinical trial. *Am J Orthod Dentofacial Orthop* 2009; 136: 657-661.
- › Becker A. Early treatment for impacted maxillary incisors. *Am J Orthod Dentofacial Orthop* 2002; 121(6): 586-587.
- › Bishara SE. Treatment of unerupted incisors. *Am J Orthod* 1971; 59: 443-447.
- › Bryan RA, Cole BO, Welbury RR. Retrospective analysis of factors influencing the eruption of delayed permanent incisors after supernumerary tooth removal. *Eur J Paediatr Dent* 2005; 6(2): 84-89.
- › Cozza P, Giancotti A, Petrosino A. "Butterfly Expander" In Mixed Dentition. *JCO* 1999; 33(10): 583-587.
- › Cozza P, Giancotti A, Petrosino A. Rapid Palatal Expansion in Mixed Dentition using a Modified Expander: a cephalometric investigation. *J Orthod* 2001; 28: 129-134.
- › Cozza P, Marino A, Laganà G. Interceptive management of eruption disturbances: case report. *J Clin Pediatr Dent* 2004; 29(1): 1-4.
- › Frank CA. Treatment options for impacted teeth. *J Am Dent Assoc* 2000; 131: 623-632.
- › Hitchin AD. The impacted maxillary incisor. *Dent Pract Dent Rec* 1970; 20(12): 423-433.
- › Jones JW. A Medico-legal Review of Some Current UK Guidelines in Orthodontics: A personal View. *J Orthod* 1999; 26: 307-324.
- › Kuroi J. Early treatment of tooth eruption disturbances. *Am J Orthod Dentofacial Orthop* 2002; 121: 588-591.
- › Morning P. Impacted teeth in relation to odontomas. *Int J Oral Surg* 1980; Apr 9(2): 81-91.
- › Smaliene D, Sidlauskas A, Bucinskiene J. Impaction of the central maxillary incisor associated with supernumerary teeth: initial position and spontaneous eruption timing. *Stomatologija* 2006; 8(4): 103-107.
- › Vanarsdall RL, Corn H. Soft-tissue management of labially positioned unerupted teeth. *Am J Orthod* 1977; 72(1): 53-64.