

## Third ventricle anaerobic abscess after perforation of the intestine by a ventriculo-peritoneal shunt

Roberto Vagnozzi(\*), Giuseppe Gentile(\*\*), Pietro Martino(\*\*), Mario Venditti(\*\*\*),  
Francesco Pastore(\*), Renato Giuffrè(\*)

**Summary.** *Third ventricle anaerobic abscess after perforation of the intestine by a ventriculo-peritoneal shunt.* A case of third ventricle abscess in a patient with a ventriculo-peritoneal shunt came recently to our observation. Apparently retrograde spread of intestinal micro-organisms via the shunt, after a peritoneal catheter-induced bowel perforation, was responsible for this unusual, anaerobic Gram-negative abscess. After the aspiration of the abscess, and the instillation of Metronidazole into the cavity, the patient promptly improved without any evidence of neurological side effects.

**Key words:** Bowel perforation, cerebral abscess, shunt complications, VP shunt, ventriculitis.

**Riassunto.** Gli AA. presentano un caso di ascesso del terzo ventricolo sviluppatosi in una paziente portatrice di derivazione liquorale ventricolo-peritoneale.

Questa lesione, insolitamente sostenuta da germi anaerobi Gram negativi, era conseguita alla perforazione intestinale da parte del catetere distale dello shunt.

Con il drenaggio dell'ascesso e l'irrigazione cavitaria di metronidazolo, le condizioni della paziente sono gradualmente migliorate fino alla guarigione, senza che si siano manifestati sintomi di tossicità generale o neurologica del farmaco impiegato.

**Parole chiave:** Ascesso cerebrale, complicanze delle derivazioni, derivazioni ventricolo-peritoneali, perforazione intestinale, ventricolite.

Ventriculitis resulting from retrograde spread of Gram-negative micro-organisms after a peritoneal catheter - induced bowel perforation, is a rare com-

plication of ventriculoperitoneal (VP) shunts. To our knowledge only one case of abscess featuring this unusual etiopathogenesis appears in the literature (3).

### Case report

The patient, a 14 year old girl, underwent a VP shunt at the age of 2 months for a post-meningitic hydrocephalus. After 6 months, a ventriculo-atrial (VA) shunt was inserted in place of the peritoneal one because of a peritoneal cyst (50 ml) surrounding the catheter tip. When she was 9 year old, a VP shunt was newly inserted. Four years later (on February 1985) a new peritoneal cyst with sterile liquid (150 ml.) was drained and a new VP shunt was inserted under direct vision. In February 1986 a generalized ventriculitis and an abscess within the III ventricle was diagnosed by Ct-scan (Fig. 1). Antibiotic treatment was started without clinical and Ct-scan improvement. On May 1986 the patient was admitted to the hospital because of lethargia, akinesia, dysmetria, and Parkinson-like rigidity. The subcutaneous tissue overlying peritoneal catheter was swollen and floating. The shunt was removed and the insertion of an external ventricular drainage became necessary. Treatment with systemic and intraventricular antibiotics was started. Cultures of ventricular fluid yielded *E. coli*, *S. faecalis* and *B. fragilis*. On day 7 of antibiotic therapy the patient's conditions worsened and she was no more able to follow commands. Aspiration of the abscess was performed under Ct-scan guidance with instillation of metronidazole into the abscess cavity (25 mg every 6 h.). Cultures of the ventricular fluid were sterile, whereas pus taken from the abscess yielded *Bacteroides fragilis* susceptible to metronidazole. On day 14 cultures taken from the abscess were negative, Ct-scan and neurologic status improved and the intraabscess therapy was discontinued. On day 36 the patient was discharged with a new VA shunt after having completed a 30 days course of systemic antibiotic treatment. On October 1986 a follow-up Ct-scan documented the complete resolution of all lesions (Fig. 2). No relaps was observed during a 4.5 year follow-up.

(\*) Cattedra di Neurochirurgia, 2ª Università «Tor Vergata», Roma.

(\*\*) Dipartimento di Biopatologia Umana, Sezione di Ematologia, Università «La Sapienza», Roma.

(\*\*\*) 3ª Cattedra di Patologia Medica, Università «La Sapienza», Roma.

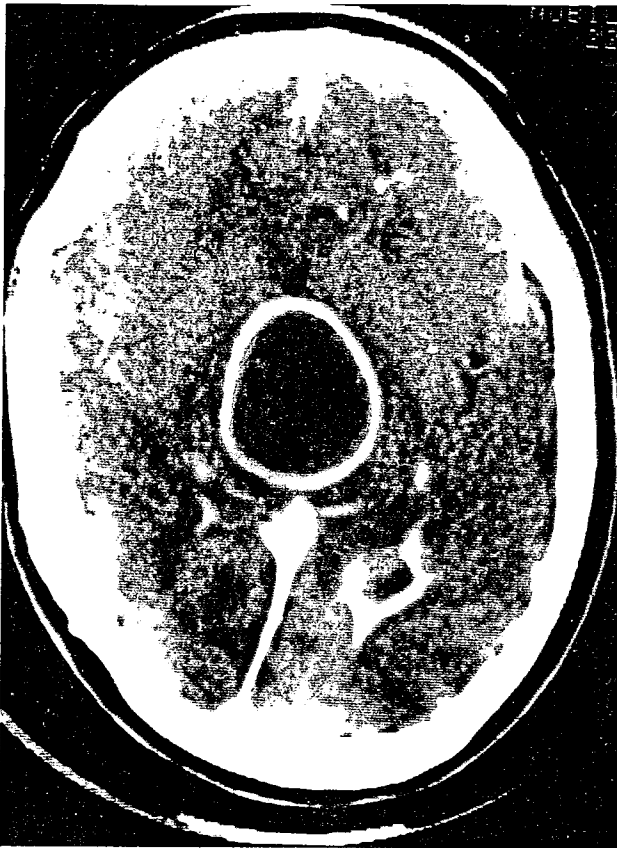


Fig. 1A

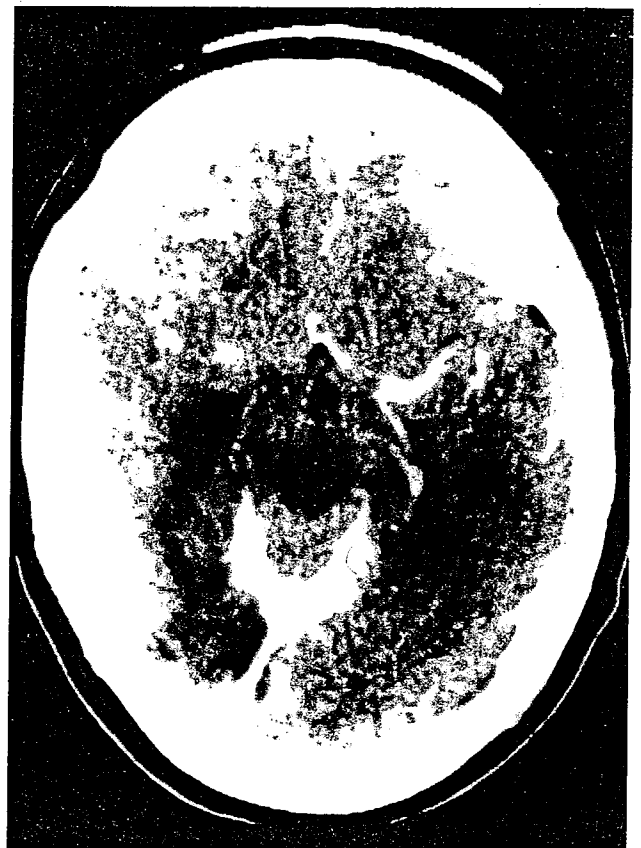


Figure 2. - CT-scan obtained 8 months after the operation demonstrating the complete resolution of the ependymitis as well as the abscess.

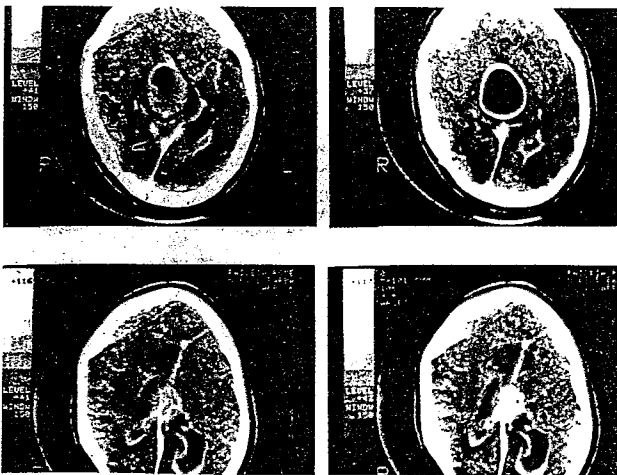


Fig. 1B

Figure 1. - Pre-operative CT-scan showing a third ventricle ring-enhanced lesion and signs of bilateral ventriculitis.

### Discussion

Foreign bodies retained within the abdominal cavity have been known to perforate the bowel wall. A possible anchoring effect caused by fibrous encasement of the peritoneal end of the tube, in addition to a decreased peristalsis, due, as in our case to a previous peritonitis, may result in repeated pressure by its tip at a fixed point on the bowel surface, eventually leading to perforation. Penetration of the peritoneal tip of a ventriculo-peritoneal catheter into the intestinal lumen seems to be a rare event. It is the opinion of some Authors<sup>7, 8, 10</sup> that the presence of the spring wire in the Silastic wall of the Raimondi catheter may increase the risk of perforation. In our case a polyethylene peritoneal catheter had been used, introduced under direct vision. In about 50% of the reported cases the presence of a bowel perforation was recognised only by passage of the peritoneal end of the shunt "per rectum" with the

Table 1. — Previously reported cases of retrograde ventriculitis as complication of VP-shunts.

Author	Year	Peritoneal sympt.	Shunt func.t	Outcome
Rubin	1972	Absent	Yes	Death
Sells	1973	Present	No	Death
Grosfeld	1974	Present	Yes	Death
Schulhof	1975	Case 2	Absent	Yes Recovered
		Case 3	Present	Yes Recovered
		Case 6	Absent	Yes Death
		Case 7	Present	Yes Recovered
Peirce	1975		Present	No Recovered
Levine	1983		Absent	Yes Recovered
Abu-Dalu	1983	Case 2	Absent	Yes Recovered
		Case 3	Absent	Yes Recovered
Fisher*	1983		Absent	Yes Death
Vagnozzi**	1992		Absent	Yes Recovered

\* Abscess

\*\* Ventriculitis and abscess

catheter tip seen extruding from the anus of an otherwise asymptomatic patient<sup>1, 2, 5, 6, 7, 9, 11, 13, 14</sup>. In the other instances, however, an unusual Gram-negative ventriculitis resulted from retrograde spread of normal intestinal microflora (usually *E. coli*) via the shunt<sup>1, 2, 6, 7, 10, 11, 12, 13</sup>. To our knowledge in only one case the infection resulted in an intracerebral abscess<sup>3</sup>. In eleven of thirteen patients the shunt was normally functioning, and no signs of peritonitis were detected in eight, as shown on table 1. Five of thirteen patients with *E. coli* ventriculitis secondary to a shunt-induced bowel perforation have not survived. In our patient the intraventricular infection resulted in generalized ventriculitis and third ventricle abscess. Vigorous reaction of periventricular tissues had induced the formation of a dense capsule around the necrotic and purulent debris of this huge, intracerebral lesion. The swallowing of the subcutaneous tissue overlying the peritoneal catheter, full of air, the green colour of the abscess content and its characteristic smell, suggested the anaerobic, Gram-negative nature of the infectious agent. These findings were confirmed by culture which yielded *Bacteroides fragilis*. In view of the high mortality rate associated with Gram-negative ventriculitis and abscess, and the worsening conditions of the patient, despite the systemic antimicrobial therapy, we decided to administer intraabscess metronidazole. As previously reported<sup>4</sup> this is the first case, to our knowledge, of the instillation of metronidazole into a brain abscess cavity. Relevant in the present case

appears to be the bowel perforation due to the peritoneal catheter, causing a retrograde infection with the features of a generalized polymicrobial ventriculitis associated with a third ventricle anaerobic abscess. Also relevant was the treatment of this complication which, although presenting no signs of shunt malfunction, was particularly difficult due to the nature of the infective agent, i.e. intestinal bacteria. Antibiotics alone or in association, via systemic or intraventricular route, were ineffective. However, surgical evacuation of the abscess and repeated intracavitary instillations of Metronidazole, which was never administered topically for CNS infections before, granted successful and complete recovery of the patient.

Due to the underlying peritonitis, a ventriculo-atrial shunt was mandatory. As a consequence of the complete microbiological eradication of the abscess, the patient has shown no generalized or local infection in 4.5 year follow-up.

## References

1. Abu-Dalu K., Podes D., Hadani M., Sahar A.: Colonic complications of ventriculoperitoneal shunts. *Neurosurgery*, 1983; 13: 167-169.
2. Davidson R.: Peritoneal by-pass in the treatment of hydrocephalus: historical review and abdominal complications. *J. Neurol. Neurosurg. Psychiatry*, 1976; 39: 640-646.
3. Fisher G., Goebel H., Latta E.: Penetration of the colon by a ventriculoperitoneal drain resulting in an intra-cerebral abscess. *Zbl. Neurochirurgie*, 1983; 44: 155-160.
4. Gentile G., Vagnozzi R., Giuffrè R., Venditti M., Martino P.: Instillation of Metronidazole into a brain abscess cavity. *Eur. J. Clin. Microbiol. Infect. Dis.*, 1988; 7: 582-583.
5. Giuffrè R., Di Lorenzo N.: Two unusual complications of ventriculoperitoneal shunt procedures. *Surg. Neurol.*, 1975; 3: 23-24.
6. Grosfeld J.L., Cooney D.R., Smith J., Campbell R.L.: Intraabdominal complications following ventriculoperitoneal shunt procedures. *Pediatrics*, 1974; 54: 791-796.
7. Levine M.S.: Radiologic evaluation of *E. Coli* meningitis after a ventriculoperitoneal shunt. *AJNR*, 1983; 4: 1247-1248.
8. McComb J.G.: Comment to Griffith A.J. and De Feo D. *Neurosurgery*, 1987; 21: 261.
9. Murtagh F.R., Quencer R.M., Poole C.A.: Extracranial complications of cerebrospinal fluid shunt function in childhood hydrocephalus. *AJR*, 1980; 135: 763-766.
10. Peirce K.R., Loeser J.D.: Perforation of the intestine by a Raimondi peritoneal catheter. *J. Neurosurg.*, 1975; 43: 112-113.
11. Rubin R.C., Ghatak N.R., Visudhipan P.A.: Asymptomatic perforated viscus and Gram-negative ventriculitis as a complication of valve-regulated ventriculoperitoneal shunts. *J. Neurosurg.*, 1972; 37: 616-618.
12. Sell C.J., Loeser J.D.: Peritonitis following perforation of the bowel: a rare complication of a ventriculoperitoneal shunt. *J. Pediatr.*, 1973; 83: 823-824.
13. Schulhof L.A., Worth R.M., Kalsbeck J.E.: Bowel perforation due to peritoneal shunt: a report of seven cases and a review of the literature. *Surg. Neurol.*, 1975; 3: 265-269.
14. Wilson C.B., Bertan V.: Perforation of the bowel complicating peritoneal shunt for hydrocephalus. Report of two cases. *Amer. Surg.*, 1966; 32: 601-603.