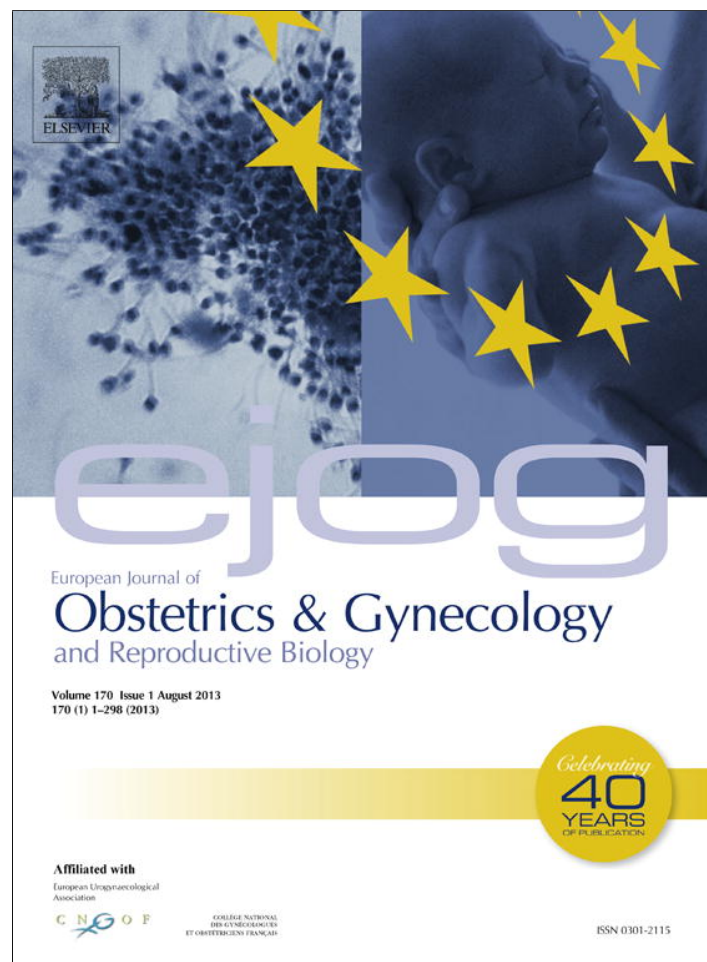


Provided for non-commercial research and education use.
Not for reproduction, distribution or commercial use.



This article appeared in a journal published by Elsevier. The attached copy is furnished to the author for internal non-commercial research and education use, including for instruction at the authors institution and sharing with colleagues.


Other uses, including reproduction and distribution, or selling or licensing copies, or posting to personal, institutional or third party websites are prohibited.

In most cases authors are permitted to post their version of the article (e.g. in Word or Tex form) to their personal website or institutional repository. Authors requiring further information regarding Elsevier's archiving and manuscript policies are encouraged to visit:

<http://www.elsevier.com/authorsrights>

Contents lists available at [SciVerse ScienceDirect](http://www.sciencedirect.com)

European Journal of Obstetrics & Gynecology and Reproductive Biology

journal homepage: www.elsevier.com/locate/ejogrb

Review

Gasless laparoscopic surgery during pregnancy: evaluation of its role and usefulness



Francesco Sesti*, Adalgisa Pietropolli, Franz Federico Sesti, Emilio Piccione

Academic Department of Biomedicine & Prevention and Clinical Department of Surgery, Section of Gynecology, Tor Vergata University Hospital, Rome, Italy

ARTICLE INFO

Article history:

Received 19 December 2011

Received in revised form 10 April 2013

Accepted 30 April 2013

Keywords:

Gasless laparoscopy

Pregnancy

Ovarian cystectomy

Salpingo/oophorectomy

Uterine myomectomy

Cholecystectomy

ABSTRACT

The minimally invasive laparoscopic approach in the surgical treatment of diseases during pregnancy has become progressively more accepted and applied. In an attempt to overcome the potential adverse effects of pneumoperitoneum on the fetus, gasless laparoscopic surgery (GLS) has been developed. This article reviews the evidence available for the role and effectiveness of GLS in pregnancy. A computerized literature search was conducted on Medline, Science Citation Index, Current Contents, Embase, and PubMed databases for English language publications from the first report of GLS in pregnancy in 1995 to June 2012. Eleven case reports or retrospective series were identified. A total of 44 pregnant women underwent GLS for various surgical indications. In all cases, the procedures were carried out without complication, and the women were discharged from hospital with a continuing pregnancy. GLS in pregnancy has comparable outcomes to conventional CO₂ laparoscopy, but it is associated with some advantages. Hypercarbia and increased intraperitoneal pressure due to CO₂ insufflation are avoided. The use of high-pressure continuous suction may prevent the problems that are potentially associated with intra-abdominal smoke generated by electrosurgery, which can increase the risk of fetal exposure to elevated levels of toxic gases. Because this procedure may be performed under regional anesthesia, avoiding general anesthesia, there is a minimal transplacental passage of anesthetic drugs to the fetus. The surgeon must be expert in advanced laparoscopic procedures.

© 2013 Elsevier Ireland Ltd. All rights reserved.

Contents

1. Introduction	8
2. Methods	9
3. Results	9
3.1. General surgical procedures	9
3.1.1. Cholecystectomy and appendicectomy	9
3.2. Gynecologic procedures	9
3.2.1. Adnexal disorders	9
3.2.2. Gasless laparoscopy for uterine diseases	10
4. Discussion	10
5. Conclusion	11
References	11

1. Introduction

Surgical diseases in the pregnant woman remain a diagnostic and therapeutic challenge. General surgical procedures are required in approximately 1 in 635 pregnancies, acute appendicitis and symptomatic biliary disease being the most common indications [1]. Among the gynecologic conditions requiring

* Corresponding author at: School of Medicine, Academic Department of Biomedicine & Prevention and Clinical Department of Surgery, Tor Vergata University Hospital, Viale Oxford, 81-00133 Rome, Italy.
Tel.: +39 06 20 902 921; fax: +39 06 20 902 921.

E-mail address: Francesco.Sesti@uniroma2.it (F. Sesti).

surgery during pregnancy, ovarian cysts, adnexal masses or torsions are the most frequent. Adnexal surgery accounts for one-third of laparoscopic procedures performed during pregnancy, and 56% of these operations are performed in the second trimester [2].

All these disorders are routinely treated using carbon dioxide (CO₂) laparoscopic techniques in the non-pregnant patient. The advantages of CO₂ laparoscopic procedures over open procedures in the general population are well described and include diminished postoperative pain, shorter length of hospital stay, quicker recovery, a reduced occurrence of thromboembolic events, and shorter length of postoperative ileus [3]. Despite this, some surgeons are reluctant to utilize this method when treating a pregnant woman, especially after the first trimester, because there are few data showing the safety of operative laparoscopy during pregnancy [4]. This is probably because of the potential risk to the fetus due to trocar insertion, CO₂ insufflation, and an inadequate surgical field. In addition, potential risks to the mother consist of altered physiology of pneumoperitoneum and decreased venous return to the heart, with possible compromise of the uteroplacental perfusion as a result of augmented intra-abdominal pressure, and fetal acidosis generated by CO₂ absorption [3].

Although many technical improvements and adjustments have been developed to improve security and efficiency of CO₂ laparoscopy, numerous studies have reported pathophysiological or clinical problems related to CO₂ laparoscopy in pregnancy. Indeed, CO₂ laparoscopy may create diminution of pulmonary function, increased pulmonary wedge pressure, ventilation–perfusion mismatch, visceral vasoconstriction, augmented dead space, increase of total peripheral resistance, effects on cardiac output and increase in PaCO₂ [5].

In an attempt to overcome the adverse effects of pneumoperitoneum, many techniques have been developed to lift the abdominal wall without gas. With gasless laparoscopic surgery (GLS) the potential detrimental effects of CO₂ pneumoperitoneum on the fetus can be avoided, while the advantages of reduced postoperative pain and improved recovery are retained [6]. The procedures involve the use of two wire loops placed through the abdominal wall and pulled upward by a mechanical device. The first generation of abdominal wall lifting devices provided an intraperitoneal lift [7]. An alternative approach was first described by Hashimoto et al. [8]: abdominal lifting was provided by subcutaneous wires. This concept was then developed with the introduction of new subcutaneous lifting systems for laparoscopic surgery [9]. The method widely used today is the planar lifting of the abdominal wall.

Some data suggest that clinical outcomes of gasless laparoscopy are equivalent to those of conventional laparoscopic techniques, while providing improved safety. In this paper the published evidence regarding the use of gasless laparoscopy during pregnancy is reviewed, focusing on general surgical and gynecologic procedures.

2. Methods

A computerized literature search was conducted on Medline, Science Citation Index, Current Contents, Embase, and PubMed databases for English language publications from the first report of GLS in pregnancy in 1995 to June 2012. Eleven cases reports or retrospective series were identified.

3. Results

Forty-four pregnant women underwent GLS for various surgical indications. The largest group of cases ($n = 40$) was of adnexal mass, and there were two cases of adnexal torsion, one case of

necrotic uterine leiomyoma and one of acute cholecystitis. The procedures undertaken included ovarian cystectomy ($n = 38$), salpingo-oophorectomy ($n = 2$), salpingectomy ($n = 1$), adnexal detorsion ($n = 1$), uterine myomectomy ($n = 1$), and cholecystectomy ($n = 1$). In 25 cases the procedure was performed under epidural anesthesia. In all cases, the procedures were carried out without complication, and the women were discharged from the hospital with a continuing pregnancy.

3.1. General surgical procedures

3.1.1. Cholecystectomy and appendicectomy

A recent retrospective review of both laparoscopic and open procedures performed on pregnant women showed that CO₂ laparoscopic cholecystectomy was as safe and efficacious as its respective open procedure [4]. In fact, reduced rates of miscarriage and preterm labor have been reported in association with laparoscopic cholecystectomy when compared to an open cholecystectomy [10].

A single case report of gasless laparoscopic cholecystectomy was identified in our literature search. In order to avoid the potential problems related to CO₂ insufflation while benefiting from the reduced postoperative pain and improved recovery of CO₂ laparoscopic cholecystectomy, Iafrati et al. [11] performed a gasless laparoscopic cholecystectomy. They used an abdominal wall-lifting device (Laparofit – Origin Medsystems, Menlo Park, CA) with J-shaped lifting arms on a 38-year-old woman who was 14 weeks pregnant and suffering from acute cholecystitis. The procedure was carried out without complication, and the woman was discharged from the hospital in 24 h with a viable fetus [11].

Traditionally, the surgical treatment of choice for acute appendicitis during pregnancy has been open appendicectomy. A recent retrospective review of 65 consecutive pregnant patients, however, aimed to evaluate CO₂ laparoscopic versus open surgery for suspected appendicitis during pregnancy and demonstrated no significant difference in fetal losses [12]. No cases of GLS appendicectomy during pregnancy were identified in our literature search.

3.2. Gynecologic procedures

3.2.1. Adnexal disorders

3.2.1.1. Adnexal torsion. Several case reports have confirmed the safety and effectiveness of CO₂ laparoscopy in the treatment of adnexal torsion during pregnancy [10,13,14]. The first case of GLS for adnexal torsion during a twin pregnancy was reported subsequently [15]. In 2001 Schmidt et al. described a case of an acute abdomen related to right ovarian pedicle torsion in the fifth week of pregnancy. The authors performed GLS using the Laparofan (Origin, Menlo Park, CA), and the ovary was rotated into its usual position. The patient was well, and was discharged on the seventh postoperative day.

Another case of torped hematosalpinx in a woman in the thirteenth week of pregnancy was treated using the Laparofan fixed on Laparofit (Origin, Menlo Park, CA) [16]. Römer et al. performed GLS, detecting a torped 6 cm hematosalpinx, and successfully carried out salpingectomy using bipolar diathermy. The patient was well, and was discharged on the fifth postoperative day.

3.2.1.2. Adnexal masses. Several case reports support the use of CO₂ laparoscopy in the treatment of symptomatic adnexal masses in each trimester of pregnancy [10]. A retrospective cohort study of 101 pregnant women at 14 weeks or more of gestation undergoing laparoscopy ($n = 50$) or laparotomy ($n = 51$) for management of a

persistent adnexal mass showed shorter hospital stay, decreased blood loss, and fewer postoperative complications in the laparoscopy group compared with the laparotomy group, without seeming to have a negative effect on the pregnancy [17].

The first study comparing the effectiveness and safety of GLS ovarian cystectomy during pregnancy with those of conventional laparotomy was reported in 1999 [6]. GLS ovarian cystectomy was performed under epidural anesthesia in 17 women between 12 and 16 weeks' gestation. The procedure was carried out without any fetal loss. The total doses of analgesics and tocolytic agents used after GLS ovarian cystectomy were lower compared to those used after laparotomy.

In another report, seven pregnant women with adnexal cysts at 12–19 weeks of gestation were successfully treated without complications using GLS ovarian cystectomy under epidural anesthesia [18].

Another report concerned a woman who was affected by a left ovarian cyst in the fifteenth week of pregnancy. The cyst was larger than 60 mm and was located in the pouch of Douglas. An elective GLS ovarian cystectomy was performed using a Laparofit system (Tyco Healthcare Japan, Tokyo, Japan). A metreurynter, an inflatable bag for dilating the cervical canal, was inserted through the left trocar site into the bottom of cul-de-sac. A volume of 250 mL saline was extraperitoneally inflated into the balloon of metreurynter. The ovarian cyst appeared spontaneously out of the cul-de-sac after ballooning the metreurynter in the pouch of Douglas. This allowed an extraperitoneal cyst enucleation and ovarian suturing after having aspirated the cyst contents, and the left ovary was pulled out through the left port site. Histologic diagnosis was mature cystic teratoma. The subsequent antenatal and intrapartum course was uneventful [19].

More recently, two other reports of GLS ovarian surgery during pregnancy have been published. In the first cases series, 13 women with adnexal cysts at 10–17 weeks of gestation were successfully treated using GLS ovarian cystectomy under general anesthesia [20]. Postoperative complications comprised uterine contractions in three women and vaginal bleeding in four women, but these symptoms resolved rapidly after surgery. All the cases were delivered between 37 and 40 weeks of pregnancy. In another report, elective GLS salpingo-oophorectomy due to a persistent voluminous left ovarian cyst was performed under general anesthesia at the fourteenth week of gestation without complications. The subsequent antenatal and intrapartum course was unremarkable [21].

There are reports of the use of CO₂ laparoscopy in the management of heterotopic pregnancy [22,23]. More recently, the first case of heterotopic tubal pregnancy treated using GLS has been reported [24]. The woman was successfully managed under general anesthesia at the seventh week of gestation using GLS salpingectomy of the tubal pregnancy. The subsequent antenatal course was uneventful.

3.2.2. Gasless laparoscopy for uterine diseases

3.2.2.1. Uterine myomas. Myomectomy performed during pregnancy through a laparotomy [25] or conventional laparoscopy with pneumoperitoneum [26] has been described. To date there is a single published report of GLS myomectomy during pregnancy in a woman with a subserosal myoma measuring 7 cm × 7 cm on the uterine fundus at 24 weeks of gestation [27]. She had acute abdominal pain with suspected torsion or necrosis of the myoma. GLS was performed using the Laparotenser device (Lucini Surgical Concept, Milan, Italy) under epidural anesthesia. A partially necrotic uterine leiomyoma was detected and the myoma was removed and successively extracted from the abdominal cavity by morcellation with a scalpel [28]. Monopolar and bipolar

electrosurgery were not used. The uterine defect was repaired in a continuous one-layer closure using a conventional long needle holder. No intraoperative complications occurred, and there were no anesthesia-related complications. The woman was discharged on the first postoperative day and the remainder of her pregnancy was unremarkable.

4. Discussion

Symptomatic gallbladder disease is the most frequent indication for non-gynecologic procedures during pregnancy. Gallstones are present in 12% of all pregnancies, and more than one-third of the symptomatic patients do not respond to conservative medical management [29]. CO₂ laparoscopic cholecystectomy during pregnancy is preferred because of the good outcomes and low rate of complications [10]. The single case report of GLS cholecystectomy demonstrated that the use of abdominal wall-lifting devices could be supported, since both hypercarbia and increased intraperitoneal pressure are avoided [11]. Both wire suspension and retracting arm devices have been used [8]. During the development phase of these devices, exposure for cholecystectomy has occasionally been problematic, although pelvic exposure was generally satisfactory. It is suggested that the addition of a J-shaped lifting arm permits an exposure into the right upper quadrant essentially equivalent to pneumoperitoneum, allowing a safe cholecystectomy to be undertaken [11].

The incidence of adnexal masses during pregnancy is 2%. Most adnexal masses discovered during the first trimester of pregnancy are functional ovarian cysts that resolve spontaneously by the second trimester. Expectant management has been suggested for adnexal masses ≤6 cm in pregnancy based on an 82–94% rate of spontaneous resolution. Persistent masses are most frequently functional cysts or mature cystic teratomas with malignancy reported in 2–6% [30]. In the event that surgery is indicated, various case reports support the use of laparoscopy in the management of adnexal masses in every trimester [31,32]. It was reported, however, that if maternal respiratory acidosis occurs, as in pneumoperitoneum, the diffusion of CO₂ can cause fetal hypercarbia and acidosis, and that premature labor can occur from the increased intra-abdominal pressure [31]. Indeed, several studies of pneumoperitoneum in a pregnant ewe model showed an increase in the fetal PaCO₂ and a decrease in the fetal arterial pH [33,34].

In addition to the chemical effects of absorbed CO₂, the pressure effect of pneumoperitoneum may be detrimental to the mother and fetus; fetal hypoxia can be generated by increased intrauterine pressure. CO₂ insufflation in the pregnant ewe can result in a reduction of uterine blood flow and an increase in intra-amniotic pressure [34]. These studies suggest that pneumoperitoneum may have deleterious effects on the fetus. On the contrary, stable maternal PaCO₂ was observed in patients undergoing GLS [6]. The use of abdominal wall-lifting devices in the pregnant patient might be considered because both hypercarbia and increased intraperitoneal pressure are avoided with less significant hemodynamic and respiratory maternal effects [6,18]. In particular, the use of subcutaneous lift systems [35] is recommended because they show several advantages over the full-thickness wall lift devices [36]. First, the surgeon can prevent injury to the gravid uterus. Second, the subcutaneous lift system can be applied to all patients, regardless of any history of abdominal surgery or any unexpected adhesions.

Fetal acid–base balance may also be affected adversely by reduction in the maternal diaphragmatic excursion and vena caval flow, both of which may result from the increased maternal intraperitoneal pressure [37]. An additional potential risk is the fetal exposure to intra-abdominal smoke, generated by electro-

surgery and lasers, which can increase the levels of toxic gases, the most important of which is carbon monoxide [38]. GLS can facilitate the use of high-pressure continuous suction, preventing that problem.

It has been proposed that GLS may extend the variety of gynecologic surgeries, particularly on the adnexa in pregnancy. Indeed, there is no risk of injuring the pregnant uterus with a Veress needle or cannula, and no increase in intra-abdominal pressure. A further advantage is the ability to use conventional instruments. The uterus can be cautiously manipulated by moving it with a sponge that is held by a ring forceps [16].

Surgical management of uterine leiomyoma during pregnancy may be successfully performed in carefully selected patients, but it can be complicated by injury to the gravid uterus, resulting in pregnancy loss. The surgeon must therefore be skillful in advanced techniques of laparoscopic surgery, adopting a safe protocol for the port placement system considering the size of the pregnant uterus [39]. An increasing number of reported cases have shown laparoscopy to be safe in the first two trimesters with good maternal and fetal outcome. It is recommended that a laparoscopic myomectomy can be considered a minimally invasive alternative to traditional laparotomy for selected patients when myomectomy during pregnancy is unavoidable [26].

GLS myomectomy seems to offer several advantages over conventional laparoscopy with pneumoperitoneum. Because the peritoneal cavity does not need to be sealed airtight, conventional long laparotomy instruments, such as tissue clamps, tenaculum clamps, needle holders, knives, and scissors can be used. This facilitates several steps of the procedure. One of the main advantages is in uterine repair because applying the conventional curved needle deeply into the myometrium with a laparotomy needle holder is easier and faster. As previously emphasized [40], the augmented vascularization and tissue impedance of the pregnant uterus can amplify the risk of electrosurgical damage. It is therefore important to avoid the use of monopolar and bipolar electrosurgery in the myoma resection, as occurred in the only case of gasless laparoscopic myomectomy during pregnancy reported in the literature [27].

5. Conclusion

During its early years, some argued that laparoscopy was contraindicated during pregnancy. The use of the minimally invasive laparoscopic approach in the surgical treatment of diseases during pregnancy has, however, become progressively more accepted and applied as data supporting its safety and enhancements in use have accumulated. In an attempt to overcome the potential adverse effects of pneumoperitoneum on the fetus, many techniques have been developed to lift the abdominal wall without gas. Limited published data on GLS during pregnancy show outcome measures comparable to those of conventional CO₂ laparoscopy, but it is associated with some potential advantages. With this technique the potential deleterious effects of carbon dioxide insufflation on the fetus are avoided, while the benefits of diminished postoperative pain and enhanced recovery are retained. The reported use of GLS in pregnancy is limited and the surgeon must be expert in advanced laparoscopic procedures before considering GLS as a safe alternative for his/her patient.

References

- [1] Andreoli M, Servakov M, Meyers P, Mann Jr WJ. Laparoscopic surgery during pregnancy. *J Am Assoc Gynecol Laparosc* 1999;6:229–33.
- [2] Lachman E, Schienfeld A, Voss E, et al. Pregnancy and laparoscopic surgery. *J Am Assoc Gynecol Laparosc* 1999;6:347–51.
- [3] Jackson H, Granger S, Price R, et al. Diagnosis and laparoscopic treatment of surgical diseases during pregnancy: an evidence-based review. *Surg Endosc* 2008;22:1917–27.
- [4] Cornielle MG, Gallup TM, Bening T, et al. The use of laparoscopic surgery in pregnancy: evaluation of safety and efficacy. *Am J Surg* 2010;200:363–7.
- [5] Baxter JN, O'Dwyer PJ. Pathophysiology of laparoscopy. *Br J Surg* 1995;82:1–2.
- [6] Akira S, Yamanaka A, Ishihara T, Takeshita T, Araki T. Gasless laparoscopic ovarian cystectomy during pregnancy: comparison with laparotomy. *Am J Obstet Gynecol* 1999;180:554–7.
- [7] Chin AK, Moll FH, McColl MB, Reich H. Mechanical peritoneal retraction as a replacement for carbon dioxide pneumoperitoneum. *J Am Assoc Gynecol Laparosc* 1993;1:62–6.
- [8] Hashimoto D, Nayeem SA, Kajiwara S, Hoshino T. Abdominal wall lifting with subcutaneous wiring: an experience of 50 cases of laparoscopic cholecystectomy without pneumoperitoneum. *Surg Today* 1993;23:786–90.
- [9] Chin AK, Eaton J, Tsoi EK, et al. Gasless laparoscopy using a planar lifting technique. *J Am Coll Surg* 1994;178:401–3.
- [10] Pearl J, Price R, Richardson W, Fanelli R. Society of American Gastrointestinal Endoscopic Surgeons. Guidelines for diagnosis, treatment, and use of laparoscopy for surgical problems during pregnancy. *Surg Endosc* 2011;25:3479–92.
- [11] Iafrazi MD, Yarnell R, Schwaizberg SD. Gasless laparoscopic cholecystectomy in pregnancy. *J Laparoendosc Surg* 1995;5:127–30.
- [12] Sadot E, Telem DA, Arora M, Butala P, Nguyen SQ, Divino CM. Laparoscopy: a safe approach to appendicitis during pregnancy. *Surg Endosc* 2010;24:383–9.
- [13] Mage G, Canis M, Manhes H, Pouly JL, Bruhat MA. Laparoscopic management of adnexal torsion. A review of 35 cases. *J Reprod Med* 1989;34:520–4.
- [14] Bassil S, Steinhart U, Donnez J. Successful laparoscopic management of adnexal torsion during week 25 of a twin pregnancy. *Hum Reprod* 1999;14:855–7.
- [15] Schmidt T, Nawroth F, Foth D, Rein DT, Römer T, Mallmann P. Gasless laparoscopy as an option for conservative therapy of adnexal pedicular torsion with twin pregnancy. *J Am Assoc Gynecol Laparosc* 2001;8:621–2.
- [16] Römer T, Bojahr B, Schwesinger G. Treatment of a torqued hematosalpinx in the thirteenth week of pregnancy using gasless laparoscopy. *J Am Assoc Gynecol Laparosc* 2002;9:89–92.
- [17] Balthazar U, Steiner AZ, Boggess JF, Gehrig PA. Management of a persistent adnexal mass in pregnancy: what is the ideal surgical approach. *J Minim Invasive Gynecol* 2011;18:720–5.
- [18] Tanaka H, Futamura N, Takubo S, Toyoda N. Gasless laparoscopy under epidural anesthesia for adnexal cysts during pregnancy. *J Reprod Med* 1999;44:929–32.
- [19] Murakami T, Noda T, Okamura C, Terada Y, Morito Y, Okamura K. Cul-de-sac packing with a metreurynter in gasless laparoscopic cystectomy during pregnancy. *J Am Assoc Gynecol Laparosc* 2003;10:421–3.
- [20] Oguri H, Taniguchi K, Fukaya T. Gasless laparoscopic management of ovarian cysts during pregnancy. *Int J Gynaecol Obstet* 2005;91:258–9.
- [21] Phupong V, Bunyavejchewin S. Gasless laparoscopic surgery for ovarian cyst in a second trimester pregnant patient with a ventricular septal defect. *Surg Laparosc Endosc Percutan Tech* 2007;17:565–7.
- [22] Barrenetxea G, Barinaga-Rementería L, Lopez De Larruzea A, Agirregoikoa JA, Mandiola M, Carbonero K. Heterotopic pregnancy: two cases and a comparative review. *Fertil Steril* 2007;87(417):e9–15.
- [23] Pasic RP, Hammons G, Gardner JS, Hainer M. Laparoscopic treatment of cornual heterotopic pregnancy. *J Am Assoc Gynecol Laparosc* 2002;9:372–5.
- [24] Phupong V, Bunyavejchevin S. Successful treatment of a heterotopic tubal pregnancy by gasless laparoscopic surgery. *J Obstet Gynaecol Res* 2010;36:686–9.
- [25] Usifo F, Macrae R, Sharma R, Opemuyi IO, Onwuzurike B. Successful myomectomy in early second trimester of pregnancy. *J Obstet Gynaecol* 2007;27:196–7.
- [26] Son CE, Choi JS, Lee JH, Jeon SW, Bae JW, Seo SS. A case of laparoscopic myomectomy performed during pregnancy for subserosal uterine myoma. *J Obstet Gynaecol* 2011;31:180–1.
- [27] Melgrati L, Damiani A, Franzoni G, Marziali M, Sesti F. Isobaric (gasless) laparoscopic myomectomy during pregnancy. *J Minim Invasive Gynecol* 2005;12:379–81.
- [28] Damiani A, Melgrati L, Marziali M, Sesti F. Gasless laparoscopic myomectomy: indications, surgical technique, and advantages of a new procedure for removing uterine leiomyomas. *J Reprod Med* 2003;48:792–8.
- [29] Sungler P, Heinerman PM, Steiner H, et al. Laparoscopic cholecystectomy and interventional endoscopy for gallstone complications during pregnancy. *Surg Endosc* 2000;14:267–71.
- [30] Sherard 3rd GB, Hodson CA, Williams HJ, Semer DA, Hadi HA, Tait DL. Adnexal masses and pregnancy: a 12-year experience. *Am J Obstet Gynecol* 2003;189:358–62 [discussion 362–3].
- [31] Mathevet P, Nessah K, Dargent D, Mellier G. Laparoscopic management of adnexal masses in pregnancy: a case series. *Eur J Obstet Gynecol Reprod Biol* 2003;108:217–22.
- [32] Yuen PM, Ng PS, Leung PL, Rogers MS. Outcome in laparoscopic management of persistent adnexal mass during the second trimester of pregnancy. *Surg Endosc* 2004;18:1354–7.
- [33] Hunter JG, Swanstorm L, Thomburg K. Carbon dioxide pneumoperitoneum induces fetal acidosis in a pregnant ewe model. *Surg Endosc* 1995;9:272–9.
- [34] Cruz AM, Southerland LC, Duke T, Townsend HG, Ferguson JG, Crone LA. Intraabdominal carbon dioxide insufflation in the pregnant ewe. Uterine blood flow, intraamniotic pressure, and cardiopulmonary effects. *Anesthesiology* 1996;85:1395–402.

- [35] Nagai H, Kondo Y, Yasuda T. An abdominal wall-lift method of laparoscopic cholecystectomy without peritoneal insufflation. *Surg Laparosc Endosc* 1993;3:175–9.
- [36] Smith RS, Fry WR, Tsoi EK, et al. Gasless laparoscopy and conventional instruments: the next phase of minimally invasive surgery. *Arch Surg* 1993;128:1102–7.
- [37] Callery MP, Soper NJ. Physiology of the pneumoperitoneum. *Baillieres Clin Gastroenterol* 1993;7:757–77.
- [38] Beebe DS, Swica H, Carlson N, Palahniuk RJ, Goodale RL. High levels of carbon monoxide are produced by electro-cautery of tissue during laparoscopic cholecystectomy. *Anesth Analg* 1993;77:338–41.
- [39] Al-Fozan H, Tulandi T. Safety and risks of laparoscopy in pregnancy. *Curr Opin Obstet Gynecol* 2002;14:375–9.
- [40] Sesti F, Capobianco F, Capozzolo T, Pietropolli A, Piccione E. Isobaric gasless laparoscopy versus minilaparotomy in uterine myomectomy: a randomized trial. *Surg Endosc* 2008;22:917–23.