

THE SURGICAL TREATMENT OF PITUITARY ADENOMAS IN THE EIGHTH DECADE

Bernardo Fraioli, M.D., Francesco S. Pastore, M.D., Stefano Signoretti, M.D., Giovanni M.F. De Caro, M.D., and Renato Giuffrè, M.D.

Institute of Neurosurgery, University of Rome "Tor Vergata," Rome, Italy

Fraioli B, Pastore FS, Signoretti S, De Caro GMF, Giuffrè R. The surgical treatment of pituitary adenomas in the eighth decade. *Surg Neurol* 1999;51:261-7.

BACKGROUND

The surgical treatment of pituitary adenomas in elderly patients (i.e., over 70 years of age) is a special problem because of the increased rate of perioperative complications and the reduced tolerance of postoperative fluid and electrolyte imbalance. Therefore, the unquestionable progress in the pharmacological and radiotherapy may not allow these patients the option of radical surgical treatment. We report our experience with the transsphenoidal procedure for pituitary adenomas in aged patients in an attempt to contribute to a better definition of the actual role of surgery.

METHODS

Transsphenoidal surgery was performed in 11 patients over 70 years of age affected by various histological types of pituitary micro- and macroadenomas, ranging from Hardy Grade I through IIIc. Special care was dedicated to the postoperative treatment, in particular to water and electrolyte balances, and to the immediate treatment of any pathological variation of these parameters.

RESULTS

We had no mortality and no postoperative adjunctive morbidity. All the patients recovered well from the operation with an average hospital stay of 20 days. The tumor removal was complete in six cases and partial in the remaining five. With an average follow-up of 2 years, we did observe only one case of symptomatic recurrence of the disease.

CONCLUSIONS

Transsphenoidal surgery in the elderly is feasible and quite safe in the hands of an experienced team, if special care is devoted to the preoperative selection of patients and to the postoperative treatment of fluid and electrolyte imbalance. © 1999 by Elsevier Science Inc.

KEY WORDS

Pituitary adenoma, surgery, elderly.

Pituitary adenoma is not considered a disease of advanced age; its incidence is rated around 3-4% [14,18,19,21,25]. Yet the age-related functional endocrine and visual impairment of elderly people may occasionally delay or even hinder the correct diagnosis of pituitary adenoma [5].

Out of our series of 904 pituitary adenomas operated on from January 1976 to May 1997, 11 cases older than 70 years at the time of surgery are considered. Our guidelines for patient selection and treatment are reported.

PATIENTS AND METHODS

The 11 patients were all in the eighth decade of life. The mean age was 72 years, with a range from 70 to 77 years. Five patients were males and six females. In all patients complete hormonal screening was obtained and the visual acuity and visual fields were examined pre- and postoperatively. Eight patients presented with non-functioning adenomas. One patient had a GH-secreting adenoma, causing acromegalic features, treated for 3 months with octreotide; another patient harbored an ACTH adenoma with consequent Cushing syndrome; and one patient had a PRL-secreting adenoma.

In 10 patients the hormonal serum levels suggested a panhypopituitarism without any evident clinical feature. Nine patients complained of a significant visual deficit (amaurosis in one case) and visual field defects lasting from 6 months to 4 years (mean, 18.5 months). Case 11 presented with a III cranial nerve palsy as a first symptom.

General clinical condition was evaluated according to the ASA scale [1], rating the anesthesiological risk from 1 to 5; nine patients were rated 1 or 2 and the others 3.

Pre- and postoperative contrast computed tomography (CT) studies were obtained in patients

Address reprint request to: Dr. Bernardo Fraioli, Istituto di Neurochirurgia, Università di Roma "Tor Vergata," Ospedale S. Eugenio, Piazzale dell'Umanesimo, 10-00144 Rome, Italy.

Received November 25, 1997; accepted February 4, 1998.

operated on before 1987; in Case 2 cerebral angiography was also performed. Thereafter, all the patients underwent pre- and postoperative contrast CT and magnetic resonance imaging (MRI).

Tumor size and extension were evaluated with a modified version of the Hardy classification: for Case 1 the definition was microadenoma; Case 6 was considered an intrasellar adenoma, and Case 4 an enclosed adenoma with little suprasellar extension. Cases 3, 5, 10, and 11 appeared as enclosed adenomas with marked suprasellar extension. Moderate and marked suprasellar extension was seen in the locally invasive adenomas of Cases 8 and 9, respectively. Cases 2 and 7 had diffuse invasive adenomas with marked suprasellar extension. Little, moderate, or marked suprasellar extension, respectively, apply to tumors extending to the inferior, middle, and superior parts of the third ventricle.

Tissue of different appearance and consistency was enclosed in the adenoma of Case 7; histological examination revealed a metastatic adenocarcinoma. Eventually bronchoscopic biopsy allowed the diagnosis of small bronchogenic adenocarcinoma not visible on standard chest X-ray.

Emergency surgery was performed in Case 4 because of sudden right eye blindness caused by an intratumoral hemorrhage.

The surgical approach was transnasal- or sublabial-sphenoidal in all patients, according to the modified Hardy technique [9,10]. We especially recommend the supine position for aged patients [17]. Owing to tumoral right cavernous sinus invasion, the unilateral inferomedial transmaxillo-sphenoidal approach was performed in Case 9 [11].

Postoperatively the patients were watched in the ICU, with special attention to heart and circulation homeostasis and fluid-electrolyte balance. Monitoring of hourly diuresis, specific gravity and continuous matching between serum and urinary osmolarity, provided guidelines for therapy.

We noted diabetes insipidus to be a harmful complication in five cases, all treated with desmopressin (DDAVP).

RESULTS

Table 1 summarizes the data of the 11 reported cases. Results are shown in Table 2. No perioperative mortality was registered.

Tumor resection was total in six cases and subtotal in five. No anesthesiological complications, either intra- or postoperative, were registered.

At discharge improvement of the visual acuity and/or visual field was evident in eight patients, whereas in three it was unchanged.

Postoperative PRL and GH levels returned to normal in Cases 4 and 6. Clinical and laboratory control after 6 months in the patient bearing an ACTH-secreting adenoma demonstrated marked improvement of the Cushing syndrome and normalization of serum ACTH and of dynamic endocrinological tests.

Cerebrospinal fistula complicated the surgical procedure in three cases. In two of them a minimal cisternal leakage was sealed with intraoperative plasty by means of fat and fibrin glue; in the other case, with a large chiasmatic cistern laceration, 6 days of continuous lumbar drainage followed a careful intraoperative plasty.

Six patients developed transient postoperative diabetes insipidus lasting 1-6 days; in Case 9 diabetes insipidus was still present 4 months after discharge. The postoperative course in this patient was also complicated by a generalized seizure, very likely related to severe delayed hyponatremia [13]; it was treated with aldosterone and hypertonic solutions.

As described in Table 1, eight patients were treated with specific hormonal substitutes at discharge. The mean hospital stay was 17 days, ranging from 10 to 33 days. The mean follow-up was 2 years with a range from 6 months to 11 years. Four patients (Cases 1,2,4,5) were lost to follow-up after 6 months. Control neuroradiological examinations in this group confirmed total tumor resection in Cases 1 and 4 and subtotal ablation in Cases 2 and 5. Patient 7 died of lung cancer 2 years after transsphenoidal surgery. In this case, 1 year postoperatively the patient complained again of a visual loss; a cranial CT was performed that demonstrated local recurrence of disease. The patient at that time had multiple metastatic locations, so the option of a second transsphenoidal resection was discarded.

The other six patients up to now are living an autonomous life, three with no therapy (Cases 3,6, and 10) and three with hormonal replacement therapy (Cases 8, 9, and 11). Control neuroradiological studies confirmed the radical tumor excision in Patients 3, 6, 10, and 11, whereas in Patients 8 and 9 a small tumor remnant is still present; their evolution is monitored with serial MRI (Figures 1-5).

In the follow-up period no patient except Case 7 has shown a symptomatic recurrence.

DISCUSSION

In the literature, the figures on aged patients operated on for a pituitary adenoma are scarce. Undoubtedly, it is usually wiser to refer these patients for medical and/or radiation therapy whenever possible, than to recommend surgery.

1 Synopsis of Patient Data

#	AGE	SEX	CLINICAL SYMPTOMS	ASA	TUMOR LOCATION AND EXTENSION	HORMONE LEVELS	SURGICAL TECHNIQUE	SURGICAL REMOVAL	FLUID-ELECTROLYTE DISORDERS	HOSPITAL STAY	THERAPY AT DISCHARGE	FOLLOW-UP
1	70	F	Cushing syndrome	2	Microadenoma	ACTH = 1.5 pg/ml	Transsphenoidal (transnasal)	Total	None	21 days	None	6 months
2	71	F	Severe hemianopsy and visual acuity impairment	1	Invasive-diffuse lesion with remarkable suprasellar extension	Hypopituitarism	Transsphenoidal (transnasal)	Subtotal	Diabetes insipidus (48 hrs)	11 days	Cortisone	6 months
3	71	F	Severe hemianopsy and visual acuity impairment	1	Enclosed lesion with remarkable suprasellar extension	Hypopituitarism	Transsphenoidal (transnasal)	Total	None	16 days	Cortisone	11 years
4	71	M	Bitemporal hemianopsy Acute onset right amaurosis	2	Enclosed lesion with slight suprasellar extension	PRL = 100 ng/ml Hypopituitarism	Transsphenoidal (Transnasal)	Total	None	14 days	Cortisone	6 months
5	72	M	Severe hemianopsy and visual acuity impairment	2	Enclosed lesion with remarkable suprasellar extension	Hypopituitarism	Transsphenoidal (Transnasal)	Subtotal	None	14 days	Cortisone	6 months
6	71	M	Acromegaly	2	Intrasellar lesion	HGH = 14 ng/ml Hypopituitarism	Transsphenoidal (transnasal)	Total	None	32 days	None	3 years
7	71	M	Left amaurosis; Severe right visual impairment with hemianopsy	3	Invasive-diffuse lesion with remarkable suprasellar extension	Hypopituitarism	Transsphenoidal (sublabial)	Subtotal	Diabetes insipidus (6 days)	13 days	Cortisone	2 years
8	74	F	Bitemporal hemianopsy	2	Invasive-localized lesion with moderate suprasellar extension	Hypopituitarism	Transsphenoidal (sublabial)	Subtotal	Diabetes insipidus (4 days)	13 days	Cortisone Tiroxine	3 years
9	77	F	Severe hemianopsy and visual acuity impairment	3	Invasive-diffuse lesion with remarkable suprasellar extension	Hypopituitarism	Trans-maxillo-sphenoidal	Subtotal	Diabetes insipidus (4 months) Hyponatremia (20 days)	33 days	DDAVP (Minitrin™) Aldosterone (Florinef™) Cortisone Tiroxine	4 months
10	72	M	Severe hemianopsy and visual acuity impairment	1	Enclosed lesion with remarkable suprasellar extension	Hypopituitarism	Transsphenoidal (transnasal)	Total	Diabetes insipidus (5 days)	13 days	None	3 years
11	74	F	Headache; 3rd cranial nerve palsy	2	Enclosed lesion with remarkable suprasellar extension	Hypopituitarism	Transsphenoidal (transnasal)	Total	Diabetes insipidus (24 hrs)	10 days	Cortisone Tiroxine	6 months

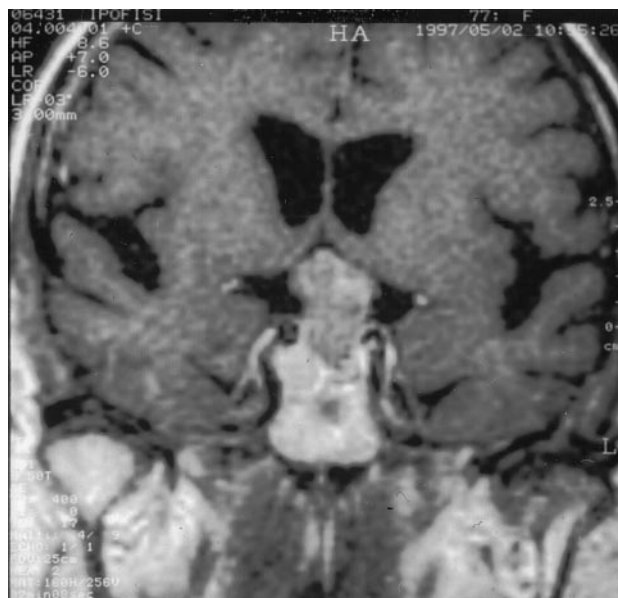2 Outcome after Surgery

PATIENT	RESULT
1	Very good
2	Good
3	Very good
4	Fair
5	Fair
6	Very good
7	Good
8	Fair
9	Fair
10	Very good
11	Good

Outcome scale: Very good, autonomous life without any specific therapy; Good, autonomous life with therapy; Fair, autonomous life with adjunctive neurologic deficits; and Poor, Non-autonomous life.

Our experience, in agreement with other authors [3-5,18,19,21], suggests that the surgical treatment of pituitary adenomas diagnosed in the eighth decade of life is certainly feasible, as supported by the results of the present series, with no mortality.

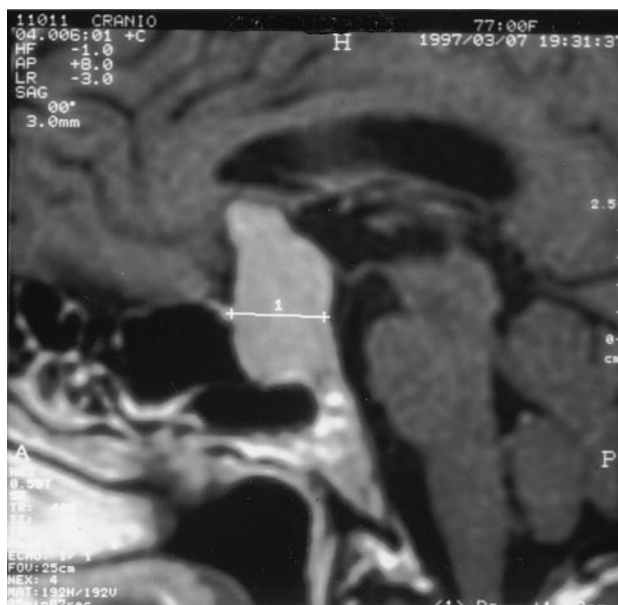
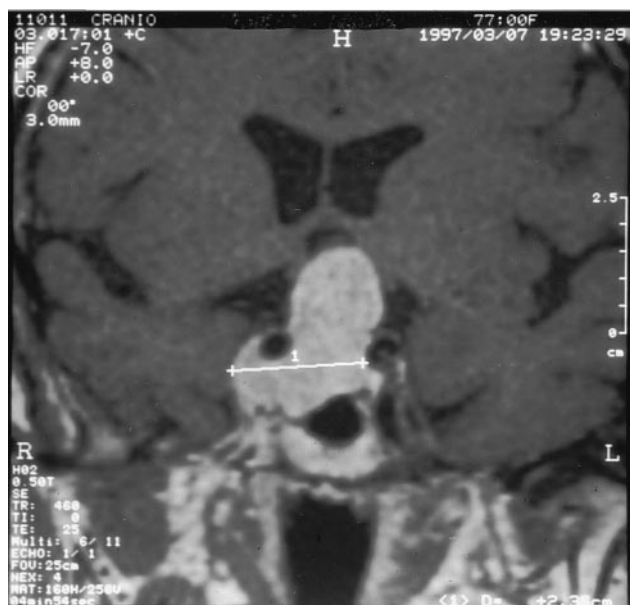Nevertheless, the surgical option should be compared first with pharmacological and radiotherapeutic therapies. The initial choice of the medical treatment with bromocriptine or cabergoline for patients bearing PRL-secreting adenomas seems sensible, unless one is dealing with an acute neurological emergency such as the sudden amaurosis in one of our cases. Medical treatment [2,3,6] should



3 Case 9; T2-weighted MRI coronal sequence performed 1 month postoperatively illustrate the amount of tumor resection and the descent of its uppermost component in the sella.

also be advocated before considering surgery for aged patients harbouring GH-secreting adenomas, although a much lower efficacy of the drugs has been demonstrated in this particular age group [8].

The majority of patients in our series complained of visual disturbances; therefore, radiotherapy was



1 +

2 Case 9; T2-weighted MRI coronal and sagittal sequences show a huge pituitary adenoma extending upwards to the third ventricle and laterally involving both the cavernous sinuses.

gravity, and urinary-serum osmolarity ratio was established.

Diabetes insipidus was adequately treated with vasopressin DDAVP (5-10 U). Hyponatremia was corrected with continuous parenteral infusion of sodium hypertonic solutions (1-2 ml/Kg/hour, 1-2 mEq Na/hour). The limited sodium sparing capability and the hypovolemic state of most of these patients did not allow us to treat hyponatremia with fluid restriction.

Last but not least, the goal of surgery should not be to pursue radical tumor excision at all cost: for hypophyseal and diencephalopituitary surgery, the primary goal is no mortality or relevant adjunctive morbidity.

REFERENCES

- American Society of Anesthesiologists. New classification of physical status. *Anesthesiology* 1963;24:111.
- Baskin DS, Wilson CB. Bromocriptine treatment of pituitary adenomas. *Neurosurgery* 1981;8:741-4.
- Bevan JS, Adams CBT, Burke CW, Morton KE, Molyneux AJ, Moore RA, Esiri MM. Factors in the outcome of transsphenoidal surgery for prolactinoma and non-functioning tumour, including pre-operative bromocriptine therapy. *Clin Endocrinol (Oxf)* 1987;26:541-6.
- Black McL P, Zervas NT, Candia GL. Incidence and management of complications of transsphenoidal operation for pituitary adenomas. *Neurosurgery* 1987;20:920-4.
- Cohen DL, Bevan JS, Adams CB. The presentation and management of pituitary tumours in the elderly. *Age Ageing* 1989;18:247-52.
- Crosignani PG, Ferrari C, Liuzzi A, Benco R, Mattei A, Rampini P, Dellabonzana D, Scarduelli C, Spelta B. Treatment of hyperprolactinemic states with different drugs: a study with bromocriptine, metergoline and lisuride. *Fertil Steril* 1982;37:61-7.
- Dòczi T, Joè F, Bodosi M. Central neuroendocrine control of the brain water, electrolyte, and volume homeostasis. *Acta Neurochir (Wien)* 1990;47 Suppl: 122-6.
- Ezzat S, Snyder PJ, Young WF, Boyajy LD, Newman C, Klibanski A, Molitch ME, Boyd AE, Sheeler L, Cook DM, Malarkey WB, Jackson I, Vance ML, Thorner MO, Barkan A, Frohman LA, Melmed S. Octreotide treatment of acromegaly: a randomized multicenter study. *Ann Intern Med* 1992;117:711-18.
- Fraioli B, Esposito V, Palma L, Cantore G. Hemorrhagic pituitary adenomas: clinico-pathological features and surgical treatment. *Neurosurgery* 1990;27: 741-7.
- Fraioli B, Esposito V, Liccardo G, Giuffrè R, Cantore G. The supine position for trans-sphenoidal surgery. *Neurosurg Rev* 1994;17:275-6.
- Fraioli B, Esposito V, Santoro A, Iannetti G, Giuffrè R, Cantore G. Transmaxillophenoidal approach to tumors invading the medial compartment of the cavernous sinus. *J Neurosurg* 1995;82:63-9.
- Goffman TE, Dewan R, Arakaki R, Gorden P, Oldfield EH, Glatstein E. Persistent or remittent acromegaly: long term endocrinologic efficacy and neurologic safety of post-surgical radiation therapy. *Cancer* 1992;69:271-5.
- Kelly DF, Laws ER Jr, Fossett D. Delayed hyponatremia after transsphenoidal surgery for pituitary adenoma—report of nine cases. *J Neurosurg* 1995;83: 363-7.
- Kovacs K, Ryan N, Horvath E, Singer W, Ezrin C. Pituitary adenomas in old age. *J Gerontol A Biol Sci Med Sci* 1980;35:16-22.
- Levy RP, Fabrikant JL, Frankel KA, Phillips MH, Lyman JT, Lawrence JH, Tobias CA. Heavy-charged-particle radiosurgery of the pituitary gland: clinical results of 840 patients. *Stereotact Funct Neurosurg* 1991;57:22-35.
- Lightman S. Central nervous system control of fluid balance: physiology and pathology. *Acta Neurochir (Wien)* 1990;47 Suppl:90-4.
- Newfield P, Albin MS, Chestnut JS, Maroon J. Air embolism during transsphenoidal pituitary operations. *Neurosurgery* 1978;2:39-42.
- Pospiech J, Stolke D, Pospiech FR. Surgical treatment of pituitary adenomas in elderly patients. *Acta Neurochir Suppl (Wien)* 1996;65:35-6.
- Puchner MJA, Knappe UJ, Ludecke DK. Pituitary surgery in elderly patients with acromegaly. *Neurosurgery* 1995;35:677-84.
- Rolls BJ, Phillips PA. Aging and disturbances of thirst and fluid balance. *Nutr Rev* 1990;48:137-44.
- Ross DA, Wilson CB. Results of transsphenoidal microsurgery for growth hormone-secreting pituitary adenomas in a series of 214 patients. *J Neurosurg* 1988;68:854-67.
- Sica DA, Harford A. Sodium and water disorders in the elderly. In: Zawada ET Jr, Sica DA, eds. *Geriatric Nephrology and Urology*. Littleton: John Wright-PSG Inc., 1985:127.
- Solomon LR, Lye M. Hyponatremia in the elderly patient. *Gerontology* 1990;36:171-9.
- Vacanti CJ, van Houten RJ, Hiu RC. A statistical analysis of the relationship of physical status to post-operative mortality in 68,388 cases. *Anesth Analg* 1970;49:564-6.
- Walker AE, Robins M, Weinfeld FD. Epidemiology of brain tumors: the national survey of intracranial neoplasms. *Neurology* 1985;35:219-26.
- Wilson CB. A decade of pituitary microsurgery—The Herbert Olivecrona Lecture. *J Neurosurg* 1984;61: 814-33.

COMMENTARY

This is a very well-written and sufficiently clear documentation of 11 operated cases of pituitary adenomas in patients in their eighth decade of life. Because we are confronted more and more often with the decision of how and whether to treat elderly patients, data like these are very helpful. The authors have obtained excellent results in the treatment of large pituitary adenomas causing visual

impairment. They outline their modalities for decision-making and their treatment protocol for this specific situation.

We have published similar experiences in acromegaly, extending the age limit to 81 years [1]. Concerning non-secreting adenomas, we were forced to operate on patients up to 86 years of age to prevent blindness. Nevertheless, as shown by Fraioli, even with patients in their 70s, we have to consider many factors to achieve results that really

improve the condition of these often fragile and multimorbid patients.

D. K. Lüdecke, M.D.
*Neurochirurgie
Universität Hamburg
Hamburg, Germany*

REFERENCE

1. Puchner MJ, Knappe UJ, Lüdecke DK. Pituitary surgery in elderly patients with acromegaly. *Neurosurgery* 1995;36:677-83.