



Secondary parkinsonism due to arachnoid cyst of the frontal lobe

Dorina Tiple, Floriana De Angelis, Aldo Spallone, et al.

J Neurol Neurosurg Psychiatry 2010 81: 400

doi: 10.1136/jnnp.2009.177683

Updated information and services can be found at:
<http://jnnp.bmj.com/content/81/4/400.full.html>

These include:

References

This article cites 8 articles, 2 of which can be accessed free at:
<http://jnnp.bmj.com/content/81/4/400.full.html#ref-list-1>

Email alerting service

Receive free email alerts when new articles cite this article. Sign up in the box at the top right corner of the online article.

Notes

To order reprints of this article go to:
<http://jnnp.bmj.com/cgi/reprintform>

To subscribe to *Journal of Neurology, Neurosurgery & Psychiatry* go to:
<http://jnnp.bmj.com/subscriptions>

Neurological picture

Secondary parkinsonism due to arachnoid cyst of the frontal lobe

A 42-year-old right-handed woman presented with a 1 year history of headache, localised in both frontoparietal regions, and a 6 month history of left-sided tremor and clumsiness; depression was another notable symptom of this patient. Neurological examination revealed left hemiparkinsonism, characterised by mixed tremor (postural, action and intermittent rest tremor) in both extremities, hypomimia, bradykinesia, cogwheel rigidity and loss of arm swing during gait on the left hand side. Deep tendon reflexes were brisk on the left side with a positive Babinski sign. The Unified Parkinson's Disease Rating Scale motor score was 15 points and the Hamilton Rating Scale for Depression was 16 points.

Cerebral CT scan was performed showing a vast arachnoid cyst of the right frontal lobe with a maximum diameter of 66×89 mm; this formation determined compression of the right basal ganglia and lateral ventricle causing a shift of these cerebral structures towards the left side (figure 1A).

The patient underwent neurosurgical treatment with partial removal of the arachnoid cyst. Excision of the outer wall of the cyst membrane resulted in loss of transparent CSF from the lesion. Histological examination of the postoperative biopsy confirmed the diagnosis of arachnoid cyst. In the following days after the neurosurgical intervention, rapid clinical improvement was observed, characterised by disappearance of the headache and significant amelioration of the motor disorder and depression. The Unified Parkinson's Disease Rating Scale motor score 1 week after surgery was 5. Postoperative CT scan performed at the same time revealed decompression of the right frontal lobe with a markedly reduced volume of the cyst formation (figure 1B). Iodine-123-FP-CIT (DaTSCAN) cerebral single photon emission CT was also performed. Its normal picture excluded concomitant degeneration of the nigrostriatal pathways and was consistent with the diagnosis in this patient of secondary parkinsonism.

Arachnoid cysts are the most frequent congenital cystic intracranial abnormalities. Frontal arachnoid cysts have been reported in

association with non-specific neurological signs, such as headache, psychiatric and cognitive disorders (depression, verbal memory deficits, hallucinations, stupor), hemiparesis, ataxia and seizures.¹⁻⁷ Obstructive hydrocephalus is also a possible consequence.⁸ Our case is the first associating frontal arachnoid cyst with a parkinsonian picture, which markedly improved after neurosurgical treatment of the cyst. It also underlines the fact that early neuroimaging is mandatory in any case of parkinsonism presenting subacutely, in addition to other neurological signs with strictly unilateral features.

Dorina Tiple,^{1,2} Floriana De Angelis,^{1,2} Aldo Spallone,² Carlo Colosimo¹

¹Dipartimento di Scienze Neurologiche, Sapienza Università di Roma, Roma, Italy;

²Dipartimento di Scienze Neurologiche, Neurological Centre of Latium, Roma, Italy

Correspondence to Dr C Colosimo, Dipartimento di Scienze Neurologiche, Sapienza Università di Roma, Viale dell'Università 30, Rome I-00185, Italy; carlo.colosimo@uniroma1.it

Competing interests None.

Patient consent Obtained.

Provenance and peer review Not commissioned; externally peer reviewed.

Accepted 18 May 2009

J Neurol Neurosurg Psychiatry 2010;**81**:400. doi:10.1136/jnnp.2009.177683

REFERENCES

1. **Tsurushima H**, Harakuni T, Saito A, *et al*. Symptomatic arachnoid cyst of the left frontal convexity presenting with memory disturbance—case report. *Neurol Med Chir (Tokyo)* 2000;**40**:339–41.
2. **da Silva JA**, Alves A, Talina M, *et al*. Arachnoid cyst in a patient with psychosis: case report. *Ann Gen Psychiatry* 2007;**6**:16.
3. **Arroyo S**, Santamaria J. What is the relationship between arachnoid cysts and seizure foci? *Epilepsia* 2005;**38**:1098–102.
4. **Helland CA**, Wester K. A population based study of intracranial arachnoid cysts: clinical and neuroimaging outcomes following surgical cyst decompression in adults. *J Neurol Neurosurg Psychiatry* 2007;**78**:1129–35.
5. **Raeder MB**, Helland CA, Huqdaql K, *et al*. Arachnoid cysts cause cognitive deficits that improve after surgery. *Neurology* 2005;**64**:160–2.
6. **Wester K**. Peculiarities of intracranial arachnoid cysts: location, sidedness, and sex distribution in 126 consecutive patients. *Neurosurgery* 1999;**45**:775–9.
7. **Golaz J**, Bouras C. Frontal arachnoid cyst. A case of bilateral frontal arachnoid cyst without clinical signs. *Clin Neuropathol* 1993;**12**:73–8.
8. **Tohma Y**, Hasegawa M, Nakau H, *et al*. Obstructive hydrocephalus associated with arachnoid cyst in the elderly. *J Clin Neurosci* 2004;**11**:542–54.

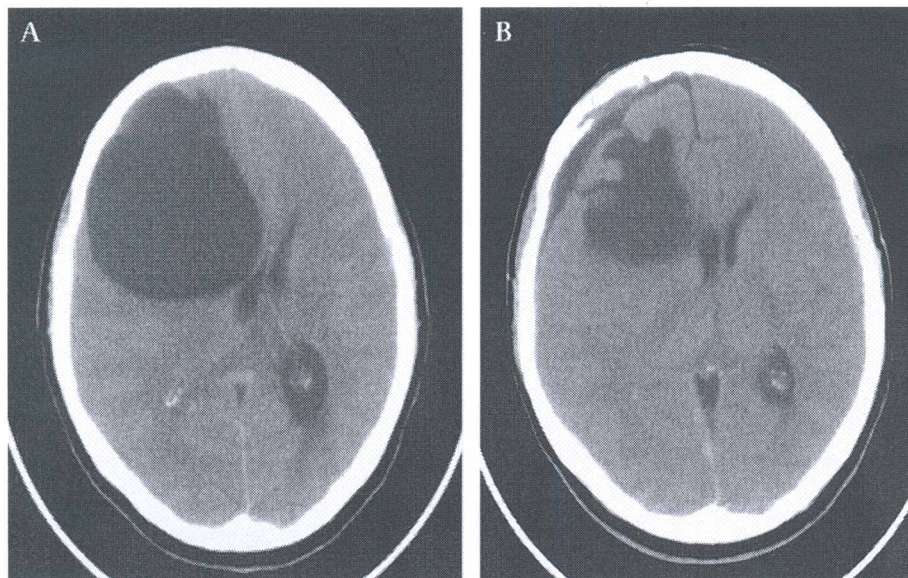


Figure 1 Preoperative (A) and postoperative (B) brain CT scan of the patient. Non-contrast computed tomography (CT) demonstrating a large arachnoid cyst before (left) and after (right) its surgical treatment. The image before surgery also shows right basal ganglia compression associated with marked midline shift.