

## ORIGINAL ARTICLE

# Clinical and radiological outcomes of novel digital workflow and dynamic navigation for single-implant immediate loading in aesthetic zone: 1-year prospective case series

Alessandro Pozzi<sup>1,2</sup>  | Lorenzo Arcuri<sup>3</sup> | Paolo Carosi<sup>3</sup>  | Alessandra Nardi<sup>4</sup> | Joseph Kan<sup>5</sup>

<sup>1</sup>Goldstein Center for Esthetic and Implant Dentistry, Department of Restorative Sciences, Augusta University, Augusta, GA, USA

<sup>2</sup>Private Practice Rome, Rome, Italy

<sup>3</sup>Department of Chemical Science and Technologies, PhD in Materials for Health, Environment and Energy-Dentistry, University of Rome Tor Vergata, Rome, Italy

<sup>4</sup>Department of Mathematics, University of Rome Tor Vergata, Rome, Italy

<sup>5</sup>Department of Implant Dentistry, Loma Linda University School of Dentistry, Loma Linda, CA, USA

## Correspondence

Alessandro Pozzi, International Center Oral Rehabilitation, Viale Liegi, 44, 00198 Rome, Italy.  
Email: apozzi@augusta.edu

## Funding information

This research received no specific grant from any funding agency in the public, commercial, or not-for-profit sectors

## Abstract

**Objectives:** To evaluate clinical, radiological performance of novel digital workflow integrating dynamic navigation to streamline in one-visit single-implant immediate loading in aesthetic zone.

**Material and methods:** Consecutive patients requiring one single-implant in aesthetic zone of both jaws were treated between May and September 2017. Primary outcomes were implant and prosthetic success rates, surgical and prosthetic complications, marginal bone loss (MBL), final pink aesthetic score (PES-f), and implant stability quotient (ISQ-f). Secondary outcomes were ISQ-0 and PES-0 at implant positioning and PES-p at definitive prosthesis placement. Potential effect of jaw (maxilla vs mandible), bio-type (thin vs thick), type of incision (flap vs flapless), and implant site (healed vs. post-extractive) on the primary outcomes (MBL, PES-f, and ISQ-f) was evaluated through a multivariable analysis.

**Results:** Fifty-two implants were placed (follow-up 18.6, 15–20 months). One post-extractive implant failed. No other surgical, biological complications occurred, accounting for 98.10% cumulative success rate (CSR). No definitive prostheses failed. Mean MBL was  $-0.63 \pm 0.25$  mm ( $-1.69$  to  $-0.06$ ). PES-f was  $12.34 \pm 1.41$  (9–14). ISQ-f was  $78.1 \pm 3.2$  (70–84). Age had significantly negative effect on MBL and PES-f ( $p = .0058$  and  $p = .0052$ ). No other variables significantly affected primary outcomes.

**Conclusions:** Within study limitations, investigated digital workflow integrating dynamic navigation was reliable for single-implant immediate loading in aesthetic zone in one visit. No statistically significant difference was found for MBL, PES-f, and ISQ-f, considering type of incision (flap vs. flapless), implant site (healed vs post-extractive), jaw (maxilla vs. mandible), and biotype (thick vs. thin). Live-tracked dynamic navigation may have contributed to improve operator clinical performance regardless of implant site characteristics. Further investigations are needed to confirm positive outcomes.

## KEYWORDS

dental implant, digital workflow, Dynamic navigation, guided surgery, immediate loading

This is an open access article under the terms of the Creative Commons Attribution-NonCommercialLicense, which permits use, distribution and reproduction in any medium, provided the original work is properly cited and is not used for commercial purposes.

© 2021 The Authors. *Clinical Oral Implants Research* published by John Wiley & Sons Ltd.

## 1 | INTRODUCTION

Nowadays, both clinicians and patients have set more stringent benchmarks for implant success (Fügl et al., 2016; Jivraj & Chee, 2006). Optimal implant positioning through a prosthetically driven decision making was mandatory to achieve function and satisfactory aesthetics (Pozzi et al., 2016; Rosenfeld et al., 2006). The growing interest in minimally invasive implant placement with the option of delivering immediately a prefabricated temporary prosthesis to restore function and aesthetics led to the development of numerous three-dimensional (3D) planning software programs (Pozzi et al., 2016; van Steenberghe et al., 2005; Verstreken et al., 1996). Technological advancements have significantly improved data acquisition, providing a highly realistic overview of the bone and soft tissue anatomy, and their relationship with the future rehabilitation, as well as bone density, for enhanced predictability of implant stability during the virtual planning stage (Pozzi et al., 2020; Sennerby et al., 2015).

Superimposition and 3D rendering of the facial skeleton, soft tissue, and dentition by means of the fusion of different sets of 3D imaging files (digital imaging and communications in medicine [DICOM]) and stereolithography (STL) files resulted in the creation of a virtual dental patient, providing a systematic method for evaluating all aspects of dentofacial anatomy, function, and aesthetics in a more logical and interdisciplinary manner than the conventional approach (Joda et al., 2015; Joda & Gallucci, 2015; Pozzi et al., 2018a). An integrated digital workflow may enhance a more comprehensive treatment plan, based on a non-invasive simulation of the surgical and prosthetic outcomes, as well as of the critical zone of the soft tissue interface (Pozzi et al., 2018b, 2020).

Computer-assisted implant positioning included static and dynamic systems. Static guided surgery was synonymous with a predetermined implant position without real-time visualization of the implant site preparation as it is being achieved by means of a computer-aided design/computer-aided manufacturing (CAD/CAM) template, with metal sleeves and a coordinated surgical instrumentation (Block & Emery, 2016). No intraoperative position changes can be made with a static system. Dynamic guided surgery or navigation allowed the surgeon a real-time visualization of implant site development, while the drills are in function without any template hiding the surgical field or hampering the soft tissue handling. Full guidance was possible, deviations from the predetermined plan can be assessed in "real time," and the related adjustments of position can be made at any time during the surgery (Jayaratne et al., 2010; Luebbbers et al., 2008).

Dynamic navigation allowed an accurate orchestration of the surgical and prosthetic aspects in real time during the surgery to achieve ideal site-specific results and meet patient expectations of anticipating a lifelike appearance with a fixed provisional restoration to be delivered immediately (Block et al., 2017; Pozzi et al., 2018a).

This prospective single-cohort study aimed to report the clinical and radiological outcomes of patients treated by means of a novel digital workflow integrating dynamic navigation surgery to

streamline in one visit the execution of immediately loaded single-implant treatment in the anterior zone.

Primary outcomes were implant and prosthetic success rates, surgical and prosthetic complications, marginal bone loss (MBL), final pink aesthetic score (PES-f), and implant stability quotient (ISQ-f). Secondary outcomes were ISQ-0 and PES-0 at implant positioning and PES-p at definitive prosthesis placement. The null hypothesis was that jaw (maxilla vs mandible), biotype (thin vs thick), type of incision (flap vs flapless), and implant site (healed vs post-extractive) do not influence the primary outcomes (MBL, PES-f, and ISQ-f).

## 2 | MATERIALS AND METHODS

### 2.1 | Participants and inclusion criteria

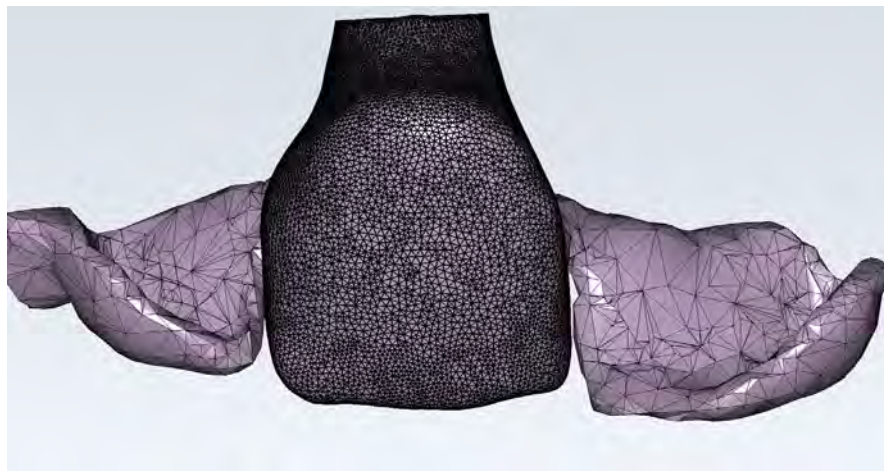
Any patient of both sexes, aged 18 years or older, requiring one single-tooth implant-supported fixed dental prosthesis (FDP), in the aesthetic zone (Belser et al., 2004) of both jaws after signature of the informed consent was enrolled since December 2016. Patients were informed of the nature of the study, benefits, risks, and possible alternative treatments and provided consent prior to inclusion in the study, as well as any follow-up evaluations required for the clinical study. Patients were consecutively treated in one rehabilitation center between May and September 2017 and followed for at least 1 year of function. The study was approved by the institutional scientific and ethical committee of the University of Rome Tor Vergata (Protocol number 202-20). The study was conducted in compliance with the Declaration of Helsinki for biomedical research involving human subjects as amended in 2008 and according to the industry regulations (the International Conference for Harmonization Guideline for Good Clinical Practice and ISO14155).

According to the university institution regulations on the Clinical Trials, study data are in the University repository and not publicly available to avoid compromising ethical standards and legal requirements.

Peer review of empirical data was conducted by an independent examiner-member of the ethical and scientific committee of University of Rome Tor Vergata to confirm the quality of the shared data, and to confirm the data reproduce the analytic results reported in the paper: (1) sample sizes match, (2) the variables described in the article are present as fields in the data university repository, (3) data are complete; (4) data are properly labeled and described; (5) it has the appropriate metadata for the kind of data being shared; and (6) data are available on request from the corresponding author. This study is reported in accordance with the Strengthening the Reporting of Observational Studies in Epidemiology (STROBE) statement for improving the quality of observational studies (<http://www.strobe-statement.org> (von Elm et al., 2014) (Supplementary Material).

Parallel-walled implants with internal conical connection, built-in platform shifting, and a 0.5-mm machined collar (NobelParallel CC, Nobel Biocare AG) were positioned by means of a dynamic navigation

**FIGURE 1** STL file of the preoperative digitally designed screw-retained immediate PMMA provisional. The two lateral wings were used to properly positioning the single crown onto the temporary cylinder



surgery system (X-Guide; X-Nav Technologies, Inc.), in healed and extraction sites, and immediately loaded with a screw-retained FDP. One expert clinician performed all surgical and prosthetic procedures after having received two full days of over-the-shoulder training and completed 40 dynamic navigation implant surgeries.

The following inclusion criteria were used: (1) healthy patients; (2) full-mouth bleeding and full-mouth plaque index lower than or equal to 25%; (3) bone height for at least 10-mm-long implants; (4) bone width of at least 5 and 6 mm for narrow (NP 3.75 mm) and regular (RP 4.3 mm) implants, respectively; (5) fresh extraction sockets with an intact buccal wall; (6) at least 4 and 5 mm of bone beyond the root apex in the mandible and maxilla; (7) minimal insertion torque of 45 Ncm; (8) minimal ISQ mean value of 64; and (9) same-day surgical and prosthetic treatment.

Exclusion criteria were general medical (American Society of Anesthesiologists, ASA, class III or IV) and/or psychiatric contraindications; pregnancy or nursing; any interfering medication such as steroid therapy or bisphosphonate therapy; alcohol or drug abuse; heavy smoking (>10 cigarettes/day), radiation therapy to head or neck region within 5 years, and untreated periodontitis; acute and chronic infections of the adjacent tissues or natural dentition; severe maxillomandibular skeletal discrepancy; high and moderate parafunctional activity (Johansson et al., 2011), absence of opposite teeth; and unavailability to attend regular follow-up visits.

## 2.2 | Digital protocol

All patients received a comprehensive examination including cone beam computed tomography (CBCT) radiographic evaluation and intraoral optical scanning (IOS) on the same day of the dynamic navigation surgery. A high-speed CBCT device (Scanora 3Dx; Kavo Dental GmbH) with an amorphous silicon detector was used to scan the patient with the following settings: field of view (FOV) 140 mm height, 100 mm width, high resolution (voxel sizes 0.25 mm), kV 90, mA 10, and an effective exposure time 6 s. Prior to acquisition of the CBCT scan, a prefabricated thermoplastic device with three radiopaque fiducials (X-Clip; X-Nav Technologies) was placed on the same

dental arch of the implant surgery. The clip device was removed after the CBCT, appropriately labeled, and stored for later use during implant surgery. The patient-specific clip is designed to hold the patient tracking array during the implant surgery. The implant planning software used by the authors (DTX Studio™ Implant 3.4.3.3, Nobel Biocare AG) automatically overlays DICOM data from the CBCT with STL data from the IOS (Carestream 3600 Intraoral Scanner, Carestream Dental LLC) of the patient's intraoral anatomy using a proprietary algorithm process. Therefore, the patient dentition (STL files) was integrated with the craniofacial anatomy (DICOM files) to create a virtual dental patient (VDP) showing a broad smile under static conditions according to a previously published digital workflow named "Smiling scan" (Pozzi et al., 2018a). The automatic tooth design software tool (smart setup) streamlined the digital planning, reducing the time needed to create a prosthetically driven treatment plan and produce a personalized CAD/CAM interim restoration. The smiling scan technique will allow the clinician to visualize the smile design of the patient and particularly the relationship between the upper, mid, and lower thirds of the face, the lines of symmetry, the lips, the cheeks, and the residual dentition and to properly evaluate the aesthetic zone. The 3D implant planning was shared with the prosthetic software (DTX Studio™ Lab 1.10.6; Nobel Biocare AG), and the single-tooth interim prosthesis was automatically designed with an open transmucosal portion and two proximal wings (Figure 1). Such prosthetic design allowed the precise positioning of the temporary crown onto the recipient site in the digitally planned position. The approved 3D planning file including the implant coordinates and the temporary prosthesis was exported and uploaded into the dynamic navigation system (X-Guide; X-Nav Technologies, LLC).

## 2.3 | Calibration protocol

Calibration of the surgical handpiece and the patient tracking array was performed prior to surgery. The handpiece calibration determined the relationship between the geometry of the handpiece tracking array and the axis of the drill. The patient tracking array calibration related the geometry of the patient tracking array to the

CBCT fiducials. Thereafter, the clip with the fiducial markers and the connected patient tracking array cylinder, properly oriented extraorally, was secured onto the teeth in the same location as during CBCT acquisition. The surgical handpiece and patient tracking arrays must be within the line of sight of the overhead stereo cameras to be accurately tracked on the monitor. Hence, a link between the preoperative planning coordinate system and the tracking coordinate system is automatically generated. This stereo tracking algorithm triangulated the two arrays continuously, to determine their precise position and orientation in a common coordinate frame during the surgery. The dynamic connection of the drill body and tip with the patient's CBCT anatomy and the implant coordinates pre-planned into the software is visualized with high magnification on a dedicated screen to guarantee an accurate navigation through a real-time coordination of the surgeon's hands and eyes (Block et al., 2017).

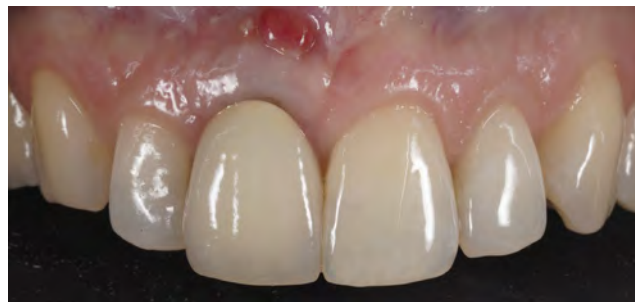## 2.4 | Surgical protocol

On the day of surgery, a single dose of antibiotics (2 g of amoxicillin and clavulanic acid or 600 mg of clindamycin if allergic to penicillin) was administered prophylactically 1 h prior to surgery and continued for 7 days (1 g amoxicillin and clavulanic acid or 300 mg of clindamycin twice a day) after surgery. Prior to the start of surgery, patients rinsed with chlorhexidine 0.2% mouthwash for 1 minute. Local anesthesia was induced by using a 4% articaine solution with epinephrine 1:100,000 (Ubistesin, 3 M ESPE).

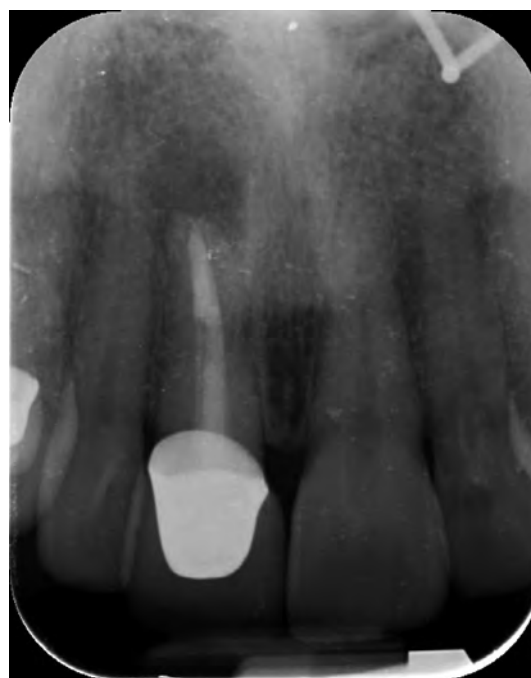Depending on the recipient site characteristics, conventional (with flap) or flapless surgical procedure was performed. The dynamic navigation system did not require a dedicated drill kit. Any type of drill can be used to prepare the implant site after calibrating the drill length. The 360° dynamic navigation control of the implant site preparation allowed the operator to perform a low-speed drilling ranging from 250 rotations per minute (RPM) and 500 RPM according to the bone density. Each drill was used under copious irrigation and bringing the tip of the drill back and forward to avoid overheating. Bone density was assessed during the drilling phase by clinician experience and tactile perception based on the Lekholm and Zarb classification (Lekholm & Zarb, 1985). In healed and post-extractive sites, the drilling protocol recommended by the manufacturer was customized according to the bone density and the amount of native bone to be engaged in case of post-extractive sites. The implant site width was underprepared to obtain adequate primary stability for the immediate loading and an insertion torque of at least 45 Ncm.

-Maxillary healed sites: For the narrow platform (NP) implants, the first drill (twist drill, 2.0 mm) was used to the planned depth and the last drill (step drill, 2.4–2.8) was used to half of its working length. For the regular platform (RP), the first drill (twist drill, 2.0 mm) and the intermediate drills (step drill, 2.4–2.8 and 2.8–3.2) were used to the planned depth, while the last one (step drill, 3.2–3.6) was used to half of its working length.

-Mandibular healed sites: For the NP and RP implants, the recipient site was prepared for the entire planned depth following the



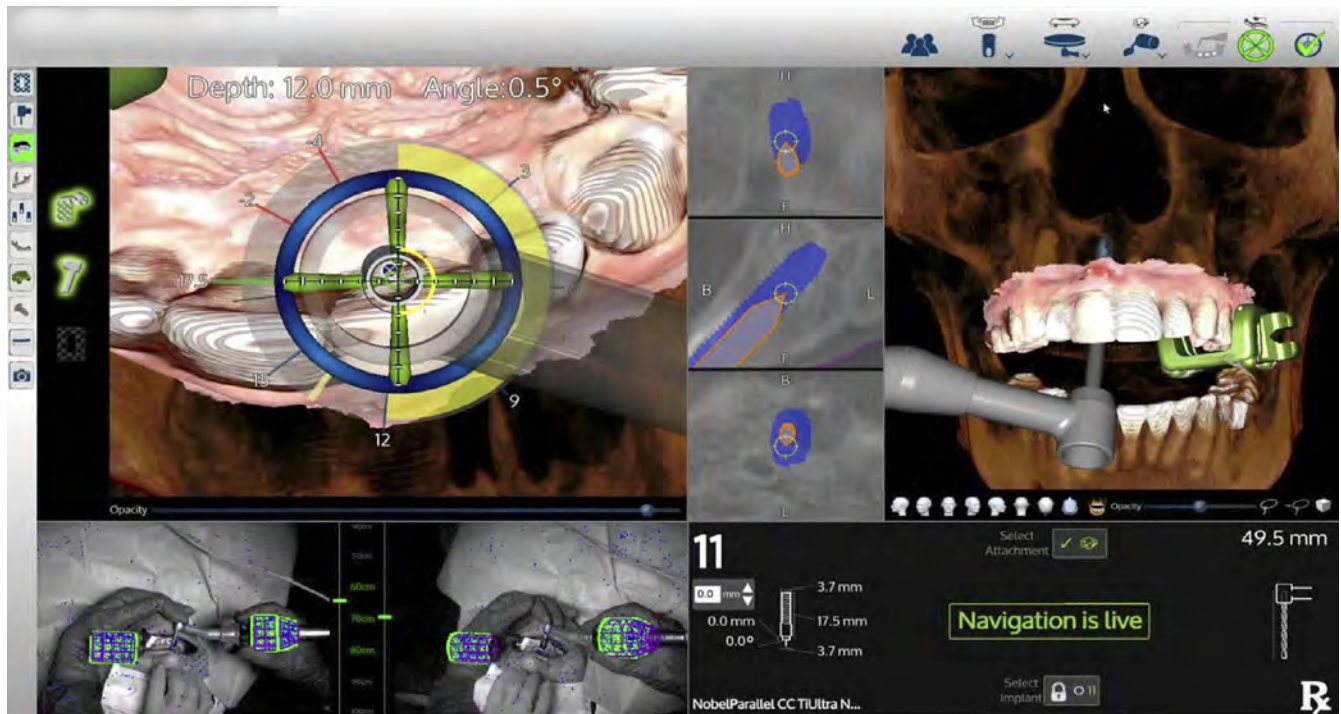
**FIGURE 2** Preoperative view of the failed porcelain fused to metal FDP on the right central incisor with gingival recession and fistula



**FIGURE 3** Preoperative periapical X-ray: failed porcelain fused to metal FDP with periapical radiolucency

drilling protocol recommended by the manufacturer. Countersinking and screw tapping were performed when needed to engage as much cortical bone as possible.

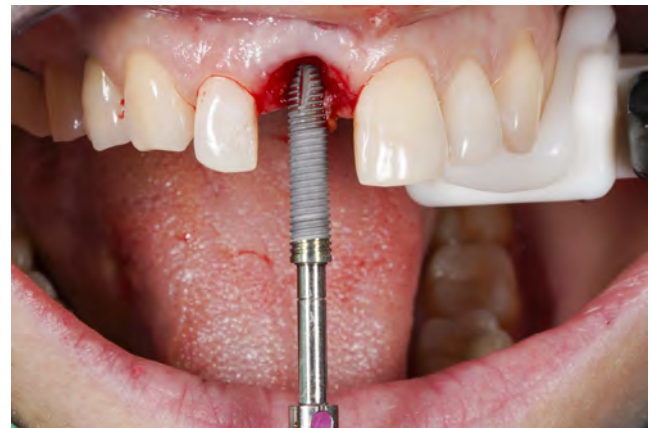-Post-extractive sites: Atraumatic tooth extraction was performed to preserve the remaining alveolar bone and surrounding tissues. The residual extraction sockets were debrided thoroughly of granulation tissue and residual periodontal ligament fibers with curettes. To gain a maximal degree of stability, the implants were planned at least 5 mm beyond the root apex in the maxilla and 4 mm in the mandible, and the implant platform was positioned at least 1.5 mm below the buccal wall margin. The last drill recommended by the manufacturer was not used to underprepare the recipient site width. No countersinking and screw tapping were performed (Pozzi et al., 2015). The implant platform was positioned between 0.5 and 2 mm below the bone crest level according to a prosthetically driven decision making (Pozzi & Mura, 2014). The insertion



**FIGURE 4** Navigation system screen during the dynamically guided implant drilling and positioning. The blue track indicated the implant trajectory planned in the software. The window on the right showed the 3D interplay between the surgical handpiece and the rendering of the patient anatomy. The window on the left showed the 360° control on the implant trajectory and depth



**FIGURE 5** Calibration of implant length on the calibration plate



**FIGURE 6** Dynamically guided implant positioning. On the left side, the clip with the fiducial landmarks properly secured to the tooth surface

torque was recorded using a surgical unit (OsseoCare Pro Drill Motor Set, Nobel Biocare), and ISQ was recorded using a patented technology based on a Resonance Frequency Analysis (RFA) that measures the frequency with which a device screwed into the implant vibrates (Osstell, W&H). In immediate post-extractive sites, xenogeneic adsorbable bone substitute material (Bio-Oss, Geistlich Pharma, Wolhusen, Switzerland) was placed in the gap between the implant and the bony socket to compensate for the horizontal and vertical ridge alterations after tooth extraction (Fickl et al., 2008) (Figures 2-6). Moreover, xenogeneic adsorbable collagen matrix (Fibrogide, Geistlich Pharma) was positioned

at the transmucosal portion of the temporary restoration after creating a hole in the matrix, in order to fill the volume in between the intaglio surface of the gingival tissue and the restorative interface.

## 2.5 | Prosthetic protocol

The virtual articulator embedded in the restorative software is effective for designing a “non-occluding” single FDP, eliminating

any static and/or dynamic contacts (Pozzi et al., 2018b). A five-axis milling machine (DWX-51D, Roland DG) fabricates the temporary shell from a multilayered polymethyl methacrylate (PMMA) (Whitepeaks, Whitepeaks Dental Solutions GmbH & Co) CAD/CAM material to confer the provisional restoration with a natural aesthetic appearance. The digitally designed temporary shell with proximal wings was relined onto the temporary abutment (Temporary Snap Abutment, Nobel Biocare AG) using an autopolymerizing polyurethane resin (ProTemp4, 3 M ESPE) (Pozzi et al., 2018a). The emergence profile of the provisional restoration is adapted by trimming the resin remnants, polishing the surface, and, lastly, removing the proximal wings used to index the restoration. The infraocclusion of the temporary crown was verified by means of 200 microns articulating paper (Bausch Articulating Paper, Bausch, NH, USA) in centric relation and during the eccentric movements of the mandible. The screw-retained interim prosthesis was secured to the implant with a dedicated manual torque wrench at 25 Ncm (Table 1) (Figure 7). Patients were instructed to eat a soft diet and to wear a night-guard during the first 4 weeks for the mandibular implants and 6 weeks for the maxillary implants. Depending on the surgical site characteristics, the healing period ranged from 1 to 2 months and 2 to 3 months in the mandible and in the maxilla, respectively. Thereafter, the provisional restoration was removed, and the implant stability quotient was measured. In case of ISQ > 70, a IOS impression was taken using dedicated scan abutments (IBSs) (Elos Accurate Scan Body, Elos Medtech, Göteborg, Sweden) to record the implant coordinates. The impression file was shared to the dental laboratory to fabricate the definitive restorations. The screw-retained lithium disilicate fused to zirconia definitive restorations was digitally designed and delivered at the implant level. In case of a prosthetic correction of the implant axis, an angulated screw channel (ASC) technology was adopted to properly locate the screw channel on the lingual or occlusal site of the definitive restoration (Friberg & Ahmadzai, 2019). The final implant

crown was torque to 35 Ncm as recommended by the manufacturer, and the screw access channel was filled with a composite resin (Figures 8,9,10).

Follow-up visits were scheduled at 1, 2, and 4 months after implant insertion and up to 1 year after definitive prosthesis placement (Figures 11-13).

## 2.6 | Outcomes

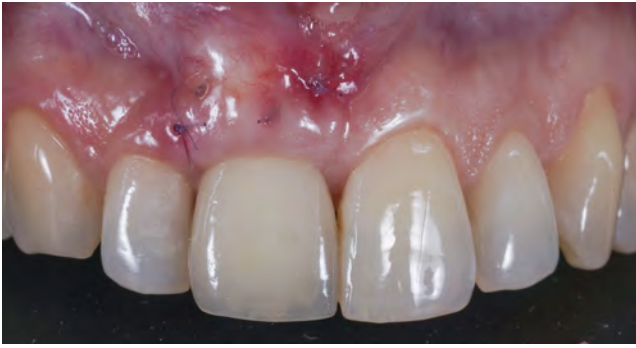An independent blinded assessor recorded all of the measurements and gathered the related data. Primary outcomes were implant and prosthetic success rates, surgical and prosthetic complications, marginal bone loss (MBL), final pink aesthetic score (PES-f), and implant stability quotient (ISQ-f). The implant success and survival criteria used in this study were modifications of criteria suggested by Van Steenberghe (1997). Complications were defined as any biological (pain, swelling, suppuration, etc.) and/or mechanical complications (fracture of the abutment and/or the veneering material, screw loosening or fracture, etc.).

Marginal bone levels were assessed using standardized intraoral digital periapical radiographs with the parallel technique by means of a periapical radiograph with a dedicated holder, at implant placement (baseline) and after 1 year from the definitive prosthesis delivery. These periapical X-rays were forwarded to an independent radiologist not informed on the aims of the study for evaluation. The periapical X-rays were loaded onto OsiriX MD 7.5 image diagnosis and analysis software package (Pixmeo SARL, Geneva, CH) on a Mac Pro Workstation (iOS 10.13.6) adjusting the density and contrast for optimal visibility of the crestal bone. For measurements, the images were magnified 15–20× and all distances taken in pixels. The mesio-distal width of the implant was measured by drawing a reference line from edge to edge along the implant-abutment junction (IAJ). The distance between the outer edge of the implant platform and the first bone-to-implant contact point was measured on both mesial and distal

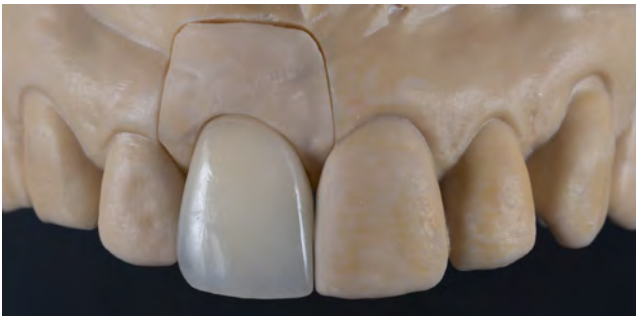Navigation-assisted immediate loading in one visit: radiological, digital, and clinical protocol	Mean time (minutes)
CBCT (smiling scan technique) including the smart-clip preparation	10
IOS scanning	5.5
Generate virtual patient and digitally assisted implant planning	6.5
<sup>a</sup> Export implant planning file to the dedicated prosthetic software to design and mill the temporary shell interim restoration	<sup>a</sup> 40 (overall production time by five-axis milling machine)
<sup>a</sup> Export implant planning file to the navigation surgical system, calibration, and dynamic guided surgery	<sup>a</sup> 25
Immediate adaptation and refinement of temporary shell interim restoration onto the prosthetic abutment, and final adjustment of occlusion.	20
Overall mean time of the procedure	82

TABLE 1 Timeline of the navigation-assisted immediate loading in 1 visit

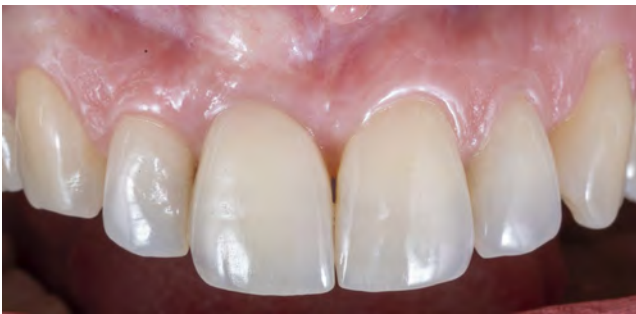<sup>a</sup>Simultaneously conducted.



**FIGURE 7** Postoperative view after the immediate implant positioning and loading in the post-extractive socket



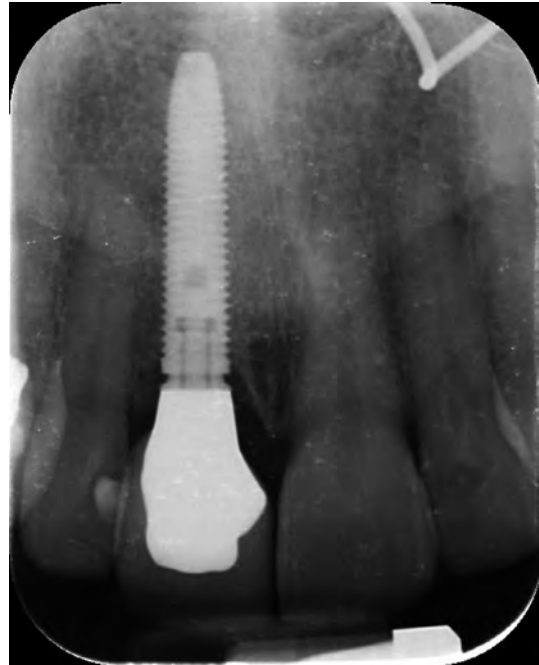**FIGURE 8** 3D printed master cast with removable gingival tissue and the definitive porcelain fused to zirconia crown



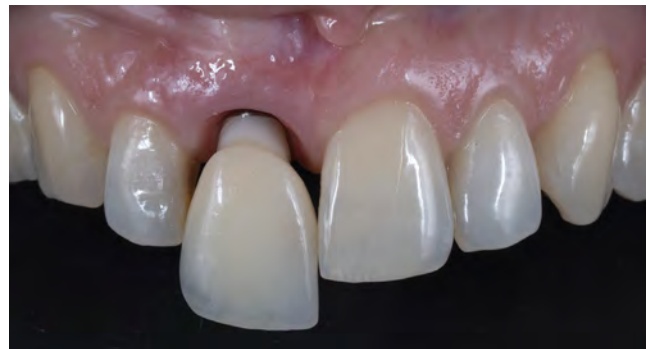**FIGURE 9** Postoperative view at the definitive crown delivery showed the progressive soft tissue maturation and PES improvement

surfaces of the implant. Either positive or negative measurement depends on whether the bone level was above/coronal or below/apical to the IAJ reference line, respectively. Using the correlation between the known (in mm) and measured (in pixels) width of the implant as a calibration reference, all pixel measurements were converted to mm. MBL was subsequently calculated for paired radiographs from baseline (the day of definitive prosthesis delivery) to last follow-up.

Implant stability at definitive impression (ISQ-f) was assessed through the RFA (ISQ values, range, 1 to 100) (Meredith et al., 1996). PES-f was assessed 1 year after definitive prosthesis placement by



**FIGURE 10** Periapical X-ray at the definitive crown delivery



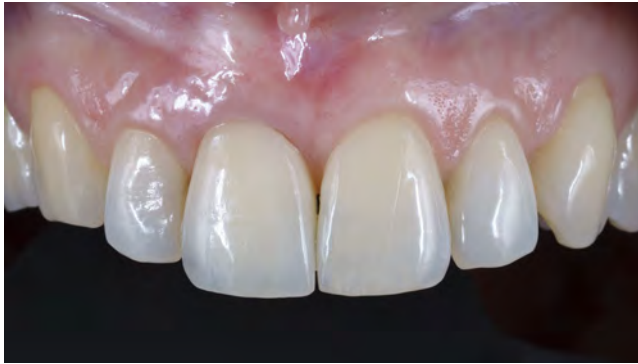**FIGURE 11** Postoperative view 1 year after the definitive crown delivery. The crown was unscrewed to assess the status of the mesial and distal papilla

an independent examiner evaluating seven variables: mesial papilla, distal papilla, soft tissue level, soft tissue contour, alveolar process deficiency, soft tissue color, and texture. Using a 0–1–2 scoring system, 0 being the lowest and 2 being the highest value, the maximum achievable PES was 14 (Fürhauser et al., 2005).

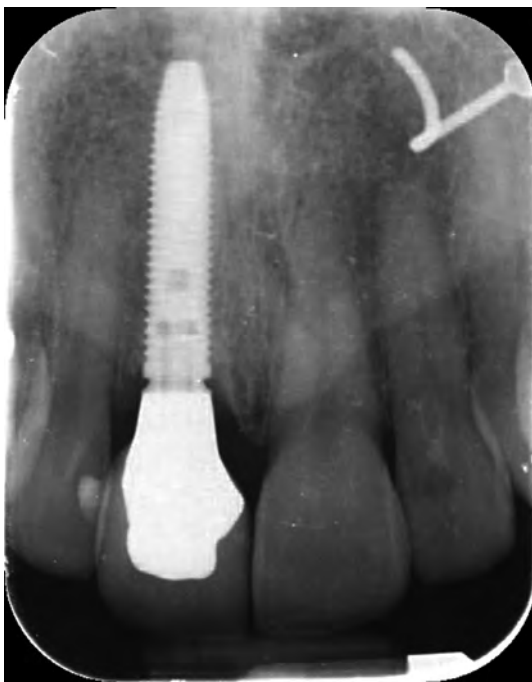As secondary outcomes, the following intermediate measures were obtained during follow-up: ISQ and PES at implant positioning (ISQ-0 and PES-0); and PES at definitive prosthesis placement (PES-p).

## 2.7 | Statistics

Considering marginal bone loss as primary outcome and assuming a standard deviation of 0.25, a sample size of 52 implants was



**FIGURE 12** Postoperative view 1 year after the definitive crown delivery, showing the further soft tissue maturation and PES improvement



**FIGURE 13** Periapical X-ray at the last follow-up 1 year after the definitive crown delivery

calculated to guarantee a standard error of 0.035 in estimating the expected bone loss. Note that, assuming an expected MBL of 1 mm as null hypothesis and a significance level of 0.05,  $n = 52$  guarantees, for a minimum expected difference of 0.10 mm (standard deviation 0.25), a test power of 0.90. Continuous variables were summarized by mean and standard deviation (SD), and categorical variables were described by absolute and relative frequencies. Histograms were utilized to describe empirical distributions of continuous variables; kernel density estimates and corresponding normal densities were overimposed. Box-and-whisker plots were created to graphically compare empirical distributions.

In multivariable analysis, a parametric approach was chosen based on the general linear model. Three different analysis of covariance models were fitted, considering MBL, ISQ-f, and PES-f as response variables.

In each model, jaw (maxilla vs mandible), biotype (thin vs thick), type of incision (flap vs flapless), implant site characteristics (healed vs post-extractive), and age were considered as potential risk factors.

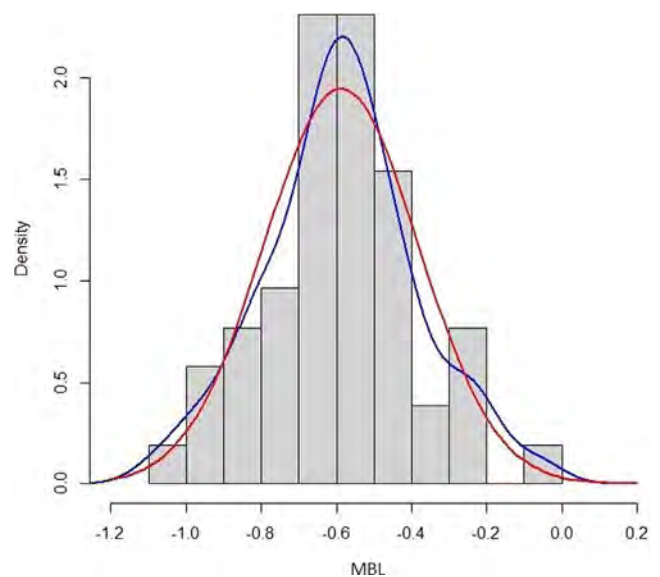
The method of least squares was used to fit each model to observed data. Parameter estimates and standard errors were reported, and t tests for the effect of explanatory variables were provided.

Studentized residuals from the fitted models were used to evaluate the assumption of normality.

All analyses were undertaken using SAS software version 9.4 (SAS Institute) and R version 3.4.

### 3 | RESULTS

Fifty-two patients (20 males and 32 females, mean age  $63 \pm 12$  years, 22–83) were treated and followed up for at least 1 year after the definitive prosthesis placement (mean 18.6 months, 15–20 months). No patient dropout occurred. One implant out of 52 failed before the definitive prosthesis delivery. The failed implant ( $3.75 \times 11.5$  mm, mandibular post-extractive site) was immediately replaced by a  $3.75 \times 13$  mm implant; therefore, the analysis was undertaken on 52 implants, while the success rate was calculated on 53 implants. All patients were treated according to the original protocol. No visible plaque was detected at 77.3% and 86.4% of implant sites at the 6-month and 1-year visits, respectively. No biological or mechanical complications occurred during the entire follow-up, accounting for a cumulative success rate (CSR) of 98.10%. Twenty-eight implants (53.8%) were placed in the maxilla (8 central incisors, 6 lateral incisors, 3 cuspids, and 11 premolars) and 24 in the mandible (46.2%) (11 incisors, 4 cuspids, and 9 premolars).



**FIGURE 14** MBL empirical distribution (blue line: kernel density estimate, red line: fitted normal density)



Thirty-one implants (59.6%) were placed in thin biotype sites while 21 (40.4%) in thick biotype sites. Thin biotype was observed mainly in women (90.3%), while thick was most common in men (81.0%). Thirty-four implants (65.4%) were positioned flapless and 18 with flap (34.6%). Twenty-seven implants (51.9%) were immediately placed in post-extractive sockets, while 25 (48.1%) implants were in healed sites. The mean insertion torque was  $60.7 \pm 6.2$  Ncm (46–70) and  $62.4 \pm 8.2$  Ncm (47–73) in the post-extractive and healed sites, respectively.

The cumulative mean MBL between implant placement and the last follow-up was  $-0.63 \pm 0.25$  mm ( $-1.69$  to  $-0.06$  mm). MBL distributions are reported in Figure 14. The mean MBL was  $-0.57 \pm 0.25$  and  $-0.59 \pm 0.13$  for post-extractive and healed sites, respectively.

The mean values of PES-O, PES-p, and PES-f means were  $8.22 \pm 1.19$ ,  $9.92 \pm 1.16$ , and  $12.34 \pm 1.41$ , respectively. The corresponding box-and-whisker plots are shown in Figure 15.

Implants were placed with a mean ISQ-O of  $72 \pm 2.86$  (66–78). ISQ-O mean was  $72 \pm 2.89$  for post-extractive implants and  $72 \pm 2.87$  for implants placed in healed sites. ISQ-f mean was  $78.1 \pm 3.2$  (70–84). ISQ-f distribution is reported in Figure 16.

At multivariable analysis, the potential effect of jaw (maxilla vs mandible), biotype (thin vs. thick), type of incision (flap vs. flapless) and implant site characteristics (healed vs. post-extractive) on the three primary outcomes (MBL, PES-f, and ISQ-f) was evaluated controlling for age. Sex was excluded from the fitted model because of its high correlation with both biotype and jaw. PES-f was  $12.34 \pm 1.41$  (9–14), ISQ-f was  $78.1 \pm 3.2$  (70–84). MBL and PES-f were significantly affected only by age ( $p = .0058$  and  $p = .0052$ , respectively). The expected MBL increased by 0.01 mm per year of age. The expected PES-f was reduced by 0.05 points per year of age. No other factors had a significant impact on the three primary outcomes. It is known that jaw effect was close to the significance level for the ISQ-f ( $p = .0584$ ): The expected ISQ-f was 2.05 higher in the mandible as compared to the maxilla. Results from the fitted models are reported in Tables 2, 3, and 4.

## 4 | DISCUSSION

The primary objective of this prospective single-cohort study was to report the clinical and radiological performance of a novel digital workflow, integrating dynamic navigation surgery and CAD/CAM technology. Because it was designed as a single-cohort study, the main limitation was the lack of a control group, which may have unidentified some differences limiting the generalization of the results. However, to the best of our knowledge, this is the first study investigating dynamic navigation surgery, to streamline in one visit the execution of single-implant immediate loading in the aesthetic zone.

Moreover, this investigation was designed as a pilot for future investigations evaluating the accuracy and multicenter randomized clinical trials (RCTs). Nevertheless, 52 patients were treated in accordance with principles of good clinical practice and documented by strict radiographic measurements with no protocol deviations.

Consequently, preliminary and generalizable conclusions could be drawn.

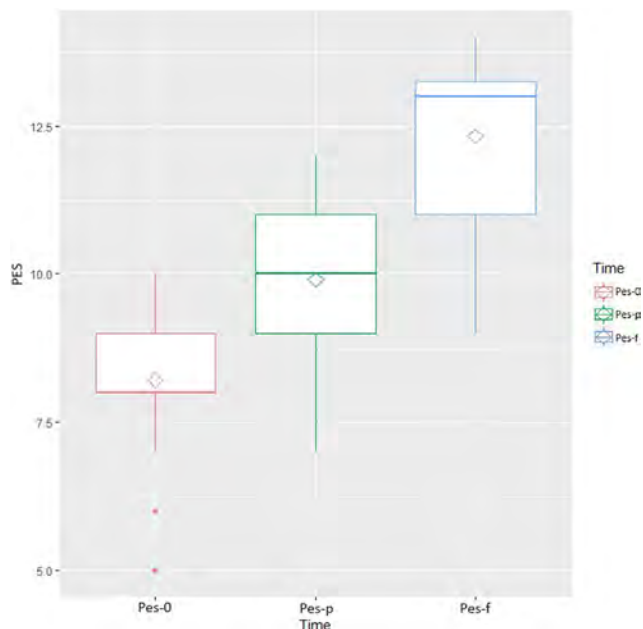
The null hypothesis that the investigated variables (jaw (maxilla vs mandible), biotype (thin vs thick), type of incision (flap vs flapless), and implant site (healed vs post-extractive)) would not affect MBL, PES-f, and ISQ-f was partially rejected. MBL was significantly affected by age: Estimated bone resorption is increasing by 0.01 mm per year of age. No significant effect was detected for jaw, biotype, incision, and implant site. PES-f was significantly affected by age: PES-f is reduced by 0.05 points per year of age. No significant effect was detected for jaw, biotype, incision and implant site. ISQ-f was not significantly affected by the analyzed variables; only for jaw, we observed a  $p$ -value at the border of significance.

One mandibular post-extractive implant failed before the definitive prosthesis delivery. The failed implant was immediately replaced and loaded, using the original dynamic navigation planning, a longer implant, and the same screw-retained temporary prosthesis. No other surgical or biological complications occurred, accounting for a CSR of 98.10%. No definitive prostheses failed. A recently published systematic review and meta-analysis reported a similar outcome for immediately loaded implants in the aesthetic zone at the 1-year follow-up (Cheng et al., 2020). Considering the benefits of shortened treatment time and meeting patients' expectations, immediate loading of single-tooth implants and full-arch restorations showed comparable survival rates, single-tooth implants were thought to have a higher risk of failure (Cheng et al., 2020). In the present study, 52 single-tooth-gap implants were treated with the investigated same-day workflow, and dynamically guided implant positioning did not produce any clinically relevant complication. All the prefabricated CAD/CAM temporary prostheses, designed according to the implant coordinates planned into the software, were delivered with minor adjustments of the contact points.

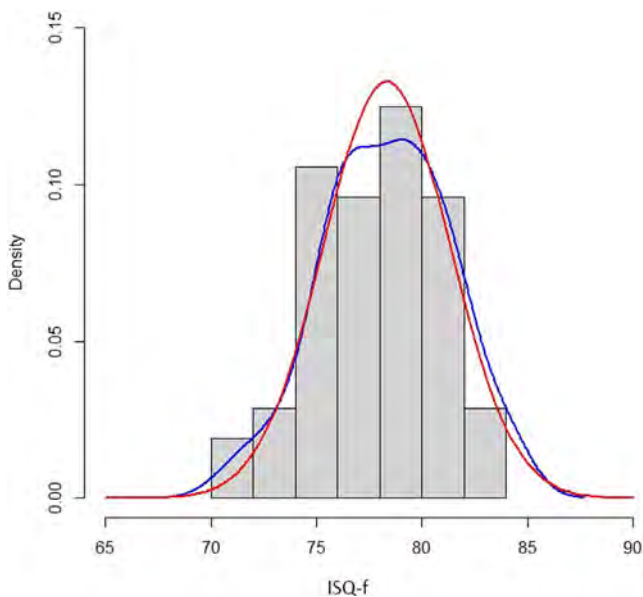
Several randomized clinical trials confirm that fully guided surgery offers the highest accuracy in transmission of the implant positioning from the pre-surgical planning to the patient (Aydemir & Arisan, 2019; Kaewsiri et al., 2019; Younes et al., 2018).

However, surgical CAD-CAM templates, covering the entire surgical field and limiting the visibility of soft tissue and bone anatomy during the bone drilling, do not allow to detect any deviations in the drilling trajectory or implant mispositioning unless the template is removed from the patient mouth.

A recently published prospective cohort study evaluating the accuracy of static guided surgery reported tooth-supported drill guides made in a digital workflow is a feasible treatment option. However, implants that were lacking a directly neighboring tooth or implant to support the drill guide, and implants placed distally to an edentulous site in a free-ending situation showed larger deviations at implant apices and entry points. Moreover, even though crowding did not influence the accuracy, in moderate and severe crowding cases, seating of the drill guides sometimes consumed more time. Due to the described inaccuracies, caution needs to be taken in cases with limited bone or challenging anatomical circumstances (Derksen et al., 2019). Other studies have moreover shown that drills



**FIGURE 15** PES-0, PES-p, and PES-f distribution (the bottom and top edges of the box are located at the 25th and 75th percentiles of the sample and, within the box, the median is displayed as a line and the mean as a diamond)



**FIGURE 16** ISQ-f empirical distribution (blue line: kernel density estimate, red line: fitted normal density)

and sleeves have a certain freedom in movement, which could easily lead to lateral deviations of the implants (Koop et al., 2013; Van Assche & Quirynen, 2010). In the navigation-guided surgery, a link between the preoperative planning coordinate system and surgical handpiece and patient tracking arrays was accurately tracked continuously by the overhead stereo cameras and the stereo tracking algorithm, determining a dynamic connection of the drill with the

patient's CBCT and IOS anatomy, the temporary prosthesis design, and the implant trajectory. Block and colleagues observed that the improved accuracy in terms of implant angulation is the prominent feature of using dynamic navigation when compared to semi-guided and freehand implant positioning (Block et al., 2017). Stefanelli and colleagues reported consistent deviations in two studies investigating dynamic navigation accuracy with two different calibration protocols and live tracking technologies (0.71 mm at entry point, 1 mm at apex and 2.26° of angular deviation) (Stefanelli et al., 2019) (0.67 mm at entry point, 0.9 mm at apex and 2.50° of angular deviation) (Stefanelli et al., 2020). Edelmann and colleagues experienced mean deviations of 1.83 mm at entry point, 1.95 mm at apex, and 2.7° of angular deviation with another navigation system (Edelmann et al., 2021). A recently published systematic review and meta-analysis on accuracy of surgery reported an average global platform deviation, global apex deviation, and angular deviation of 1.02 mm (95% CI 0.83–1.21), 1.33 mm (95% CI 0.98–1.67), and 3.59° (95% CI 2.09–5.09) and concluded it was clinically acceptable with potential in clinical usage (Wei et al., 2021).

Based on the reported outcomes, the major conclusion of this prospective study was that novel digital workflow integrating dynamic navigation surgery and CAD/CAM technology for immediate loading of single-tooth-gap implants in the aesthetic zone in one visit may be considered an effective and reliable treatment option.

The cumulative mean MBL between implant placement and the last follow-up was  $-0.63 \pm 0.25$  mm. This favorable bone resorption trend was in accordance with previously published studies assessing the radiological outcome of single implants in the aesthetic zone, immediate loading, and followed up to 1 year in both healed and post-extractive sites. Hall et al. (2007) and den Hartog et al. (2011), investigating immediately loaded implants positioned in the anterior zone in healed sites only, reported a cumulative MBL of  $-0.63 \pm 1.00$  mm and  $-0.91 \pm 0.61$  mm at 1 year of follow-up, respectively. In immediately loaded post-extractive implants, De Rouck et al (De Rouck et al., 2009) reported a cumulative MBL of  $-0.86 \pm 0.54$  mm after 1 year in function. In the present study, the authors did not evidence any statistically significant difference in MBL between healed and post-extractive sites. The mean MBL was  $-0.57 \pm 0.25$  and  $-0.59 \pm 0.13$  for post-extractive and healed sites, respectively. The immediate implant insertion and loading did not affect the peri-implant bone remodeling of the fresh extraction sockets within the investigated follow-up. Such outcomes agreed with previously published reviews stating that immediate placement and provisionalization of single implants in the anterior zone did not interfere with the peri-implant soft and hard tissues compared with the conventional loading (Cheng et al., 2020; Yan et al., 2016).

In the present study, no statistically significant difference in the MBL between healed and post-extractive sites ( $p = .7100$ ) was evidenced. Compared with the aforementioned studies, where all the implants were positioned with different freehand surgical approaches, in the current study all the patients were treated with a flapless or mini-flap procedure and with the dynamic guidance of the navigation system. Therefore, a less traumatic surgery and more

**TABLE 2** Results from the fitted analysis of covariance model considering MBL as response variable

	Estimate	Standard Error	t Value	p-value
Intercept	-0.15	0.15	-0.97	.3350
incision flapless vs. flap	-0.03	0.07	-0.47	.6388
Bone healed vs. post-extractive	-0.02	0.06	-0.37	.7100
Position mandible vs maxilla	0.09	0.07	1.28	.2070
Age	-0.01	0.00	-2.89	.0058*
Biotype thick vs. Thin	0.00	0.06	0.00	.9993

\* $p \leq .05$  indicates statistical significance.

**TABLE 3** Results from the fitted analysis of covariance model PES-f as response variable

	Estimate	Standard Error	t Value	p-value
Intercept	15.46	1.02	15.12	<.0001
Incision flapless vs. flap	-0.36	0.46	-0.80	.4280
Bone healed vs. Post-extractive	-0.35	0.40	-0.89	.3767
Position mandible vs maxilla	0.18	0.48	0.39	.6997
Age	-0.05	-0.02	-2.93	.0052*
Biotype thick vs. Thin	0.59	0.44	1.34	.1863

\* $p \leq .05$  indicates statistical significance.

**TABLE 4** Results from the fitted analysis of covariance model considering ISQ-f as response variable

	Estimate	Standard Error	t Value	p-value
Intercept	81.69	2.27	36.05	<.0001
incision flapless vs. flap	-0.30	1.01	-0.29	.7710
bone healed vs. post-extractive	0.04	0.88	0.04	.9670
Position mandible vs maxilla	2.05	1.05	1.94	.0584
Age	-0.06	0.04	-1.60	.1169
Biotype thick vs. thin	-1.01	0.98	-1.03	.3062

accurate implant positioning compared with the conventional free-hand approach (Aydemir & Arisan, 2019) may have positively influenced the bone remodeling pattern.

Moreover, the overall low-invasive navigation-guided protocol may be directly connected to the favorable soft tissue and aesthetic outcomes (PES-f  $12.34 \pm 1.41$ ), in agreement with similar results reported in the literatures using static template-assisted guided surgery (Fürhauser et al., 2014) and freehand conventional approach (Sun et al., 2020). However, Fürhauser included only healed sites treated with a flapless approach, highlighting indirectly the difficulties to properly manage the surgical incision when a CAD/CAM template is secured on the patient dentition. The dynamic virtual guidance provided by the navigation system provided the authors with the proper freedom to optimize the soft tissue approach without any limitation related to the use of a physical template, hiding the surgical field. Moreover, the simultaneous live tracking system allowed to adjust the drilling in case any type of events may occur during the surgery, particularly during the treatment of the post-extractive sockets, in order to find out the primary stability needed by the immediate loading. The mean PES values (PES-O, PES-p and

PES-f) demonstrated an increasing positive trend along the investigated follow-up, confirming a previously published evidence on the positive influence of immediate loading on the aesthetic outcome (Kan et al., 2018).

The investigated protocol was indicated when patients desire to shorten the overall treatment time and being rehabilitated immediately or in case of an emergency due to a failing tooth. However, integrating dynamic navigation surgery and CAD/CAM technology for immediate implant placement and loading, in both fresh extractive and healed sites, has to be considered technically demanding and the surgical and prosthetic skills needed are superior to those necessary for conventional implant treatment. Moreover, proper patient selection and well-trained operators are needed to minimize the risk of implant failure.

## 5 | CONCLUSIONS

Within study limitations, the investigated novel digital workflow integrating dynamic navigation seems to be effective to streamline in

one-visit single-implant immediate loading in aesthetic zone. Good treatment outcomes with regard to implant and prosthetic success, MBL changes and soft tissue conditions were experienced. No statistically significant differences were found for MBL, PES-f, and ISQ-f, considering type of incision (flap vs flapless), implant site (healed vs post-extractive), jaw (maxilla vs mandible), and biotype (thick vs thin). Live-tracked low-speed drilling dynamic guidance may have contributed to improve the clinical performance of the operator regardless of implant site characteristics. Further investigations are required to confirm such favorable outcomes.

#### ACKNOWLEDGMENTS

This study was supported by the X-Nav Technologies, LLC, Lansdale, PA, USA. The authors acknowledge MIUR Excellence Department Project awarded to the Department of Mathematics, University of Rome Tor Vergata, and Moretti Paglia Dental Laboratory, Rome, Italy.

#### CONFLICT OF INTEREST

The authors have stated explicitly that there are no conflicts of interest to disclose in connection with this article.

#### AUTHOR CONTRIBUTION

**Alessandro Pozzi:** Conceptualization (lead); Data curation (lead); Formal analysis (lead); Funding acquisition (equal); Investigation (lead); Methodology (lead); Project administration (equal); Resources (equal); Software (lead); Supervision (lead); Validation (lead); Visualization (equal); Writing-original draft (lead); Writing-review & editing (lead). **Lorenzo Arcuri:** Conceptualization (equal); Data curation (equal); Formal analysis (equal); Funding acquisition (equal); Investigation (equal); Methodology (equal); Project administration (equal); Resources (equal); Software (equal); Supervision (equal); Validation (equal); Visualization (equal); Writing-original draft (equal); Writing-review & editing (equal). **Paolo Carosi:** Conceptualization (equal); Data curation (lead); Formal analysis (equal); Funding acquisition (equal); Investigation (equal); Methodology (lead); Project administration (equal); Resources (equal); Software (lead); Supervision (lead); Validation (lead); Visualization (equal); Writing-original draft (lead); Writing-review & editing (lead). **Alessandra Nardi:** Conceptualization (equal); Data curation (lead); Formal analysis (lead); Funding acquisition (equal); Investigation (equal); Methodology (lead); Project administration (equal); Resources (equal); Software (equal); Supervision (equal); Validation (equal); Visualization (equal); Writing-original draft (equal); Writing-review & editing (equal). **Joseph Kan:** Conceptualization (lead); Data curation (equal); Formal analysis (equal); Funding acquisition (equal); Investigation (lead); Methodology (equal); Project administration (equal); Resources (equal); Software (equal); Supervision (equal); Validation (equal); Visualization (equal); Writing-original draft (lead); Writing-review & editing (equal).

#### ETHICAL APPROVAL

The study was approved by the Ethics Committee of University of Rome Tor Vergata (protocol number 202/20).

#### PATIENT CONSENT

All involved participants gave their informed consent prior to study inclusion.

#### PERMISSION TO REPRODUCE MATERIAL FROM OTHER SOURCES

No permission to reproduce material from other sources was needed. Clinical trial registration: University of Rome Tor Vergata Clinical Trial protocol number 202/20. After signature of the informed consent, patients were enrolled since December 2016 and thereafter consecutively treated in one rehabilitation center between May and September 2017. According to the university institution regulations on the Clinical Trials, study data are in the University repository and not publicly available to avoid compromising ethical standards and legal requirements. However, study data may be available on request from the corresponding author in respect of privacy and ethical restrictions. Peer review of empirical data was conducted by an independent examiner—member of the Ethical and Scientific Committee of University of Rome Tor Vergata to confirm the quality of the shared data, and to confirm the data reproduce the analytic results reported in the paper: (1) sample sizes match, (2) the variables described in the article are present as fields in the data university repository, (3) data are complete; (4) data are properly labeled and described; and 5) it has the appropriate metadata for the kind of data being shared.

#### DATA AVAILABILITY STATEMENT

According to the university institution regulations on the Clinical Trials, study data are in the university repository and not publicly available to avoid compromising ethical standards and legal requirements. However, study data may be available on request from the corresponding author in respect of privacy and ethical restrictions.

#### ORCID

Alessandro Pozzi  <https://orcid.org/0000-0002-3052-8186>

Paolo Carosi  <https://orcid.org/0000-0002-2442-1091>

#### REFERENCES

- Aydemir, C. A., & Arisan, V. (2019). Accuracy of dental implant placement via dynamic navigation or the freehand method: A split-mouth randomized controlled clinical trial. *Clinical Oral Implants Research*, 20, 9–26. <https://doi.org/10.1111/clr.13563>
- Belser, U., Buser, D., & Higginbottom, F. (2004). Consensus statements and recommended clinical procedures regarding esthetics in implant dentistry. *International Journal of Oral & Maxillofacial Implants*, 19, 73–74.
- Block, M. S., & Emery, R. W. (2016). Static or dynamic navigation for implant placement—choosing the method of guidance. *Journal of Oral and Maxillofacial Surgery*, 74(2), 269–277. <https://doi.org/10.1016/j.joms.2015.09.022>
- Block, M., Emery, R., Lank, K., & Ryan, J. (2017). Implant placement accuracy using dynamic navigation. *The International Journal of Oral & Maxillofacial Implants*, 32(1), 92–99. <https://doi.org/10.11607/jomi.5004>
- Cheng, Q., Su, Y.-Y., Wang, X., & Chen, S. (2020). Clinical outcomes following immediate loading of single-tooth implants in the esthetic

- zone: A systematic review and meta-analysis. *The International Journal of Oral & Maxillofacial Implants*, 35(1), 167–177. <https://doi.org/10.11607/jomi.7548>
- De Rouck, T., Collys, K., Wyn, I., & Cosyn, J. (2009). Instant provisionalization of immediate single-tooth implants is essential to optimize esthetic treatment outcome. *Clinical Oral Implants Research*, 20(6), 566–570. <https://doi.org/10.1111/j.1600-0501.2008.01674.x>
- den Hartog, L., Raghoobar, G. M., Stellingsma, K., Vissink, A., & Meijer, H. J. A. (2011). Immediate non-occlusal loading of single implants in the aesthetic zone: A randomized clinical trial. *Journal of Clinical Periodontology*, 38(2), 186–194. <https://doi.org/10.1111/j.1600-051X.2010.01650.x>
- Derksen, W., Wismeijer, D., Flügge, T., Hassan, B., & Tahmaseb, A. (2019). The accuracy of computer-guided implant surgery with tooth-supported, digitally designed drill guides based on CBCT and intraoral scanning. A prospective cohort study. *Clinical Oral Implants Research*, 30(10), 1005–1015. <https://doi.org/10.1111/clr.13514>
- Edelmann, C., Wetzels, M., Knipper, A., Luthardt, R. G., & Schnutenhaus, S. (2021). Accuracy of computer-assisted dynamic navigation in implant placement with a fully digital approach: A prospective clinical trial. *Journal of Clinical Medicine*, 10(9), 1808. <https://doi.org/10.3390/jcm10091808>
- Fickel, S., Zühr, O., Wachtel, H., Stappert, C. F., Stein, J. M., & Hürzeler, M. B. (2008). Dimensional changes of the alveolar ridge contour after different socket preservation techniques. *Journal of Clinical Periodontology*, 35(10), 906–913. <https://doi.org/10.1111/j.1600-051X.2008.01305.x>
- Friberg, B., & Ahmadzai, M. (2019). A prospective study on single tooth reconstructions using parallel walled implants with internal connection (NobelParallel CC) and abutments with angulated screw channels (ASC). *Clinical Implant Dentistry and Related Research*, 21(2), 226–231. <https://doi.org/10.1111/cid.12709>
- Fügl, A., Zechner, W., Pozzi, A., Heydecke, G., Mirzakhani, C., Behneke, N., Behneke, A., Baer, R. A., Nölken, R., Gottesman, E., & Colic, S. (2016). An open prospective single cohort multicenter study evaluating the novel, tapered, conical connection implants supporting single crowns in the anterior and premolar maxilla: interim 1-year results. *Clinical Oral Investigations*, 21(6), 2133–2142. <https://doi.org/10.1007/s00784-016-2003-0>
- Fürhauser, R., Florescu, D., Benesch, T., Haas, R., Mailath, G., & Watzek, G. (2005). Evaluation of soft tissue around single-tooth implant crowns: The pink esthetic score. *Clinical Oral Implants Research*, 16(6), 639–644. <https://doi.org/10.1111/j.1600-0501.2005.01193.x>
- Fürhauser, R., Mailath-Pokorny, G., Haas, R., Busenlechner, D., Watzek, G., & Pommer, B. (2014). Esthetics of flapless single-tooth implants in the anterior maxilla using guided surgery: Association of three-dimensional accuracy and pink esthetic score. *Clinical Implant Dentistry and Related Research*, 17(Suppl), e427–e433. <https://doi.org/10.1111/cid.12264>
- Hall, J. A. G., Payne, A. G. T., Purton, D. G., Torr, B., Duncan, W. J., & De Silva, R. K. (2007). Immediately restored, single-tapered implants in the anterior maxilla: prosthodontic and aesthetic outcomes after 1 year. *Clinical Implant Dentistry and Related Research*, 9(1), 34–45. <https://doi.org/10.1111/j.1708-8208.2007.00029.x>
- Jayarathne, Y. S. N., Zwahlen, R. A., Lo, J., Tam, S. C., & Cheung, L. K. (2010). Computer-aided maxillofacial surgery: An update. *Surgical Innovation*, 17(3), 217–225. <https://doi.org/10.1177/1553350610371626>
- Jivraj, S., & Chee, W. (2006). Treatment planning of implants in the aesthetic zone. *British Dental Journal*, 201(2), 77–89. <https://doi.org/10.1038/sj.bdj.4813820>
- Joda, T., Brägger, U., & Gallucci, G. (2015). Systematic literature review of digital three-dimensional superimposition techniques to create virtual dental patients. *The International Journal of Oral & Maxillofacial Implants*, 30(2), 330–337. <https://doi.org/10.11607/jomi.3852>
- Joda, T., & Gallucci, G. O. (2015). The virtual patient in dental medicine. *Clinical Oral Implants Research*, 26(6), 725–726. <https://doi.org/10.1111/clr.12379>
- Johansson, A., Omar, R., & Carlsson, G. E. (2011). Bruxism and prosthetic treatment: A critical review. *Journal of Prosthodontic Research*, 55(3), 127–136. <https://doi.org/10.1016/j.jpor.2011.02.004>
- Kaewsiri, D., Panmekiate, S., Subbalekha, K., Mattheos, N., & Pimkhaokham, A. (2019). The accuracy of static vs. dynamic computer-assisted implant surgery in single tooth space: A randomized controlled trial. *Clinical Oral Implants Research*, 28(9), 1089–1133. <https://doi.org/10.1111/clr.13435>
- Kan, J., Rungcharassaeng, K., Deflorian, M., Weinstein, T., Wang, H. L., & Testori, T. (2018). Immediate implant placement and provisionalization of maxillary anterior single implants. *Periodontology 2000*, 77(1), 197–212. <https://doi.org/10.1111/prd.12212>
- Koop, R., Vercruyssen, M., Vermeulen, K., & Quirynen, M. (2013). Tolerance within the sleeve inserts of different surgical guides for guided implant surgery. *Clinical Oral Implants Research*, 24, 630–634. <https://doi.org/10.1111/j.1600-0501.2012.02436.x>
- Lekholm, U., & Zarb, G. A. (1985). Patient selection and Preparation. In P. I. Branemark (Ed.), *Tissue integrated prostheses: osseointegration in clinical dentistry* (pp. 199–209). Quintessence Publishing Co.
- Luebbers, H.-T., Messmer, P., Obwegeser, J. A., Zwahlen, R. A., Kikinis, R., Graetz, K. W., & Matthews, F. (2008). Comparison of different registration methods for surgical navigation in cranio-maxillofacial surgery. *Journal of Cranio-Maxillofacial Surgery*, 36(2), 109–116. <https://doi.org/10.1016/j.jcms.2007.09.002>
- Meredith, N., Alleyne, D., & Cawley, P. (1996). Quantitative determination of the stability of the implant-tissue interface using resonance frequency analysis. *Clinical Oral Implants Research*, 7(3), 261–267. <https://doi.org/10.1034/j.1600-0501.1996.070308.x>
- Pozzi, A., Arcuri, L., & Moy, P. K. (2018a). Temporary shell proof-of-concept technique: digital-assisted workflow to enable customized immediate function in two visits in partially edentulous patients. *Compendium of Continuing Education in Dentistry (Jamesburg, N.J. : 1995)*, 39(3), e9–e12.
- Pozzi, A., Arcuri, L., & Moy, P. K. (2018b). The smiling scan technique: Facially driven guided surgery and prosthetics. *Journal of Prosthodontic Research*, 62(4), 514–517. <https://doi.org/10.1016/j.jpor.2018.03.004>
- Pozzi, A., Arcuri, L., S. Block, M., & K. Moy, P. (2020). Digital assisted soft tissue sculpturing (DASS) technique for immediate loading pink free complete arch implant prosthesis. *Journal of Prosthodontic Research*, 65(1), 119–124. [https://doi.org/10.2186/jpr.JPOR\\_2019\\_386](https://doi.org/10.2186/jpr.JPOR_2019_386)
- Pozzi, A., & Mura, P. (2014). Clinical and radiologic experience with moderately rough oxidized titanium implants: up to 10 years of retrospective follow-up. *The International Journal of Oral & Maxillofacial Implants*, 29(1), 152–161. <https://doi.org/10.11607/jomi.3306>
- Pozzi, A., Polizzi, G., & Moy, P. K. (2016). Guided surgery with tooth-supported templates for single missing teeth: A critical review. *European Journal of Oral Implantology*, 9(Suppl. 1), S135–S153.
- Pozzi, A., Tallarico, M., & Moy, P. K. (2015). Immediate loading with a novel implant featured by variable-threaded geometry, internal conical connection and platform shifting three-year results from a prospective cohort study. *European Journal of Oral Implantology*, 8(1), 51–63.
- Rosenfeld, A. L., Mandelaris, G. A., & Tardieu, P. B. (2006). Prosthetically directed implant placement using computer software to ensure precise placement and predictable prosthetic outcomes. Part 1: diagnostics, imaging, and collaborative accountability. *The International Journal of Periodontics & Restorative Dentistry*, 26(3), 215–221.
- Sennerby, L., Andersson, P., Pagliani, L., Giani, C., Moretti, G., Molinari, M., & Motroni, A. (2015). Evaluation of a novel cone beam computed tomography scanner for bone density examinations in pre-operative 3D Reconstructions and correlation with primary implant

- stability. *Clinical Implant Dentistry and Related Research*, 17(5), 844–853. <https://doi.org/10.1111/cid.12193>
- Stefanelli, L. V., DeGroot, B. S., Lipton, D. I., & Mandelaris, G. A. (2019). Accuracy of a dynamic dental implant navigation system in a private practice. *The International Journal of Oral & Maxillofacial Implants*, 34(1), 205–213. <https://doi.org/10.11607/jomi.6966>
- Stefanelli, L. V., Mandelaris, G. A., DeGroot, B. S., Gambarini, G., De Angelis, F., & Di Carlo, S. (2020). Accuracy of a novel trace-registration method for dynamic navigation surgery. *The International Journal of Periodontics & Restorative Dentistry*, 40(3), 427–435. <https://doi.org/10.11607/prd.4420>
- Sun, C., Zhao, J., Liu, Z., Tan, L., Huang, Y., Zhao, L., & Tao, H. (2020). Comparing conventional flap-less immediate implantation and socket-shield technique for esthetic and clinical outcomes: A randomized clinical study. *Clinical Oral Implants Research*, 31(2), 181–191. <https://doi.org/10.1111/clr.13554>
- Van Assche, N., & Quirynen, M. (2010). Tolerance within a surgical guide. *Clinical Oral Implants Research*, 21, 455–458. <https://doi.org/10.1111/j.1600-0501.2009.01836.x>
- van Steenberghe, D. (1997). Outcomes and their measurement in clinical trials of endosseous oral implants. *Annals of Periodontology*, 2(1), 291–298. <https://doi.org/10.1902/annals.1997.2.1.291>
- van Steenberghe, D., Glauser, R., Blombäck, U., Andersson, M., Schutyser, F., Pettersson, A., & Wendelhag, I. (2005). A computed tomographic scan-derived customized surgical template and fixed prosthesis for flapless surgery and immediate loading of implants in fully edentulous maxillae: a prospective multicenter study. *Clinical Implant Dentistry and Related Research*, 7(Suppl. 1), S111–S120. <https://doi.org/10.1111/j.1708-8208.2005.tb00083.x>
- Verstreken, K., Van Cleynenbreugel, J., Marchal, G., Naert, I., Suetens, P., & van Steenberghe, D. (1996). Computer-assisted planning of oral implant surgery: a three-dimensional approach. *The International Journal of Oral & Maxillofacial Implants*, 11(6), 806–810.
- von Elm, E., Altman, D. G., Egger, M., Pocock, S. J., Gøtzsche, P. C., Vandenbroucke, J. P., & Initiative, S. T. R. O. B. E. (2014). The Strengthening the Reporting of Observational Studies in Epidemiology (STROBE) Statement: guidelines for reporting observational studies. *International Journal of Surgery (London, England)*, 12(12), 1495–1499. <https://doi.org/10.1016/j.ijssu.2014.07.013>
- Wei, S.-M., Zhu, Y., Wei, J.-X., Zhang, C.-N., Shi, J.-Y., & Lai, H.-C. (2021). Accuracy of dynamic navigation in implant surgery: A systematic review and meta-analysis. *Clinical Oral Implants Research*, 32(4), 383–393. <https://doi.org/10.1111/clr.13719>
- Yan, Q., Xiao, L.-Q., Su, M.-Y., Mei, Y., & Shi, B. (2016). Soft and hard tissue changes following immediate placement or immediate restoration of single-tooth implants in the esthetic zone: A systematic review and meta-analysis. *The International Journal of Oral & Maxillofacial Implants*, 31(6), 1327–1340. <https://doi.org/10.11607/jomi.4668>
- Younes, F., Cosyn, J., De Bruyckere, T., Cleymaet, R., Bouckaert, E., & Eghbali, A. (2018). A randomized controlled study on the accuracy of free-handed, pilot-drill guided and fully guided implant surgery in partially edentulous patients. *Journal of Clinical Periodontology*, 45(6), 721–732. <https://doi.org/10.1111/jcpe.12897>

## SUPPORTING INFORMATION

Additional supporting information may be found online in the Supporting Information section.

**How to cite this article:** Pozzi, A., Arcuri, L., Carosi, P., Nardi, A., & Kan, J. (2021). Clinical and radiological outcomes of novel digital workflow and dynamic navigation for single-implant immediate loading in aesthetic zone: 1-year prospective case series. *Clinical Oral Implants Research*, 32, 1397–1410. <https://doi.org/10.1111/clr.13839>