

Biallelic *CLPB* mutation associated with isolated neutropenia and 3-MGA-uria

Severe congenital neutropenia (SCN) is a heterogeneous group of inborn errors of immunity-related to impaired differentiation of neutrophilic granulocytes precursors. Since the original description of exclusively hematologic conditions (*HAX1* and *ELANE*), mutations in several additional genes responsible for hematopoietic multilineage differentiation disorders (*GATA2* or *CXCR4*), extra-hematopoietic manifestations, and syndromic conditions (*G6PC3* or *SBDS*) have been associated with SCN. Subsequently, neutropenia has also been observed in metabolic diseases such as glycogen storage diseases (*SLC37A4*), methylmalonic aciduria (*TCN2*), and 3-methylglutaconic acidurias (*TAZ*, *CLPB*).¹

3-methylglutaconic acidurias (3-MGA-urias) comprise a variety of inborn errors of metabolism associated with increased urinary excretion of 3-methylglutaconic acid as a discriminative feature. Clinically these disorders are usually associated with a variable degree of severe neurological impairment, cardiomyopathy, myopathy, liver and kidney dysfunctions, optic atrophy and cataracts, deafness, congenital neutropenia, and endocrine dysfunctions.

In 2015, thanks to the implementation of genome sequencing technology, loss-of-function mutations in *CLPB*, a gene encoding for the caseinolytic peptidase B homolog, were identified in children with a severe phenotype characterized by 3-MGA-uria, neurological involvement, neutropenia, cataracts, and early death.²⁻⁵ Subsequently, one study has broadened the phenotypic variability including patients with a mild clinical presentation characterized by cataract, renal cysts, and nephrocalcinosis, but with the absence of neurological signs.⁶ Moreover, monoallelic *CLPB* variants have recently been associated with variable clinical presentations ranging from moderate/severe/cyclic neutropenia, developmental delay/seizure and 3-MGA-uria, to neutropenia without 3-MGA-urias, uncommon cataracts, and neurologic involvement⁷⁻⁹ (Table S1).

The *CLPB* gene encodes a heat shock protein/chaperonin responsible for disaggregating mitochondrial and cytosolic proteins. It has been demonstrated that mutations in this gene impair its role as a disaggregase and that mutations resulting in its instability or inactivity lead to the accumulation of protein aggregates following cellular stresses impairing maintenance of the functional milieu of the mitochondrial membrane.⁶ Moreover, *CLPB* protein interacts and permits the solubility of *HAX1* a protein involved in Kostmann syndrome characterized by severe neutropenia and neurological disease.¹⁰

Here, we report the case of a 5-year-old girl with isolated neutropenia, 3-MGA-uria, and normal neurologic development in which we found three heterozygous mutations in the *CLPB* gene. Patient's parents provided written informed consent for the publication of this case report.

The patient, born from healthy, non-consanguineous parents, was admitted to our hospital for persistent neutropenia at 2.5 years of age. She was born by cesarean section because of oligohydramnios and PROM (prolonged rupture of membranes) at 32 weeks of gestation. At birth, she received nasal-CPAP, calcium/bicarbonate correction for a mild metabolic acidemia, and antibiotic therapy for increase of C-reactive protein (CRP) (no data on neutrophil count are available at birth). She showed normal growth and development. At 1 year of age, she was evaluated for respiratory distress and fever, laboratory tests demonstrated a severe neutropenia (200/mm³) and mild elevation of CRP (2.2 mg/dl). Throat culture resulted positive for *Haemophilus influenzae* and *E. coli*. Chest XR suggested bronchitis resolved after oral antibiotic therapy.

Persistent severe neutropenia was confirmed at subsequent examinations. Autoimmune neutropenia or other autoimmunity were excluded by peripheral blood examination. The bone marrow morphologic examination showed a selective maturation arrest of neutrophil precursor cells. During the follow-up, she maintained good clinical condition but suffered recurrent viral bronchitis for which she was hospitalized two times at 4 years of age. During the second episode, administration of G-CSF growth factor was attempted with a poor response (neutrophil rise from 120/mm³ to 320/mm³). Immunologic investigation showed hypergammaglobulinemia (IgG 1949 at last follow-up) with normal IgA, IgM, and IgE and response to vaccines. Flow cytometry analysis on his peripheral blood mononuclear cells (PBMC), in vitro T (PHA and anti-OKT3) and B (CpG) cells proliferation were normal. Brain MRI and spectroscopy, abdominal and cardiac ultrasound, and ophthalmologic evaluation did not show particular abnormalities.

At 2 years and half of age, after excluding the most common form of neutropenia, we performed a metabolic screening and found an increased urinary excretion of 3-methylglutaconic acid and 3-methylglutaric acid.

Targeted NGS analysis, using the TruSight One Expanded (a clinical exome from Illumina which covers coding regions of 6794 genes), revealed three heterozygous mutations in the *CLPB* gene, the c.1903G>A, the c.1904C>A and the c.1882C>T. Segregation analysis,

This is an open access article under the terms of the [Creative Commons Attribution-NonCommercial-NoDerivs](https://creativecommons.org/licenses/by-nc-nd/4.0/) License, which permits use and distribution in any medium, provided the original work is properly cited, the use is non-commercial and no modifications or adaptations are made.

© 2022 The Authors. *Pediatric Allergy and Immunology* published by European Academy of Allergy and Clinical Immunology and John Wiley & Sons Ltd.

performed using Sanger sequencing, revealed that the c.1903G>A and the c.1904C>A were inherited from the father, whereas the c.1882C>T was inherited from the mother (Figure 1A, upper panel). Both parents were asymptomatic. The first two variants were not reported in the public database (gnomAD, ExAc, 1000Genomes), were classified as "Variant of Unknown Significance" (ACMG: PM2, PP2, PP3), produced the aminoacidic change p. Ala635Lys in a highly conserved region of the protein (Figure 1A, lower panel), and were predicted to be deleterious by different bioinformatics tools (Polyphen-2, SIFT, MutationTaster, MutPred). Conversely, the c.1882C>T variant that produces the aminoacidic modification p. Arg628Cys is located in the highly conserved nucleotide-binding subdomain (NBD) of the protease modules (AAA+) and was recently reported in compound heterozygosity by Kanabus et al.⁶ in two siblings showing congenital lamellar cataracts, nephrocalcinosis, renal medullary cysts, 3-methylglutaconic aciduria but not neutropenia.⁶ In these two siblings, the c.1882C>T mutation was in compound heterozygosity with the c.1915G>A located near the c.1903G>A and the c.1904C>A found in our patient. More recently, the c.1882C>T variant has also been found in heterozygosity, although not functionally validated, in three unrelated families screened for cyclic neutropenia.⁷

In our patient, the complex V activity measured in fibroblasts mitochondria was reduced with all the substrates used (-34% using succinate, -21% with Malate, and -48% using pyruvate+malate) (Figure 1B) suggesting an altered electron flux through the mitochondrial respiratory chain and consequently a mitochondrial disorder.

Biallelic *CLPB* variants were identified in children with 3-MGA-urias associated with variable neurological, cardiac and kidney involvement, neutropenia, cataracts, and early death. The clinical phenotype of patients described by Wortmann⁸ and Warren⁷ with monoallelic *CLPB* variants significantly overlaps that of patients with biallelic variants. All 6 patients described by Wortmann showed 3-MGA-uria and seizure. None of them cataracts. Two patients underwent hematopoietic stem cell transplantation for severe infections. Among 10 patients described by Warren, only 5 were tested for 3-MGA-uria resulting negative. In combination with neutropenia, 2 patients showed seizure, 2 developmental delay, and 1 cataract. For none of them 3-MGA-uria was tested. One patient was deceased for myeloid malignancy.

The small number of individuals with *CLPB* deficiency limits the analysis of genotype-phenotype correlations. The biallelic mutations in *CLPB* described are generally frameshift or nonsense variants scattered throughout the protein (Figure 1A, lower panel). In contrast, variants observed in the monoallelic *CLPB* cohort described by Warren are missense and localize to the C-terminal ATP-binding domain⁷ or near to/interfering with the ATPase binding site's activity described by Wortmann.⁸ Only one pathogenic variant, the p.Pro427Leu found by Wortmann et al was found in the pore area and associated with only a mildly decreased ATPase activity. All variants described by Wortmann were associated with a loss of disaggregase activity.⁸

Our patient further expands the spectrum associated with *CLPB* mutations and suggests that biallelic variants in *CLPB* could cause mild phenotype with isolated severe congenital neutropenia and 3-MGA-uria.

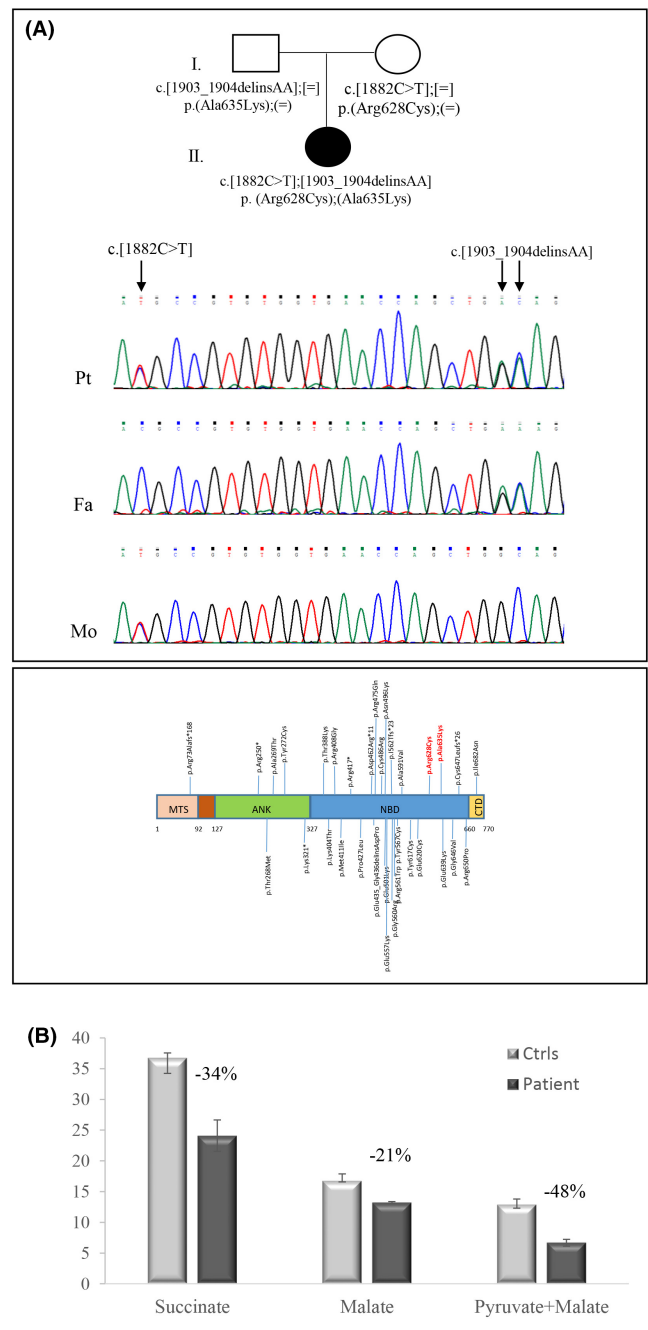


FIGURE 1 (A-upper panel) Electropherograms encompassing the mutated genomic region in *CLPB*, for patient (Pt), father (Fa), and mother (Mo). The chromatograms show the segregation of the c.[1903_1904delinsAA] mutations inherited from the father, and the c.[1882C>T] inherited from the mother; (A-lower panel) Representation of the mutations found so far in *CLPB*; in red the mutations described in this paper. (B) Spectrophotometric determination of complex V activity. ATP synthesis in fibroblasts mitochondria was reduced with either substrates used; succinate: -34%; malate: -21%; pyruvate+malate: -48%. All reported differences are significant (** $p < .0001$)

The therapeutic options for *CLPB* deficiency include G-CSF therapy, which usually leads to improved neutrophil numbers and decreased infection episodes. However, patients may be resistant to

G-CSF therapy as in our case. Few cases of acute myeloid leukemia and myelodysplastic syndrome, which resulted in patient death, have been reported in these patients. Therefore, malignancy surveillance with bone marrow evaluations are recommended.

In conclusion, we describe for the first time a case with a combination of isolated neutropenia and 3-methylglutaconic aciduria in a child with compound heterozygous mutations in *CLPB*. Finally, considering that mass urinary screening is a cheap and non-invasive tool, it should be included in the work-up of children presenting with congenital neutropenia.

CONFLICT OF INTEREST

The authors declare that the research was conducted in the absence of any commercial or financial relationships that could be construed as a potential conflict of interest.

FUNDING INFORMATION

This work was supported by the Italian Ministry of Health Ricerca Corrente [RC2020_INFETT_FINOCCHI], the Italian Ministry of Health Ricerca Finalizzata (RF-2016-02361241).

AUTHOR CONTRIBUTIONS

Beatrice Rivalta: Conceptualization (equal); Investigation (equal); Data Curation (equal); Writing – Original Draft Preparation (Lead). **Alessandra Torracco:** Conceptualization (equal); Investigation (Lead); Data Curation (equal); Writing – Review & Editing (equal). **Diego Martinelli:** Data Curation (equal); Writing – Review & Editing (equal). **Matteo Luciani:** Data Curation (equal); Writing – Review & Editing (equal). **Rosalba Carrozzo:** Conceptualization (Lead); Data Curation (equal); Writing – Original Draft Preparation (equal); Writing – Review & Editing (equal). **Andrea Finocchi:** Conceptualization (equal); Data Curation (equal); Writing – Review & Editing (equal).

Beatrice Rivalta^{1,2}
 Alessandra Torracco³
 Diego Martinelli⁴
 Matteo Luciani⁵
 Rosalba Carrozzo² 
 Andrea Finocchi^{1,6}

¹Research Unit of Primary Immunodeficiencies, Immune and Infectious Diseases Division, Academic Department of Pediatrics (DPUO), Bambino Gesù Children's Hospital, IRCCS, Rome, Italy

²Department of Systems Medicine, University of Rome "Tor Vergata", Rome, Italy

³Unit of Muscular and Neurodegenerative Disorders, Laboratory of Molecular Medicine, Department of Neurosciences, Bambino Gesù Children's Hospital, IRCCS, Rome, Italy

⁴Division of Metabolism, Bambino Gesù Children Hospital and Research Institute, IRCCS, Rome, Italy

⁵Department of Pediatric Hemato-Oncology and Cell and Gene Therapy, Bambino Gesù Children's Hospital, IRCCS, Rome, Italy

⁶Chair of Pediatrics, Department of Systems Medicine, University of Rome "Tor Vergata", Rome, Italy

Editor: Fabio Candotti

Correspondence

Rosalba Carrozzo, Unit of Muscular and Neurodegenerative Disorders, Laboratory of Molecular Medicine, Bambino Gesù Children's Hospital, IRCCS, Viale di San Paolo 15, 00146 Rome, Italy.

Email: rosalba.carrozzo@opbg.net

ORCID

Rosalba Carrozzo  <https://orcid.org/0000-0002-3327-4054>

REFERENCES

- Skokowa J, Dale DC, Touw IP, Zeidler C, Welte K. Severe congenital neutropenias. *Nat Rev Dis Primers*. 2017;3:17032.
- Kiykim A, Garncarz W, Karakoc-Aydiner E, et al. Novel *CLPB* mutation in a patient with 3-methylglutaconic aciduria causing severe neurological involvement and congenital neutropenia. *Clin Immunol*. 2016;165:1-3.
- Wortmann SB, Ziętkiewicz S, Kousi M, et al. *CLPB* mutations cause 3-methylglutaconic aciduria, progressive brain atrophy, intellectual disability, congenital neutropenia, cataracts, movement disorder. *Am J Hum Genet*. 2015;96(2):245-257.
- Saunders C, Smith L, Wibrand F, et al. *CLPB* variants associated with autosomal-recessive mitochondrial disorder with cataract, neutropenia, epilepsy, and methylglutaconic aciduria. *Am J Hum Genet*. 2015;96(2):258-265.
- Capo-Chichi JM, Boissel S, Brustein E, et al. Disruption of *CLPB* is associated with congenital microcephaly, severe encephalopathy and 3-methylglutaconic aciduria. *J Med Genet*. 2015;52(5):303-311.
- Kanabus M, Shahni R, Saldanha JW, et al. Bi-allelic *CLPB* mutations cause cataract, renal cysts, nephrocalcinosis and 3-methylglutaconic aciduria, a novel disorder of mitochondrial protein disaggregation. *J Inherit Metab Dis*. 2015;38(2):211-219.
- Warren JT, Cupo RR, Wattanasirakul P, et al. Heterozygous variants of *CLPB* are a cause of severe congenital neutropenia. *Blood*. 2022;139(5):779-791.
- Wortmann SB, Ziętkiewicz S, Guerrero-Castillo S, et al. Neutropenia and intellectual disability are hallmarks of biallelic and de novo *CLPB* deficiency. *Genet Med*. 2021;23(9):1705-1714.
- Pronicka E, Ropacka-Lesiak M, Trubicka J, et al. Additional individual contributors. A scoring system predicting the clinical course of *CLPB* defect based on the foetal and neonatal presentation of 31 patients. *J Inherit Metab Dis*. 2017;40(6):853-860.
- Cupo RR, Shorter J. *Skd3* (human *ClpB*) is a potent mitochondrial protein disaggregase that is inactivated by 3-methylglutaconic aciduria-linked mutations. *eLife*. 2020;9:e55279.

SUPPORTING INFORMATION

Additional supporting information may be found in the online version of the article at the publisher's website.

How to cite this article: Rivalta B, Torracco A, Martinelli D, Luciani M, Carrozzo R, Finocchi A. Biallelic *CLPB* mutation associated with isolated neutropenia and 3-MGA-uria. *Pediatr Allergy Immunol*. 2022;33:e13782. doi:[10.1111/pai.13782](https://doi.org/10.1111/pai.13782)