

# Update on coronavirus disease 2019: Ophthalmic Manifestations and Adverse Reactions to Vaccination

Timothy P.H. Lin, MBChB\*†, Mrittika Sen, MD, MRCSEd‡, Vishali Gupta, MD§, Rupesh Agrawal, MD||¶#\*\*††, Paolo Lanzetta, MD‡‡§§, Giuseppe Giannaccare, MD, PhD|||, Carmen K.M. Chan, MRCP\*†, Kajal Agrawal, MDS||, Nitin Kumar Menia, MS¶¶, William Rojas-Carabali, MD||¶, Atul Arora, MS, MCh§, Deborah Martinuzzi, MD‡‡, Andrea Taloni, MD##, Leopoldo Rubinato, MD‡‡, Giulia Coco, MD, PhD\*\*\*, Valentina Sarao, MD‡‡§§, Daniele Veritti, MD‡‡, Lizhen Chen, MA†††, Santosh G. Honavar, MD‡‡‡, and Dennis S.C. Lam, MD§§§|||

**Abstract:** The coronavirus disease 2019 (COVID-19) pandemic caused by the severe acute respiratory syndrome coronavirus 2 was one of the most devastating public health issues in recent decades. The ophthalmology community is as concerned about

Submitted September 19, 2023; accepted October 12, 2023.

From the \*Department of Ophthalmology and Visual Sciences, The Chinese University of Hong Kong, Hong Kong, China; †Hong Kong Eye Hospital, Hong Kong, China; ‡Ocular Oncology and Ophthalmic Plastic Surgery Services, Raghunath Netralaya, Mumbai, India; §Department of Ophthalmology, Advanced Eye Centre, Post Graduate Institute of Medical Education and Research, Chandigarh, India; ||Lee Kong Chiang School of Medicine, Nanyang Technological University, Singapore; ¶Department of Ophthalmology, Tan Tock Seng Hospital, Singapore; #Moorfields Eye Hospital, NHS Foundation Trust, London, UK; \*\*Singapore Eye Research Institute, The Academia, Singapore, Singapore; ††Duke NUS Medical School, National University of Singapore, Singapore; ‡‡Department of Medicine-Ophthalmology, University of Udine, Udine, Italy; §§Istituto Europeo di Microchirurgia Oculare, Udine, Italy; |||Department of Surgical Sciences, Eye Clinic, University of Cagliari, Cagliari, Italy; ¶¶All India Institute of Medical Sciences, Jammu, Jammu and Kashmir, India; ##University Magna Graecia of Catanzaro, Viale Europa, Catanzaro, Italy; \*\*\*Department of Clinical Science and Translational Medicine, University of Rome Tor Vergata, Rome, Italy; †††C-MER (Shenzhen) Dennis Lam Eye Hospital, Shenzhen, China; ‡‡‡Ocular Oncology and Ophthalmic Plastic Surgery Services, Centre for Sight Eye Hospital, Hyderabad, India; §§§The International Eye Research Institute of The Chinese University of Hong Kong (Shenzhen), Shenzhen, China; and |||The C-MER Dennis Lam and Partners Eye Center, C-MER International Eye Care Group, Hong Kong, China.

D.S.C.L. and T.P.H.L.: conceptualization and writing (review and editing). V.G., N.K.M., and A.A.: section Ocular Surface Manifestations of COVID-19. P.L., D.M., L.R., V.S., and D.V.: section Vitreoretinal Manifestations of COVID-19. R.A., W.R.C., and K.A.: section Uveitis Associated with COVID-19. T.P.H.L. and C.K.M.C.: section Neuro-ophthalmic Manifestations of COVID-19. G.G., A.T., and G.C.: section Ocular Surface Adverse Events to COVID-19 Vaccination. V.G., N.K.M., and A.A.: section Vitreoretinal Adverse Events to COVID-19 Vaccination. R.A., W.R.C., and K.A.: section Uveitis-Related to COVID-19 Vaccination. T.P.H.L. and C.K.M.C.: section Neuro-ophthalmic Adverse Events to COVID-19 Vaccination. S.G.H. and M.S.: section Orbital Adverse Reactions to COVID-19 Vaccination.

P.L. has been involved as a consultant for Aerie, Apellis, Bayer, Biogen, iCare, Novartis, and Roche. D.V. has been involved as a consultant for Bayer, Novartis, and Roche. V.S. has been involved as a consultant for iCare. The remaining authors declare no competing financial interests.

Address correspondence and reprint requests to: Dennis S. C. Lam, The International Eye Research Institute of The Chinese University of Hong Kong (Shenzhen), Shenzhen, China (dennislam@cuhk.edu.hk); Santosh G. Honavar, MD, Ocular Oncology and Ophthalmic Plastic Surgery Services, Centre for Sight Eye Hospital, Hyderabad, India (santosh.honavar@gmail.com).

Copyright © 2023 Asia-Pacific Academy of Ophthalmology. Published by Wolters Kluwer Health, Inc. on behalf of the Asia-Pacific Academy of Ophthalmology. This is an open access article distributed under the terms of the Creative Commons Attribution-Non Commercial-No Derivatives License 4.0 (CCBY-NC-ND), where it is permissible to download and share the work provided it is properly cited. The work cannot be changed in any way or used commercially without permission from the journal.

ISSN: 2162-0989

DOI: 10.1097/APO.0000000000000647

the COVID-19 pandemic as the global public health community is, as COVID-19 was recognized to affect multiple organs in the human body, including the eyes, early in the course of the outbreak. Ophthalmic manifestations of COVID-19 are highly variable and could range from mild ocular surface abnormalities to potentially sight and life-threatening orbital and neuro-ophthalmic diseases. Furthermore, ophthalmic manifestations may also be the presenting or the only findings in COVID-19 infections. Meanwhile, global vaccination campaigns to attain herd immunity in different populations are the major strategy to mitigate the pandemic. As novel vaccinations against COVID-19 emerged, so were reports on adverse ophthalmic reactions potentially related to such. As the world enters a post-pandemic state where COVID-19 continues to exist and evolve as an endemic globally, the ophthalmology community ought to be aware of and keep abreast of the latest knowledge of ophthalmic associations with COVID-19 and its vaccinations. This review is a summary of the latest literature on the ophthalmic manifestations of COVID-19 and the adverse ophthalmic reactions related to its vaccinations.

**Key Words:** adverse reaction, COVID-19, ocular manifestations, vaccination

(*Asia Pac J Ophthalmol (Phila)* 2023;12:512–536)

## INTRODUCTION

The coronavirus disease 2019 (COVID-19) pandemic caused by the severe acute respiratory syndrome coronavirus 2 (SARS-CoV-2) has devastating impacts globally.<sup>1</sup> At the time of writing, there were up to 700 million cases and 7 million deaths worldwide.<sup>2</sup> By now, it has become apparent that the world has entered a postpandemic state where the global populations and health care systems are adapting to new normality to coexist with the novel coronavirus as the World Health Organization (WHO) declared an end to COVID-19 as a public health emergency on May 5, 2023. Despite an end to the pandemic's emergency status, the global health threats of COVID-19 ensue with the emergence of ever-mutating novel variants. In the meantime, vaccination has become the most important global public health strategy to mitigate the COVID-19 pandemic.

It was well recognized that SARS-CoV-2 was able to result in systemic complications in multiple organs be-

sides the respiratory system. Ophthalmology is a specialty of concern in patients with COVID-19 as ophthalmic manifestations of SARS-CoV-2 infections were reported by clinicians worldwide.<sup>3</sup> Conjunctivitis was reported as the first and only clinical manifestation among patients with COVID-19 early in the course of the pandemic by Chinese investigators from Wuhan.<sup>4</sup> Furthermore, SARS-CoV-2 has been isolated from ocular surface specimens, such as tears and conjunctival swabs, from patients with COVID-19.<sup>5,6</sup> At present, the knowledge of COVID-19 continues evolving within the ophthalmology community, with recognition of its ophthalmic manifestations which span the entirety of the eye from the ocular surface to the posterior segment, orbit, and along the afferent and efferent visual pathways. Historically, vaccines were also known to be associated with ocular phenomena. The rapid immunization against COVID-19 to achieve herd immunity in the global population by widescale vaccination campaigns accompanied the surge of ophthalmic adverse events related to COVID-19 vaccinations. The pandemic has also brought along moderate changes in the mode of ophthalmic practices, especially the role of artificial intelligence, digital technology, and virtual health care.<sup>7–12</sup>

This comprehensive review aims to provide a summary of COVID-19–related ophthalmic manifestations and the ophthalmic adverse events related to its vaccinations. This knowledge would become indispensable to practicing ophthalmologists and general physicians as COVID-19 transforms from a pandemic to an endemic to affect patients from all populations and regions in the years or decades ahead.

## METHODS

A comprehensive and systematic search of the literature on PubMed for articles about ophthalmic manifestations of COVID-19, adverse ocular effects from COVID-19 treatment, and vaccination was conducted. The following keywords were used for searching the database: (“coronavirus” OR “covid-19” OR “sars-cov-2”) AND (“eye” OR “ocular” OR “ophthalmic” OR “ophthalmology” OR “eyelid” OR “conjunctiva” OR “cornea” OR “uvea” OR “lens” OR “retina” OR “orbit” OR “optic neuritis” OR “optic neuropathy” OR “diplopia” OR “ophthalmoplegia” OR “visual loss”). The final search was performed on October 10, 2023. Important and representative case reports/series and meta-analyses of ophthalmic cases associated with COVID-19 and its vaccinations were reviewed by an international panel of co-authors with backgrounds and expertise in different subspecialties. The severity of COVID-19 was considered according to the description in the articles, if mentioned, or based on the clinical presentation and management described. The diagnosis of COVID-19 in all cases was based on a SARS-CoV-2 polymerase chain reaction (PCR) test from nasopharyngeal or oropharyngeal swabs or SARS-CoV-2 serology.

## OCULAR SURFACE MANIFESTATIONS OF CORONAVIRUS DISEASE 2019

The ocular surface was postulated to be a portal of entry and potential route of transmission of SARS-CoV-2.<sup>6</sup> Notably, the expression of ACE-2 and TMPRSS2, which were surface receptors and proteins for viral entry, was observed in conjunctival and corneal tissues.<sup>13</sup> In view of the ocular surface susceptibility to the virus, it was hypothesized that primary viral infection of the ocular surface could induce local immune or inflammatory responses and result in the reported ocular surface findings in patients with COVID-19. This section discusses the common ocular surface manifestations of COVID-19 disease.

### Conjunctivitis

One of the most frequently observed ocular symptoms of COVID-19 is conjunctivitis, which can manifest before other systemic symptoms appear.<sup>4</sup> The inflammation can range from mild to severe, with presentations including tearing, itchiness, photophobia, and blurred vision, among others.<sup>4,14</sup> More serious forms of conjunctivitis, such as follicular, hemorrhagic, and pseudomembranous conjunctivitis have also been documented.<sup>4,14–16</sup> Navel et al<sup>17</sup> reported patients with COVID-19 with pseudomembranous and hemorrhagic conjunctivitis where the patient developed severe conjunctivitis on the 19th day of hospitalization. SARS-CoV-2 may gain entry into the eyes by binding to ACE-2 receptors present on ocular surface tissues. The viral shedding from the conjunctiva may continue even after the SARS-CoV-2 PCR from nasopharyngeal swabs has become negative.<sup>18</sup> Conjunctivitis can be the sole manifestation of COVID-19 disease, and conjunctival secretions may be a potential route of viral transmission. Health care workers should therefore be vigilant and maintain contact precautions while managing eye diseases among patients with COVID-19.<sup>5,19</sup>

### Keratoconjunctivitis

Similar to other ocular tissues, the cornea is susceptible to infiltration by the SARS-CoV-2.<sup>18</sup> Corneal involvement in COVID-19 disease was initially reported by Cheema et al<sup>20</sup> in which a young and, otherwise, healthy woman presented with conjunctival injection, lacrimation, and photophobia. The patient was initially diagnosed with herpetic keratoconjunctivitis. However, the patient did not respond to systemic valacyclovir therapy, and the PCR for SARS-COV-2 was positive from nasopharyngeal and conjunctival swabs.<sup>20</sup> Similarly, Chen et al<sup>4</sup> reported 14 cases of keratitis in their cohort of 535 Chinese patients with COVID-19. Majtanova et al<sup>21</sup> reported reactivation of herpes simplex virus–related keratitis in 5 patients after SARS-CoV-2 infection. These patients presented with pain, injection, photophobia, and blurred vision.

### Episcleritis

Episcleritis is another eye condition that has been noted as a potential ocular surface disorder in COVID-19, although it is less commonly reported in the literature. Managna et al<sup>22</sup> reported nodular episcleritis in a young woman who developed the condition within a week of her initial COVID-19 symptoms. The underlying cause of episcleritis is thought to be the accumulation of immune complexes in episcleral blood vessels, leading to secondary vasculitis. Another case

was reported by Otaif et al,<sup>23</sup> where episcleritis was the patient's first symptom of COVID-19. Only 3 days after the appearance of ocular symptoms, the patient developed a multitude of COVID-19 symptoms. In a larger series conducted by Bostanci Ceran and Ozates,<sup>24</sup> episcleritis was, however, found to be relatively rare among patients with COVID-19. In this particular study, just 2 out of 93 patients were diagnosed with episcleritis. This study also highlighted that episcleritis was associated with elevated serum D-dimer.<sup>24</sup>

### Scleritis

Feizi et al<sup>25</sup> reported 2 cases of anterior scleritis after the resolution of the systemic symptoms of COVID-19 disease, whereas Adenwala et al<sup>26</sup> highlighted a case with nodular episcleritis as the first manifestation of COVID-19. Sanjay et al<sup>27</sup> reported a series of patients who developed episcleritis and scleritis after COVID-19 infection and vaccination. Immune complex deposition in vessels leading to vasculitis of small vessels at the level of the sclera is the proposed mechanism for scleritis in this scenario. Dysregulation of the immune system has also been proposed as a mechanism of scleritis after COVID-19 disease.<sup>27</sup>

### Corneal Graft Rejection

Cornea is one of the most frequently transplanted tissues of the human body. Acute corneal graft rejections or failures involve complex immune responses, leading to tissue destruction. Graft rejections and failures have been reported after a variety of vaccinations and corneal graft rejection has been reported to be one of the common ocular surface manifestations of the COVID-19 disease.<sup>28–30</sup> The clinical signs specific to graft rejections and failures include the development of anterior chamber reaction, graft edema, keratic precipitates, Descemet membrane folds, and opacification of the graft. Multisystem involvement and widespread immune dysregulation have been commonly seen in patients with severe COVID-19 infections. Severe inflammatory reactions can overcome the immune privilege of the corneal tissue and can lead to acute graft rejection episodes.

### Dry Eye Disease

Dry eye disease was also reported to be associated with COVID-19. Chen et al<sup>4</sup> reported that a significant proportion of patients presented with dry eyes in their series. In their study, among 535 patients with COVID-19, 102 had dry eyes, whereas 10 had dry eyes along with conjunctival congestion.<sup>4</sup> Lim et al<sup>31</sup> also reported dry eye disease in a patient with human immunodeficiency virus and COVID-19 coinfection.

To summarize, ocular surface manifestations can be seen in a significant proportion of patients with COVID-19 disease. Although a direct causal relationship is challenging to establish, the temporal proximity of ocular surface events and COVID-19 infections in the reported cases indicate an association likely exists between SARS-CoV-2 infection and the ocular surface manifestations.

## OCULAR SURFACE ADVERSE REACTIONS TO CORONAVIRUS DISEASE 2019 VACCINATION

Adverse reactions in the ocular surface were reported to be associated with COVID-19 vaccination. COVID-19

vaccination may trigger immunologic reactions, inducing new-onset or reactivation of inflammatory ocular surface conditions. Similar to primary infection by SARS-CoV-2, it may result in herpetic keratitis, episcleritis and scleritis, corneal graft rejection, and dry eye disease (Table 1 and Fig. 1).

### Herpetic Eye Disease

Herpes simplex and zoster ophthalmicus have frequently been reported after COVID-19 vaccination: 1477 cases, with herpes zoster being the most common ( $n = 1044$ , 70.7%), were reported in the Vaccine Adverse Event Reporting System database and 43 cases of herpetic keratitis were reported in the literature.<sup>31</sup> Both new-onset and, more commonly, reactivations of herpetic infection (29.3% and 61.0%, respectively) were described, with no significant differences in the age group affected. Symptom onset usually occurred within the first 14 days after vaccination (80.4%), with higher incidence after the first (51.2%) and second dose (39.0%). All reported cases showed either resolution or improvement after antiviral treatment.<sup>31</sup>

### Episcleritis and Scleritis

Eighteen cases of scleritis and episcleritis were reported in the literature. Of these, Sanjay et al<sup>27</sup> described 8 cases of scleritis and 7 cases of episcleritis after vaccinations of AZD1222 and BBV152, 9 of which were recurrences. The average onset time was 16 days (ranged = 4–30). Clinical presentation usually occurs as anterior scleritis and either diffuse or nodular episcleritis ( $n = 12$ ). Most described cases were mild and successfully resolved within 1 month after standard conventional treatment.<sup>27</sup>

### Corneal Graft Rejection

According to the Vaccine Adverse Event Reporting System database, 52 cases of corneal graft rejection were reported after vaccinations of mRNA-based 1273 ( $n = 15$ ) and BNT162b2 ( $n = 37$ ), whereas 40 were described in the literature. All types of corneal transplants were reported to potentially be affected by graft rejection after vaccination, with most cases described in penetrating keratoplasty and endothelial keratoplasty, and only 2 events in deep anterior lamellar keratoplasty.<sup>40,41</sup> Corneal graft rejection usually occurred within 2 weeks (80.5%) after the first or second dose of the vaccine (onset range = 1–117 d), whereas no cases were reported after booster doses. The time between the most recent transplant and the rejection episode was highly variable, ranging from 14 days to 25 years. Most cases were treated with topical corticosteroids and only occasionally intravenous (IV) corticosteroid was deemed necessary. Overall, almost two-third of the reported cases showed resolution after treatment, whereas the remaining demonstrated either some improvement or no improvement.<sup>40</sup> Cumulative data suggest that rejection was less likely to resolve after DMEK compared with penetrating keratoplasty and DSAEK, potentially due to the lower frequency and potency of topical steroid treatment after DMEK. Although corneal graft rejection is reported more frequently after the first dose of vaccine, a greater incidence of rejection resolution was noted in this instance, compared with grafts rejected after the second dose of vaccine.<sup>40</sup> A multicenter, retrospective study showed that patients who received COVID-19 vaccines ( $n = 74$ ) had a

TABLE 1. Summary of Adverse Ocular Surface Conditions Related to COVID-19 Vaccination

Study; Author (y)	Study Design	Subjects	Results
<b>Herpetic keratitis</b>			
Rallis et al (2022) <sup>30</sup>	Retrospective case series	10 patients (11 eyes) 5 AZD1222 (AstraZeneca) 5 mRNA BNT162b2 (Pfizer-BioNTech)	Mean interval between vaccination and ocular symptoms/signs 12.3 ± 10.3 d Herpes simplex/zoster 40% Herpes simplex 60% Herpes zoster Common ocular signs 90.9% dendritic epitheliopathy 63.6% anterior uveitis 27.3% endothelitis
<b>Uveitis</b>			
Jordan et al (2023) <sup>32</sup>	Retrospective cohort study	New Zealand (Auckland) 4184 eyes (3008 patients) mRNA BNT162b2 (Pfizer-BioNTech) Follow-up: 3 mo	Rate of flare by anatomic location 2218 eyes, anterior uveitis 11.9% baseline vs 20.5% after first dose ( $P = 0.027$ ) Rate of flare by etiology Noninfectious, 2296 eyes, 12.4% baseline vs 20.9% first dose ( $P = 0.026$ ) HLAB27, 683 eyes 12.7% baseline vs 30.5% after the first dose ( $P = 0.030$ )
Testi et al (2023) <sup>33</sup>	Multinational case series	20 patients ( $\leq 18$ y) diagnosed with ocular inflammatory events within 28 d of COVID-19 vaccination	Uveitis localization 8 (40%) anterior uveitis 7 (35%) intermediate uveitis 4 (20%) panuveitis 1 (5%) posterior uveitis Onset 11 (55.0%) first week after vaccination 12 (60.0%) previous history of uveitis Outcome 13 complete healing 7 visual acuity loss $\leq 3$ lines
Sheng et al (2023) <sup>34</sup>	Retrospective cohort study	106 patients with Shanghai, China Inactivated vaccine BBIBP-CorV (Sinopharm)	Recurrence rate 12 (11.32%; 95% CI = 5.29%–17.35%) Mean time of relapse 5.27 ± 3.72 d (range = 1–13 d) Relapse characteristics Following vaccination: IOP 33.55 ± 12.99 mm Hg KPs 91.67% Course 30.71 ± 34.74 d Previous to vaccination: IOP 25.38 ± 3.80 mm Hg KPs 33.33% Course 7.33 ± 6.51 d (always $P < 0.05$ )
<b>Corneal graft rejection</b>			
Igarashi et al (2023) <sup>35</sup>	Retrospective cohort study	198 patients undergone DMEK 124 nonvaccinated 74 vaccinated	Corneal rejection events 1 case, nonvaccinated vs 5 cases, vaccinated ( $P = 0.003$ )
Ghiasian et al (2023) <sup>36</sup>	Prospective case series	56 patients have undergone PK BBIBP-CorV (Sinopharm)	Corneal rejection events 6 cases of endothelial rejection (after 3–117 d)
Busin et al <sup>37</sup>	Retrospective study	77 eyes cases of graft rejection 19 eyes 2018 19 eyes 2019 21 eyes 2020 18 eyes 2021	Change in the incidence rate of rejection in the risk period after COVID-19 vaccination incidence risk ratio = 0.56, 95% CI = 0.13–2.28, $P = 0.70$ Fitted as a time-varying covariate: HR = 0.77, 95% CI = 0.29–5.46, $P = 0.77$ Adjusted Cox models: HR = 0.75, 95% CI = 0.10–5.52, $P = 0.78$
Roberts et al (2023) <sup>38</sup>	Multicenter, retrospective study	Moorfield Eye Hospital UK 471 rejections OPF “Villa Igea,” Italy 95 rejections	Median rates of graft rejections before and after initiation of the vaccination program were not significantly different $P = 0.367$ Moorfield $P = 0.124$ OPF (2018–2022)
<b>Ocular surface disease</b>			
DAĞ et al (2022) <sup>39</sup>	Case-control study	61 eyes, post-COVID 63 eyes, 2 doses of mRNA BNT162b2 (Pfizer-BioNTech) 57 eyes, control	NIFBUT 4.1 ± 2.7 s post-COVID 4.7 ± 2.9 sec vaccinated 5.8 ± 2.8 s control ( $P = 0.007$ vs control)

TABLE 1. (Continued)

Study; Author (y)	Study Design	Subjects	Results
Scleritis and episcleritis Sanjay et al (2023) <sup>27</sup>	Retrospective case series	15 eyes (12 patients) 10 ChAdOx1nCoV-19 (Covishield) 2 BBV152 (Covaxin)	Mean time of onset 15.7 d (range = 4–30) Scleritis 13.2 d (range = 2–30) Episcleritis Occurrence 5 de novo 7 recurrency

COVID-19 indicates coronavirus disease 2019; DMEK, Descemet membrane endothelial keratoplasty; HR, hazard ratio; IOP, intraocular pressure; KPs, keratic precipitates; NIFBUT, noninvasive first break-up time; OPF, Ospedali Privati Forli; PK, penetrating keratoplasty; PSS, Posner-Schlossman syndrome.

significantly higher risk of DMEK graft rejection compared with nonvaccinated patients [ $n = 124$ ; 5 (6.7%) vs 1 case, respectively;  $P = 0.003$ ].<sup>40</sup>

Nevertheless, the strength of the association between COVID-19 vaccination and corneal graft rejection was questioned by some authors. Busin et al<sup>37</sup> found no notable increase in the rate of graft rejection in 2021, after the introduction of the COVID-19 vaccination, nor did the rejection rate appear to increase during the “risk period,” namely the first 60 days after vaccination, nor did any difference in the rate of graft rejections was noted between patients who received corneal transplant before and after COVID-19 vaccination. Similarly, Roberts et al<sup>38</sup> showed no significant differences in the occurrence of graft rejection before and after the vaccination campaign ( $P = 0.71$ ) in a multicenter, retrospective analysis of 566 rejection cases.

### Dry Eye Disease

A case-control study by Dag and Acet<sup>39</sup> on 181 patients compared the noninvasive first break-up time among patients with post-COVID, patients who received COVID-19 vaccination (mRNA BNT162b2), and a control group. noninvasive first break-up time was significantly lower in post-COVID and vaccinated patients compared with the control group ( $P = 0.007$ ), suggesting the occurrence of destabilization of the tear

film after infection and vaccination, which resulted in dry eye disease in this group of patients.

### Other Anterior Segment Adverse Events

Other uncommon adverse events in the anterior segment suspected to be associated with COVID-19 vaccination were also reported. These included keratitis besides herpetic eye disease, marginal and ulcerative keratitis, keratolysis, corneal perforation due to Mooren ulcer and Thygeson superficial punctate keratitis have also been described in isolated case reports after vaccination.<sup>40</sup> Cases of rejection of kerato and conjunctival limbal allografts were also reported after vaccination.<sup>42,43</sup>

In summary, the available evidence suggests that COVID-19 vaccination may trigger immunologic reactions, inducing new-onset or reactivation of several inflammatory ocular conditions in the anterior segment (Table 1). Although generally mild and transient, these adverse reactions should be further investigated, as more vaccine booster administrations may become necessary in the following years. Currently, the association between vaccines and anterior segment adverse events remains elusive and debatable, and more rigorous studies are necessary to draw definitive conclusions.

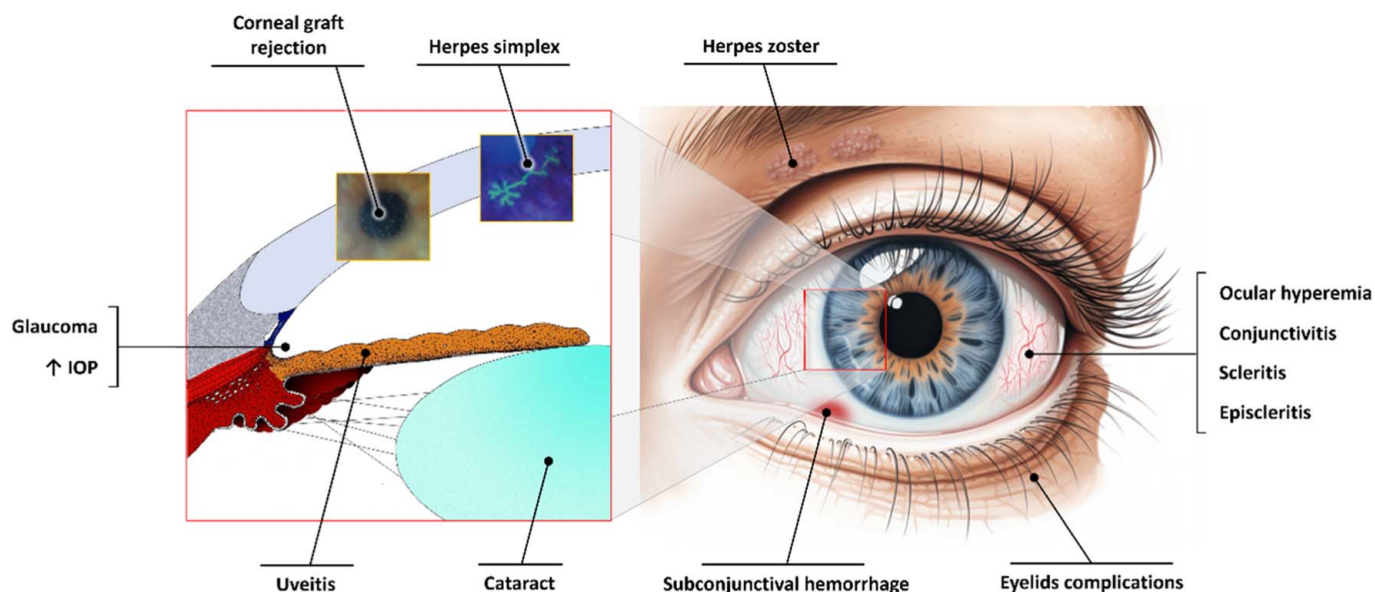


FIGURE 1. Summary of the most common ocular surface adverse events to COVID-19 vaccination. COVID-19 indicates coronavirus disease 2019.

## VITREORETINAL MANIFESTATIONS OF CORONAVIRUS DISEASE 2019

COVID-19 has been suggested to affect the retinal tissues.<sup>44</sup> The virus has been implicated in vascular perturbations within the eye, manifesting as a spectrum of retinal abnormalities that range from subclinical changes detectable solely through advanced imaging techniques to overt clinical presentations including microvascular changes, retinal vascular occlusions, acute macular neuroretinopathy (AMN), and paracentral acute middle maculopathy (PAMM).

Retinal vascular diseases associated with COVID-19 may be attributed to the direct interaction of the virus with vascular endothelial cells, which subsequently triggers a cascade involving the activation of the complement system, coagulation pathways, and platelet aggregation, culminating in thromboembolic events and retinal hypoxia. Alternatively, these changes may be mediated by an inflammatory or autoimmune response instigated by the viral infection. In addition, SARS-CoV-2 infection and subsequent treatment have been linked to the onset of central serous chorioretinopathy (CSCR) and endogenous endophthalmitis (EE), in particular among patients who were administered high-dose corticosteroid therapy.<sup>45</sup>

### Microvascular Changes

Approximately 0.01%–20% of patients with COVID-19 develop retinal microvasculopathy, including microhemorrhages and vascular tortuosity. These changes may be attributed to the infection and systemic conditions like hypertension or medical treatments.<sup>46</sup> Differences in vascular density between patients with COVID-19 and healthy controls have been observed, and these may last for months postinfection.<sup>47</sup> Some research shows reduced vascular density in both superficial and deep capillary plexuses (DCP) at foveal and parafoveal levels among patients with COVID-19, whereas other studies find these changes mainly in peripheral areas. Some research also shows an enlarged foveal avascular zone and increased choroidal capillary plexus blood flow, likely due to hypoxia and inflammation-induced vasodilation.<sup>48</sup>

### Retinal Vascular Occlusion

Retinal vascular occlusion is a significant retinal condition that can complicate COVID-19, though existing literature does not clearly indicate if its incidence has changed due to the pandemic or if it is directly linked to the virus. This condition may arise from inflammation, viral damage to endothelial cells, and a cytokine-induced prothrombotic state. Interestingly, 36%–50% of COVID-19–related retinal vein occlusion (RVO) cases had no other health issues, and their average age was 39, younger than prepandemic RVO cases.<sup>48</sup> In 75% of retinal artery occlusion cases, patients displayed no notable abnormalities on the brain or Doppler sonography of the carotid artery. However, some exhibited vascular complications, such as carotid occlusions, cavernous sinus thrombosis, and simultaneous strokes.<sup>48</sup> Most RVO cases were nonischemic central RVO, often complicated by macular edema. Data on incidence are conflicting: some studies show an initial pandemic spike, whereas others find no significant change, even when accounting for vaccination status.<sup>48</sup> One study in Spain noted a higher RVO incidence in 2021, with 60

cases, compared with an average of 36.3 cases per year over the past 13 years.<sup>49</sup>

### Acute Macular Neuroretinopathy

AMN is an uncommon retinal condition characterized by the acute onset of brownish-red, wedge-shaped perifoveal lesions, leading to paracentral or central scotomata. It is linked to viral flu-like symptoms, contraceptives, catecholamines, trauma, and systemic shock often related to microvascular damage or reduced blood flow in the DCP and choroidal capillary plexus.<sup>50</sup> Four AMN cases connected to COVID-19 have emerged, strengthening the suspected link to SARS-CoV-2.<sup>50</sup> These cases lack typical AMN risk factors and usually manifest symptoms within 2 weeks of infection. A recent study identified 40 AMN cases and 3 combined AMN and PAMM cases after either COVID-19 infection (29 cases) or vaccination (28 cases).<sup>51</sup> However, when rare retinal anomalies like AMN coincide with much more frequent events such as COVID-19 infection and vaccination, the correlation might be incidental rather than causal.

### Paracentral Acute Middle Maculopathy

PAMM is a rare retinal disease characterized by ischemia of the DCP, leading to a visual acuity impairment. While often related to vascular surgery, pregnancy, and flu-like syndromes, its underlying causes remain unclear. A recent study found 9 cases of PAMM in patients who had moderate to severe COVID-19. Two had both AMN and PAMM, whereas 5 had only PAMM. One case was linked to central retinal artery occlusion and another to ciliary artery occlusion; both patients had no prior medical issues.<sup>50</sup>

### Central Serous Chorioretinopathy

CSCR is a common retinal disease worldwide, but its association with COVID-19 is not well-documented. Only 5 cases have been reported, developing 2–3 weeks after a COVID-19 diagnosis, with 4 of these patients having received corticosteroids during their infection. Although stress and corticosteroids are known risk factors for CSCR, a direct correlation with COVID-19 is still uncertain. The stress induced by the pandemic could worsen the condition in susceptible individuals, and corticosteroid treatment, often necessary for COVID-19–related lung issues, could also be a contributing factor.<sup>52</sup>

### Endogenous Endophthalmitis

Patients with moderate to severe COVID-19 are at risk of developing EE, due to exposure to multidrug-resistant pathogens in hospitals and extended use of corticosteroids, which increase vulnerability to secondary infections. A recent study identified 10 eyes that developed EE about a month after a COVID-19 diagnosis, with most requiring surgery and infections predominantly caused by *Candida albicans* and *Aspergillus fumigatus*.<sup>53</sup> Another study documented 6 EE cases, 2 being bilateral, ~40 days after a COVID-19 diagnosis, with vitreous samples showing a mix of *Candida*, *Bipolaris*, and *Staphylococcus* species.<sup>54</sup> In addition, 5 eyes were found with presumed fungal EE a month postinfection, treated with antibiotics and antifungals; one case necessitated retinal detachment surgery.<sup>55</sup> Shroff et al<sup>56</sup> reported 7 eyes with EE, mainly due to *Candida* or *Aspergillus*. Lastly, 3 EE cases of post-COVID-19 pneumonia were documented, with causative

agents being *Klebsiella pneumoniae*, *Stenotrophomonas maltophilia*, and methicillin-resistant *Staphylococcus aureus*, confirmed in blood, nasopharyngeal cultures and vitreous samples.<sup>57</sup>

### VITREORETINAL ADVERSE EVENTS TO CORONAVIRUS DISEASE 2019 VACCINATION

The posterior segment manifestations after COVID-19 vaccination may cause severe loss of vision and may be a significant cause of ocular morbidity. This section discusses posterior segment manifestations after COVID-19 vaccination.

#### Acute Macular Neuroretinopathy

Multiple studies have highlighted the development of AMN in patients after COVID-19 vaccination.<sup>51,58,59</sup> Recently, Dutta Majumder and Agarwal<sup>51</sup> presented a review of patients with AMN after COVID-19 infections and vaccinations. It has been postulated that the thrombogenic effects of COVID-19 vaccination may lead to AMN.<sup>60,61</sup> The complement-activated microangiopathy secondary to COVID-19 vaccination has also been implicated in the ischemic changes at the level of deep capillary plexus in AMN.<sup>51</sup> Treatment may include observation and a short course of oral corticosteroids, and the disease is usually self-limiting with favorable outcomes.

#### Paracentral Acute Middle Maculopathy

PAMM after COVID-19 infection or vaccination has been attributed to changes in retinal circulation secondary to thrombosis.<sup>51</sup> Pichi and colleagues reported a patient who noted inferior scotoma after COVID-19 vaccination. The swept source optical coherence tomography showed opacification of the inner retinal layers, and optical coherence tomography angiography highlighted an increased foveal avascular zone suggestive of PAMM.<sup>61</sup> Malerbi et al<sup>62</sup> reported a case of Susac syndrome with associated PAMM after COVID-19 vaccination. Vinzamuri et al<sup>63</sup> reported PAMM lesions in a patient who had received a recombinant COVID-19 vaccine and the symptoms appeared almost 1 month after administering the second vaccination dose.

#### Acute Zonal Occult Outer Retinopathy

Acute Zonal Occult Outer Retinopathy (AZOOR) is an autoimmune, inflammatory disease characterized by scotomas, photopsia, and loss of vision. The OCT shows widespread loss of the outer retinal layers (Fig. 2). After vaccination, activated T-helper cells can cross-react with proteins and antigens in the outer retinal layers and retinal pigment epithelial cells, leading to typical findings in AZOOR. In a Japanese, multicentric, retrospective study, 2 cases of AZOOR were reported secondary to COVID-19 vaccination.<sup>64</sup> Maleki et al<sup>65</sup> also reported 2 instances of AZOOR after COVID-19 vaccination. The disease is usually self-limiting, but corticosteroids and immunosuppression may be considered to prevent the spread of the lesions and the loss of vision. One of the patients in the reported cases was managed with an intravitreal dexamethasone implant and retained good vision.

#### Central Serous Chorioretinopathy

Fowler et al<sup>66</sup> reported CSCR in a young man after immunization with the Pfizer-BioNTech BNT162b2 mRNA

COVID-19 vaccine. This report highlighted the temporal association of CSCR development without a specific history of exogenous steroid use or other risk factors. The patient was started on spironolactone, and CSCR resolved at 3 months of follow-up. Similar patients who developed CSCR after COVID-19 vaccination have been recently reported in the literature.<sup>67</sup> The proposed mechanisms contributing to the pathogenesis of CSCR included an increase in endogenous cortisol production. Other proposed mechanisms included free mRNA leading to leaks in the choriocapillaris vessels and an increase in the inflammatory cytokines secondary to an exaggerated immune response to vaccination.

Ophthalmologists should be aware of the various posterior segment manifestations of COVID-19 vaccinations. Patients with preexisting retinal and uveitic diseases may be advised about the possible though small risk of recurrences and the need for reporting early to ophthalmologists in case of such recurrences. The benefits of vaccination apparently outweigh the risks. Hence, it should always be emphasized to follow the guidelines and advice of local health authorities.

### UVEITIS ASSOCIATED WITH CORONAVIRUS DISEASE 2019

Uveitis is a recognized ophthalmic manifestation of COVID-19 that was widely reported in the literature. However, it remains challenging to establish a definitive cause-effect relationship between COVID-19 and uveitis. This section discusses the relationship between COVID-19 and uveitis, exploring the associated findings and the complexities surrounding this connection.

#### Anterior, Intermediate, Posterior, and Panuveitis

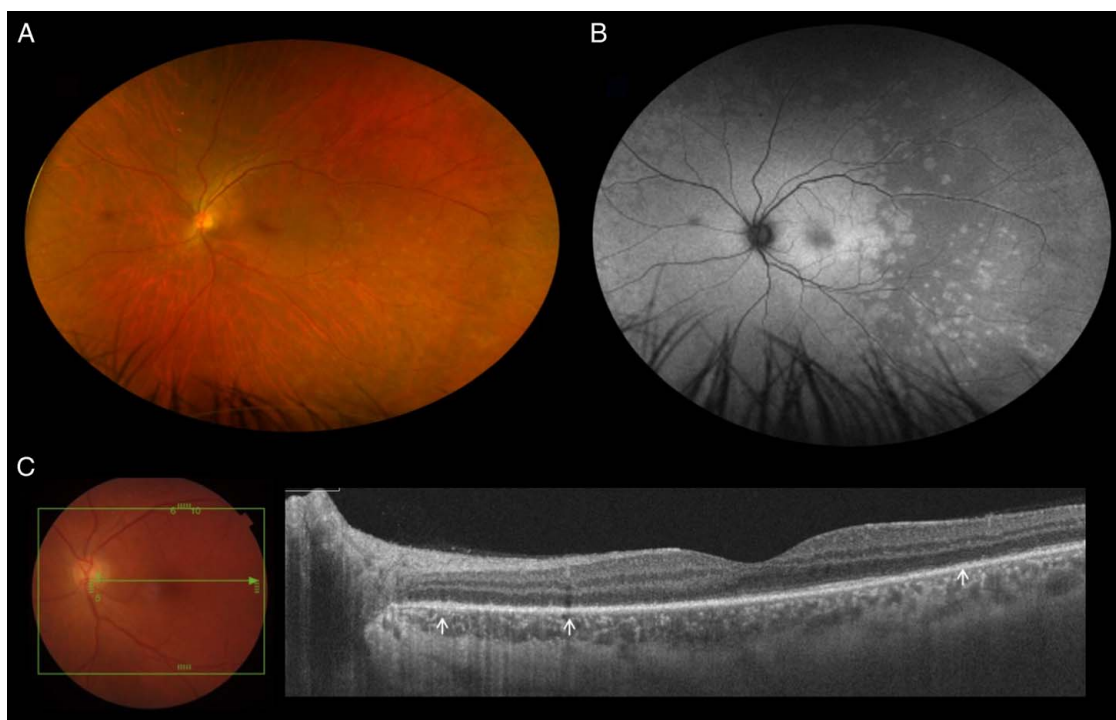
COVID-19 infection has been associated with anterior, intermediate, posterior, and panuveitis. Patients with COVID-19 with uveitis may present with a diverse array of ocular symptoms, such as injection, pain, floaters, and photophobia. Notably, these ocular inflammatory presentations are not solely confined to the involvement of the uvea alone. In some instances, the inflammation may be associated with systemic complications, leading to syndromes associated with uveitis, such as Vogt-Koyanagi-Harada disease.<sup>68,69</sup> While numerous studies have documented patients experiencing either the first onset or reactivation of uveitis post-COVID-19 infection,<sup>70-74</sup> the precise mechanisms and causal relationships between the virus and these ocular symptoms remain elusive and are areas of active investigation.

#### Specific Types of Choroiditis

A few cases of choroid-specific uveitides have also been reported. Among these, White Dot syndrome, serpiginous choroiditis, and punctate inner choroidopathy were the most commonly reported conditions to be associated with COVID-19.<sup>75,76</sup>

#### Retinitis and Retinal Vasculitis

There have been reports of patients with COVID-19 displaying clinical features consistent with Acute Retinal Necrosis (ARN) or retinitis, including retinal inflammation and necrosis, both of which are hallmarks of ARN.<sup>77,78</sup> It was recognized from the earlier discussion that the spectrum of



**FIGURE 2.** A 38-year-old Asian Indian man presented with floaters and flashes of light in his left eye 8 weeks after his first dose of COVID-19 vaccine (ChAdOx1 nCov-19, AstraZeneca). His presenting visual acuity was 20/30. Clinical examination revealed a normal-looking fundus. A, Fundus autofluorescence showed hyperautofluorescence in the macular area. B, SS-OCT showed loss of the ellipsoid layer (white arrows) in the area of hyperautofluorescence. C, The symptoms improved upon treatment with oral steroids with reversal of autofluorescence and OCT changes. COVID-19 indicates coronavirus disease 2019; SS-OCT, swept source optical coherence tomography.

retinal manifestations associated with COVID-19 is broad, which ranges from vascular occlusion, and vascular dilatation, to retinal vasculitis with perivascular infiltrate and retinal exudate.<sup>19,79</sup> It is important to note that some of these cases are relatively rare and the reports may only be anecdotal. Therefore, it remains challenging to establish a direct causal relationship between COVID-19 and inflammatory retinal manifestations given the low incidence of the latter.

### The Complex Relationship: Challenges and Implications

Despite numerous cases being reported globally, a definitive relationship between COVID-19 and the aforementioned ocular inflammatory manifestations remains elusive and warrants further study. Several hypotheses have emerged to elucidate the underlying pathophysiology of these manifestations. It is postulated that in certain patients, COVID-19 triggers an exaggerated and aberrant immune response, culminating in the production of autoantibodies and subsequent inflammation in different tissues.<sup>80</sup> Such an autoimmune response might present as ocular inflammatory syndromes. The concept of molecular mimicry, wherein viral proteins mimic host proteins, offers another potential explanation. If COVID-19 proteins exhibit antigenic similarities with uveal proteins, this could inadvertently instigate uveitis.<sup>80</sup> In contrast, some researchers have proposed that SARS-CoV-2 may directly infect ocular tissues, including the retina, leading to inflammation and necrosis.<sup>19</sup> However, evidence supporting this hypothesis remains limited. Finally, in view of the enormous scale of the COVID-19 pandemic, the occurrence of uveitis in a patient with COVID-19 may only be coincidental. While the virus may be associated with various uveitis-related

conditions, it is essential to exercise caution and emphasize the need for more comprehensive studies to establish a definitive link between COVID-19 and inflammatory ocular manifestations.

The precise identification of COVID-19-associated uveitis amidst the heterogeneous presentations of uveitis represents a paramount challenge to clinicians. To confront this diagnostic conundrum, we have undertaken an innovative approach by incorporating the differential diagnosis of COVID-19 within the spectrum of infective aetiologies in our comprehensive and purposefully engineered Ocular Autoimmune Systemic Infectious Study platform.<sup>81</sup> The Ocular Autoimmune Systemic Infectious Study platform serves as a repository of clinical and imaging data, encompassing both COVID-19-associated uveitis and non-COVID-19 uveitis cases. This rich repository holds the potential to utilize and develop artificial intelligence-based diagnostic tools dedicated to diagnosing COVID-19-related uveitis from uveitis of other etiologies in the future and guiding clinicians in the next step of management in the emerging era of digital medicine.

### Management of Uveitis Associated With Coronavirus Disease 2019

When uveitis is suspected in patients with COVID-19, careful evaluation and a multidisciplinary approach are essential.<sup>74</sup> Treatment strategies should consider both the ocular manifestations and systemic complications of COVID-19, ensuring the best possible outcomes for the patient. In most cases, there are no differences in the management of a patient with COVID-19-associated uveitis, and each type of uveitis can usually be safely treated with its standard treatment protocol.



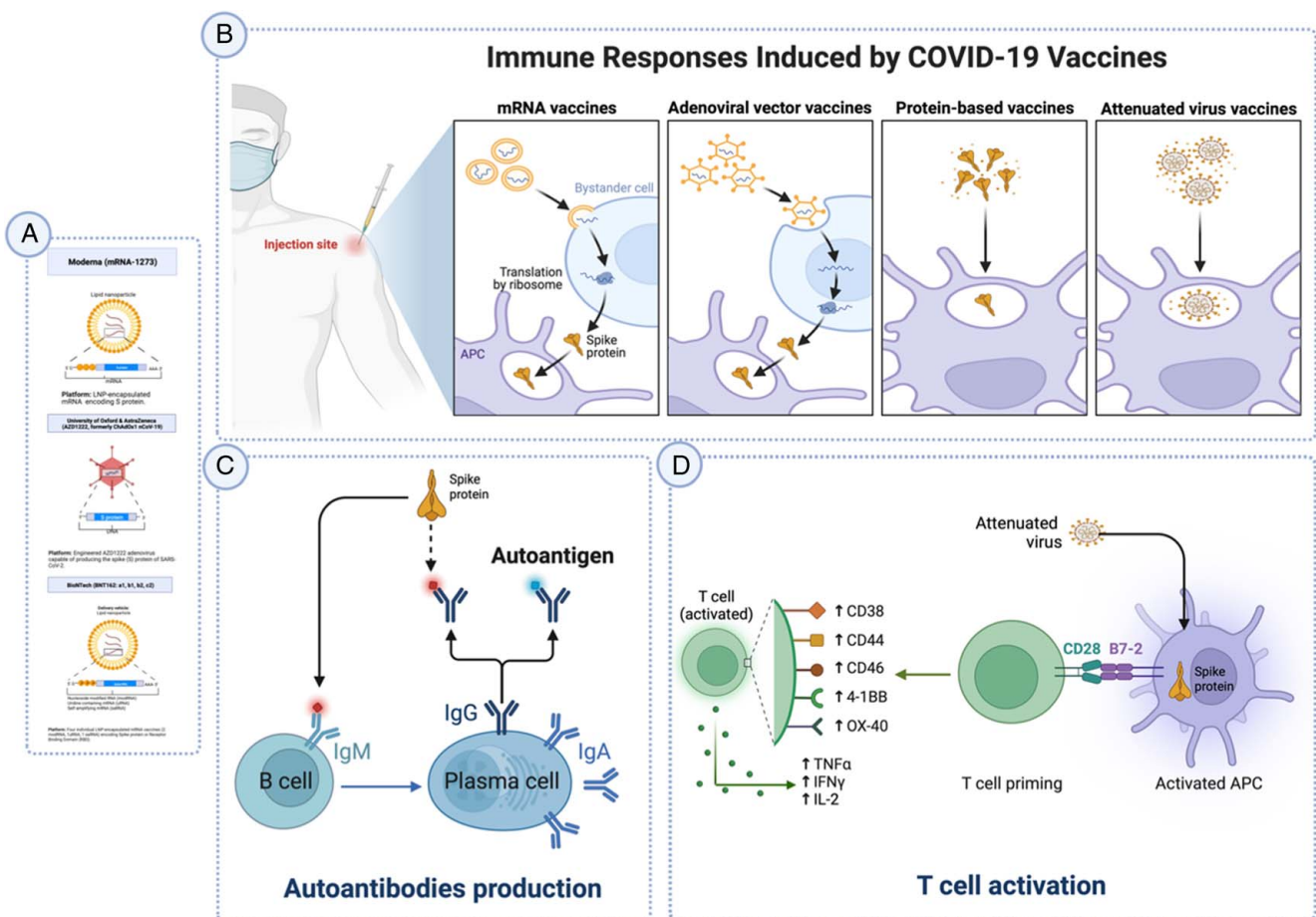
### UVEITIS-RELATED TO CORONAVIRUS DISEASE 2019 VACCINATION

Vaccines are powerful stimulators of the immune system.<sup>82</sup> Shortly after the FDA approval of the first COVID-19 vaccine, several reports were published linking the vaccine to the onset and reactivation of autoimmune diseases. Theories suggest that molecular mimicry, the production of specific autoantibodies, and the role of certain vaccine adjuvants may contribute to these observations (Fig. 3). These mechanisms are of particular relevance to uveitis-related to COVID-19 vaccination given the autoimmune nature of most uveitides.<sup>83</sup> In view of the extensive reports on uveitis-related to COVID-19 vaccination, this section aims to summarize the key findings from important studies and discuss the clinical implications of the numerous uveitis cases reported to occur after COVID-19 vaccination.

The COVID-19 Vaccination Ocular Inflammatory Events Study Group reported 70 adult patients with ocular inflammatory events within 14 days after COVID-19 vaccination in a multinational study. Most of the cases were related to mRNA COVID-19 vaccination (57.1%) and the most common types of inflammation were anterior uveitis (58.6%), posterior uveitis (12.9%), and anterior scleritis (10.0%). Treatment of the

ocular inflammation included topical corticosteroids (55.7%), systemic corticosteroids (18.6%), antivirals (8.6%), and topical corticosteroids with oral nonsteroidal anti-inflammatory drugs (2.8%). Ten patients (14.3%) did not require any treatment and eventually recovered.<sup>84</sup> Moreover, Testi and colleagues reported a multinational case series of 20 pediatric patients with ocular inflammatory events after COVID-19 vaccination. Similar to adults, inflammation was noticed in the first week after vaccination in most patients (55.0%) and the most common event was anterior uveitis (n = 8, 40.0%), but in this case followed by intermediate uveitis (7 patients, 35%), panuveitis (4 patients, 20%), and posterior uveitis (1 patient, 5%). Likewise, patients were managed with topical corticosteroids (n = 19, 95.0%), oral corticosteroids (n = 10, 50.0%), or increased doses of immunosuppressive treatment (n = 6, 30.0%).<sup>33</sup> In both cases-series, final visual acuity was unaffected or <3 lines of loss and the reported complications included nummular corneal lesions, cystoid macular edema, posterior synechiae, peripheral retinal atrophy, serous retinal detachment, and macular scarring, all of them occurring in <5% of cases.<sup>33</sup>

In addition, a systematic review conducted by Sadok et al demonstrated that COVID-19 vaccine-associated uveitis is



**FIGURE 3.** Vaccine viral configurations, immune responses to COVID-19 vaccines, and molecular mimicry effects (A) delineate the configurations of Moderna as a lipid nanoparticle-enclosed mRNA, AstraZeneca as a replication-deficient adenovirus vector with the SARS-CoV-2 spike protein gene, and BioNTech (Pfizer) as an mRNA strand encased in a lipid nanoparticle. B, The immune responses: mRNA vaccines like Moderna and BioNTech induce ribosomal translation and consequent antibody and T-cell activation, AstraZeneca prompts immune response through viral entry and gene transcription, protein-based vaccines drive an antibody-centric reaction, whereas attenuated virus vaccines initiate a broad immune response through a weakened viral life cycle. C, Highlights molecular mimicry, depicting the risks of autoantibody production due to viral proteins resembling host proteins. D, T-cell activation resulting from similarities between viral and host peptides presented on MHC molecules, underscoring potential misdirected T-cell attacks on healthy host cells. COVID-19 indicates coronavirus disease 2019; MHC, major histocompatibility complex; SARS-CoV-2, severe acute respiratory syndrome coronavirus 2.

more likely to occur in females than in males (68.93% vs 31.06%). Patients of any age could be affected, with middle-aged patients (41–50 y of age) more commonly affected and a declining trend as it towards both extremes of ages (0–10 or  $\geq 91$  y). The most common presentation was acute, anterior, unilateral, and noninfectious uveitis. However, cases of choroiditis, retinitis, retinochoroiditis, and pars planitis have been reported.<sup>85</sup> The manifestations of uveitis are diverse and can be categorized based on their locations (Table 2). The expansive range of these manifestations underscores the need for comprehensive monitoring and further research into the ocular side effects associated with the COVID-19 vaccine.<sup>85,86</sup>

Despite all the cases of ocular inflammation reported in observational studies after the administration of the COVID-19 vaccine, a large epidemiological study in the USA did not find an increased risk of noninfectious uveitis after COVID-19 vaccination in individuals without a history of the disease.<sup>87</sup> Moreover, although cases of noninfectious uveitis have been reported after vaccination with any type of vaccine, most cases have been reported in patients who received the mRNA-based BNT162b2 vaccine, with most cases occurring within the first 14 days and after the first dose of vaccination.<sup>88</sup>

A study from the Inflammatory Eye Disease Registry at Auckland demonstrated an increased risk of uveitis flare after the first dose of the COVID-19 vaccine, in both infectious uveitis (154% increase) and noninfectious uveitis (169% increase). Risk factors for uveitis flare were identified to be

recurrent uveitis, chronic uveitis, shorter period of quiescence, and first dose of vaccine. The median time to uveitis flare was 0.53 months after the first vaccination, 1.74 months after the second vaccination, and 1.35 months after the third vaccination.<sup>32</sup> Likewise, concomitant treatment with either systemic glucocorticoids [hazard ratio (HR) = 0.24 (95% CI = 0.09–0.69);  $P = 0.008$ ] or cyclosporine [HR = 0.36 (95% CI = 0.14–0.93);  $P = 0.034$ ] for uveitis at the time of COVID-19 vaccination was associated with a lower risk of uveitis relapse after vaccination.<sup>89</sup> However, in a randomized clinical trial conducted at a specialized uveitis centre in China, 543 unvaccinated patients with inactive uveitis were studied to assess early versus deferred non-mRNA COVID-19 vaccination recommendations. By 3 months, 41.6% in the early vaccination group had been vaccinated compared with 5.0% in the deferred vaccination group. The results showed a shorter time to symptomatic uveitis flare in the early vaccination group (HR = 1.68;  $P = 0.01$ ), though there were no significant differences in objective uveitis activity or visual acuity between the groups at 3 months. It was, therefore, concluded that early non-mRNA COVID-19 vaccination was linked to a higher incidence of symptomatic uveitis worsening, possibly due to reporting bias, but did not affect disease or visual outcomes at 3 months.<sup>90</sup>

In summary, although COVID-19 vaccination has been associated with a broad spectrum of ocular inflammation manifestations, the current evidence remains inconclusive regarding whether these vaccines are truly a cause of de novo disease. However, there appears to be an association with the reactivation of preexisting uveitis. The most common presentation is acute, anterior, unilateral, and noninfectious uveitis. When uveitis occurred after COVID-19 vaccination, it was particularly linked to the mRNA-based vaccines and is more commonly observed in middle-aged females. However, there have also been reports of other uveitides, such as panuveitis (including VKH), choroiditis, retinitis, retinochoroiditis, and pars planitis, across all age groups and with various vaccine types.

## NEURO-OPHTHALMIC MANIFESTATIONS

COVID-19 is known to be associated with significant neurological complications,<sup>91,92</sup> and neuro-ophthalmic manifestations of COVID-19 have gained attention with increasing case reports since the advent of the pandemic. Both afferent and efferent disorders were reported to be associated with COVID-19 infection. Table 3 gives a summary of COVID-19-associated neuro-ophthalmic manifestations.

### Optic Neuritis

Optic neuritis is the most prevalent neuro-ophthalmic manifestation associated with COVID-19. A total of 26 cases of optic neuritis secondary to COVID-19 infection were reported in the literature.<sup>19,91–94</sup> The mainstay of treatment for optic neuritis which arose secondary to COVID-19 infection was high-dose IV methylprednisolone (IVMP), followed by an oral prednisolone taper as in the Optic Neuritis Treatment Trial.<sup>95</sup> Most patients demonstrated complete or significant resolution of visual symptoms and optic disc swelling after treatment. Optic neuritis is likely a para-infectious autoimmune process triggered by SARS-CoV-2. Of the 26 reported cases, anti-

**TABLE 2.** Spectrum of Ocular Inflammatory Reactions Related to COVID-19 Vaccination Documented in the Literature

Keratouveitis <sup>4</sup>
Uveitis
Anterior
Idiopathic anterior uveitis <sup>9</sup>
Herpetic uveitis <sup>8</sup>
TINU syndrome <sup>15</sup>
Intermediate
Pars Planitis <sup>4</sup>
Posterior
AMN <sup>9</sup>
PAMM <sup>8</sup>
Multiple evanescent white dot syndrome <sup>8,9</sup>
Neuroretinitis <sup>16</sup>
Persistent Placoid Maculopathy
AZOOR <sup>9</sup>
Multifocal Choroiditis <sup>9</sup>
APMPPE <sup>8</sup>
Acute retinal necrosis <sup>4</sup>
Tubercular choroiditis <sup>17</sup>
Toxoplasmosis retinochoroiditis <sup>4</sup>
Panuveitis
Idiopathic panuveitis <sup>9</sup>
Vogt-Koyanagi-Harada disease <sup>9</sup>
Sympathetic ophthalmia <sup>8</sup>
Scleritis
Anterior diffuse <sup>9</sup>
Anterior nodular <sup>18</sup>
Posterior <sup>19</sup>

AMN indicates acute macular neuroretinopathy; APMPPE, acute posterior multifocal placoid pigment epitheliopathy; AZOOR, acute zonal occult outer retinopathy; COVID-19, coronavirus disease 2019; PAMM, paracentral acute middle maculopathy; TINU, tubulointerstitial nephritis and uveitis.

**TABLE 3.** Summary of Neuro-Ophthalmic Manifestations of COVID-19

Diagnosis	Age (y)	Number of Reported Cases	Sex (F:M)	Duration between onset of COVID-19 symptoms/diagnosis and ophthalmic presentations (d)	Severity of COVID-19	Management	Outcomes
Optic Neuritis	43.0 ± 17.8	26	12:14	21.6 ± 35.2	Asymptomatic to Moderate	High-dose IVMP, followed by tapering oral prednisolone	Improvement of symptoms and vision, resolution of optic disc swelling
Papillophlebitis	40	1	1 male	42	Mild	Oral acetylsalicylic acid and sustained-release dexamethasone implant	Decrease in papillary and macular edema with gradual recovery of VA
NAION	56.3 ± 9.7	NAION: 9 NPION: 2	4:6	20.2 ± 18.2	Mild to severe	Conservative management, optimization of vasculopathy risk factors	NAION: variable outcomes; some patients showed improvement in visual acuity, and some developed optic atrophy with visual loss NPION: spontaneous recovery
Vision loss due to ischemic stroke	72.0 ± 17.0	2	0:2	2.5 ± 3.5	Mild to moderate	Subcutaneous LMWH, oral aspirin, and statin	Not reported
Vision loss due to increased intracranial pressure	23	1	1 female	30	Moderate	Optic nerve sheath fenestration, endovascular transverse sinus thrombectomy, acetazolamide, and heparin	Continued deterioration of vision to bilateral NLP
MFS	43.3 ± 16.8	16	4:13	13.9 ± 16.6	Asymptomatic or mild	IVIg, plasmapheresis	Improvement and resolution in neurological symptoms
Cranial neuropathy	42.0 ± 23.9	Third nerve palsy: 4 Fourth nerve palsy: 2 Sixth nerve palsy: 4	3:7	5.3 ± 7.1	Asymptomatic or mild	Supportive management, high-dose IVMP, followed by tapering oral prednisolone, oral prednisolone alone	Complete recovery
OMG	57.3 ± 9.3	4	1:3	24.7 ± 9.2	Mild to moderate	Oral pyridostigmine alone or in combination with oral prednisolone	Improvement in symptoms
Pupillary abnormalities	47.5 ± 17.8	4	3:1	28.0 ± 24.5	Mild to moderate	Conservative management	Spontaneous recovery
Ocular movement disorders	65.0 ± 12.2	3	0:3	18.7 ± 21.1	Mild to severe	IVIg, IVMP, conservative management	Improvement of symptoms

COVID-19 indicates coronavirus disease 2019; IV, intravenous; IVIg, intravenous immunoglobulin; IVMP, intravenous methylprednisolone; LMWH, low molecular weight heparin; MFS, Miller-Fisher syndrome; NAION, nonarteritic anterior ischemic optic neuropathy; NLP, no light perception; NPION, nonarteritic posterior ischemic optic neuropathy; OMG, ocular myasthenia gravis; VA, visual acuity.

myeline oligodendrocyte (MOG) or aquaporin 4 (AQP4) antibodies were identified in 13 and 1 cases, respectively.<sup>93,94,96</sup> It is recognized that SARS-CoV-2 can incite a profound host immune dysregulation as demonstrated by the cytokine storm and acute respiratory distress syndrome in severe COVID-19 infections. The infection likely incited an aberrant host immune response against endogenous MOG or AQP4 proteins and culminated in the development of MOG-associated disease and neuromyelitis optica spectrum disorder with positive antibodies.<sup>97</sup>

### Papillophlebitis

Papillophlebitis is a rare condition that was reported in one patient after COVID-19 infection.<sup>94</sup> It occurs as a consequence of inflammation of the retinal veins and possibly the capillaries of the optic disc. Papillophlebitis in COVID-19 is likely a thrombotic microangiopathy secondary to the vascular endothelial dysfunction and hypercoagulable inflammatory state induced by SARS-CoV-2. García et al reported a 40-year-old white man who presented with a unilateral decrease in visual field (VF) sensitivity, whose fundus examination in the affected eye showed dilated and tortuous retinal vessels, disc edema, and retinal hemorrhages. He was diagnosed with papillophlebitis which was characterized by venous congestion and optic disc edema. Systemic workup revealed coagulopathy with raised serum D-dimers and fibrinogen. The patient was initially treated with oral acetylsalicylic acid and topical bromfenac, but his vision subsequently deteriorated due to macular edema in the affected eye. He was thereafter treated with an intravitreal dexamethasone implant, and his vision eventually completely recovered with a resolution of macular and papillary edema after treatment.<sup>98</sup>

### Nonarteritic Ischemic Optic Neuropathy

Vision loss due to nonarteritic ischemic optic neuropathy after COVID-19 infection has also been documented in 11 patients in the literature.<sup>99–101</sup> Ischemic optic neuropathy is an acute ischemia of the optic nerve, which is classified anatomically into anterior ischemic optic neuropathy (AION) which involves the optic nerve head and the posterior ischemic optic neuropathy (PION) which involves the rest of the optic nerve posteriorly.<sup>102</sup> Etiologically, AION can be arteritic or nonarteritic. In the current literature, 9 cases of nonarteritic AION (NAION) were reported to be associated with COVID-19. There were no reports of arteritic AION associated with COVID-19 infection in the literature. PION is a diagnosis of exclusion and was reported in 2 patients with recent COVID-19 infection.<sup>103,104</sup> They presented with acute painless vision loss and relative afferent pupillary defect with no optic disc edema. The VF showed nonspecific loss in one patient and neuroimaging did not reveal any lesions or optic nerve changes in both patients with presumed PION. These patients were managed conservatively with optimization of their vasculopathy risk factors and spontaneous recovery in vision has been observed among these cases.

### Visual Loss Due to Ischemic Stroke

Cortical blindness secondary to occipital lobes cerebral infarcts were reported in 2 patients after COVID-19 infection.<sup>105,106</sup> Both patients presented with acute bilateral vision loss during active COVID-19 infection with unremarkable

ophthalmic examination. The diagnosis of cortical blindness secondary to ischemic stroke involving the occipital lobes in both patients was confirmed by neuroimaging. Serum inflammatory markers, including D-dimer, and C-reactive protein were elevated while thrombocytopenia suggestive of underlying coagulopathy was observed in these patients. The workup for thromboembolism was negative. Thrombolytic and anticoagulant therapy were the mainstay of management for both patients. Although the visual outcomes were not reported in the literature in both cases, it is likely that the vision loss was irreversible in the context of cortical infarcts.

### Visual Loss due to Increased Intracranial Pressure

Vision loss has also been reported in one patient who developed papilloedema and intracranial hypertension secondary to cerebral venous sinus thrombosis associated with COVID-19.<sup>107</sup> Omari et al<sup>107</sup> reported a young patient who developed bilateral vision loss, papilloedema, partial right third nerve, and bilateral sixth nerve palsies after COVID-19 infection with cerebrospinal fluid opening pressure <60 mm Hg. Magnetic resonance venography subsequently revealed bilateral cerebral venous sinus thromboses. She was treated aggressively with acetazolamide and heparin, followed by optic nerve sheath fenestration and endovascular transverse sinus thrombectomy. Nevertheless, despite the resolution of her papilloedema, her vision progressively deteriorated to no light perception bilaterally. This case illustrated that COVID-19-associated intracranial hypertension complicated by vision loss could be severe and sight-threatening. The underlying pathophysiology is still likely related to the neurotropism, hypercoagulability, endothelial dysfunction, and vascular permeability induced by SARS-CoV-2.<sup>108</sup> Prompt diagnosis and aggressive treatment are necessary to salvage the vision in these scenarios.

### Miller-Fisher Syndrome

Miller-Fisher syndrome (MFS) is a variant of Guillain-Barré syndrome, which is an acute peripheral polyneuropathy that develops after exposure to various viral, bacterial, or fungal pathogens. MFS is also immune-mediated and often associated with antiganglioside (GQ1b) antibodies, and characterized by a triad of ophthalmoplegia, ataxia, and areflexia. In the literature, 17 cases of MFS associated with COVID-19 infection were reported.<sup>109</sup> It is noteworthy that although these patients presented with typical symptoms of MFS, only 4 patients (25%) demonstrated seropositivity for GQ1b antibodies, contrary to the earlier literature which reported an 85% seropositivity of GQ1b antibodies in MFS with no associated COVID-19 infection.<sup>110</sup> This might indicate alternative targets and immune-mediated mechanisms in COVID-19-associated MFS. Nevertheless, there were no differences in the prognosis among GQ1b positive or negative cases, and the vast majority of patients demonstrated significant improvement with the resolution of ophthalmoplegia and associated neurological symptoms after treatment by IV immunoglobulins (IVIg). One patient required plasmapheresis and eventually recovered.<sup>111</sup>

### Cranial Neuropathy

Ophthalmoparesis and diplopia may also arise after COVID-19 infections due to cranial neuropathies aside from

MFS.<sup>112–114</sup> In the literature, 10 cases of new-onset cranial nerve palsy involving the oculomotor, trochlear, or abducens nerves were reported. One case of trochlear nerve palsy was associated with a concurrent Adie tonic pupil in the contralateral eye.<sup>113</sup> Cranial neuropathy was believed to arise after COVID-19 infection due to viral neurotropism with direct viral neurological injury or indirect neuroinflammatory mechanisms due to aberrant host immune response.<sup>115</sup> Most patients demonstrated spontaneous recovery of cranial neuropathy with supportive management. Meanwhile, 2 cases of pediatric patients with isolated third nerve palsy associated with COVID-19 infection received treatment by oral corticosteroid, and 1 adult patient with sixth nerve palsy was treated by high-dose IVMP, followed by an oral prednisolone taper.<sup>114,116,117</sup> The 2 cases of trochlear palsy were also treated with a short course of oral prednisolone and IVMP, respectively, which resulted in clinical improvement and resolution of diplopia without reporting adverse effects of treatment.<sup>113,118</sup>

### Ocular Myasthenia Gravis

Myasthenia gravis with purely ocular symptoms was also a possible neuro-ophthalmic manifestation of COVID-19 infection.<sup>119–121</sup> These patients presented with typical signs of ocular myasthenia gravis (OMG). Serum acetylcholine receptor (AChR) antibodies were identified in all cases, and a decremental response > 10% on repetitive nerve stimulation test was also reported. Computed tomography ruled out the presence of thymoma in all cases. These patients were treated with oral pyridostigmine alone or in combination with low-dose oral prednisolone (20 mg/d), which resulted in significant clinical improvement. It is noteworthy that generalized myasthenia gravis (GMG) with both ocular and systemic symptoms were also reported to be associated with COVID-19. Restivo et al<sup>122</sup> reported 2 cases of generalized myasthenia gravis complicated by dysphagia and respiratory failure which required IVIg and plasmapheresis. Both patients improved after prompt and aggressive treatment. It was proposed that an immune-mediated disorder secondary to molecular mimicry of SARS-CoV-2 epitopes triggered the production of autoantibodies against AChR in the neuromuscular junction in the development of myasthenia gravis after COVID-19 infection.

### Pupillary Abnormalities

Tonic pupils or Horner syndrome were also noted as a neuro-ophthalmic manifestation in 4 patients with COVID-19.<sup>123–127</sup> Tonic pupils were reported to develop after COVID-19 infection with sluggish pupillary reaction to light with vermiform movement and segmental constriction. Notably, near response was also impaired in reported cases of tonic pupils contrary to the typical presentation in noninfectious cases,<sup>123,124</sup> and the diagnosis was confirmed by hypersensitivity to 0.1% pilocarpine with pupillary constriction in the affected eyes. Transient Horner syndrome with unilateral ptosis and miosis in the absence of sympathetic chain lesions on imaging was also reported in acute COVID-19 infections. These cases spontaneously resolved without treatment. It was proposed that direct neuronal invasion of the autonomic nervous system may contribute to these manifestations.

### Ocular Movement Disorders

Abnormal control of ocular movements in the form of opsoclonus, nystagmus, and ocular flutter were also reported to be rare associations of COVID-19 infection. Sanguinetti and Ramdhani<sup>128</sup> reported a case of a 57-year-old man who developed opsoclonus with spontaneous horizontal and vertical oscillations of his eyes without an intersaccadic interval after COVID-19 infection.<sup>128</sup> The ocular findings were also associated with arrhythmic myoclonic jerks in his hands and an ataxic gait. Neuroimaging was unremarkable. A diagnosis of opsoclonus-myoclonus syndrome associated with COVID-19 was made and this patient subsequently received IVIg and low-dose IVMP 40 mg twice daily leading to marked clinical improvement, including resolution of his opsoclonus and ocular flutter. Wright et al<sup>129</sup> reported another similar case of COVID-19-associated opsoclonus-myoclonus syndrome which presented with opsoclonus, ocular flutter, and ataxia without myoclonus. This patient only received conservative management with the eventual resolution of his ocular movement abnormalities. Finally, Umapathi et al<sup>130</sup> reported a case of severe COVID-19 infection complicated by infective encephalitis, whose ocular findings included roving eye movements, ocular flutter, and ocular dipping. His abnormal ocular movements improved with repeated courses of IVIg.

Tisdale et al<sup>91</sup> have reviewed the neuro-ophthalmic manifestations of COVID-19 and discussed possible underlying mechanisms. Aberrant immune response, vascular endothelial dysfunction, coagulopathy, and direct viral neurotropism may be culpable for the development of the aforementioned neuro-ophthalmic diseases among patients with COVID-19.

It is recognized that SARS-CoV-2 is capable of inciting a profound immune response, which could be pathologic and harmful as demonstrated by the lethal cytokine storm in severe COVID-19 infections.<sup>131</sup> Various neurological disorders such as optic neuritis, MFS, and OMG which have an immunologic basis are thought to be triggered by a misdirected host immune response upon exposure to SARS-CoV-2. In this review, more than 50% of cases of optic neuritis (14/26) were associated with MOG-IgG or AQP4-IgG. This suggests a potential for SARS-CoV-2 to trigger autoantibody production through molecular mimicry of its viral epitopes in human hosts. Compared with other respiratory viral infections, patients with COVID-19 demonstrated higher frequency and severity of thrombotic events, such as pulmonary embolism and myocardial infarction. The interaction of SARS-CoV-2 and ACE-2 receptors on vascular endothelium may perturb the kallikrein-kinin system, resulting in endothelial injury, prothrombotic activity, and thrombosis.<sup>108</sup> Thrombotic events in the neurological and ocular systems may result in papillophlebitis, ischemic optic neuropathy, and visual loss due to ischemic stroke. Finally, a direct viral neurotropism and neuronal cytopathic effect triggered by SARS-CoV-2 invasion of the neurological system was also hypothesized. The spike glycoprotein of the coronavirus mediates viral entry into host cells through the ACE-2 receptors, which are present in multiple tissues including neuronal and glial cells. This direct access to the neurological systems could explain the COVID-19-associated cranial neuropathy, autonomic dysfunction with pupillary abnormalities, and encephalitis with abnormal ocular movements.<sup>115</sup>

## NEURO-OPHTHALMIC ADVERSE EVENTS TO CORONAVIRUS DISEASE 2019 VACCINATION

The reported neuro-ophthalmic adverse events associated with commercially available COVID-19 vaccines were reviewed and summarized (Table 4). Most vaccine-related ophthalmic adverse events were indeed similar to the neuro-ophthalmic manifestations of COVID-19 infections. A few additional neuro-ophthalmic disorders were also reported to be potentially related to COVID-19 vaccines.

Optic neuritis is the most commonly reported adverse neuro-ophthalmic complication after COVID-19 vaccination.<sup>132</sup> It has been reported to occur in mRNA-based (BNT162b2 and mRNA-1273), nonreplicating viral vector (AZD1222 and Ad25. COV2.S) and inactivated virus (CoronaVac) vaccines. Optic neuritis is known to be the most frequent vaccine-related demyelinating clinical manifestation. Among vaccines for common pathogens that have been linked to optic neuritis include hepatitis virus types A and B, pneumococcal, influenza, measles, and rabies vaccines.<sup>133</sup> Although the exact mechanism of vaccine-induced optic neuritis remains elusive, it is hypothesized to be related to the activation of the host immune response through the introduction of foreign antigens, such as mRNA or viral molecules, which result in subsequent neuroinflammation.<sup>134</sup> Almost all reported cases received standard treatment with IVMP, followed by tapering oral prednisolone, which resulted in significant clinical improvement. Nevertheless, one documented case of optic neuritis after the Moderna mRNA-1273 vaccine resulted in subsequent deterioration in vision to no light perception with no improvement despite treatment.<sup>135</sup>

Ocular motility disorders were also reported to occur after the common COVID-19 vaccines. MFS, a Guillain-Barré syndrome variant, has been known to occur after viral infection or vaccination. On the contrary, OMG after vaccination was less frequently reported in the traditional literature before the era of COVID-19 vaccination. The GQ1b and AChR antibodies have been identified in reported cases of MFS and OMG after COVID-19 vaccination, respectively.<sup>136,137</sup> It was, therefore, favored that a molecular mimicry mechanism may be involved. A case of incomplete third nerve palsy was reported to occur after the administration of the Moderna mRNA-1273 vaccine. In the absence of a definite mechanism, it was interpreted as an autoimmune phenomenon occurring through molecular mimicry or a viral-like inflammatory reaction to the vaccine resulting in immune-mediated indirect insult to the nerve. Clinical improvement or complete recovery was demonstrated in the reported cases after treatment.

NAION was reported after the Pfizer-BioNTech mRNA-based and AstraZeneca nonreplicating viral vector vaccines.<sup>138,139</sup> NAION was rarely reported to be associated with vaccination in the past. According to a case series, which included 14 patients who developed NAION after COVID-19 vaccinations, 50% of patients had no known vascular risk factors before the diagnosis of NAION.<sup>140</sup> It was, therefore, believed that COVID-19 vaccination may predispose patients to an increased risk of NAION. Studies have reported that the administration of COVID-19 viral vector-based vaccines and mRNA-based vaccines could result in thrombotic events. Furthermore, the Pfizer-BioNTech BNT152b2 mRNA-based vaccine was also reported to induce transient endothelial dysfunction in human subjects.<sup>141</sup> In the literature, most

patients with NAION induced by COVID-19 vaccination demonstrated clinical recovery with conservative management.

Transient visual loss due to vasospasm was reported in isolated cases after the Pfizer-BioNTech mRNA-based and CoronaVac inactivated virus vaccines. Cunha et al<sup>142</sup> reported a previously healthy man who developed recurrent sudden and painless monocular complete vision loss with spontaneous full recovery after Pfizer-BioNTech vaccination. Ocular examination, systemic workup, and neuroimaging were all unrevealing. Optical coherence tomography angiography and fundus photograph captured during his attack showed reduced circumpapillary vessel density and diffuse vascular narrowing, respectively. A diagnosis of retinal vasospasm was made, and he was treated with oral verapamil hydrochloride which subsequently prevented recurrent attacks. Similarly, Jumroendararasame et al<sup>143</sup> reported a case of bilateral transient VF defect with spontaneous recovery experienced by an ophthalmologist within 1 hour after CoronaVac vaccination. In view of unremarkable systemic workup and neuroimaging, the authors postulated it to be related to vasospasm in the postchiasmatic visual pathway. Once again, this is likely attributed to the vascular endothelial dysfunction triggered by the COVID-19 vaccines.

Finally, rare but potentially sight-threatening neuro-ophthalmic complications were noted to develop after the administration of the Pfizer-BioNTech BNT162b2 vaccine. Che et al<sup>144</sup> reported a case of bilateral ischemic optic neuropathy due to temporal artery biopsy-proven giant cell arteritis (GCA). The patient presented with fever, scalp tenderness, bilateral visual loss, and optic disc edema after vaccination. Despite being treated with IV high-dose methylprednisolone followed by oral prednisolone, her vision in one eye worsened to no light perception despite treatment. GCA was known to be associated with vaccination including influenza vaccines, which accounted for an estimated 2.8% of GCA according to a previous study.<sup>145</sup> It is likely that the mRNA in the COVID-19 vaccine which coded for the viral spike protein may trigger an autoimmune response hence inducing GCA. Saffra et al<sup>146</sup> reported 3 cases of presumed autoimmune optic neuropathy after vaccination. The patients presented with painless visual loss, relative afferent pupillary defect, VF defects, and optic disc swelling with negative systemic workup and unremarkable imaging of the optic nerves. They were treated with high-dose corticosteroids which led to clinical improvement but incomplete recovery. Similarly, it was thought that an immune-mediated indirect insult to the optic nerve was induced due to the inflammatory reaction to the vaccine antigens.

## ORBITAL MANIFESTATIONS OF CORONAVIRUS DISEASE 2019

Orbital manifestations after COVID-19 infection are rare compared with other ophthalmic manifestations. Orbital cellulitis, subperiosteal muco-pyocoeles, dacryoadenitis, and inflammatory changes to intra and extraconal fat have all been reported after COVID-19 infection<sup>147</sup> (Table 5). This section summarizes the orbital manifestations associated with COVID-19 infection.

TABLE 4. Summary of Neuro-Ophthalmic Adverse Events Associated With COVID-19 Vaccinations

Vaccine	Manufacturer	Type of Vaccine	Duration between vaccination and ophthalmic presentations (d)	Neuro-ophthalmic Adverse Events	Number of Reported Events	Management	Outcomes
BNT162b2	Pfizer-BioNTech	mRNA-based	49.2 ± 65.7	Optic neuritis	14	High-dose IVMPs, followed by tapering oral prednisolone, plasmapheresis	Clinical improvement in vision and resolution of disc swelling
			16.3 ± 9.8	MFS	7	IVIg	Complete recovery
			21	OMG	1	Oral pyridostigmine and prednisolone	Clinical improvement
			5.2 ± 4.2	NAION	11	Conservative management, tapering the dose of oral prednisolone	Resolution of optic disc swelling and improvement in vision
			14	Recurrent transient monocular vision loss	1	Oral verapamil	Resolution of recurrent attacks
			1	Bilateral AAION (GCA)	1	High-dose IVMP, followed by tapering dose of oral prednisolone	Improvement in vision in one eye and deterioration in the fellow eye to no light perception
			4.7 ± 1.5	Presumed AON	3	High-dose IV or oral corticosteroids	Partial recovery
mRNA-1273	Moderna	mRNA-based	1	Optic neuritis	1	High-dose IVMP	No improvement (no light perception at presentation)
			8	MFS	1	IVIg	Complete recovery
			3	Third nerve palsy	1	A short tapering course of oral prednisolone	Complete recovery
AZD1222	AstraZeneca	Nonreplicating viral vector	12.0 ± 5.9	Optic neuritis	9	High-dose IVMP, followed by tapering dose of oral prednisolone	Clinical improvement in vision and resolution of disc swelling
			2.8 ± 0	NAION	6	Conservative management, tapering the dose of oral prednisolone	Resolution of optic disc swelling and improvement in vision
			12.0 ± 3.5	MFS	3	IVIg	Complete recovery
			14	OMG	1	Oral pyridostigmine, prednisolone and azathioprine	Complete recovery after stopping all medications
Ad26.COV2.S	Johnson and Johnson	Non-replicating viral vector	7	Optic neuritis	1	High-dose IVMPs, followed by tapering oral prednisolone, plasmapheresis	Clinical improvement in vision and resolution of disc swelling
CoronaVac	Sinovac Biotech	Inactivated virus	14	Optic neuritis	1	High-dose IVMPs, followed by tapering oral prednisolone, plasmapheresis	Clinical improvement in vision and resolution of disc swelling
			9 ± 1.4	MFS	2	IVIg	Complete recovery
			0	Transient bilateral visual loss due to vasospasm	1	Conservative management	Spontaneous recovery
Wuhan	Sinopharm/Chinese Academy of Science	Inactivated virus	—	None reported in English literature	—	—	—

AAION indicates arteritic anterior ischemic optic neuropathy; AON, autoimmune optic neuropathy; COVID-19, coronavirus disease 2019; GCA, giant cell arteritis; IV, intravenous; IVIg, intravenous immunoglobulin; IVMP, IV methylprednisolone; MFS, Miller-Fisher syndrome; NAION, nonarteritic anterior ischemic optic neuropathy; OMG, ocular myasthenia gravis.

**TABLE 5.** Orbital Manifestations of COVID-19 and COVID-19 Vaccines

1.	Dacryoadenitis
2.	Orbital cellulitis, sinusitis
3.	Retro-orbital pain
4.	ROCM
5.	Histiocytic lesions
6.	Tolosa-Hunt syndrome
7.	Superior ophthalmic vein thrombosis
8.	Thyroid eye disease

COVID-19 indicates coronavirus disease 2019; ROCM, Rhino-orbital-cerebral mucormycosis.

### Dacryoadenitis

Dacryoadenitis is the turgescence of the lacrimal gland after infection or inflammation. Viral infection, particularly Epstein-Barr virus, is the most common etiology in children and young adults.<sup>148</sup> Dacryoadenitis related to COVID-19 infection has been reported as isolated case reports.<sup>147–150</sup> The mean age of patients in the published literature was 22.2 years (median 23 y, 6 mo–36 y) with symptoms developing at a mean of 15.2 days (median 12 d, 7–30 d) after the diagnosis/onset of symptoms of COVID-19.

Martinez Diaz et al<sup>148</sup> reported a case of acute dacryoadenitis in a 22-year-old man who had a history of contact with COVID-19–infected patients and his serum SARS-CoV-2 IgM and IgG antibodies were positive. In the case reported by Rodrigues et al,<sup>149</sup> a type 2 diabetic who developed unilateral ptosis and ophthalmoplegia a month after being diagnosed with COVID-19 was initially treated with IV amphotericin B as a case of COVID-19–related mucormycosis. Lack of response prompted a repeat magnetic resonance imaging which revealed a bulky lacrimal gland and a diagnosis of dacryoadenitis. The patient improved after a course of IV antibiotics and methylprednisolone. Almater et al<sup>150</sup> reported a case of presumed acute suppurative bacterial dacryoadenitis 10 days after the diagnosis of COVID-19.

Temporal association with COVID-19 infection, elevated C-reactive protein, D-dimer and leukocyte count, negative autoimmune profile, and serology for other infectious etiology and response to steroids led to the presumed role of COVID-19 in the development of dacryoadenitis.<sup>151,152</sup> The detection of SARS-CoV-2 virus in the tear film and their retrograde ascent into the lacrimal gland through the lacrimal ductules or hematogenous spread are implicated in the development of infective dacryoadenitis.<sup>148</sup> The ACE-2 receptor is a major functional receptor and entry protein for SARS-CoV-2, which is expressed in various tissues, including ocular and adnexal tissues. Kase and Ishida<sup>153</sup> demonstrated the expression of ACE-2 receptors in the lacrimal gland and ductal epithelium in patients with COVID-19 and dacryoadenitis. Furthermore, the SARS-CoV-2 nucleocapsid protein was detected in the lacrimal gland tissue of patients with COVID-19 infection indicating that SARS-CoV-2 could adhere to the lacrimal ducts and reach the glandular tissue.<sup>153</sup> Dacryoadenitis may even develop as a late complication especially in, otherwise, healthy individuals as an immunologic response.<sup>78</sup> Histopathology of the lacrimal gland tissue in the patient with COVID-19 with chronic dacryoadenitis demonstrated marked inflammation with fibrosis which was attributed as an aftereffect of the SARS-CoV-2 positive inflammatory cell infiltration of the lacrimal gland.<sup>153</sup> The

histopathological finding in the lacrimal gland was also comparable to the chronic inflammation, interstitial collagen deposition through induction of epithelium-mesenchymal transition, and myofibroblastic differentiation occurring in the lungs of patients with COVID-19 infection.<sup>153</sup> Glandular damage and the presence of eosinophilic material deposited within the ductules were also described in histopathology from the patient with COVID-19.<sup>153</sup>

Acute and chronic dacryoadenitis related to COVID-19 infections responded well to systemic corticosteroids with complete resolution in 2–24 weeks.<sup>148,151</sup> Some authors preferred to administer steroids under the cover of systemic antibiotics and/or COVID-19 vaccination in previously unvaccinated patients.<sup>153</sup>

### Orbital Cellulitis and Sinusitis

Orbital cellulitis is a potential complication of paranasal sinusitis. It is common in the pediatric population and presents with periorbital edema, erythema, painful ophthalmoplegia, visual deficit, relative afferent pupillary defect, and proptosis.<sup>154</sup> *Staphylococcus aureus* and Streptococcal species are the most prevalent causal organisms.<sup>154</sup> Orbital cellulitis and sinusitis reported in association with COVID-19 had certain unique features. COVID-19 infection induces upper respiratory congestion that can compromise mucociliary clearance, subsequent sinus obstruction, and secondary bacterial infection.<sup>19</sup> Superior ophthalmic vein and cerebral sinus venous thrombosis with facial vein extension can also be a complication of COVID-19–associated thrombotic state.<sup>19</sup>

Turbin and colleagues reported 2 cases of young patients with COVID-19 infection developing acute orbital cellulitis. Computed tomography of the orbit showed ipsilateral sinusitis, superior subperiosteal fluid collection, and periantral fat infiltration in the first patient and additional superior ophthalmic vein thrombophlebitis and epidural abscess in the second patient.<sup>155</sup> Superior orbitotomy with drainage of subperiosteal muco-pyocoele and subperiosteal irrigation with antibiotics and endoscopic sinusotomy were performed.<sup>152</sup> Neither of them had overt COVID-19 symptoms at presentation and the drained content showed no pathologic organisms.<sup>155</sup> Carvalho et al<sup>156</sup> reported a case of unilateral orbital cellulitis developing in a young healthy male with evidence of bilateral chronic pansinusitis 13 days after COVID-19 infection. Ethmoidal sinusitis is the most common source of orbital spread of sinus infection. However, the superior orbital collection in this case was suggestive of a frontal sinus source.<sup>156</sup> Shires et al<sup>157</sup> described a spontaneously draining orbital abscess, sinusitis, and skull base osteomyelitis with globe perforation necessitating enucleation and sinus debridement in a 76-year-old man with diabetes, hypertension, testicular cancer, and COVID-19. The nasal mucosa was observed to be highly avascular intraoperatively which may have been due to thromboembolic complications of COVID-19 infection.<sup>157</sup> Culture from material obtained from sinus debridement grew methicillin-resistant *Staphylococcus aureus*, *Streptococcus constellatus*, and *Peptoniphilus indolicus*. *Peptoniphilus indolicus* has been found in the vagina and stomach, and orbital infection with this bacterium has not been previously reported. COVID-19 may have predisposed the patient to infection with an unusual bacterium not typically found in the orbit.<sup>157</sup>



Orbital cellulitis, unless diagnosed and treated in a timely manner, can lead to potentially fatal cavernous sinus thrombosis and central nervous system (CNS) infections.<sup>154</sup> In the case described by LoBue et al,<sup>158</sup> a 62-year-old man with presumed COVID-19 infection, who presented with painful right-sided facial and eyelid edema, rapidly developed bilateral cavernous sinus thrombosis, superior ophthalmic vein thrombosis, and ipsilateral pachymeningeal thickening. His general condition also deteriorated rapidly with elevated D-dimer, activated partial thromboplastin time, prothrombin time, international normalized ratio and fibrinogen, acute hypoxic respiratory failure, and renal failure. The authors attributed the aggressive course to COVID-19–associated coagulopathy.<sup>158</sup> Mears et al<sup>154</sup> reported a case of pansinusitis, orbital cellulitis, and extensive thromboses involving bilateral cavernous sinus, internal jugular veins, bilateral sigmoid sinus, and right ophthalmic vein with subdural empyema potentiated by COVID-19 in a 17-year old girl. COVID-19–related venous thrombosis generally presents as deep venous thrombosis or pulmonary embolism.<sup>154</sup> These are also more common in adults with systemic comorbidities. The incidence of thrombotic events in children with COVID-19 is estimated to be 2.1% in critically ill and over 12 years of age.<sup>154</sup> However, the mortality rate is 28% in pediatric patients with thromboembolic events related to COVID-19.<sup>154</sup>

Bagheri et al<sup>159</sup> reported orbital apex syndrome with orbital cellulitis as a manifestation of COVID-19. Orbital apex syndrome is characterized by the involvement of the optic nerve and cranial nerves 3, 4, and 6 and the first division of the trigeminal nerve with painful visual loss, ophthalmoplegia, ptosis, proptosis, and loss of sensations.<sup>159</sup> Abdelkader et al<sup>160</sup> reported 9 cases of simultaneous unilateral endophthalmitis with orbital cellulitis as a presenting feature of COVID-19 infection. Of these, only one patient had paranasal sinusitis suggesting a distant source of infection in the rest. The authors suggested generalized poor immunity of patients, direct viral infection, and multisystem inflammatory syndrome related to COVID-19 as possible mechanisms of this unusual ophthalmic manifestation.<sup>160</sup>

Abdul-Kadir and Rosli<sup>161</sup> reported an unusual case of orbital cellulitis with a subperiosteal abscess in a 4-year-old child after nasopharyngeal swab to test for COVID-19 infection. Cantarella et al<sup>162</sup> reported a similar complication in a 79-year-old patient with damage to the lamina papyracea and subsequent orbital cellulitis after a nasopharyngeal swab test. While nasopharyngeal swab is a standard test used extensively during the pandemic, and has a minimal complication rate (0.001%–0.16%), the authors suggested the possibility of the swab technique aggravating underlying rhinitis or trauma to turbinates or lamina papyracea leading the sinus drainage obstruction, acute sinusitis, and subsequent orbital cellulitis, hence should be performed with caution giving importance to the technique and site of a nasal swab.<sup>161,162</sup>

It is important to rule out mucormycosis which can have similar presenting features. Management in these cases was with endoscopic sinus drainage or sinusotomy, orbitotomy with abscess drainage, aggressive parenteral antibiotics (covering gram-positive, gram-negative, and anaerobic organisms), oxymetazoline nasal sprays, topical ocular antibiotics with close inpatient monitoring of the patient.<sup>55</sup> In pediatric patients with

sinusitis with COVID-19, an initial course of medical management for 48–72 hours is recommended before surgical intervention.<sup>163</sup> However, surgical intervention is often required early to prevent complications, such as orbital apex syndrome, cavernous sinus thrombosis, and CNS extension of the infection. The use of anticoagulation should be individualized. Typically, patients are started on unfractionated heparin and then transitioned to oral rivaroxaban after 5–10 days.<sup>154</sup>

### Rhino-Orbital-Cerebral Mucormycosis

Mucormycosis historically was an opportunistic infection seen in immunocompromised patients and those with uncontrolled diabetes mellitus.<sup>164</sup> COVID-19–associated rhino-orbital-cerebral mucormycosis (ROCM) emerged as a life-threatening complication during the pandemic. India was the worst hit and contributed to 81% of the cases of COVID-19–associated ROCM.<sup>165</sup> COVID-19 produces a hypoxic environment with high serum glucose and ferritin levels, attenuated phagocytic activity of leukocytes, and immunosuppression due the viral infection and corticosteroid use in severe cases. These were risk factors for the fungal spores to germinate and proliferate in the host body.<sup>165</sup>

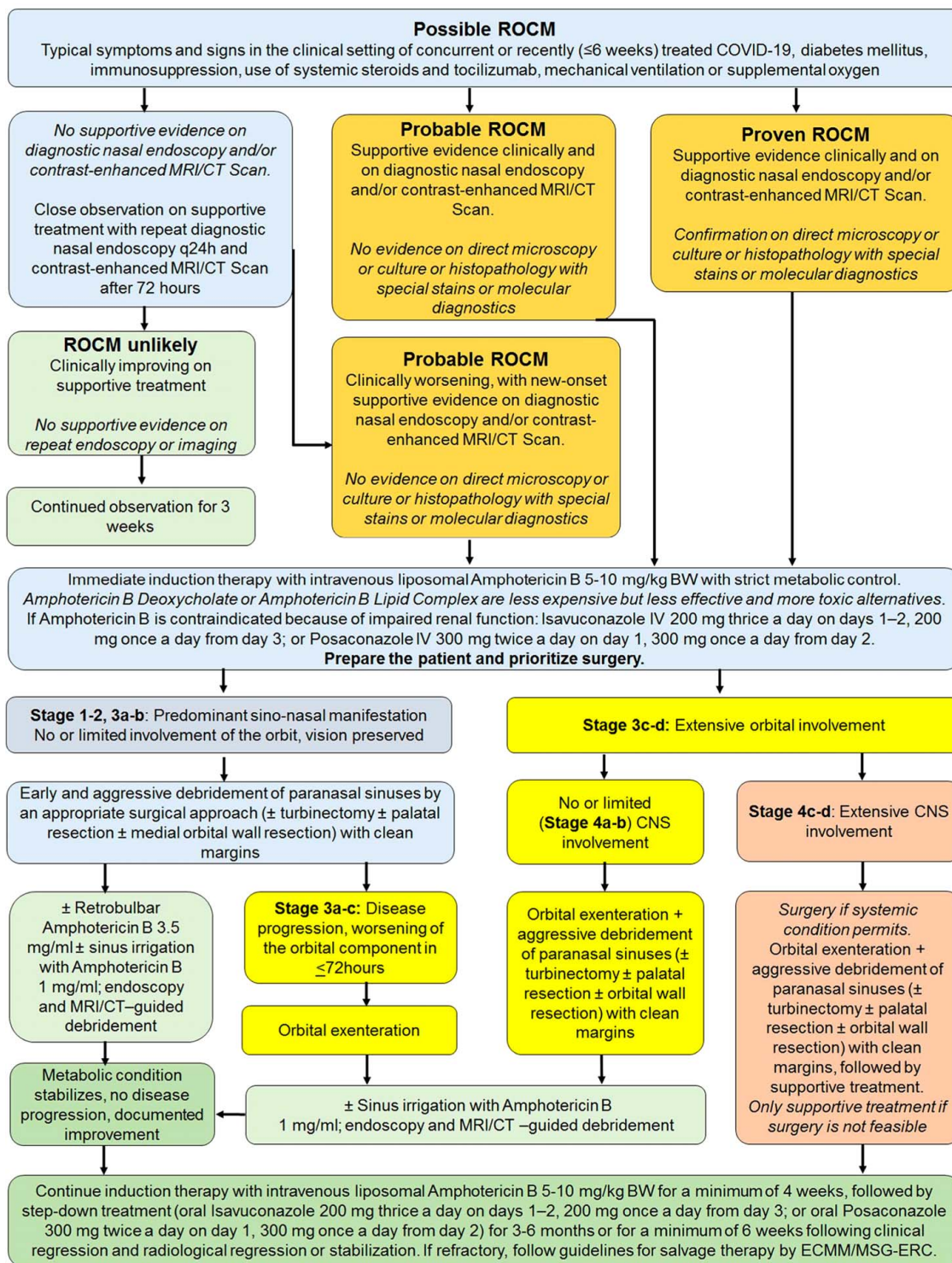
The diagnosis of COVID-19-associated ROCM is based on clinical, radiologic, and mycological features (Fig. 4). A staging system has been proposed by Honavar<sup>166</sup> to triage patients with ROCM and guide ophthalmologists in the management of this group of patients (Fig. 5).

The mean age of patients of COVID-19–associated ROCM was 52–55 years, with male predominance (71%–76%).<sup>164,165</sup> According to the study by Sen et al,<sup>164,165</sup> 87% of the patients with COVID-19 who developed ROCM received systemic corticosteroids and 78% had diabetes mellitus at presentation. Inappropriate use of corticosteroids at high doses or extended durations, and diabetes mellitus are independent risk factors for the development of ROCM.<sup>165</sup> The median time for ROCM from the diagnosis of COVID-19 was 8–13 days.<sup>162,165</sup> Interestingly, delayed presentation of ROCM (> 14 d after diagnosis of COVID-19) was seen in 44% of the patients.<sup>165</sup> It is, therefore, important to follow patients with COVID-19 even after recovery for delayed complications.

Results of a multicenter collaborative study undertaken in India which included 2826 patients of COVID-19–associated ROCM from January 2020 to May 2021 showed that the most common symptoms of ROCM were orbital/ facial pain (23%), orbital/ facial edema (21%), and vision loss (19%; Fig. 6). The majority of the patients (72%) had stage 3 orbital disease at presentation.<sup>165</sup> Early initiation of treatment with IV liposomal amphotericin B, prolonged step-down therapy with oral Posaconazole or isavuconazole for 3–6 months, radical sinus debridement, orbital exenteration, and intraorbital amphotericin B are essential. Orbital exenteration is performed for patients with no visual prognosis, extensive orbital involvement, apical involvement with no or minimal cavernous sinus extension, and diffuse loss of contrast enhancement in orbit.<sup>164,165</sup>

ROCM carries a grave prognosis in almost 40% of the patients despite prompt treatments.<sup>164</sup> In the study by Sen et al,<sup>165</sup> at a mean follow-up period of 14.4 ± 21.3 days, eye salvage was achieved in only 16% while the mortality rate was 14%. Mortality and disease progression were less in patients with ROCM with orbital involvement who were treated with

### Management Approach for Possible, Probable or Proven Rhino-Orbital-Cerebral Mucormycosis (ROCM)



**FIGURE 4.** Proposed diagnosis and management algorithm for ROCM (reproduced with permission from Honavar SG. Code Mucor: Guidelines for the Diagnosis, Staging, and Management of Rhino-Orbital-Cerebral Mucormycosis in the Setting of COVID-19. Indian Journal of Ophthalmology. 2021 Jun;69:1361-5). COVID-19 indicates coronavirus disease 2019; ROCM, rhino-orbital-cerebral mucormycosis.

orbital exenteration compared with those without exenteration (22% vs 33%,  $P = 0.008$ ). For patients with CNS involvement (stage 4), the outcome was better with surgical intervention versus no surgical intervention: sinus surgery (death 39% vs 67%,  $P < 0.05$ ) and orbital exenteration (death 39% vs 52%,  $P = 0.01$ ). Of the 137 patients with  $> 3$  weeks follow-up, 88% had stable/regressed disease, and orbital

exenteration did not significantly alter the outcome in patients with stage 3c and 3d disease ( $P = 0.24$ ).<sup>165</sup> In the study by Dave and colleagues, at a mean follow-up of 5.6 months, the mortality rate was 34% and CNS involvement was significantly correlated with mortality ( $P = 0.03$ ). Uncontrolled diabetes ( $P = 0.001$ ), involvement of orbital apex ( $P = 0.04$ ), CNS involvement ( $P = 0.04$ ), and steroid use

Proposed Staging of Rhino-Orbital-Cerebral Mucormycosis (ROCM)

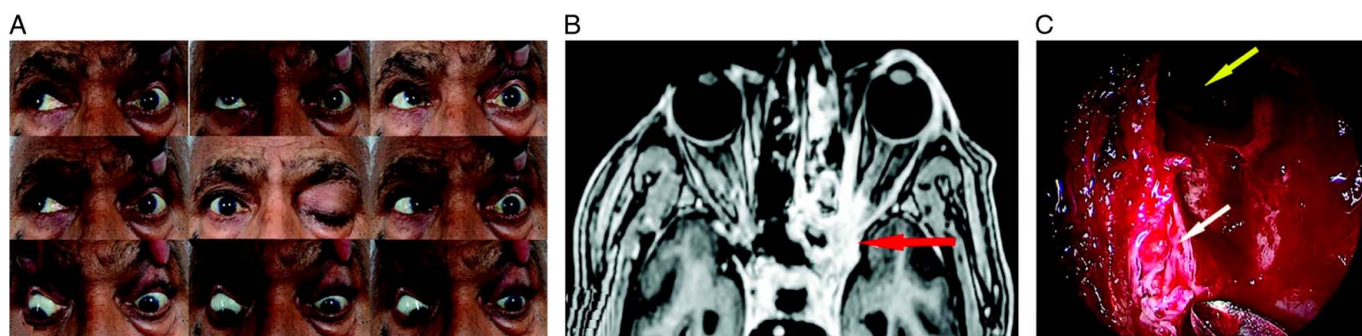
Staging of Rhino-Orbito-Cerebral Mucormycosis	Symptoms	Signs	Primary Assessment	Confirmation of Diagnosis
<b>Stage 1: Involvement of the nasal mucosa</b> 1a: Limited to the middle turbinate 1b: Involvement of the inferior turbinate or ostium of the nasolacrimal duct 1c: Involvement of the nasal septum 1d: Bilateral nasal mucosal involvement	Nasal stuffiness, nasal discharge, foul smell, epistaxis	Foul-smelling sticky mucoid or black-tinged, or granular or haemorrhagic nasal discharge, nasal mucosal inflammation, erythema, violaceous or blue discoloration, pale ulcer, anaesthesia, ischemia, eschar	Diagnostic nasal endoscopy, Contrast-enhanced MRI (preferred) or CT-scan	Deep nasal swab or endoscopy-guided nasal swab or nasal mucosal biopsy for direct microscopy, culture and molecular diagnostics; nasal mucosal biopsy for rapid histopathology with special stains
<b>Stage 2: Involvement of paranasal sinuses</b> 2a: One sinus 2b: Two ipsilateral sinuses 2c: > Two ipsilateral sinuses and/or palate/oral cavity 2d: Bilateral paranasal sinus involvement or involvement of the zygoma or mandible	Symptoms in Stage 1 + facial pain, facial edema, dental pain, systemic symptoms (malaise, fever)	Signs in Stage 1 + unilateral or bilateral, localized or diffuse facial edema, edema localized over the sinuses, localized sinus tenderness	Diagnostic nasal endoscopy, Contrast-enhanced MRI (preferred) or CT-scan	Same as Stage 1 + sinus biopsy for direct microscopy, culture and molecular diagnostics and rapid histopathology
<b>Stage 3: Involvement of the orbit</b> 3a: Nasolacrimal duct, medial orbit, vision unaffected 3b: Diffuse orbital involvement (>1 quadrant or >2 structures), vision unaffected 3c: Central retinal artery or ophthalmic artery occlusion or superior ophthalmic vein thrombosis; involvement of the superior orbital fissure, inferior orbital fissure, orbital apex, loss of vision 3d: Bilateral orbital involvement	Symptoms in Stage 1 and 2 + pain in the eye, proptosis, ptosis, diplopia, loss of vision, infraorbital and facial V1 V2 nerve anesthesia	Signs in Stage 1 and 2 + conjunctival chemosis, isolated ocular motility restriction, ptosis, proptosis, infraorbital nerve anesthesia, central retinal artery occlusion, features of ophthalmic artery occlusion and superior ophthalmic vein thrombosis. V1 and V2 nerve anesthesia, and features of III, IV and VI nerve palsy indicating orbital apex/superior orbital fissure involvement.	Diagnostic nasal endoscopy, Contrast-enhanced MRI (preferred) or CT-scan	Same as Stage 2 + orbital biopsy if indicated and if feasible (if the disease is predominantly orbital) for direct microscopy, culture and molecular diagnostics and rapid histopathology
<b>Stage 4: Involvement of the CNS</b> 4a: Focal or partial cavernous sinus involvement and/or involvement of the cribriform plate 4b: Diffuse cavernous sinus involvement and/or cavernous sinus thrombosis 4c: Involvement beyond the cavernous sinus, involvement of the skull base, internal carotid artery occlusion, brain infarction 4d: Multifocal or diffuse CNS disease	Symptoms in Stage 1 to 3 + bilateral proptosis, paralysis, altered consciousness, focal seizures	Signs in Stage 1-3 (some features overlap with Stage 3) + V1 and V2 nerve anesthesia, ptosis, and features of III, IV and VI nerve palsy indicate cavernous sinus involvement. Bilaterality of these signs with contralateral orbital edema with no clinico-radiological evidence of paranasal sinus or orbital involvement on the contralateral side indicate cavernous sinus thrombosis. Hemiparesis, altered consciousness and focal seizures indicate brain invasion and infarction.	Diagnostic endoscopy, Contrast-enhanced CT Scan, MRI (preferred)	Same as Stage 3

FIGURE 5. Proposed staging system for COVID-19-associated ROCM (reproduced with permission from Honavar SG. Code Mucor: Guidelines for the Diagnosis, Staging, and Management of Rhino-Orbito-Cerebral Mucormycosis in the Setting of COVID-19. Indian Journal of Ophthalmology. 2021;69:1361-5). COVID-19 indicates coronavirus disease 2019; ROCM, rhino-orbital-cerebral mucormycosis.

( $P < 0.0001$ ) were associated with unfavorable outcomes. The usage of tocilizumab with an unfavorable prognosis did not reach statistical significance. Orbital exenteration was associated with higher mortality ( $P = 0.08$ ) but the authors caution that this result may be confounded by the patients with the most severe disease and at risk of dying undergoing exenteration.<sup>162</sup>

**ORBITAL ADVERSE REACTIONS TO CORONAVIRUS DISEASE 2019 VACCINATION**

Orbital adverse reactions to COVID-19 vaccination were less commonly reported than other ophthalmic adverse reactions. This section summarizes the important and unique orbital adverse events suspected to occur after COVID-19 vaccination.



**FIGURE 6.** Stage 4a ROCM (A) Clinical photograph showing restriction of ocular movements in all gazes in the left eye. B, Axial MRI (T1) of the orbit and brain showing diffuse orbital involvement along with focal cavernous sinus involvement (red arrow). C, Endoscopy picture showing eroded left cribriform plate (white arrow) with dural defect (yellow arrow). Endoscopy image provided by Sandeep Karmarkar [reproduced with permission from Sen M, Honavar SG, Bansal R, Sengupta S, Rao R, Kim U, Sharma M, Sachdev M, Grover AK, Surve A, Budharapu A. Epidemiology, clinical profile, management, and outcome of COVID-19-associated ROCM in 2826 patients in India—Collaborative OPAI-IJO Study on Mucormycosis in COVID-19 (COSMIC), Report 1. Indian Journal of Ophthalmology. 2021 Jul;69(7):1670.]<sup>113</sup> COVID-19 indicates coronavirus disease 2019; ROCM, rhino-orbital-cerebral mucormycosis.

### Dacryoadenitis

Dacryoadenitis after COVID-19 vaccination has also been reported in 3 patients with a mean age of 33 years (median = 32, 14–53 y).<sup>71,73,152</sup> The duration from the COVID-19 vaccination to the development of dacryoadenitis was found to be highly variable ranging from a few hours to 7 months.<sup>71,73,152</sup> The mRNA vaccines (n = 2) and the viral vector–based vaccine (n = 1) were implicated in these reports.<sup>71,73,152</sup> The causal relationship is supported by the temporal association. Molecular mimicry between ocular tissue and virus/vaccine proteins leading to an immunologic response is the most accepted mechanism.<sup>167</sup>

### Orbital Cellulitis and Inflammatory Conditions

Hári-Kovács et al<sup>168</sup> reported a case of unilateral orbital cellulitis without sinusitis developing in a 72-year-old man with diabetes and hypertension 9 days after the second dose of the CoronaVac vaccine. The orbital signs resolved rapidly with systemic steroids administered under antibiotic cover. There was no evidence of sinusitis in this case unlike the published reports of orbital cellulitis after COVID-19.<sup>168</sup> Delayed development of orbital symptoms (> 1 wk and complete resolution with steroids point towards a hypersensitivity reaction to SARS-CoV-2 vaccine).<sup>168</sup> Chuang et al<sup>169</sup> reported a case of Tolosa-Hunt syndrome developing 5 days after receiving the BNT162b2 mRNA-based vaccine. Tolosa-Hunt syndrome is a granulomatous inflammatory process involving the cavernous sinus and remains a diagnosis of exclusion. The patient presented with severe left-sided headache, progressive proptosis, decreased visual acuity, relative afferent pupillary defect, and complete ophthalmoplegia. The patient was initially treated with IV antibiotics, followed by IVMP and then oral corticosteroids once the infection was excluded.<sup>170</sup> Superior ophthalmic vein thrombosis has been reported after the viral vector–based ChAdOx1 nCoV-19 vaccine.<sup>19,170,171</sup> Headache, proptosis, ophthalmoplegia, diplopia, and diminished vision are the common presenting features and patients can have thrombocytopenia, high D-dimer levels, and platelet factor 4 antibodies.<sup>170,171</sup> Thrombotic thrombocytopenia after COVID-19 vaccination is an immune-mediated complication.<sup>172</sup> A multicentric cohort study by Perry and colleagues found that patients with vaccine-induced immune thrombotic thrombocytopenia–related cerebral venous sinus thrombosis were more likely to have received the ChAdOx1 vaccine, younger, without systemic risk factors, had more extensive venous thrombosis, intracranial

hemorrhage and more concurrent extracranial and arterial thrombosis with worse outcome as compared with patients without vaccine-induced immune thrombotic thrombocytopenia-associated cerebral venous sinus thrombosis.<sup>172,173</sup> The outcome is better with judicious use of IVIGs, systemic corticosteroids, and non-heparin anticoagulants.<sup>173</sup>

### CONCLUSIONS

The ophthalmology community has been witnessing the continuously advancing understanding and knowledge of the ophthalmic manifestations of COVID-19.<sup>174,175</sup> Nasiri et al estimated the latest pooled prevalence of ophthalmic manifestations in COVID-19 patients to be 11.03%. Although evidence of a causal relationship between the ophthalmic symptoms and COVID-19 infection remains elusive, it has become apparent to clinicians that COVID-19 has an association with ophthalmic complications and ought to be considered as an important differential diagnosis in most common ophthalmic disorders in the postpandemic era. Future studies focusing on the pathogenesis and molecular mechanisms to establish a clear link between SARS-CoV-2 infection and the development of its ophthalmic manifestations would certainly be warranted. Understanding the nature of the disease and its pathophysiology would guide clinicians not only in the treatment but also in the development of prophylaxis against certain complications, such as ophthalmic vascular occlusions, which may benefit from early anticoagulation in selected COVID-19 cases with high thrombotic risks. Meanwhile, vaccination has proven to be an effective strategy in mitigating the impact of COVID-19, in particular among high-risk populations. It is imperative for the general public and clinicians to be aware that given the nascent nature of COVID-19 vaccines and the evolving data on their adverse effects, there is at present no causality established in the current literature. It is noteworthy that as of September 2023, according to WHO, there were 173 doses of COVID-19 vaccine administered per 100 population. Globally, over 13 billion doses of COVID-19 vaccinations have been delivered. In this perspective, the incidence of adverse events after vaccination is remarkably low and certainly outweighed by the enormous public health benefits of the massive vaccination campaigns worldwide. We hope with the foundational information provided in this review, the ophthalmology community will be

empowered to enter the postpandemic world and continue advancing our knowledge as a new chapter of the COVID-19 era unfolds.

## REFERENCES

1. Wan KH, Lin TPH, Ko CN, et al. Impact of COVID-19 on ophthalmology and future practice of medicine. *Asia Pac J Ophthalmol (Phila)*. 2020;9:279–280.
2. World Health Organization. WHO Coronavirus (COVID-19) dashboard. Published 2023. Accessed October 10. <https://covid19.who.int>
3. Wong RLM, Ting DSW, Wan KH, et al. COVID-19: ocular manifestations and the APAO prevention guidelines for ophthalmic practices. *Asia Pac J Ophthalmol (Phila)*. 2020;9:281–284.
4. Chen L, Deng C, Chen X, et al. Ocular manifestations and clinical characteristics of 535 cases of COVID-19 in Wuhan, China: a cross-sectional study. *Acta Ophthalmol*. 2020;98:e951–e959.
5. Lin TPH, Ko CN, Zheng K, et al. COVID-19: update on its ocular involvements, and complications from its treatments and vaccinations. *Asia Pac J Ophthalmol (Phila)*. 2021;10:521–529.
6. Zhang X, Chen X, Chen L, et al. The evidence of SARS-CoV-2 infection on ocular surface. *Ocul Surf*. 2020;18:360–362.
7. Ong J, Tan G, Ang M, et al. Digital advancements in retinal models of care in the post-COVID-19 lockdown era. *Asia Pac J Ophthalmol (Phila)*. 2022;11:403–407.
8. Lai KE, Ko MW. Can Tele-Neuro-Ophthalmology Be Useful Beyond the Pandemic? *Curr Neurol Neurosci Rep*. 2023;23:15–23.
9. Kim SE, Logeswaran A, Kang S, et al. Digital transformation in ophthalmic clinical care during the COVID-19 pandemic. *Asia Pac J Ophthalmol (Phila)*. 2021;10:381–387.
10. Chourasia S, Pandey SM, Murtaza Q, et al. Redefining industry 5.0 in ophthalmology and digital metrology: a global perspective. *Mapan J Metrol Soc India*. 2023;38:1–19.
11. Sim SS, Yip MY, Wang Z, et al. Digital technology for AMD management in the post-COVID-19 new normal. *Asia Pac J Ophthalmol (Phila)*. 2021;10:39–48.
12. Valentim CC, Muste JC, Iyer AI, et al. Characterization of ophthalmology virtual visits during the COVID-19 pandemic. *Eye*. 2023;37:332–337.
13. Zhou L, Xu Z, Castiglione GM, et al. ACE2 and TMPRSS2 are expressed on the human ocular surface, suggesting susceptibility to SARS-CoV-2 infection. *Ocul Surf*. 2020;18:537–544.
14. Sindhuja K, Lomi N, Asif MI, et al. Clinical profile and prevalence of conjunctivitis in mild COVID-19 patients in a tertiary care COVID-19 hospital: a retrospective cross-sectional study. *Indian J Ophthalmol*. 2020;68:1546–1550.
15. Al-Namaeh M. Ocular manifestations of COVID-19. *Ther Adv Ophthalmol*. 2022;14:25158414221083374.
16. Rokohl AC, Grajewski RS, Matos PAW, et al. Ocular involvement in COVID-19: conjunctivitis and more. *Klin Monbl Augenheilkd*. 2021;238:555–560.
17. Navel V, Chiambaretta F, Dutheil F. Haemorrhagic conjunctivitis with pseudomembranous related to SARS-CoV-2. *Am J Ophthalmol Case Rep*. 2020;19:100735.
18. Wan Y, Shang J, Graham R, et al. Receptor recognition by the novel coronavirus from Wuhan: an analysis based on decade-long structural studies of SARS coronavirus. *J Virol*. 2020;94:e00127–20.
19. Sen M, Honavar SG, Sharma N, et al. COVID-19 and eye: a review of ophthalmic manifestations of COVID-19. *Indian J Ophthalmol*. 2021;69:488–509.
20. Cheema M, Aghazadeh H, Nazari S, et al. Keratoconjunctivitis as the initial medical presentation of the novel coronavirus disease 2019 (COVID-19). *Can J Ophthalmol*. 2020;55:e125–e129.
21. Majtanova N, Kriskova P, Keri P, et al. Herpes simplex keratitis in patients with SARS-CoV-2 infection: a series of five cases. *Medicina (Kaunas)*. 2021;57:412.
22. Mangana CM, Kargacin AB, Barraquer RI. Episcleritis as an ocular manifestation in a patient with COVID-19. *Acta Ophthalmol*. 2020;98:e1056–e1057.
23. Otaif W, Al Somali AI, Al Habash A. Episcleritis as a possible presenting sign of the novel coronavirus disease: a case report. *Am J Ophthalmol Case Rep*. 2020;20:100917.
24. Bostanci Ceran B, Ozates S. Ocular manifestations of coronavirus disease 2019. *Graefes Arch Clin Exp Ophthalmol*. 2020;258:1959–1963.
25. Feizi S, Meshksar A, Naderi A, et al. Anterior scleritis manifesting after coronavirus disease 2019: a report of two cases. *Cornea*. 2021;40:1204–1206.
26. Adenwala A, Shetty R, D'Souza S, et al. Nodular scleritis—a rare presentation of COVID-19 and variation with testing. *Am J Ophthalmol Case Rep*. 2022;25:101396.
27. Sanjay S, Handa A, Kawali A, et al. Scleritis and episcleritis following coronavirus disease (COVID-19) vaccination. *Ocul Immunol Inflamm*. 2023;31:1184–1190.
28. Wasser LM, Roditi E, Zadok D, et al. Keratoplasty rejection after the BNT162b2 messenger RNA vaccine. *Cornea*. 2021;40:1070–1072.
29. Phylactou M, Li JO, Larkin DFP. Characteristics of endothelial corneal transplant rejection following immunisation with SARS-CoV-2 messenger RNA vaccine. *Br J Ophthalmol*. 2021;105:893–896.
30. Ralliss KI, Fausto R, Ting DSJ, et al. Manifestation of Herpetic Eye Disease after COVID-19 Vaccine: A UK Case Series. *Ocul Immunol Inflamm*. 2022;30:1136–1141.
31. Lim TH, Wai YZ, Chong JC. Unilateral frosted branch angiitis in a human immunodeficiency virus-infected patient with concurrent COVID-19 infection: a case report. *J Med Case Rep*. 2021;15:267.
32. Jordan CA, Townend S, Allen N, et al. Navigating coronavirus disease 2019 vaccination and uveitis: identifying the rates and risk of recurrent uveitis after coronavirus disease vaccination. *Ophthalmology*. 2023;130:501–508.
33. Testi I, Brandao-de-Resende C, De-La-Torre A, et al. Ocular inflammatory events following COVID-19 vaccination in the paediatric population: a multinational case series. *Ocul Immunol Inflamm*. 2023;1–6.
34. Sheng Q, Sun Y, Zhai R, et al. Posner-Schlossman syndrome relapse following inactivated COVID-19 vaccination in China. *Front Public Health*. 2023;10:1051378.
35. Igarashi A, Shimizu T, Takeda M, et al. Incidence of Graft Rejection in Descemet Membrane Endothelial Keratoplasty After COVID-19 mRNA Vaccination. *Cornea*. 2023;42:1286–1292.
36. Ghiasian L, Pourmousa Z, Hadi Y, et al. Corneal Allograft Endothelial Rejection after Sinopharm COVID-19 Vaccination; Report of Six Cases. *Semin Ophthalmol*. 2023;38. doi:10.1080/08820538.2023.2169579
37. Busin M, Zauli G, Pellegrini M, et al. COVID-19 Vaccination may not increase rates of corneal graft rejection. *Cornea*. 2022;41:1536–1538.

38. Roberts HW, Wilkins MR, Malik M, et al. A lack of an association between COVID-19 vaccination and corneal graft rejection: results of a large multi-country population-based study. *Eye (Lond)*. 2023;37:2316–2319.
39. Dag Y, Acet Y. Evaluation of the effect of infection and immunity on the tear film by Scheimpflug-Placido disc topography- a case-control study. *Photodiagnosis Photodyn Ther*. 2023;41:103216.
40. Kuziez L, Eleiwa TK, Chauhan MZ, et al. Corneal adverse events associated with SARS-CoV-2/COVID-19 vaccination: a systematic review. *Vaccines (Basel)*. 2023;11:166.
41. Swarup R, Mehta S. DALK rejection following vaccination against SARS-CoV-2: 2 case reports. *Eur J Ophthalmol*. 2023;33:11206721231158672.
42. Gouvea L, Slomovic AR, Chan CC. Smoldering<sup>™</sup> rejection of keratolimbal allograft. *Cornea*. 2022;41:651–653.
43. de la Presa M, Govil A, Chamberlain WD, et al. Acute corneal epithelial rejection of LR-CLAL after SARS-CoV-2 vaccination. *Cornea*. 2022;41:252–253.
44. Veritti D, Sarao V, Bandello F, et al. Infection control measures in ophthalmology during the COVID-19 outbreak: a narrative review from an early experience in Italy. *Eur J Ophthalmol*. 2020;30:621–628.
45. Bertoli F, Veritti D, Danese C, et al. Ocular findings in COVID-19 patients: a review of direct manifestations and indirect effects on the eye. *J Ophthalmol*. 2020;2020:4827304–9.
46. Teo KY, Invernizzi A, Staurenghi G, et al. COVID-19-related retinal micro-vasculopathy—a review of current evidence. *Am J Ophthalmol*. 2022;235:98–110.
47. Banderas Garcia S, Aragon D, Azarfane B, et al. Persistent reduction of retinal microvascular vessel density in patients with moderate and severe COVID-19 disease. *BMJ Open Ophthalmol*. 2022;7:e000867.
48. Yeo S, Kim H, Lee J, et al. Retinal vascular occlusions in COVID-19 infection and vaccination: a literature review. *Graefes Arch Clin Exp Ophthalmol*. 2023;261:1793–1808.
49. Napal B, Garcia-Palacios JD, Gonzalez-Mesones B, et al. Retinal vein occlusion in the general population after COVID-19 vaccination and infection. *Med Clin (Barc)*. 2023;161:231–237.
50. Premi E, Acampora R, Salmi D, et al. Clinical and diagnostic findings of acute macular neuroretinopathy and paracentral acute middle maculopathy in the COVID-19 Era. *Ophthalmologica*. 2023;246:181–191.
51. Dutta Majumder P, Agarwal A. Acute macular neuroretinopathy and paracentral acute middle maculopathy during SARS-CoV-2 infection and vaccination. *Vaccines (Basel)*. 2023;11:474.
52. Mohd-Alif WM, Nur-Athirah A, Hanapi MS, et al. Bilateral and multiple central serous chorioretinopathy following COVID-19 infection: a case report and literature review. *Cureus*. 2022;14:e23246.
53. Markan A, Dogra M, Katoch D, et al. Endogenous endophthalmitis in COVID-19 patients: a case series and literature review. *Ocul Immunol Inflamm*. 2023;31:1191–1197.
54. Agarwal M, Sachdeva M, Pal S, et al. Endogenous endophthalmitis a complication of COVID-19 pandemic: a case series. *Ocul Immunol Inflamm*. 2021;29:726–729.
55. Shah KK, Venkatramani D, Majumder PD. A case series of presumed fungal endogenous endophthalmitis in post COVID-19 patients. *Indian J Ophthalmol*. 2021;69:1322–1325.
56. Shroff D, Narula R, Atri N, et al. Endogenous fungal endophthalmitis following intensive corticosteroid therapy in severe COVID-19 disease. *Indian J Ophthalmol*. 2021;69:1909–1914.
57. Bilgic A, Sudhalkar A, Gonzalez-Cortes JH, et al. Endogenous endophthalmitis in the setting of COVID-19 infection: a case series. *Retina*. 2021;41:1709–1714.
58. Bohler AD, Strom ME, Sandvig KU, et al. Acute macular neuroretinopathy following COVID-19 vaccination. *Eye (Lond)*. 2022;36:644–645.
59. Mambretti M, Huemer J, Torregrossa G, et al. Acute macular neuroretinopathy following coronavirus disease 2019 vaccination. *Ocul Immunol Inflamm*. 2021;29:730–733.
60. Bhavsar KV, Lin S, Rahimy E, et al. Acute macular neuroretinopathy: A comprehensive review of the literature. *Surv Ophthalmol*. 2016;61:538–565.
61. Pichi F, Aljneibi S, Neri P, et al. Association of ocular adverse events with inactivated COVID-19 vaccination in patients in Abu Dhabi. *JAMA Ophthalmol*. 2021;139:1131–1135.
62. Malerbi FK, Schoeps VA, T F Matos K. Paracentral acute middle maculopathy in Susac syndrome after dual exposure to SARS-CoV-2 antigen. *BMJ Case Rep*. 2022;15:e247159.
63. Vinzamuri S, Pradeep TG, Kotian R. Bilateral paracentral acute middle maculopathy and acute macular neuroretinopathy following COVID-19 vaccination. *Indian J Ophthalmol*. 2021;69:2862–2864.
64. Yasaka Y, Hasegawa E, Keino H, et al. A multicenter study of ocular inflammation after COVID-19 vaccination. *Jpn J Ophthalmol*. 2023;67:14–21.
65. Maleki A, Look-Why S, Manhapra A, et al. COVID-19 recombinant mRNA vaccines and serious ocular inflammatory side effects: real or coincidence? *J Ophthalmic Vis Res*. 2021;16:490–501.
66. Fowler N, Mendez Martinez NR, Pallares BV, et al. Acute-onset central serous retinopathy after immunization with COVID-19 mRNA vaccine. *Am J Ophthalmol Case Rep*. 2021;23:101136.
67. Mechleb N, Khoueir Z, Assi A. Bilateral multifocal central serous retinopathy following mRNA COVID-19 vaccine. *J Fr Ophthalmol*. 2022;45:603–607.
68. Anthony E, Rajamani A, Baskaran P, et al. Vogt Koyanagi Harada disease following a recent COVID-19 infection. *Indian J Ophthalmol*. 2022;70:670–672.
69. Santamaria A, Chang J, Savarain C. SARS-CoV-2 among the potential viral triggers for Vogt-Koyanagi-Harada disease: first case report and literature review. *Ocul Immunol Inflamm*. 2022;30:1869–1875.
70. Boz AAE, Atum M, Cakir B, et al. Outcomes of the ophthalmic examinations in patients infected by SARS-CoV-2. *Ocul Immunol Inflamm*. 2021;29:638–641.
71. Goyal M, Murthy SI, Annum S. Retinal manifestations in patients following COVID-19 infection: a consecutive case series. *Indian J Ophthalmol*. 2021;69:1275–1282.
72. Iriqat S, Yousef Q, Ereqat S. Clinical profile of COVID-19 patients presenting with uveitis - A short case series. *Int Med Case Rep J*. 2021;14:421–427.
73. Miller DC, Sun Y, Chen EM, et al. The association between noninfectious uveitis and coronavirus disease 2019 outcomes: an analysis of United States claims-based data. *Ophthalmology*. 2022;129:334–343.
74. Ganesh SK, Mohanan-Earatt A. An analysis of the clinical profile of patients with uveitis following COVID-19 infection. *Indian J Ophthalmol*. 2022;70:1000–1006.
75. Providencia J, Fonseca C, Henriques F, et al. Serpiginous choroiditis presenting after SARS-CoV-2 infection: a new immunological trigger? *Eur J Ophthalmol*. 2022;32:NP97–NP101.

76. Zhang Y, Stewart JM. Retinal and choroidal manifestations of COVID-19. *Curr Opin Ophthalmol*. 2021;32:536–540.
77. Gupta A, Dixit B, Stamoulas K, et al. Atypical bilateral acute retinal necrosis in a coronavirus disease 2019 positive immunosuppressed patient. *Eur J Ophthalmol*. 2022;32:NP94–NP96.
78. Mahendradas P, Hande P, Patil A, et al. Bilateral post-fever retinitis with retinal vascular occlusions following severe acute respiratory syndrome coronavirus (SARS-CoV2) infection. *Ocul Immunol Inflamm*. 2022;30:1715–1720.
79. Shahram F, Esalatmanesh K, Khabbazi A, et al. Coronavirus disease 2019 in patients with Behcet's disease: a report of 59 cases in Iran. *Clin Rheumatol*. 2022;41:1177–1183.
80. Rojas M, Herran M, Ramirez-Santana C, et al. Molecular mimicry and autoimmunity in the time of COVID-19. *J Autoimmun*. 2023;139:103070.
81. Ng SMS, Low R, Pak C, et al. The role of a multicentre data repository in ocular inflammation: the Ocular Autoimmune Systemic Inflammatory Infectious Study (OASIS). *Eye (Lond)*. 2023;37:3084–3096.
82. Minervina AA, Pogorelyy MV, Kirk AM, et al. SARS-CoV-2 antigen exposure history shapes phenotypes and specificity of memory CD8(+) T cells. *Nat Immunol*. 2022;23:781–790.
83. Chen Y, Xu Z, Wang P, et al. New-onset autoimmune phenomena post-COVID-19 vaccination. *Immunology*. 2022;165:386–401.
84. Testi I, Brandao-de-Resende C, Agrawal R, et al Group C-VOIES. Ocular inflammatory events following COVID-19 vaccination: a multinational case series. *J Ophthalmic Inflamm Infect*. 2022;12:4.
85. Cherif YYS, Djeflal C, Abu Serhan H, et al. The characteristics of COVID-19 vaccine-associated uveitis: a summative systematic review. *Vaccines (Basel)*. 2022;11:69.
86. Habet-Wilner Z, Neri P, Okada AA, et al. COVID vaccine-associated uveitis. *Ocul Immunol Inflamm*. 2023;31:1198–1205.
87. Kumar A, Miller DC, Sun Y, et al. Risk of noninfectious uveitis after coronavirus disease 2019 vaccination in the United States claims database. *Ophthalmology*. 2023;130:1269–1278.
88. Singh RB, Parmar UPS, Kahale F, et al. Vaccine-associated uveitis after COVID-19 vaccination: vaccine adverse event reporting system database analysis. *Ophthalmology*. 2023;130:179–186.
89. Zhong Z, Wu Q, Lai Y, et al. Risk for uveitis relapse after COVID-19 vaccination. *J Autoimmun*. 2022;133:102925.
90. Zhong Z, Wu Q, Lai Y, et al. Early vs deferred non-messenger RNA COVID-19 vaccination among Chinese patients with a history of inactive uveitis: a randomized clinical trial. *JAMA Netw Open*. 2023;6:e2255804.
91. Tisdale AK, Dinkin M, Chwalisz BK. Afferent and efferent neuro-ophthalmic complications of coronavirus disease 19. *J Neuroophthalmol*. 2021;41:154–165.
92. Petzold A. Neuro-ophthalmic implications of severe acute respiratory syndrome coronavirus 2 (SARS-CoV-2) related infection and vaccination. *Asia Pac J Ophthalmol (Phila)*. 2022;11:196–207.
93. Gilardi M, Cortese A, Ferraro E, et al. MOG-IgG positive optic neuritis after SARS-CoV-2 infection. *Eur J Ophthalmol*. 2023;33:NP87–NP90.
94. Jossy A, Jacob N, Sarkar S, et al. COVID-19-associated optic neuritis - a case series and review of literature. *Indian J Ophthalmol*. 2022;70:310–316.
95. Beck RW, Cleary PA, Anderson MM Jr, et al. A randomized, controlled trial of corticosteroids in the treatment of acute optic neuritis. The Optic Neuritis Study Group. *N Engl J Med*. 1992;326:581–588.
96. Kivanany PB, Raviskanthan S, Mortensen PW, et al. Antiaquaporin 4-related optic neuritis and myelitis post-COVID-19 infection. *J Neuro-ophthalmol*. 2022;42:e571–e573.
97. Rojas-Correa DX, Reche-Sainz JA, Insausti-Garcia A, et al. Post-COVID-19 myelin oligodendrocyte glycoprotein antibody-associated optic neuritis. *Neuroophthalmology*. 2022;46:115–121.
98. Insausti-Garcia A, Reche-Sainz JA, Ruiz-Arranz C, et al. Papillophlebitis in a COVID-19 patient: inflammation and hypercoagulable state. *Eur J Ophthalmol*. 2022;32:NP168–NP172.
99. Rho J, Dryden SC, McGuffey CD, et al. A case of non-arteritic anterior ischemic optic neuropathy with COVID-19. *Cureus*. 2020;12:e11950.
100. Clarke KM, Riga V, Shirodkar AL, et al. Prone related bilateral anterior ischaemic optic neuropathy in a patient with COVID-19 related acute respiratory distress syndrome. *BMC Ophthalmol*. 2021;21:276.
101. Moschetta L, Fasolino G, Kuijpers RW. Non-arteritic anterior ischaemic optic neuropathy sequential to SARS-CoV-2 virus pneumonia: preventable by endothelial protection? *BMJ Case Rep*. 2021;14:e240542.
102. Hayreh SS. Ischemic optic neuropathy. *Prog Retin Eye Res*. 2009;28:34–62.
103. Chen AH, Pakravan M, Charoenkijajorn C, et al. Posterior ischemic optic neuropathy following recurrent COVID-19 in prior bilateral sequential nonarteritic anterior ischemic optic neuropathy. *J Neuro-ophthalmol*. 2022. doi: 10.1097/HEP.0000000000000520
104. Selvaraj V, Sacchetti D, Finn A, et al. Acute vision loss in a patient with COVID-19. *R I Med J (2013)*. 2020;103:37–38.
105. Khan AW, Ullah I, Khan KS. Ischemic stroke leading to bilateral vision loss in COVID-19 patient - a rare case report. *J Med Virol*. 2021;93:683–685.
106. Atum M, Demiryurek BE. Sudden bilateral vision loss in a COVID-19 patient: A case report. *Indian J Ophthalmol*. 2021;69:2227–2228.
107. Omari A, Kally P, Schimmel O, et al. Vision loss secondary to COVID-19-associated bilateral cerebral venous sinus thromboses. *Ophthalmic Plast Reconstr Surg*. 2022;38:e65–e67.
108. Conway EM, Mackman N, Warren RQ, et al. Understanding COVID-19-associated coagulopathy. *Nat Rev Immunol*. 2022;22:639–649.
109. Manganotti P, Pesavento V, Buoite Stella A, et al. Miller Fisher syndrome diagnosis and treatment in a patient with SARS-CoV-2. *J Neurovirol*. 2020;26:605–606.
110. Nishimoto Y, Odaka M, Hirata K, et al. Usefulness of anti-GQ1b IgG antibody testing in Fisher syndrome compared with cerebrospinal fluid examination. *J Neuroimmunol*. 2004;148:200–205.
111. Raghunathan V, Dhaliwal M, Singhi P, et al. Miller Fisher syndrome associated with COVID-19 infection. *Pediatr Neurol*. 2021;123:40.
112. Belghmaidi S, Nassih H, Boutgayout S, et al. Third cranial nerve palsy presenting with unilateral diplopia and strabismus in a 24-year-old woman with COVID-19. *Am J Case Rep*. 2020;21:e925897.
113. Ordas CM, Villaceros-Alvarez J, Pastor-Vivas AI, et al. Concurrent tonic pupil and trochlear nerve palsy in COVID-19. *J Neurovirol*. 2020;26:970–972.
114. Piazza F, Bozzali M, Morana G, et al. Early reversible leukoencephalopathy and unilateral sixth cranial nerve palsy in mild COVID-19 infection. *Neurol Sci*. 2021;42:4899–4902.
115. Costello F, Dalakas MC. Cranial neuropathies and COVID-19: neuro-tropism and autoimmunity. *Neurology*. 2020;95:195–196.
116. Lonardi V, Meneghesso D, Debertolis G, et al. Isolated third cranial nerve palsy and COVID-19 infection in a child. *Pediatr Neurol*. 2021;120:11.

117. Elenga N, Martin E, Gerard M, et al. Unilateral diplopia and ptosis in a child with COVID-19 revealing third cranial nerve palsy. *J Infect Public Health*. 2021;14:1198–1200.
118. Oliveira RMC, Santos DH, Olivetti BC, et al. Bilateral trochlear nerve palsy due to cerebral vasculitis related to COVID-19 infection. *Arg Neuropsiquiatr*. 2020;78:385–386.
119. Sriwastava S, Tandon M, Kataria S, et al. New onset of ocular myasthenia gravis in a patient with COVID-19: a novel case report and literature review. *J Neurol*. 2021;268:2690–2696.
120. Brossard-Barbosa N, Donaldson L, Margolin E. Seropositive ocular myasthenia gravis developing shortly after COVID-19 infection: report and review of the literature. *J Neuroophthalmol*. 2023;43:e235–e236.
121. Banerjee P, Hassan H, Alam MS. New-onset ocular myasthenia gravis following SARS-CoV-2 infection. *Oman J Ophthalmol*. 2023;16:187–188.
122. Restivo DA, Centonze D, Alesina A, et al. Myasthenia gravis associated with SARS-CoV-2 infection. *Ann Intern Med*. 2020;173:1027–1028.
123. Kaya Tutar N, Kale N, Tugcu B. Adie-Holmes syndrome associated with COVID-19 infection: A case report. *Indian J Ophthalmol*. 2021;69:773–774.
124. Gopal M, Ambika S, Padmalakshmi K. Tonic pupil following COVID-19. *J Neuroophthalmol*. 2021;41:e764–e766.
125. Feizi M, D RI, Tavakoli M. Neuro-ophthalmic manifestations of coronavirus disease 2019 and its vaccination: a narrative review. *J Ophthalmic Vis Res*. 2023;18:113–122.
126. Naor MS, Mathew PG, Sharon R. Transient Horner syndrome associated with COVID-19: a case report. *eNeurologicalSci*. 2021;25:100349.
127. Portela-Sanchez S, Sanchez-Soblechero A, Melgarejo Ojalora PJ, et al. Neurological complications of COVID-19 in hospitalized patients: the registry of a neurology department in the first wave of the pandemic. *Eur J Neurol*. 2021;28:3339–3347.
128. Sanguinetti SY, Ramdhani RA. Opsoclonus-Myoclonus-Ataxia syndrome related to the novel coronavirus (COVID-19). *J Neuroophthalmol*. 2021;41:e288–e289.
129. Wright D, Rowley R, Halks-Wellstead P, et al. Abnormal saccadic oscillations associated with severe acute respiratory syndrome coronavirus 2 encephalopathy and ataxia. *Mov Disord Clin Pract*. 2020;7:980–982.
130. Umamathi T, Quek WMJ, Yen JM, et al. Encephalopathy in COVID-19 patients; viral, parainfectious, or both? *eNeurologicalSci*. 2020;21:100275.
131. Hu B, Huang S, Yin L. The cytokine storm and COVID-19. *J Med Virol*. 2021;93:250–256.
132. Shemer A, Greenbaum A, Toledano A, et al. Optic neuritis after SARS-CoV-2 vaccination. *J Neuroophthalmol*. 2023;43:29–33.
133. Jun B, Fraunfelder FW. Atypical optic neuritis after inactivated influenza vaccination. *Neuroophthalmology*. 2018;42:105–108.
134. Roy M, Chandra A, Roy S, et al. Optic neuritis following COVID-19 vaccination: coincidence or side-effect?—a case series. *Indian J Ophthalmol*. 2022;70:679–683.
135. Tugizova M, Siegel DT, Huang S, et al. Case series: atypical optic neuritis after COVID-19 vaccination. *J Neuroophthalmol*. 2023;43:e120–e122.
136. Michaelson NM, Lam T, Malhotra A, et al. Miller-Fisher syndrome presenting after a second dose of Pfizer-BioNTech vaccination in a patient with resolved COVID-19: a case report. *J Clin Neuromuscul Dis*. 2021;23:113–115.
137. Abicic A, Sitas B, Adamec I, et al. New-onset ocular myasthenia gravis after booster dose of COVID-19 vaccine. *Cureus*. 2022;14:e27213.
138. Valsero Franco S, Fonollosa A. Ischemic optic neuropathy after administration of a SARS-CoV-2 vaccine: a report of 2 cases. *Am J Case Rep*. 2022;23:e935095.
139. Chung SA, Yeo S, Sohn SY. Nonarteritic anterior ischemic optic neuropathy following COVID-19 vaccination: a case report. *Korean J Ophthalmol*. 2022;36:168–170.
140. Moon Y, Jung JH, Shin HJ, et al. Non-arteritic ischemic optic neuropathy following COVID-19 vaccination in Korea: a case series. *J Korean Med Sci*. 2023;38:e95.
141. Terentes-Printzios D, Gardikioti V, Solomou E, et al. The effect of an mRNA vaccine against COVID-19 on endothelial function and arterial stiffness. *Hypertens Res*. 2022;45:846–855.
142. Cunha LP, Atalla A, de Melo Costa-Neto J, et al. Multiple attacks of transient monocular visual loss in a previously healthy man: a possible complication after COVID-19 vaccination? *Int J Retina Vitreous*. 2022;8:43.
143. Jumroendarasame C, Panyakorn S, Othong R, et al. Transient visual field loss after COVID-19 vaccination: experienced by ophthalmologist, case report. *Am J Ophthalmol Case Rep*. 2021;24:101212.
144. Che SA, Lee KY, Yoo YJ. Bilateral ischemic optic neuropathy from giant cell arteritis following COVID-19 vaccination. *J Neuroophthalmol*. 2023;43:e107–e108.
145. Liozon E, Parreau S, Filloux M, et al. Giant cell arteritis or polymyalgia rheumatica after influenza vaccination: a study of 12 patients and a literature review. *Autoimmun Rev*. 2021;20:102732.
146. Saffra NA, Emborgo TS, Kelman SE, et al. Presumed autoimmune optic neuropathy after Pfizer-BioNTech (BNT162b2) COVID-19 vaccine. *J Neuroophthalmol*. 2022. doi: 10.1097/HEP.0000000000000520
147. Dermarkarian CR, Chilakapati M, Hussein M, et al. Bilateral orbital inflammation in a 6-month-old with SARS-CoV-2 infection. *Orbit*. 2022;41:633–636.
148. Martinez Diaz M, Copete Piqueras S, Blanco Marchite C, et al. Acute dacryoadenitis in a patient with SARS-CoV-2 infection. *Orbit*. 2022;41:374–377.
149. Rodrigues G, Hiran H, Suprasanna K, et al. Ptosis and dacryoadenitis following COVID. *Clin Exp Optim*. 2023:1–3. doi: 10.1097/HEP.0000000000000520
150. Almater AI, Malaikah RH, Alzahrani S, et al. Presumed acute suppurative bacterial dacryoadenitis with concurrent severe acute respiratory syndrome coronavirus-2 infection. *Saudi J Ophthalmol*. 2021;35:266–268.
151. Murphy T, Raheem Abu Shanab A, Kang K, et al. Acute-onset dacryoadenitis following immunisation with mRNA COVID-19 vaccine. *BMJ Case Rep*. 2022;15:e248441.
152. Singh S, Gandhi A, Das S. Dacryoadenitis post COVID-19 infection and immunization. *Indian J Ophthalmol*. 2023;71:3100–3102.
153. Kase S, Ishida S. COVID-19-related chronic bilateral dacryoadenitis: a clinicopathological study. *JAMA Ophthalmol*. 2022;140:312–318.
154. Mears CJ, DeFlorio P, Murray B. Concurrent pansinusitis and orbital cellulitis complicated by extensive head and neck venous thrombosis in an unvaccinated adolescent patient with COVID-19: a case report. *J Emerg Med*. 2023;65:e31–e35.
155. Turbin RE, Wawrzusin PJ, Sakla NM, et al. Orbital cellulitis, sinusitis, and intracranial abnormalities in two adolescents with COVID-19. *Orbit*. 2020;39:305–310.



156. Carvalho VA, Verginio VEO, Brito GC, et al. Coronavirus disease 2019 as a possible cause of severe orbital cellulitis. *J Craniofac Surg*. 2021;32:e795–e798.
157. Shires CB, Klug T, Dryden S, et al. Unusual cause of acute sinusitis and orbital abscess in COVID-19 positive patient: case report. *Int J Surg Case Rep*. 2021;79:164–168.
158. LoBue SA, Park R, Giovane R, et al. Bilateral cavernous sinus thrombosis in presumed COVID-19 infection. *Cureus*. 2022;14:e31986.
159. Bagheri M, Jafari A, Jafari S. Orbital apex syndrome in COVID-19 patient, a case report. *Vis J Emerg Med*. 2021;23:101006.
160. Abdelkader M, Elshafei AMK, Nassar MM, et al. Combined endophthalmitis and orbital cellulitis in patients with coronavirus disease (COVID-19). *J Ophthalmic Inflamm Infect*. 2021;11:27.
161. Abdul-Kadir MA, Rosli AH. Orbital cellulitis complicated with subperiosteal abscess following post-nasopharyngeal swab for COVID-19: a case report. *Clin Case Rep*. 2023;11:e7324.
162. Cantarella G, Nava N, Pirondini C, et al. Misdirection of a nasopharyngeal SARS-CoV-2 swab: an unexpected complication. *Otolaryngol Case Rep*. 2022;24:100439.
163. Reed W, Okafor S, Cheng J. Pediatric COVID-19 associated acute rhinosinusitis and periorbital abscess: a case report. *Otolaryngol Case Rep*. 2022;24:100461.
164. Dave TV, Gopinathan Nair A, Hegde R, et al. Clinical presentations, management and outcomes of rhino-orbital-cerebral mucormycosis (ROCM) following COVID-19: a multi-centric study. *Ophthalmic Plast Reconstr Surg*. 2021;37:488–495.
165. Sen M, Honavar SG, Bansal R, et al. Epidemiology, clinical profile, management, and outcome of COVID-19-associated rhino-orbital-cerebral mucormycosis in 2826 patients in India - collaborative OPAI-IJO study on mucormycosis in COVID-19 (COSMIC), Report 1. *Indian J Ophthalmol*. 2021;69:1670–1692.
166. Honavar SG. Code mucor: guidelines for the diagnosis, staging, and management of rhino-orbital-cerebral mucormycosis in the setting of COVID-19. *Indian J Ophthalmol*. 2021;69:1361–1365.
167. Jalink MB, Burger BB, Kalmann R. Orbital inflammation and dacryoadenitis after COVID-19 vaccination. *Case Rep Ophthalmol*. 2022;13:789–792.
168. Hari-Kovacs A, Vass A, Lovas P, et al. Orbital cellulitis following COVID-19 vaccination. *Case Rep Ophthalmol*. 2022;13:210–214.
169. Chuang TY, Burda K, Teklemariam E, et al. Tolosa-Hunt syndrome presenting after COVID-19 vaccination. *Cureus*. 2021;13:e16791.
170. Bayas A, Menacher M, Christ M, et al. Bilateral superior ophthalmic vein thrombosis, ischaemic stroke, and immune thrombocytopenia after ChAdOx1 nCoV-19 vaccination. *Lancet*. 2021;397:e11.
171. Panovska-Stavridis I, Pivkova-Veljanovska A, Trajkova S, et al. A rare case of superior ophthalmic vein thrombosis and thrombocytopenia following ChAdOx1 nCoV-19 vaccine against SARS-CoV-2. *Mediterr J Hematol Infect Dis*. 2021;13:e2021048.
172. Sen M, Honavar SG. After the storm: ophthalmic manifestations of COVID-19 vaccines. *Indian J Ophthalmol*. 2021;69:3398–3420.
173. Perry RJ, Tamborska A, Singh B, et al. Cerebral venous thrombosis after vaccination against COVID-19 in the UK: a multicentre cohort study. *Lancet*. 2021;398:1147–1156.
174. Lam DSC, Wong RLM, Lai KHW, et al. COVID-19: special precautions in ophthalmic practice and FAQs on personal protection and mask selection. *Asia Pac J Ophthalmol (Phila)*. 2020;9:67–77.
175. Land R, Boyd C, Patel P. Assessing the impact of the COVID-19 pandemic on the ophthalmology literature. *Asia Pac J Ophthalmol (Phila)*. 2022;11:567–568.