




Since January 2020 Elsevier has created a COVID-19 resource centre with free information in English and Mandarin on the novel coronavirus COVID-19. The COVID-19 resource centre is hosted on Elsevier Connect, the company's public news and information website.

Elsevier hereby grants permission to make all its COVID-19-related research that is available on the COVID-19 resource centre - including this research content - immediately available in PubMed Central and other publicly funded repositories, such as the WHO COVID database with rights for unrestricted research re-use and analyses in any form or by any means with acknowledgement of the original source. These permissions are granted for free by Elsevier for as long as the COVID-19 resource centre remains active.



Monocentric case-series of mesenteric vascular disease occurred in the first month of the COVID-19 pandemic[☆]

Daniela Di Lella^{a,1}, Giuseppe Petrone^a, Eugenio Martelli^{b,c,*}, Rossella Chiara Vigliotti^d, Gennaro Vigliotti^a

^a Division of Vascular Surgery, Del Mare Hospital, Via Enrico Russo, 80147 Naples, Italy

^b Division of Vascular Surgery, Department of Cardiovascular Sciences, S. Anna and S. Sebastiano Hospital, Caserta, Italy. Saint Camillus International University of Health Sciences, Rome, Italy

^c Department of General and Specialist Surgery "Paride Stefanini", Sapienza University of Rome, Rome, Italy

^d Residency Program in Vascular Surgery, Department of Medical, Surgical and Experimental Sciences, University of Sassari, Sassari, Italy

ARTICLE INFO

Keywords:

CoViD -19
SARS-CoV-2
Hypercoagulability
Visceral thrombosis
Visceral ischemia

ABSTRACT

Objectives: we describe Coronavirus Disease (COVID-19) patients also manifesting gastro-intestinal symptoms.
Methods: five women, between the ages of 32 and 82 years old, were admitted for acute abdomen, and received a nasopharyngeal swab for COVID-19 screening, lab test analysis, and contrast thoraco-abdominal CT-scan. All presented leukocytosis, different localizations of visceral vessels thrombosis and ischemia, and COVID-19.
Results: emergency laparotomy was accepted by all but 1, who died after 5 days. Postoperatively, 1 died of multi-organ failure, 3 were discharged home after 14, 8 and 10 days respectively, under anti-platelet and anticoagulation treatment.
Conclusions: in COVID-19 patients with acute abdomen, abdominal contrast CT-scans should be systematically extended to the thorax to detect visceral COVID-19 initial pulmonary signs. Emergency laparotomy and visceral arteries thrombectomy could be necessary.

1. Introduction

Gastrointestinal involvement in COVID-19 occurs in up to 39% of patients.¹

The positive staining of angiotensin I converting enzyme 2 (ACE2, the viral host receptor) is expressed in gastrointestinal epithelial cells present in the stool of patients tested positive for the RNA of SARS-COV-2 (Severe Acute Respiratory Syndrome-Coronavirus-2, the virus responsible for COVID-19). Evidence suggests SARS-COV-2 fecal-oral transmission. In patients with pulmonary symptoms, the beta-coronavirus responsible for COVID-19 disease can cause gastrointestinal infection possibly evolving in hemorrhagic colitis or bowel ischemia.^{2,3} Moreover, four recent studies have highlighted a co-existing hypercoagulable state that can lead to mesenteric arterial thromboses.⁴⁻⁷

2. Material and methods

The expected medium number of patients presenting with mesenteric ischemia to our institution before COVID-19 pandemic was 2–3 patients per year. We describe our experience with patients manifesting bowel ischemia, and found affected by COVID-19: being positive for the reverse transcription polymerase chain reaction from nasopharyngeal swab. All patients were admitted to the ER, received airway and breathing support along the recommended therapeutic long-term subcutaneous enoxaparin sodium and life-long 100 mg/daily aspirin, underwent a thoraco-abdominal contrast CT-scan, and agreed to allow the authors to publish their case details and images.

3. Theory

In the current pandemic era, patients presenting acute abdominal pain should be suspected as COVID-19 positive.

[☆] Note: this research did not receive any specific grant from funding agencies in the public, commercial, or not-for-profit sectors.

* Corresponding author at: UniCamillus, via di Sant'Alessandro 8, 00131 Rome, Italy.

E-mail addresses: danieladilella@libero.it (D. Di Lella), dottpetrone@libero.it (G. Petrone), eugenio.martelli@unicamillus.org (E. Martelli), rossychiara@hotmail.it (R.C. Vigliotti), gevigli@tin.it (G. Vigliotti).

¹ To my father, passed away during the pandemic crisis. (Daniela Di Lella).

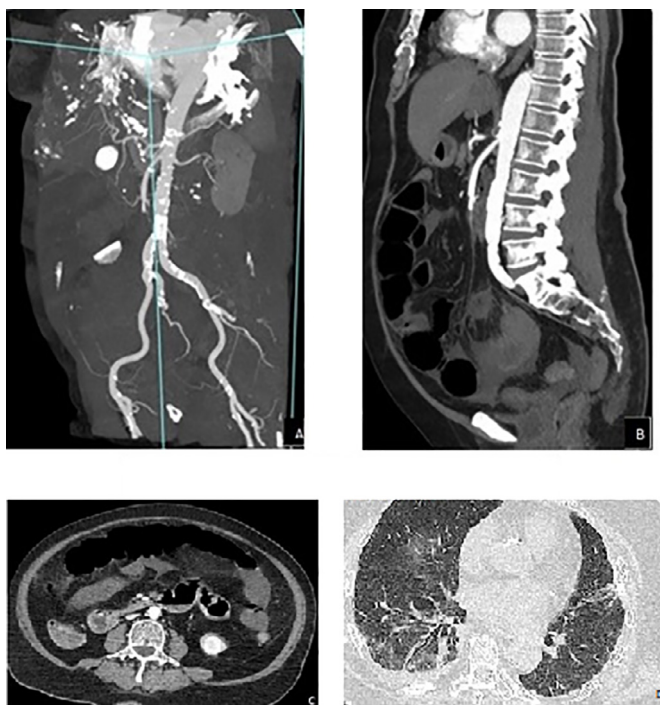


Fig. 1. Superior mesenteric artery thrombotic occlusion in its medium segment (a-b). CT scan demonstrates multiple bowel loops dilated containing air-fluid levels and thinning of the walls (c). Thoracic CT-scan (d).

4. Calculation

The abdominal contrast CT-scan, usually performed in patients with acute abdomen, should be extended to the thorax to promptly identify an eventual pulmonary involvement.

5. Results

Five women, between the ages of 32 and 82 years old, were admitted in the ER on March 2020, the 1st month of the pandemic. We experienced no other patients with mesenteric arterial/venous thrombosis associated with COVID-19 in the rest of 2020 and in the following year, at least until now.

5.1. Case series

The first patient, 82 years old, presented abdominal pain, mild respiratory symptoms, leukocytosis ($23 \times 10^9/L$), lymphopenia ($2 \times 10^9/L$), mild thrombocytosis ($497 \times 10^9/L$), elevated D-dimer level (7.8 mg/L), and normal activated partial thromboplastin time (aPTT). Images demonstrated bilateral pulmonary lung fields with a ground glass appearance, superior mesenteric artery acute thrombotic occlusion, and segmental small bowel ischemia (Fig. 1A–D). In a previous CT-scan, the SMA presented wall calcification and segmental atherosclerotic stenosis. The patient underwent successful emergency superior mesenteric artery embolectomy, and a 90 cm small bowel resection. ICU course was uneventful: the patient was discharged home on post-operative day 14.

The second patient, 82 years old, diabetic, hypertensive and affected by chronic-obstructive pulmonary disease, presented abdominal pain, severe dyspnea, leukocytosis ($21,9 \times 10^9/L$), lymphopenia ($2,8 \times 10^9/L$), mild thrombocytosis ($451 \times 10^9/L$), elevated D-dimer level (3,7 mg/L), and normal aPTT. Images showed multifocal pneumonia with diffuse bilateral ground glass opacity, proximal thrombosis of the superior mesenteric artery whose walls were not very calcified, small intestine ischemia, and splenic sub-massive infarction (Fig. 2A–D). The patient re-

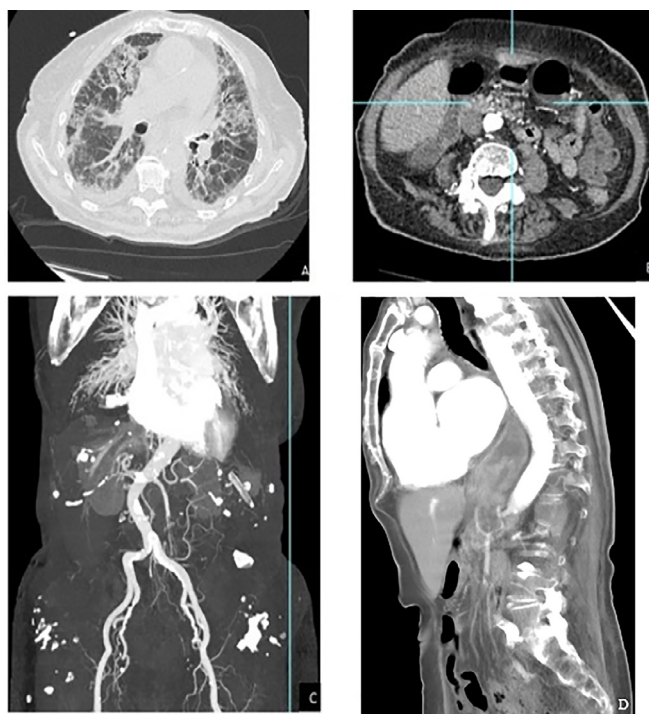


Fig. 2. CT scan demonstrates bilateral opacities localized in peripheral and central parts of the lung, with prevalence of ground-glass pattern (a). Small bowel dilatation containing air-fluid levels (b). Superior mesenteric artery thrombotic occlusion and splenic infarction (c), and relative sagittal view (d).

fused surgical treatment, palliative care was given, but deceased 5 days later.

The third patient, a 32 years old diabetic, presented vomiting, diarrhea, cough, cardiac arrest (the patient underwent prompt cardiopulmonary resuscitation and was intubated), leukocytosis ($29,9 \times 10^9/L$), lymphopenia ($2,2 \times 10^9/L$), elevated D-dimer level (6,79 mg/L), and prolonged aPTT (55"). Images showed subtotal bowel ischemia, mesenteric veins thrombosis, and signs of portal hypertension (Fig. 3). Emergency bowel resection with laparostomy was undertaken for a small intestine transmural necrosis extended to the ileocecal valve. We assume this was a case of intestinal gangrene caused by splanchnic venous thrombosis. In the postoperative, subcutaneous enoxaparin sodium at the dosage of 6000 IU twice daily was given, but ICU course was unfavorable: the patient died of multi-organ failure on post-operative day 3.

The fourth patient was a 75 years old, diabetic, obese, hypertensive, with acute abdomen (which was the prevalent symptom), presenting a dry cough for the previous 7 days, leukocytosis ($26 \times 10^9/L$), lymphopenia ($2,1 \times 10^9/L$), mild thrombocytosis ($487 \times 10^9/L$), elevated D-dimer level (6.2 mg/L), and prolonged aPTT (62"). Images showed subtotal superior mesenteric and portal veins thrombosis with signs of segmental bowel ischemia, extensive bilateral pulmonary consolidation. A bowel resection was performed (Fig. 4). ICU course was uneventful: the patient was discharged on post-operative day 8.

The fifth patient, 68 years old, presented abdominal pain, fever, cough over the previous 5 days, guarding in the left upper quadrant, with worsening of pain upon deep inspiration, leukocytosis ($21.3 \times 10^9/L$), fibrin degradation product = 7.1 mcg/mL, elevated lactate dehydrogenase and C-reactive protein levels (480 U/L and 49 mg/L, respectively), and prolonged aPTT (74"). Images showed splenic artery thrombosis (Fig. 5A and B), and partial splenic infarction: a splenectomy was not necessary since, progressively, abdominal pain disappeared, and leukocytosis and lactate dehydrogenase levels normalized. ICU course

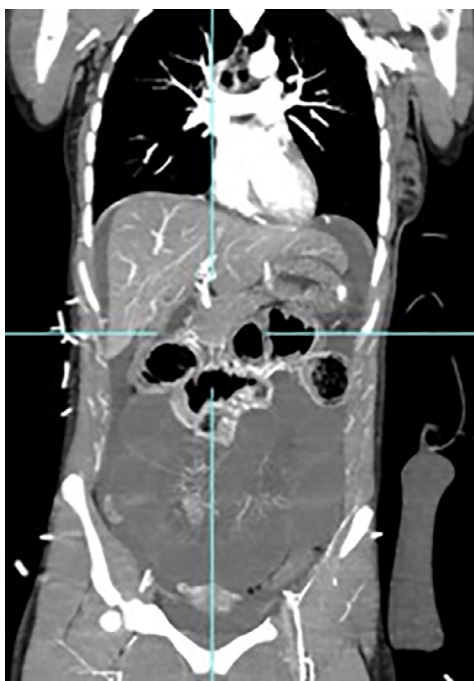


Fig. 3. CT scan shows signs of sub-total small bowel ischemia and mesenteric venous gas.

was uneventful, and the patient was home discharged on post-operative day 10.

Patients 1, 4, and 5 did not experience any recurrent thrombotic events at the 6-month follow-up.

6. Discussion

Gastrointestinal manifestations have been reported in 3–39% of patients with COVID-19, and in 3–10% of those initially presenting isolated mild gastrointestinal symptoms and later pulmonary infection.^{5,8} SARS-COV-2 RNA has been found on fecal sample of patients with hemorrhagic colitis and bloody diarrhea.²

Previous evidences have shown virus replication in the bowel, consequently causing pro-thrombotic sequelae not confined to the pulmonary circulation, with fatal complications like mesenteric ischemia or bowel wall necrosis.⁴

The pro-thrombotic consequences of SARS-COV-2 may be directly due to its architecture. The membrane of the virus presents a Spike protein (S protein) which binds to the ACE2 receptor located on the membrane of host cells. ACE2 is hyper-expressed in the lungs, intestine, oral mucosa, liver, and endothelium. The binding of SARS-COV-2 to ACE2

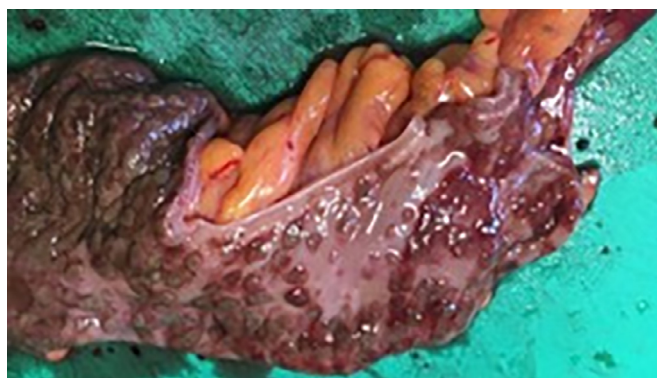

Fig. 4. Bowel resection: intra-operative finding shows macrovascular thrombi of small mesenteric vessels involving the submucosal layer.

reduces the degradation of angiotensin II, which in turn promotes the production of IL-6 and induces a cytokine storm. It has been demonstrated that angiotensin II promotes the expression of tissue factor and plasminogen activator inhibitor-1 by endothelial cells, leading to a hypercoagulable state.⁹

In our series, the main symptom wasn't pulmonary distress, but acute abdomen together with female sex, diabetes, and radiologic signs of ground glass pulmonary opacity at CT-scan.

All of our patients received therapeutic doses of enoxaparin sodium. Treatment with low-molecular-weight heparin is necessary for all hospitalized patients with COVID-19. The recommended dosages are 40 mg/daily or 30 mg/daily, in patients with creatinine clearance of more than 30 mL/min or between 15 and 30 mL/min, respectively; unfractionated heparin is recommended when creatinine clearance is less than 15 mL/min.^{10,11} COVID-19 patients requiring ICU are considered to be at highest risk of thrombotic complications and death, and necessitate higher doses of anticoagulants. It is recommended to increase the dose by 30% in patients with BMIs > 40 kg/m.^{2,12} Patients with pre-existing significant comorbidities should receive anticoagulants for at least three months after hospital discharge and undergo clotting time, platelet counts, and D-dimer level follow-ups. Macrovascular thrombosis can cause occlusion of visceral vessels determining visceral ischemia.

In our series, all patients were women; female gender has been found to be more frequently associated with known hypercoagulable disorders. Recently published papers have reported associated coagulopathy disorders in COVID-19 patients. These studies have highlighted the presence of a coexisting hypercoagulable state, which might be associated with higher mortality.¹³ Hospitalized patients with moderate/severe COVID-19, and those with poorer outcomes, are noted to have prolonged aPTT and elevated D-dimer values.¹⁴ Hypercoagulability, induced by a systemic inflammatory state and endothelial activation, may lead to mesen-

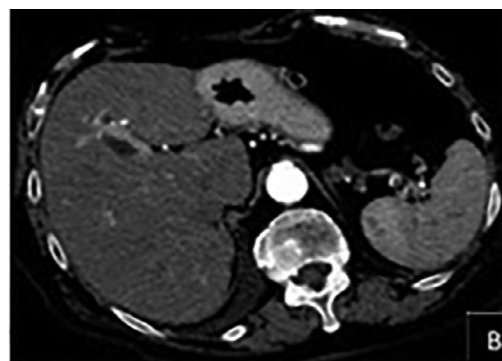
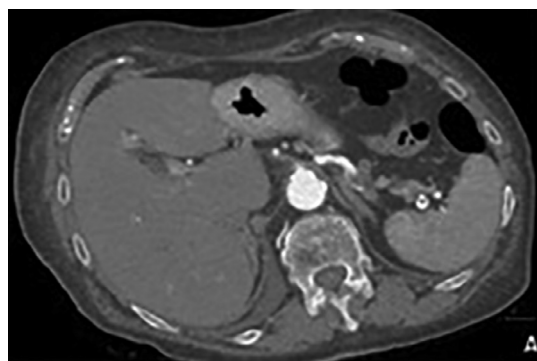


Fig. 5. CT scan demonstrates splenic artery thrombosis and infarction of the spleen.

teric vascular thrombosis. A recent evidence has shown small bowel vessel thrombosis involving the submucosal arterioles, thereby pointing to an in-situ thrombosis of small mesenteric vessels rather than an embolic event.¹⁵ The histology pattern of the bowel, secondary to a mesenteric thrombosis, showed a prominent endotheliitis of the submucosa with a clear evidence of direct viral infection of the endothelial cells such as extended swelling with mononuclear cell infiltrate.¹⁶ COVID-19 is associated with increased level of angiotensin and stimulates other pro-thrombotic proteins such as factor VIII, tissue factor, von Willebrand factor, and plasminogen activation inhibitor-1.¹⁰

Macrovascular thrombi can be observed in both visceral venous and arterial circulation, even in the absence of severe respiratory symptoms.

7. Conclusions

Mesenteric and venous thrombosis should be considered in patients with acute abdomen and COVID-19 positive. Thoraco-abdominal CTA should be considered as a diagnostic test when indicated. A common CT finding in our patient series was thick-walled, edematous and dilated bowel, suspicious of acute mesenteric ischemia. Given our low numbers, a multicenter retrospective study would be helpful to conclude whether the achievement of a systemic thoracic scanner is mandatory.

In our series, acute abdomen with bowel ischemia in COVID-19 is associated with poor prognosis, and high rate of mortality. Emergency laparotomy and eventually visceral arterial thrombectomy should be considered in these patients, whenever possible.

Declaration of Competing Interest

No competing interests to declare.

References

- Zhang JJ, Dong X, Cao YY, et al. Clinical characteristics of 140 patients infected with SARS-CoV-2 in Wuhan, China. *Allergy*. 2020;75(7):1730–1741. doi:10.1111/all.14238.
- Xiao F, Tang M, Zheng X, et al. Evidence for gastrointestinal infection of SARS-CoV-2. *Gastroenterology*. 2020;158(6):1831–1833. doi:10.1053/j.gastro.2020.02.055.
- Ignant M, Philouze G, Aussenac-Belle L, et al. Small bowel ischemia and SARS-CoV-2 infection: an undiagnosed distinct clinical entity. *Surgery*. 2020;168(1):14–16. doi:10.1016/j.surg.2020.04.035.
- Han H, Yang L, Liu R, et al. Prominent changes in blood coagulation of patients with SARS-CoV-2 infection. *Clin Chem Lab Med*. 2020;58(7):1116–1120. doi:10.1515/cclm-2020-0188.
- Tang N, Li D, Wang X, et al. Abnormal coagulation parameters are associated with poor prognosis in patients with novel coronavirus pneumonia. *J Thromb Haemost*. 2020;18(4):844–847. doi:10.1111/jth.14768.
- de Barry O, Mekki A, Diffre C, et al. Arterial and venous abdominal thrombosis in a 79-year-old woman with COVID-19 pneumonia. *Radiol Case Rep*. 2020;15(7):1054–1057. doi:10.1016/j.radcr.2020.04.055.
- Vulliamy P, Jacob S, Davenport RA. Acute aorto-iliac and mesenteric thromboses as presenting features of COVID-19. *Br J Haematol*. 2020;189(6):1053–1054. doi:10.1111/bjh.16760.
- Pan L, Mu M, Pengcheng Y, et al. Clinical Characteristics of COVID-19 patients with digestive symptoms in Hubei, China: a descriptive, cross-sectional, multicenter study. *Am J Gastroenterol*. 2020;115(5):766–773. doi:10.14309/ajg.0000000000000620.
- Parry AH, Wani AH, Yaseen M. Acute mesenteric ischemia in severe coronavirus-19 (COVID-19): possible mechanism and diagnostic pathway. *Acta Radiol*. 2020;27(8):1190. doi:10.1016/j.acra.2020.05.016.
- The Lancet Haematology COVID-19 coagulopathy: an evolving story. *Lancet Haematol*. 2020;7(6):e425. doi:10.1016/S2352-3026(20)30151-4.
- Miesbach W, Makris M. COVID-19: coagulopathy, risk of thrombosis, and the rationale for anticoagulation. *Clin Appl Thromb Hemost*. 2020;26:1–7. doi:10.1177/1076029620938149.
- Galanis N, Stavrika C, Agathangelidis F, et al. Coagulopathy in COVID-19 infection: a case of acute upper limb ischemia. *J Surg Case Rep*. 2020;6:1–4. doi:10.1093/jscr/rjaa204.
- Mondal R, Lahiri D, Deb S, et al. COVID-19: Are we dealing with a multisystem vasculopathy in disguise of a viral infection? *J Thromb Thrombolysis*. 2020;50(3):567–579. doi:10.1007/s11239-020-02210-8.
- Zhou F, Yu T, Du R, et al. Clinical course and risk factors for mortality of adult inpatients with COVID-19 in Wuhan, China: a retrospective cohort study. *Lancet*. 2020;395:1054–1062. doi:10.1016/S0140-6736(20)30566-3.
- Bhayana R, Som A, Li MD, et al. Abdominal imaging findings in COVID-19: preliminary observations. *Radiology*. 2020;297(1):E207–15. doi:10.1148/radiol.2020201908.
- Varga Z, Flammer AJ, Steiger P, et al. Endothelial cell infection and endothelitis in COVID-19. *Lancet*. 2020;395(10234):1417–1418. doi:10.1016/S0140-6736(20)30937-5.