







Article

# “Pull-through” Resection for Total and Subtotal Glossectomy Involving the Posterior Third of Tongue

Marco Della Monaca <sup>1</sup>, Valentina Terenzi <sup>1,2</sup>, Ingrid Raponi <sup>1</sup>, Paolo Priore <sup>1</sup>, Andrea Battisti <sup>1</sup>, Andrea Cassoni <sup>1</sup>, Riccardo Nocini <sup>3</sup>, Gianluca Tenore <sup>1</sup>, Edoardo Brauner <sup>1</sup>, Umberto Romeo <sup>1</sup>, Antonella Polimeni <sup>1</sup> and Valentino Valentini <sup>1,4,\*</sup>

<sup>1</sup> Odontostomatological and Maxillo-Facial Sciences Department, “Sapienza” University of Rome, 00185 Roma, Italy; marco.dellamonaca@uniroma1.it (M.D.M.); valentina.terenzi@uniroma1.it (V.T.); ingrid.raponi@uniroma1.it (I.R.); priore.paolo1@gmail.com (P.P.); andrea-batti@libero.it (A.B.); andrea.cassoni@uniroma1.it (A.C.); gianluca.tenore@uniroma1.it (G.T.); edoardo.brauner@uniroma1.it (E.B.); umberto.romeo@uniroma1.it (U.R.); antonella.polimeni@uniroma1.it (A.P.)

<sup>2</sup> ENT Unit, Ospedale “Santa Maria Goretti”, AUSL Latina, 04100 Latina, Italy

<sup>3</sup> Department of Otolaryngology-Head and Neck Surgery, University of Verona, 37129 Verona, Italy; riccardo.nocini@gmail.com

<sup>4</sup> UOS Chirurgia Oncologica, Ricostruttiva Maxillo-Facciale, Viale del Policlinico 155, 00100 Rome, Italy

\* Correspondence: valentino.valentini@uniroma1.it; Tel.: +39-064-997-9199

Received: 28 October 2020; Accepted: 26 November 2020; Published: 30 November 2020



**Abstract:** The lower lip-splitting incision associated with different types of mandibulotomy, in order to obtain wide access to total or subtotal glossectomy, is described. In those cases, high rates of functional and aesthetic deficit and postoperative morbidity (more in cases of patients in which adjuvant radiotherapy has been performed) are described. We present our experience in the treatment of patients undergoing total or subtotal glossectomy and contemporary reconstruction with flaps, and without lip-splitting incision and mandibulotomy. *Materials and Methods:* Data about patients affected by malignant tumors requiring total or subtotal (posterior third of the tongue) resection that were treated at our department from January 2004 to December 2014 were retrospectively reviewed. Data evaluated included: T and N stage, resection margins, operation time, and post-operative complications, such as fistula and flap necrosis. *Results:* 41 patients were identified. In two cases microscopic infiltration of one margin was found (R1); in one case a close margin was identified. In 26 cases reconstruction was performed using free flaps, and in the remaining cases a pectoralis major flap was used. In three cases postoperative complications were observed. *Discussion and conclusions:* In theory, lip-splitting and mandible discontinuity could allow for increased access and tumor visualization, and could facilitate flap positioning. Nevertheless, in our experience, it is not necessary in the case of total or subtotal glossectomy.

**Keywords:** pull-through technique; oral carcinoma; free flap; lip-splitting; transmandibular approach

## 1. Introduction

Head and neck cancer accounts for more than 650,000 cases and 330,000 deaths annually; only considering the lip and oral cavity, in 2018 about 355,000 new cases with 177,000 deaths (1.9% of all sites) were reported [1]. In the United States, head and neck cancer accounts for 3% of all malignancies (53,000 cases/year, with about 10,800 dying from the disease), while in Europe, the reported percentage is about 4%, with approximately 250,000 cases, and 63,500 deaths, in 2012 [2,3].

The introduction of multimodality treatment has significantly improved overall survival in patients affected by oral cancer, and many efforts have been made in order to improve the quality of

life of these patients, from both an aesthetical and functional point of view. In this context, there is the need for the surgeon to find the “least invasive” surgical approach, in terms of potential post-surgical complications (considering that most of these patients require adjuvant treatment) and adequate aesthetical results (avoiding non necessary scars). Obviously, since resection in free margins, including cervical nodes, is the mainstay of treatment for malignant tumors involving the oral cavity, the chances of performing an adequate three-dimensional removal of the tumor are higher if it presents an extensive surgical field that, at the same time, is useful in order to facilitate a flap inset. In the case of tumors arising in the tongue and/or the floor of the mouth without mandibular involvement, the “pull-through” technique, in which the primary is resected and pushed down through cervical access, maintaining the integrity of the mandible, has been described [4,5]. Nevertheless, in order to gain wide access to the oral cavity and oropharynx, the lip-splitting technique, in conjunction with a mandibulotomy (in which the proximal mandible is swung outwards), has been the preferential approach; also in those cases in which mandibular resection was not required [6]. On the other hand, complications such as mal-union or non-union of the osteotomy, plate failure, wound sepsis, and poor aesthetics are reported after this surgical procedure in a significant number of cases [7].

Even if today the “pull-through” operation is almost universally performed in those cases in which an antero-lateral buccopelvectomy and/or partial glossectomy is required, in cases of tumors involving the posterior third of the tongue most surgeons still prefer to perform removal through a transmandibular approach, with or without inferior lip-splitting [8].

We think that it is possible to use the “pull-through” technique for total or subtotal glossectomy involving the posterior third of the tongue. In this regard, we report our experience with 44 patients that underwent “pull-through” total or subtotal glossectomy for squamous cell carcinoma involving the posterior tongue, and focusing attention on oncological (incidence of non-radical resection) and reconstructive safety (incidence of complications related to an inadequate flap insetting); since we think that the surgical approach does not significantly influence functional outcome. In fact, the aim of this paper is to counter the opinion, that the “pull-through” technique is not safe in the case of tumors involving the posterior third of the tongue.

## 2. Materials and Methods

Data about patients affected by lingual malignant tumors requiring posterior tongue resection that were treated at our department from January 2004 to December 2014 were retrospectively reviewed. Inclusion criteria were: (a) histologically proved diagnosis of malignant tumor of the tongue or floor of the mouth without mandibular involvement, in which resection had to include the posterior third of the tongue; (b) neck dissection performed at the same surgical time en-bloc with the primary tumor; (c) surgery as first treatment; (d) resection performed with the “pull-through” technique; (e) absence of gross bone infiltration requiring mandibulectomy (usually only marginal mandibulectomy is performed in those tumors involving the floor of the mouth and adherent gingiva); (f) reconstruction using a free or regional flap; (g) absence of distant metastases. All patients were staged according to AJCC 2004. In the last 2 years (2013–2014), all cases have been discussed at the Head and Neck Tumor Board. Decisions about the surgical intervention type were determined collegially on the base of clinical staging and the depth of tumor invasion (in the case of clinical and radiological suspicion of deep infiltration >5 mm primary removal en-bloc with neck dissection was performed).

Data evaluated included: pT- and pN-stage (according to AJCC 2004), state of resection margins, type of reconstruction (pedicled or free flaps), type of neck dissection (RND/MRND, SND), post-operative (within 2 weeks from surgery) complications such as fistula and flap necrosis, and recurrence.

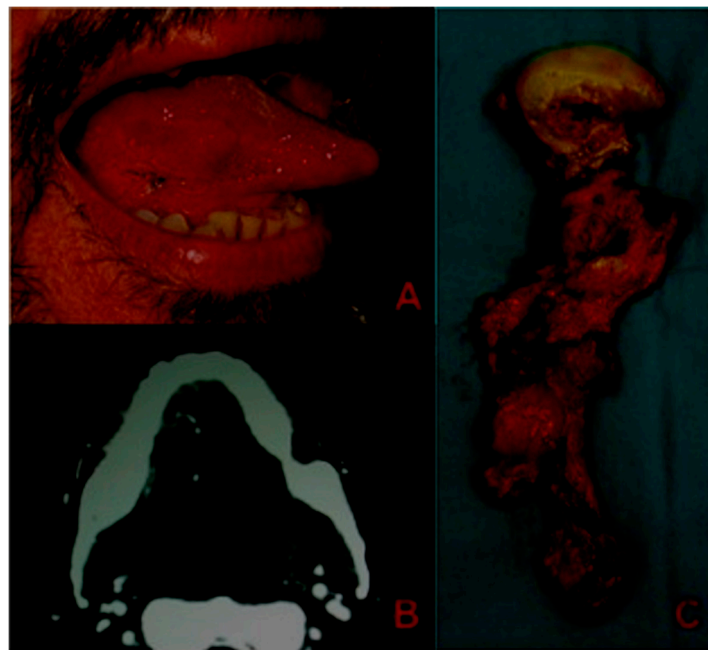
Ethic committee approval was obtained.

### Surgical Technique

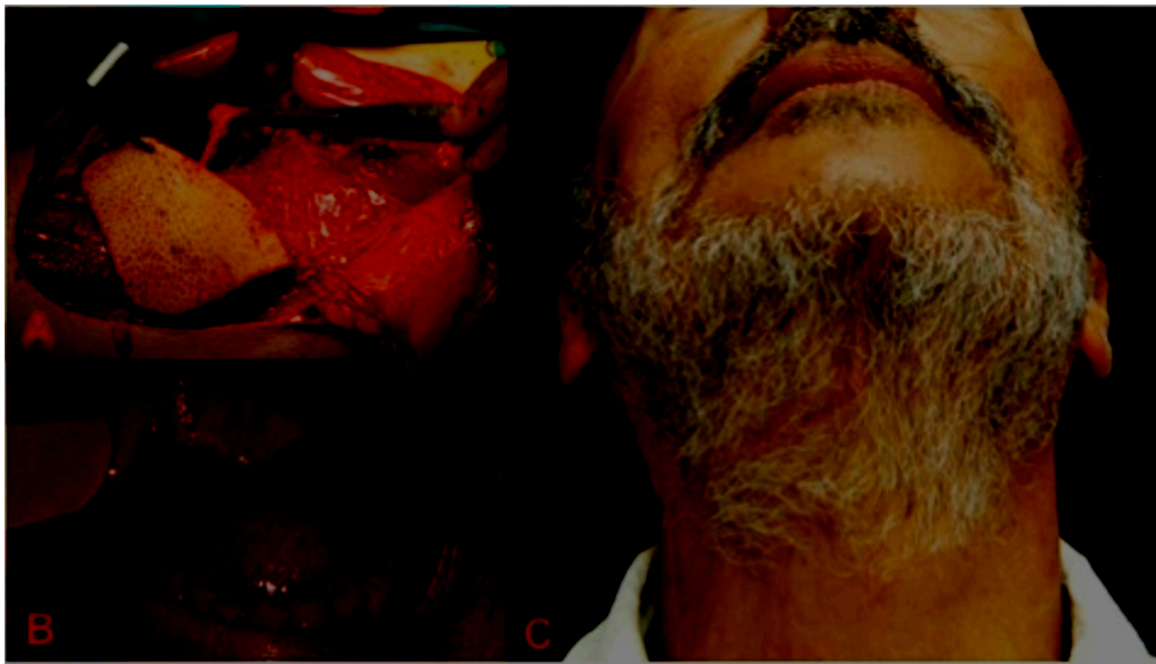In no cases mandibulotomy with or without a lower-split incision is performed in order to resect the primary and en-bloc tumor extirpation has been made via exposure afforded by neck visor flap and transoral approach. Neck incision was performed according to dissection type via a tri- or bi-flapped incision. Except in those cases of cN3 patients, in which subcutaneous tissue involvement was present, the superior flap was elevated in a subplatysmal plane to expose the mandible. If the tumor was close to the mandible, without any clinical or radiographic evidence of mandibular invasion, a marginal mandibulectomy was performed.

As reported by Ward, “we incise the floor of the mouth and pull the neck dissection specimen intra-orally, removing it in continuity with the primary disease” [1]. Using this technique milohyoid muscle is sectioned in order to permit en-bloc tumor removal as originally described [5]. Eventually, the digastric muscle can be resected in order to improve surgical access.

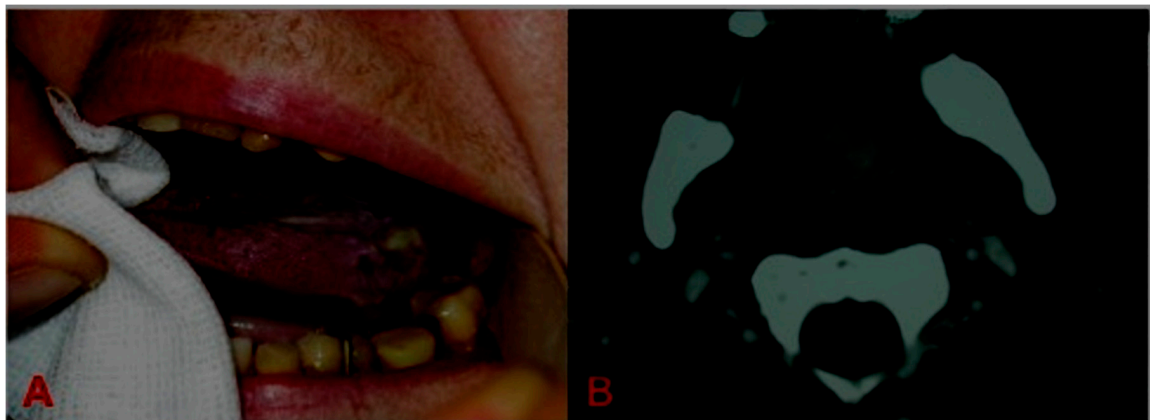
Reconstruction was performed preferentially using a free flap: in our experience the anterolateral thigh (ALT) is the best choice (Case 1-Figures 1 and 2), since we abandoned the use of the forearm free flap because of donor site morbidity [9]; the use of the rectus abdominis is reserved for total glossectomy (Case 2-Figures 3 and 4). Obviously, the pectoralis major pedicled flap is reserved for those patients in which microsurgical reconstruction is contraindicated, or in the case of salvage surgery after free flap loss. In all cases temporary tracheostomy and a nasogastric tube for feeding were positioned.



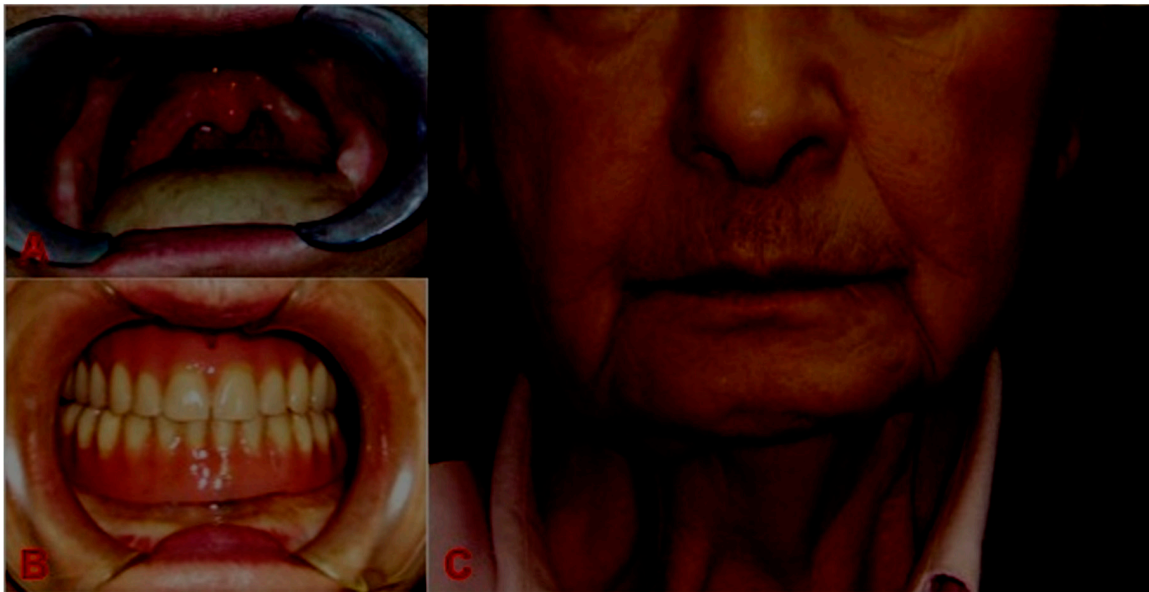
**Figure 1.** Case 1: A 67-years-old Caucasian male affected by a squamous cell carcinomas (SCC) of the middle third of the right tongue staged as pT2N0 who underwent partial glossectomy en-bloc with right modified radical neck dissection (MRND) using the “pull-through” technique; contemporary reconstruction was performed with anterolateral thigh (ALT). (A) Pre-operative intraoral view of the lesion; (B) pre-operative axial CT scan, with contrast showing a large lesion involving the right tongue; (C) intraoperative view of the specimen.



**Figure 2.** Case 1: (A) Intraoperative view of the ALT flap; (B) post-operative intraoral view (Free From Disease (FFD), 5 years after surgery); (C) post-operative axial view of the patient showing no scars on the chin and lip.



**Figure 3.** Case 2: A 67-year-old Caucasian female affected by a SCC of the tongue staged as pT4aN1 who underwent total glossectomy en-bloc with left MRND and right SND (I-III), and contemporary reconstruction using the rectus abdominis free flap. (A) Pre-operative intraoral view of the lesion; (B) pre-operative axial CT scan, with contrast showing a large lesion involving the whole left hemitongue and the anterior and middle third of the right one.



**Figure 4.** Case 2: (A) Post-operative intraoral view; (B) post-operative intraoral view (FFD, 5 years after surgery and adjuvant chemo-radiation therapy) with dental prosthesis retained using four titanium implants; (C) post-operative frontal view of the patient showing no scars on the chin and lip.

### 3. Results

Forty-four patients were identified; between them, 22 were affected by squamous cell carcinomas (SCCs) and two by adenoid cystic carcinomas (ACCs). In most cases (79.5%) the primary lesion was staged as T1 or T2; in two cases microscopic infiltration of one margin was found (R1); and in one case a close margin (<5 mm) was identified. In cases in which intraoperative histological examination of the margin revealed the presence of neoplastic cells a radicalization was performed until free tissue was found. The primary was resected en-bloc with a radical (RND) or a modified radical neck dissection (MRND) in 28 cases, while in 24 cases a selected neck dissection (SND) was performed; in eight cases neck dissection was bilateral. Positive nodes were found in 22/44 patients (24/52 neck dissections). In 29 cases reconstruction was performed using free flaps, and in the remaining cases a pectoralis major flap was used. In three cases postoperative complications were observed (one partial flap loss in a case in which reconstruction was performed using a ALT flap, and two cases of oro-cervical fistula in which the defect was closed with an ALT free flap and a pectoralis major flap, respectively). Data are illustrated in Table 1.

Medium follow-up was 34.9 months (range: 2–115 months); four patients were lost in follow-up. In 35 patients (79.5%) no recurrence was observed; the most frequent neoplastic event was loco-regional recurrence (6/9 patients) that was observed from 4 to 18 months post-operatively; three patients presented distant metastases (lung in two cases, and lung and liver in the last one). Details of cases in which recurrence was observed are illustrated in Table 2.

**Table 1.** Patient data.

Variables	N° of pts (%)
Histology	
SCC	42 (95.5%)
ACC	2 (4.5%)
pT classification	
T1–T2	35 (79.5%)
T3–T4a	9 (20.5%)
Reconstruction	
RFFF	2 (4.5%)
ALTFF	26 (59%)
Pectoralis major	15 (34%)
Rectus abdominis	1 (2.5%)
Resection margins	
R0	39 (89%)
Close	1 (2.5%)
R1	2 (4.5%)
Type of ND	
RND/MRND	28 (54%)
SND	24 (46%)
Complications	
Fistula	2 (4.5%)
Flap necrosis	1 (partial) (2.5%)

In all cases pT4a staging was consequent to extrinsic muscles infiltration. ACC: adenoid cystic carcinoma; SCC: Squamous Cell Carcinoma; RFFF: Radial Forearm Free Flap; ALTFF: Antero Lateral Thigh Free Flap; ND: Neck Dissection; RND: Radical Neck Dissection; MRND: Modified Radical Neck Dissection; SND: Selective Neck Dissection.

**Table 2.** Details of cases in which recurrence was observed.

Sex	Age	Risk Factors	Resection	Histology	Reconstruction	Complications	Adjuvant Treatment	Relapse	FU
M	60	Smoker, Alcohol abuse	Subtotal glossectomy + RND	SCC pT2pN2b G3 Pn1 DOI: 10 mm R0	Radial free flap	None	CHT-RT	rT/N (18 months)	DWD
M	48	Ex smoker	Subtotal glossectomy + left MRND and right SND	SCC pT3pN0 G2 Pn1 DOI: 11 mm R1	Pectoralis major flap	None	CHT-RT	rT (6 months)	DWD
M	72	Smoker	Subtotal glossectomy + right MRND and left SND	SCC pT2pN1 G2 Pn1 DOI: 12 mm R0	ALT	None	CHT-RT	rM (14 months)	DWD
F	53	None	Subtotal glossectomy + SND	SCC pT2pN0 G2 Pn0 DOI: 6 mm R0	ALT	None	None	rN (7 months)	DWD
F	63	Smoker, previous alcohol abuse	Subtotal glossectomy + left MRD + right SND	SCC pT3pN2c G2 Pn1 DOI: 10 mm R0	Pectoralis major flap	None	CHT-RT	rM (8 months)	DWD
F	33	Smoker	Subtotal glossectomy + SND	ACC pT2pN0 Pn1 DOI:10 mm R0	ALT	None	RT	rM (9 months)	AWD
M	52	Smoker	Subtotal glossectomy + MRND	SCC pT2pN2b G3 pN1 DOI: 11 mm R0	Pectoralis major flap	None	CHT-RT	rN (7 months)	DWD
F	39	Ex smoker, Lichen planus	Subtotal glossectomy + SND	SCC pT1pN0 G1 Pn1 DOI: 5 mm R0	ALT	None	None	rT (4 months)	AWD
F	75	Smoker, previous alcohol abuse	Subtotal glossectomy + MRND	SCC pT2pN2b G2 Pn1 DOI: 8 mm R0	Pectoralis major flap	Oro-cervical fistula	RT	rT (4 months)	DWD

RND: Radical neck dissection; MRND: Modified radical neck dissection; SND: Selective neck dissection; SCC: squamous cell carcinoma; ACC: adenoid cystic carcinoma; ALT: anterolateral thigh flap; DWD: dead with disease; AWD: alive with disease; DOI: Depth of infiltration.

#### 4. Discussion

Multimodality treatment has improved survival in head and neck cancer patients; even if disease free survival obviously remains the primary end point, efforts have been made in order to improve quality of life. From a reconstructive point of view, the use of free flaps permits us to obtain satisfactory



aesthetical and functional results [6]. Nevertheless, since wide resection is fundamental in order to improve disease free survival, it is essential to perform a complete three-dimensional resection of the primary with regional nodes. One of the first descriptions of the technique, to obtain an “en-bloc” resection of intraoral tumors, was introduced by Martin: in such cases the operations provided a resection of a mandible, or a portion of it, through a lip incision [10]. Nevertheless, in the same year Ward in his work provided a description of his technique in which resection was performed without lip-splitting; in the same paper he described the “pull-through” operation. In fact, even if it was Ravitch who coined this term, in order to describe the surgical technique that he adopted to remove a neurofibroma of the base of the tongue, it was Ward who adapted it for the treatment of malignant lesions [4]. As originally described, “it is believed that the procedure . . . is justified as long as there is at least 1 cm of clinically normal tissue between the tumor and the gingiva” [5]. It is due to this fact that the authors considered a direct closure of the defect, but the use of pedicled and/or free flaps made this indication obsolete. He also assessed that “ . . . on occasion, the mandible on the affected side is deliberately sacrificed, first to obtain adequate exposure, and second, to remove a likely site of recurrence” [4]. Today, it is universally accepted that in the case of tumors close to the mandible without clinical or radiological signs of bone invasion marginal mandibulectomy is sufficient in order to obtain a safe resection [11]. Moreover, it is interesting to note that in 1951 he concluded his paper assessing that: “ . . . as experience is gained, it is hoped that this operation will be useful in many patients with cancer of the tonsils, pillars, and lateral pharyngeal wall” [4].

Nevertheless, in order to gain wide access to the oral cavity and oropharynx, the lip-splitting technique in conjunction with a mandibulotomy (in which the proximal mandible is swung outwards) has been the preferential approach, and also in those cases in which mandibular resection was not required [6]. Morbidity of up to 35% has been reported using this method, and mal-union of the osteotomy, plate failure, wound sepsis, and poor aesthetics have been described; more so in cases in which irradiation was required [3]. Nevertheless, other studies failed to find a correlation between post-operative complications and previous irradiation or chemoradiotherapy [12].

Alternatively, the mandibular lingual releasing approach has been described: in this case there is no need for lip-splitting and mandibulectomy, since the geniohyoid, mylohyoid, and genioglossus muscles are carefully detached from the inner surface of the mandible so that the floor of mouth and tongue can then be dropped into the neck. Obviously, reattachment of muscles is essential to restore the oral diaphragm [13]. This procedure is not necessary to perform the “pull-through” technique, since geniohyoid, mylohyoid, and genioglossus muscles are not detached, but sectioned, and partially removed, and the defect is then reconstructed with the flap. Devine et al. found that patients who had a mandibular lingual release scored less favorably on speech, swallowing, and chewing, and that tongue mobility was slightly worse compared to those who underwent a lip-splitting operation [14]. Even if Devine et al. found that lip-splitting is better than the lingual release approach from an aesthetic point of view, we have to consider that the latter always requires a bilateral neck incision that can affect the result. In addition, radiotherapy can deeply worsen the aesthetic outcome of a neck incision, but this factor has not been considered by the authors [15]. In our opinion tongue mobility and speech are only slightly influenced by surgical approach, since the milohyoid muscle is always sectioned or resected using both techniques or compartmental surgery [16]. It has been demonstrated by Chang et al. that post-operative speech and swallowing strictly depend on the type of flap used and patient age, rather than on radiation therapy, smoking, and alcohol use [17].

To our knowledge, except for the first descriptions published by Ward and Slaughter, only two other studies have described the resection of tumors arising in the posterior regions of the oral cavity en-bloc with neck dissection, and avoiding lip-splitting [4,5,12,18]. Nevertheless, cases including mandibular resection were included: we decided to not consider these since mandibular body removal can facilitate primary resection, and we wanted to evaluate the oncological safety of the “pull-through” technique, according to the associated difficulties. In addition, we cannot make a comparison with patients treated using the lip-splitting approach, as from 2000 to today, we have not used this method.

On the basis of these studies, it has been found that the lip-splitting approach has a statistically significant higher rate of fistula formation than the visor flap approach [18]. Nevertheless, these results can be also explained by the fact that the authors considered in their study 70 patients that underwent resection including the mandible: between them, 41 underwent resection through a lip-splitting operation, and 29 through a visor flap, and it was found that post-operative fistula appears more frequently in cases of composite resections [12].

Another important factor that has to be considered is the aesthetic one, since facial scars affect the patient's self-image and quality of life (QOL). Nevertheless, Dziegielewski et al. affirmed that the lip-splitting approach can be considered for large, or posteriorly-located tumors, since it provides satisfactory scarring and low self-perception of disfigurement for patients, with no impact on lower-lip sensation, movement, or oral continence; in addition, in another study they reported low morbidity for that is concerning with functional results [19,20]. Unfortunately, we have no experience in order to rebut these assessments, but, on the basis of our clinical practice, since usually patients complain of scars derived from neck dissection, it is likely that lip incision would not be well accepted.

In this context, the main limitation of this retrospective study is the fact that we could not perform a comparison between the three surgical approaches (transmandibular, with or without lip-splitting, "lingual release", and "pull-through" techniques) as we have no experience except with the "pull-through" technique.

## 5. Conclusions

Today, the "pull-through" operation is almost universally performed in those cases in which an antero-lateral buccopelvectomy is required, while in the case of tumors involving the posterior third of the tongue or the base, most surgeons still prefer to perform removal through a lip-splitting transmandibular approach. This attitude is linked to two reasons:

- a) to gain three-dimensional resection of the tumor: Theoretically, the lip-splitting technique in conjunction with a mandibulotomy allows us to obtain a clear visualization of the tumor in order to obtain a wide resection. Nevertheless, it has been found that clear margins can also be achieved in patients treated using the "pull-through" technique [10]. In our study we found a rate of free margin comparable to the one found in the case of the lip-splitting approach.
- b) to facilitate flap inset: Obviously, flap inset is easier if the proximal mandible is swung outwards, and theoretically the post-operative complication rate should be lower. According to other authors [12], there is not found a high rate of flap failure, for both the use of free or pedicled flaps. In our practice, we obviously prefer to use free flaps (usually ALT), and we reserve the use of pectoralis pedicled flaps for those cases in which it is not possible due to the patient's condition. In particular, reconstruction was performed with free flaps in 29 cases, and only a 3.4% partial flap necrosis was observed.

According to Myers [12], we failed to find justifications for these assessments, and we can conclude, on the base of our experience, that "pull-through" resection can be routinely used in the resection of malignant tumors involving the posterior third of the tongue. Nevertheless, further perspective studies, with larger samples, are necessary to reinforce this opinion.

**Author Contributions:** Conceptualization: M.D.M., V.T. and V.V. Methodology: M.D.M., V.T., A.B. and A.C. Investigation: P.P. and I.R. Data curation: I.R., E.B. and G.T. Resources: R.N. and P.P. Writing—original draft preparation: M.D.M. and V.T. Writing—review and editing: V.V., A.P. and U.R. All authors have read and agreed to the published version of the manuscript.

**Funding:** This research received no external funding.

**Conflicts of Interest:** The Authors declare no conflict of interest.



## References

1. Bray, F.; Ferlay, J.; Soerjomataram, I.; Siegel, R.L.; Torre, L.A.; Jemal, A. Global cancer statistics 2018: GLOBOCAN estimates of incidence and mortality worldwide for 36 cancers in 185 countries. *CA Cancer J. Clin.* **2018**, *68*, 394. [[CrossRef](#)] [[PubMed](#)]
2. Siegel, R.L.; Miller, K.D.; Jemal, A. Cancer statistics, 2020. *CA Cancer J. Clin.* **2020**, *70*, 7. [[CrossRef](#)] [[PubMed](#)]
3. Gatta, G.; Botta, L.; Sánchez, M.J.; Anderson, L.A.; Pierannunzio, D.; Licitra, L.; Eurocare Working Group. Prognoses and improvement for head and neck cancers diagnosed in Europe in early 2000s: The EUROCORE-5 population-based study. *Eur. J. Cancer* **2015**, *51*, 2130. [[PubMed](#)]
4. Ward, G.; Robben, J.O. The Composite Operation for Radical Neck Dissection and Removal of Cancer of the Mouth. *Cancer* **1951**, *4*, 98. [[CrossRef](#)]
5. Slaughter, D.P.; Southwick, H.W. En bloc resection of cancer of the mouth and cervical lymphatics with preservation of the mandible. *Ann. Surg.* **1952**, *136*, 957–963. [[CrossRef](#)] [[PubMed](#)]
6. Spiro, R.H.; Gerold, F.P.; Strong, E.W. Mandibular “swing” approach for oral and oropharyngeal tumors. *Head Neck Surg.* **1981**, *3*, 371–378. [[CrossRef](#)] [[PubMed](#)]
7. Gooris, P.J.J.; Worthington, P.; Evans, J.R. Mandibulotomy: A surgical approach to oral and pharyngeal lesions. *Int. J. Oral Maxillofac. Surg.* **1989**, *18*, 359–364. [[CrossRef](#)]
8. Baek, C.H.; Lee, S.W.; Jeong, H.S. New modification of the mandibulotomy approach without lip splitting. *Head Neck* **2006**, *28*, 580–586. [[CrossRef](#)] [[PubMed](#)]
9. Valentini, V.; Cassoni, A.; Marianetti, T.M.; Battisti, A.; Terenzi, V.; Iannetti, G. Anterolateral thigh flap for the reconstruction of head and neck defects: Alternative or replacement of the radial forearm flap? *J. Craniofac. Surg.* **2008**, *19*, 1148–1153. [[CrossRef](#)] [[PubMed](#)]
10. Martin, H.; DelValle, B.; Ehrlick, H.; Cahan, W.G. Neck Dissection. *Cancer* **1951**, *4*, 441–499. [[CrossRef](#)]
11. Ral, L.P.; Shukla, M.; Sharma, V.; Pandey, M. Mandibular conservation in oral cancer. *Surg. Oncol.* **2012**, *21*, 109–118.
12. Myers, L.L.; Sumer, B.D.; Truelson, J.M.; Ahn, C.; Leach, J.L. Resection and free tissue reconstruction of locally advanced oral cancer: Avoidance of lip split. *Microsurgery* **2011**, *31*, 347–352. [[CrossRef](#)] [[PubMed](#)]
13. Stanley, R.B. Mandibular lingual releasing approach to Oral and Oropharyngeal carcinomas. *Laryngoscope* **1984**, *94*, 596–600. [[CrossRef](#)] [[PubMed](#)]
14. Devine, J.C.; Rogers, S.N.; McNally, D.; Brown, J.S.; Vaughan, E.D. A comparison of aesthetic, functional and patient subjective outcomes following lip-split mandibulotomy and mandibular lingual releasing access procedures. *Int. J. Oral Maxillofac. Surg.* **2001**, *30*, 199–204. [[CrossRef](#)] [[PubMed](#)]
15. Gieringer, M.; Gosepath, J.; Naim, R. Radiotherapy and wound healing: Principles, management and prospects. *Oncol. Rep.* **2011**, *26*, 299–307. [[CrossRef](#)] [[PubMed](#)]
16. Calabrese, L.; Giugliano, G.; Bruschini, R.; Ansarin, M.; Navach, V.; Grosso, E.; Gibelli, B.; Ostuni, A.; Chiesa, F. Compartmental surgery in tongue tumours: Description of a new surgical technique. *Acta Otorhinolaryngol. Ital.* **2009**, *29*, 259–264. [[PubMed](#)]
17. Chang, E.I.; Yu, P.; Skoracki, R.J.; Liu, J.; Hanasono, M.M. Comprehensive analysis of functional outcomes and survival after microvascular reconstruction of glossectomy defects. *Ann. Surg. Oncol.* **2015**, *22*, 3061–3069. [[CrossRef](#)] [[PubMed](#)]
18. Dziegielewski, P.T.; O’Connell, D.A.; Rieger, A.; Harris, J.R.; Seikaly, H. The lip-splitting mandibulotomy: Aesthetic and functional outcomes. *Oral Oncol.* **2010**, *46*, 612–617. [[CrossRef](#)] [[PubMed](#)]
19. Cilento, B.W.; Izzard, M.; Weymuller, E.A.; Futran, N. Comparison of approaches for oral cavity cancer resection: Lip-split versus visor flap. *Otolaryngol. Head Neck Surg.* **2007**, *137*, 428–432. [[CrossRef](#)] [[PubMed](#)]
20. Dziegielewski, P.T.; Mlynarek, A.M.; Dimitry, J.; Harris, J.R.; Seikaly, H. The mandibulotomy: Friend or foe? Safety outcomes and literature review. *Laryngoscope* **2009**, *119*, 2369–2375. [[CrossRef](#)] [[PubMed](#)]

**Publisher’s Note:** MDPI stays neutral with regard to jurisdictional claims in published maps and institutional affiliations.



© 2020 by the authors. Licensee MDPI, Basel, Switzerland. This article is an open access article distributed under the terms and conditions of the Creative Commons Attribution (CC BY) license (<http://creativecommons.org/licenses/by/4.0/>).