



ISSN: 0976-3376

Available Online at <http://www.journalajst.com>

ASIAN JOURNAL OF  
SCIENCE AND TECHNOLOGY

Asian Journal of Science and Technology  
Vol. 14, Issue, 04, pp. 12481-12485, April, 2023

## RESEARCH ARTICLE

### RESULTS ASSESSMENT OF RECONSTRUCTIVE BONE SURGERY: 15 YEARS FOLLOW UP

Coniglione F.<sup>1,2</sup>, Luciani F.<sup>1</sup>, Papa E.<sup>3</sup>, Bartuli F.N.<sup>4</sup>, Agrestini F.<sup>5</sup>, Leggeri A.<sup>2</sup>, Pozzi A.<sup>2</sup>, Agrestini C.<sup>2</sup>, Arcuri C.<sup>2</sup> and Calabrese L.<sup>3</sup>

<sup>1</sup>DDS, PhD, Catholic University "Our Lady of Good Counsel". Department of Surgical Science - Tirana

<sup>2</sup>University of Roma "Tor Vergata", Department of Clinical Science and Translation Medicine

<sup>3</sup>University of Roma "Tor Vergata", Department of Surgical Science. Director U.O. Maxillofacial Surgery

<sup>4</sup>U.O.C. Odontostomatologia "San Giovanni Calibita Fatebenefratelli" Hospital, "Gemelli-Isola" Foundation

<sup>5</sup>Retired Full Professor of Oral Pathology, Sapienza University of Rome

#### ARTICLE INFO

##### Article History:

Received 10<sup>th</sup> February, 2023

Received in revised form

16<sup>th</sup> March, 2023

Accepted 21<sup>st</sup> March, 2023

Published online 27<sup>th</sup> April, 2023

##### Keywords:

Guided Tissue Regeneration; Periodontal Disease; Vertical Bones Defect; Periodontal Surgery.

#### ABSTRACT

Periodontal regenerative procedure is a surgical therapy that aims to make up new bone, radicular cement, periodontal ligament (identified as new periodontal attack), demonstrated by histologic studies. The damage of these periodontal tissues is an effect of periodontal disease or occlusal trauma. Histologically, the new attachment is different from the long epithelial attachment. This occurs when there is migration of the junctional epithelium instead of connective tissue. Both preclinical and clinical studies proved that periodontal regeneration can be successful using surgical procedures, that may or may not involve membranes or grafting materials. The present study describes the clinicopathological features of 5 patients with clinical and histopathological confirmation of periodontal disease, predominantly located into the zona of two inferior central incisors, which has determined the bone reabsorption of the bone peaks. This, ultimately, provided unesthetic spaces between the teeth. The results of the surgical therapy practiced in this case, were assessed by clinical and radiological control, to ensure correct resolution of the case.

**Citation:** Coniglione F *et al.* 2023. "Results assessment of reconstructive bone surgery: 15 years follow up", *Asian Journal of Science and Technology*, 14, (04), 12481-12485.

Copyright©2023, Coniglione F., Luciani F., Papa E., Bartuli F.N., Agrestini F., Leggeri A., Pozzi A., Agrestini C., Arcuri C. and Calabrese L. This is an open access article distributed under the Creative Commons Attribution License, which permits unrestricted use, distribution, and reproduction in any medium, provided the original work is properly cited.

## INTRODUCTION

The regeneration of the periodontium tissue implies a series of biological phenomena including mitogenesis, chemotaxis and adhesion of the periodontal tissues (Polimeni *et al.*, 2006). For this reason, the surgical techniques must involve ideal conditions in order to reach the success (Brunsvold *et al.*, 1993). One of options in the field of the regenerative technique involve graft material, contained by resorbable or non-resorbable membranes (Reynolds *et al.*, 2003). It has been demonstrated that the reduction of probing values and the gain in clinical attachment levels are superior to those obtained with open flap debridement alone (Trombelli *et al.*, 2002; Polimeni *et al.*, 2004; Cortellini *et al.*, 2015; Staubli *et al.*, 2018). The purpose of using these materials is trying to replace the alveolar bone, the periodontal ligament and the root cementum. The aforementioned materials are able to regenerate the periodontium since they contain osteoprogenitor cells which act as a scaffold, allowing totipotent cells to migrate and replicate (osteo-conduction). Furthermore, some of these materials contain molecules that may induce the formation of new bone (osteo-induction) (Tavelli *et al.*, 2020). Some recent studies would highlight how the most important prognostic factor is the depth and extent of the defect (Lo'e *et al.*, 1969) but also the regenerative

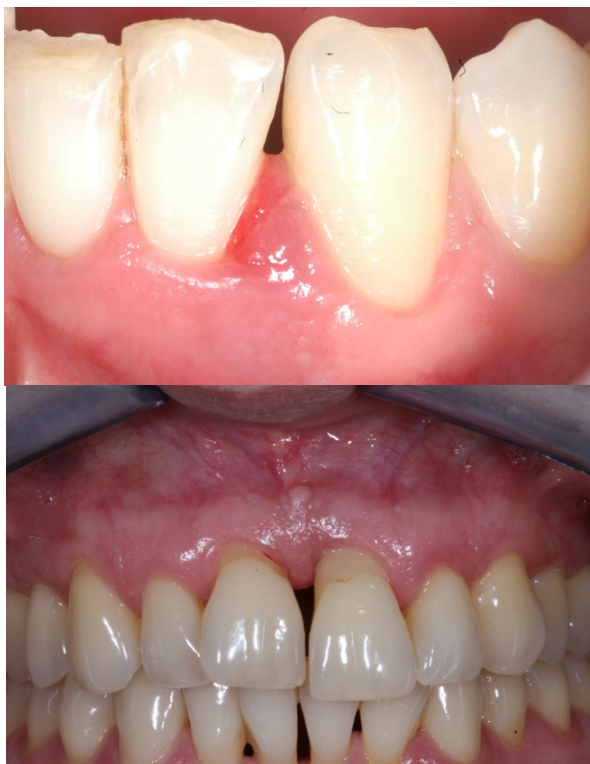capacity of the cells of the periodontal ligament (Melcher *et al.*, 1976; Karring *et al.*, 1980; Karring *et al.*, 1984; Cecchetti *et al.*, 2009; Nyman *et al.*, 1982; Lindhe *et al.*, 1984; Isidor *et al.*, 1985; Nyman *et al.*, 1982). Several authors have demonstrated that the regenerative potential of ligament cells is expressed when the epithelium and the connective tissue are separated from the defect (Lindhe *et al.*, 1984; Isidor *et al.*, 1985; Nyman *et al.*, 1982; Kao *et al.*, 2015). For this reason, various types of membranes were positioned to exclude the migration of the epithelium onto the root surface of the defect and allow the ligament cells to consume their regenerative potential (Lindhe *et al.*, 1984; Isidor *et al.*, 1985; Cecchetti *et al.*, 2010). To avoid the collapse of the membrane (not reinforced with titanium) during the healing processes, the simultaneous use of different filling materials has been proposed, such as deproteinized bone and heterologous deantigenized bone (Gottlow *et al.*, 1984; Wikesjo *et al.*, 1990). The major difficulties of this surgical methodology are represented by management of the soft tissues which must guarantee a perfect seal, in order to avoid exposure of the membrane (Urban *et al.*, 2019; Ottria *et al.*, 2017; Luciani *et al.*, 2022; Bartuli *et al.*, 2014).

## MATERIALS AND METHODS

Five clinical cases are presented. The patient's age is between 33 and 36 years. These patients came to our observation affected by localized periodontitis in an advanced state (Figs. 1, 2). The patients were in good health, therefore there were no absolute contraindications to the surgery.

\*Corresponding author: Coniglione F.,

DDS, PhD, Catholic University "Our Lady of Good Counsel". Department of Surgical Science - Tirana



**Figs. 1 (Case n°1 T=0), 2 (Case n°2 T=0)**

All patients were non-smokers. Probing depth and clinical attachment level were measured at time zero (first evaluation), after the causal phase (about 30 days) (Table 1), 1 year and 15 years after surgery (Table 2).

**Table 1.**

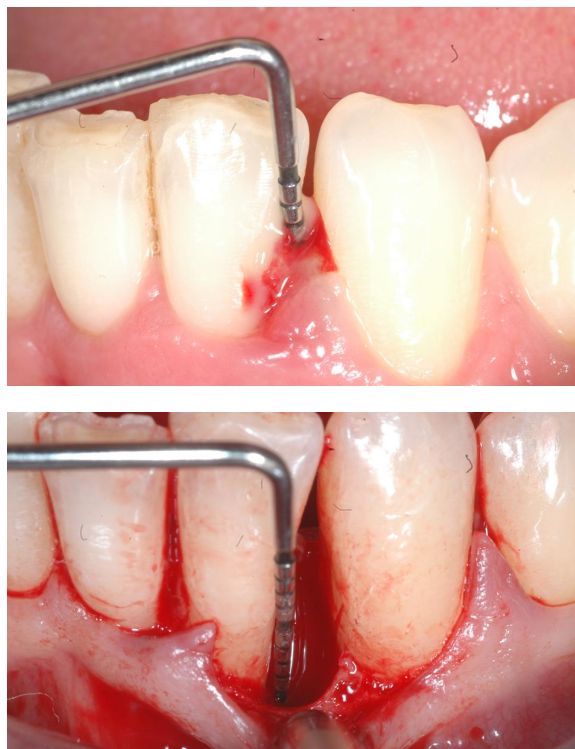|        | Probing T=0 | Probing after 30 gg | CA T=0 | CA after 30 days |
|--------|-------------|---------------------|--------|------------------|
| CASE 1 | 8 mm        | 7 mm                | 5 mm   | 5 mm             |
| CASE 2 | 10 mm       | 9 mm                | 7 mm   | 7 mm             |
| CASE 3 | 12 mm       | 11 mm               | 8 mm   | 8 mm             |
| CASE 4 | 14 mm       | 13 mm               | 11 mm  | 11 mm            |
| CASE 5 | 15 mm       | 14 mm               | 11 mm  | 11 mm            |

**Table 2**

|        | Probing after 1 year | Probing after 15 years | CA after 1 year | CA after 15 years |
|--------|----------------------|------------------------|-----------------|-------------------|
| CASE 1 | 3 mm                 | 4 mm                   | 2 mm            | 5 mm              |
| CASE 2 | 3 mm                 | 4 mm                   | 2 mm            | 5 mm              |
| CASE 3 | 4 mm                 | 5 mm                   | 3 mm            | 6 mm              |
| CASE 4 | 4 mm                 | 5 mm                   | 3 mm            | 6 mm              |
| CASE 5 | 5 mm                 | 6 mm                   | 4 mm            | 7 mm              |

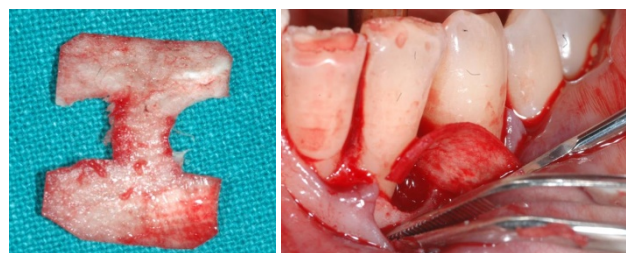
The causal therapy, included sessions dedicated to scaling and root planing in conjunction of home antibacterial therapy based on 0.2% and 0.12% Chlorhexidine. After a re-evaluation at fifteen and thirty days, the procedure was planned. The surgical treatment was performed under loco-regional anesthesia. After local anesthesia for periosteal infiltration with Mepivacaine 2% with vasoconstrictor (Adrenaline 1:100,000), intrasulcular incisions are made with No. 5 Bard-Parker scalpel with 15C blade followed by the elevation of flaps, without performing vertical release cuts. The detachment involves the total thickness up to the exposure of 3-4 mm apically to the defect, then proceeds in partial thickness detachment, up to the alveolar mucosa. We then proceed with debridement of the soft part of the defects, with the smoothing of the roots of the dental elements using Gracy's curet and piezoelectric equipment, with the elimination of plaque, tartar and necrotic cement. Subsequently, we proceed to conditioning the root surfaces through the use of Tetracyclines

(Doxycycline 250 mg cps), which with the dual decontaminating and collagenase action prepare the root surface and prolong the predictability of regeneration. The defect is then filled with deproteinated heterologous bone particles and, if necessary, a correctly shaped resorbable membrane is placed on the bone defect. The membrane is then covered and the flaps are repositioned with hermetic closure of the surgical site with Monocyl 4/0 and Vicryl 4/0 sutures with a V/5 Trocar Needle, with separate stitches, in order to preserve the papillae (Fig. 3a, 4a, 5a, 6a, 7a and Fig. 3b, 4b, 5b,).



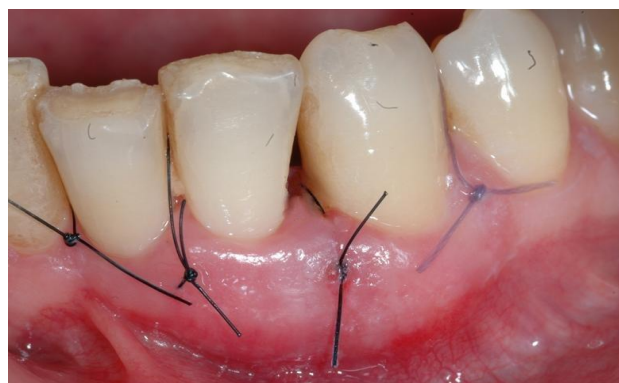*Case n°1 - Probing an evaluation of the defects*

**Figs. 3° (pre op), 4a (intra op)**



*Case n°1 - Membrane*

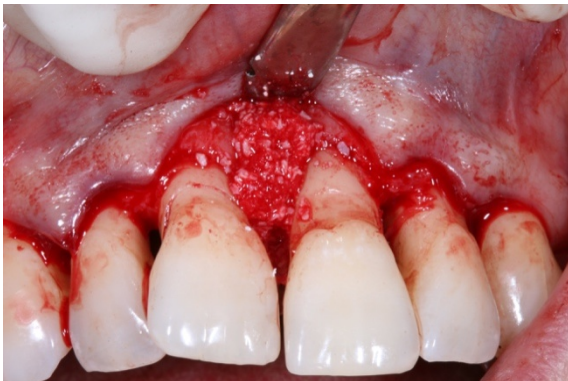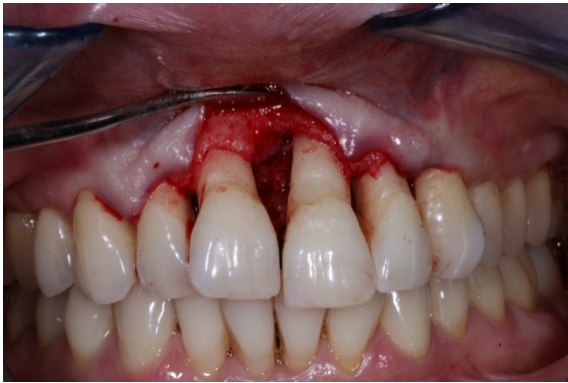**Figs. 5a (shaping), 6a (placement)**



*Case n°1 - Suture*

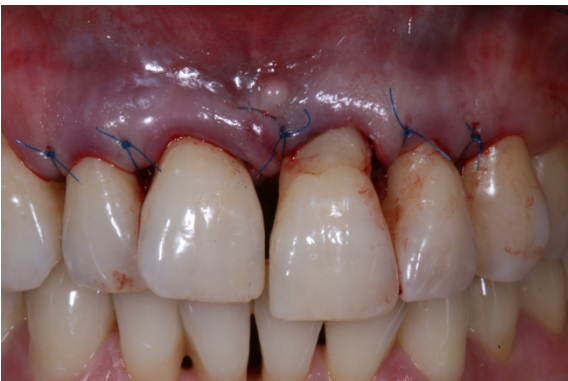**Figs. 7a (monocyl 4/0)**





Case n°2 - Intra op phases

Figs. 3b (evaluation of the defects intra op), 4b (intra op grafting)



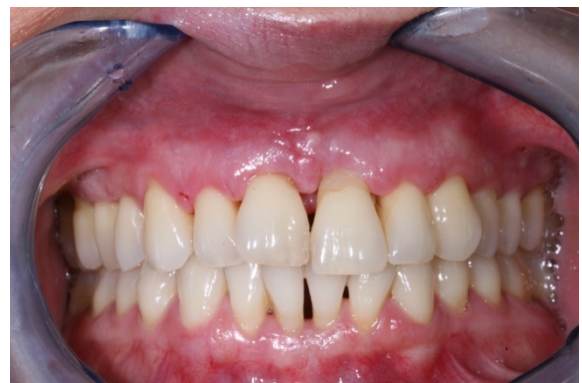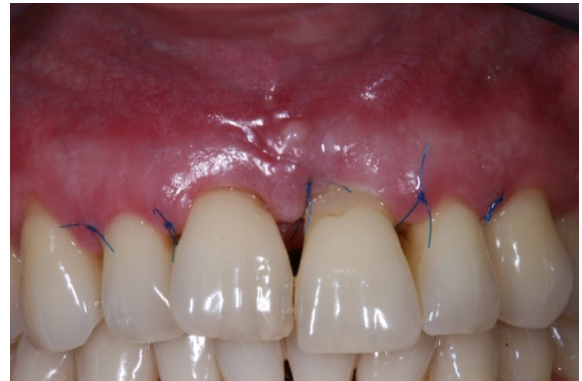Case n°2 - Suture

Figs. 5b (monocyl 4/0)

The flap must be sutured as coronally as possible and must be totally passive, in order not to affect the surgical result due to its traction, otherwise causing a recession with the exposure of the membrane (if its application is necessary). The patients were instructed in the control of bacterial plaque, using mouthwashes based on 0.2% chlorhexidine digluconate for 15 days without using the toothbrush and dental floss in the area of the operation. After 15 days, the sutures were removed (Fig 6b) and re-motivated again for correct oral hygiene and checked again 30 days after the operation (Fig 7b).

They were advised to use local gel based on 1% chlorhexidine two/three times a day, rinse with hydrogen peroxide and 0.2% chlorhexidine solution, without any use of a toothbrush for the first 15 days and maintenance of a liquid and/or soft diet for at least four weeks, in order to avoid trauma to the tissue healing site. The support program also included professional oral hygiene sessions at regular two-week intervals for six months. Probing of the defect and subgingival instrumentation were avoided for a period of 12 months. The parameters were collected before surgery, subsequently after one year and the stability of the results was re-evaluated after 15 years of follow up. The selected patients continued regularly every 4 months,

the supportive periodontal therapy sessions, the home use of 3% hydrogen peroxide, stabilized at 10 volumes, for 15 days a month, with the habit of using a toothbrush absolutely soft or super soft.



Case n°2 - Post op

Figs. 6b (15 days post op), 7b (30 days post op)

They were advised to use local gel based on 1% chlorhexidine two/three times a day, rinse with hydrogen peroxide and 0.2% chlorhexidine solution, without any use of a toothbrush for the first 15 days and maintenance of a liquid and/or soft diet for at least four weeks, in order to avoid trauma to the tissue healing site. The support program also included professional oral hygiene sessions at regular two-week intervals for six months. Probing of the defect and subgingival instrumentation were avoided for a period of 12 months. The parameters were collected before surgery, subsequently after one year and the stability of the results was re-evaluated after 15 years of follow up. The selected patients continued regularly every 4 months, the supportive periodontal therapy sessions, the home use of 3% hydrogen peroxide, stabilized at 10 volumes, for 15 days a month, with the habit of using a toothbrush absolutely soft or super soft.

During the checks we evaluated:

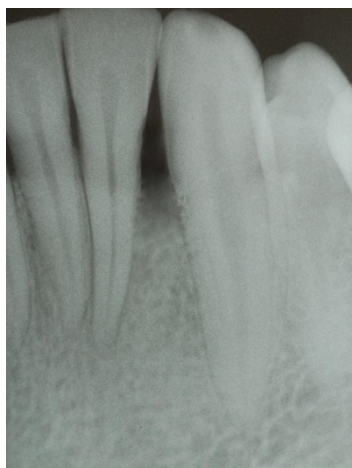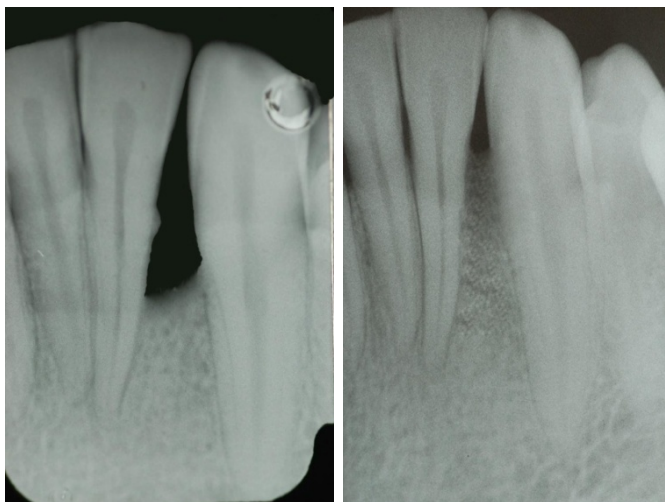
- Probing depth, from the gingival margin to the bottom of the pocket;
- Clinical attachment level, measured from the amelocemental junction to the bottom of the pocket;

## RESULTS

In case n°1, the depth of the defect before treatment was 8 mm, the clinical attachment level was 5 mm, with the presence of spontaneous bleeding. After the first periodontal phase, 30 days after the start of treatment, the depth of the defect had decreased to 7 mm, while the clinical attachment level remained unchanged (5 mm). After the first year after surgery, the patient did not show signs and symptoms of a flare-up of the periodontal disease, the probing level in the surgically treated area was 3 mm with an improvement of 4 mm; the clinical attachment level was 2 mm with an improvement of 3 mm. 15 years after the procedure, we observed a periodontal probing of 4 mm and

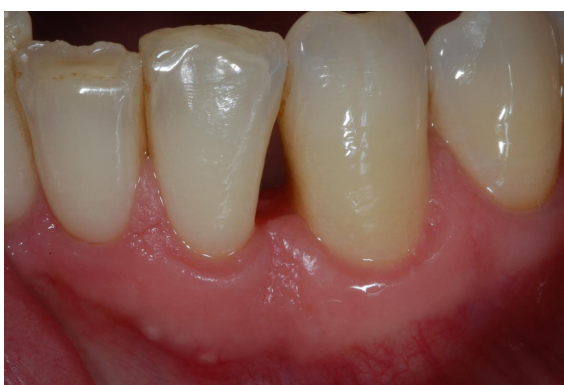the clinical attachment level passed to 5 mm. Radiographs performed after 15 years demonstrated the restoration of the physiological bone anatomy (Fig. 8a, 9a, 10a, 11a).

and the clinical attachment level passed to 5 mm. Radiographs performed after 15 years confirmed the clinical results obtained with regenerative periodontal surgery (Figs. 8b, 9b, 10b).



Case n°1

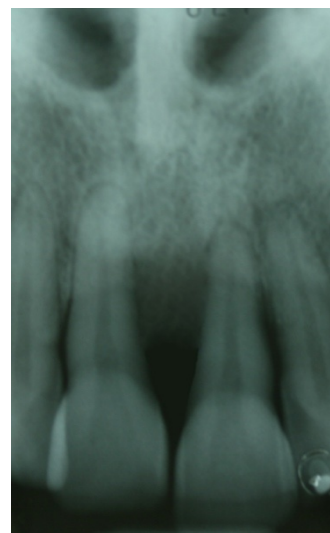
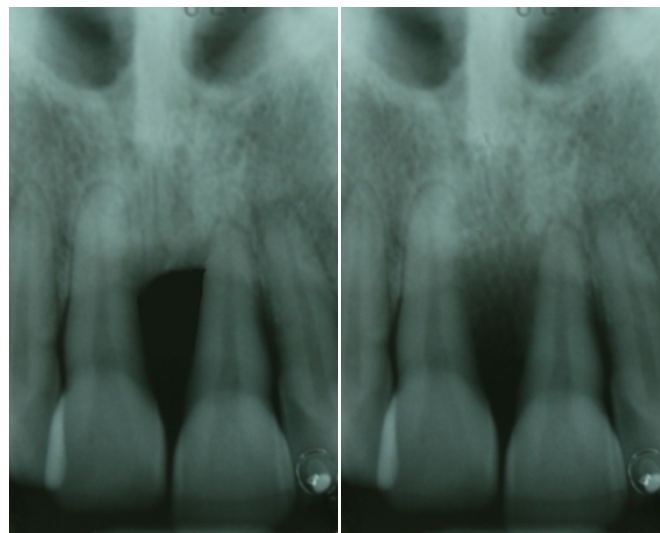
**Figs. 8a (pre op), 9a (90 days post op), 10a (15 years post op)**



Case n°1

**Figs. 11a (15 years follow up)**

In case n°2, the depth of the defect before treatment was 10 mm, the clinical attachment level was 7 mm, with the presence of bleeding on probing. After the first causal phase, 30 days after the start of treatment, the depth of the defect had decreased to 9 mm, while the clinical attachment level had remained unchanged (7 mm). After the first year after the regeneration surgery, the patient showed no signs of recurrence of the periodontal disease; the probing level in the surgically treated area was 3 mm with an improvement of 7 mm; the clinical attachment level was 2 mm with an improvement of 5 mm. 15 years after the operation, we observed a periodontal probing of 4 mm



Case n°2

**Figs. 8b (pre op), 9b (90 days post op), 10b (15 years post op)**

In case n°3, the depth of the defect before treatment was 12 mm, the clinical attachment level was 8 mm, with the presence of bleeding on probing. After the first causal phase, 30 days after the start of treatment, the depth of the defect had decreased to 11 mm, while the clinical attachment level had remained unchanged (8 mm). After the first year after the regeneration surgery, the patient showed no signs of recurrence of the periodontal disease; the probing level in the surgically treated area was 4 mm with an improvement of 8 mm; the clinical attachment level was 3 mm with an improvement of 5 mm. 15 years after the operation, we observed a periodontal probing of 4 mm and the clinical attachment level passed to 6 mm. Radiographs

performed after 15 years confirm the clinic and stability of the results obtained. In case n°4, the depth of the defect before treatment was 14 mm, the clinical attachment level was 11 mm, with the presence of bleeding on probing. After the first causal phase, 30 days after the start of treatment, the depth of the defect had decreased to 13 mm, while the clinical attachment level had remained unchanged (11 mm). After the first year after the regeneration surgery, the patient showed no signs of recurrence of the periodontal disease; the probing level in the surgically treated area was 4 mm with an improvement of 10 mm; the clinical attachment level was 3 mm with an improvement of 8 mm. Patient compliance in recalls had been excellent. 15 years after the operation, we observed a periodontal probing of 5 mm and the clinical attachment level passed to 6 mm. Radiographs performed after 15 years confirm the clinic and stability of the results obtained. In case n°5, the depth of the defect before treatment was 15 mm, the clinical attachment level was 11 mm, with the presence of bleeding on probing. After the first causal phase, 30 days after the start of treatment, the depth of the defect had decreased to 14 mm, while the clinical attachment level had remained unchanged (11 mm). After the first year after the regeneration surgery, the patient showed no signs of recurrence of the periodontal disease; the probing level in the surgically treated area was 5 mm with an improvement of 11 mm; the clinical attachment level was 4 mm with an improvement of 8 mm. The patient's compliance in the quarterly recalls had been excellent. 15 years after the operation, we observed a periodontal probing of 5 mm and the clinical attachment level passed to 6 mm. The radiographs performed after 15 years confirmed the clinical results obtained through the regenerative procedures (Table 2).

## CONCLUSIONS

We can therefore conclude that regenerative periodontal surgery, set up through a careful selection of the patients to whom it is proposed, carried out a correct diagnosis and a correct therapeutic planning, which takes into consideration all the factors that influence its course in the medium and long term, also in combination with the right compliance of the patients which must be kept constant over time to guarantee the stability of the results obtained, turns out to be a very valid and predictable treatment for the control and elimination of the acute phase of periodontal disease and the re-establishment of the correct anatomy and physiology of the supporting tissues of the destroyed teeth. In our opinion, given the success and stability of the results obtained, and from the experience of our school, the use of 3% hydrogen peroxide stabilized at 10 volumes should be greatly emphasized as an adjuvant in maintaining periodontal health, even in consideration of the fact that all patients who use it on a long-term basis have never had any type of adverse effect against a significantly and on average lower plaque and bleeding index than subjects who use it, for the control of bacterial plaque, chlorhexidine alone. However, in agreement with the literature, further data will have to be compared and analyzed in order to define a protocol for the use of the 3% hydrogen peroxide-based solution.

## REFERENCES

Bartuli FN, Piva P., Savo A, Di Dio M, Luciani F, Arcuri C. Lower Third Molar Germectomy: The Flap Recovery on The Lower Second Molar: a Clinical Study. *International Journal of Clinical Dentistry*. 2014 (7); 3: 289-294.

Brunsvold, M. A. & Mellonig, J. T. (1993) Bonegrafts and periodontal regeneration. *Periodontology* 2000 1, 80–91.

Cecchetti F., Luciani F., Bramanti E., Bartuli F.N., Ottria L., Arcuri C. Cemento-Ossifying Fibroma Juvenile of the Oral Cavity. *Oral & Implantology*; 2010 (3); 1: 32-37.

Cecchetti F., Luciani F., Nisi A., Bartuli F.N., Arcuri C. (2009) Chirurgia Plastica in Parodontologia. *Rivista Italiana di Stomatologia*; Anno LXXVII; Numero 3/2009; 18-23.

Coniglione F., Luciani F, Papa E., Leggeri A, Agrestini C. Usefulness and Reliability with CT-guided Surgery to Rehabilitate an ASA-III Patient: a clinical case report. *Albanian Journal of Medical Health Science*. 2022, 61: 1-11.

Cortellini, P., & Tonetti, M. S. (2015). Clinical concepts for regenerative therapy in intrabony defects. *Periodontology* 2000, 68(1), 282–307. <https://doi.org/10.1111/prd.12048>

Gottlow, J., Nyman, S., Karring, T. Lindhe, J. (1984) New attachment formation as a result of controlled tissue regeneration. *Journal of Clinical Periodontology* 11, 494–503.

Isidor, F., Karring, T., Nyman, S. Lindhe, J. (1985) New attachment-reattachment following reconstructive periodontal surgery. *Journal of Clinical Periodontology* 12, 728–735.

Kao, R. T., Nares, S., & Reynolds, M. A. (2015). Periodontal regeneration - intrabony defects: a systematic review from the AAP Regeneration Workshop. *Journal of periodontology*, 86(2 Suppl), S77–S104. <https://doi.org/10.1902/jop.2015.130685>

Karring, T., Nyman, S. & Lindhe, J. (1980) Healing following implantation of periodontitis affected roots into bone tissue. *Journal of Clinical Periodontology* 7, 96–105

Karring, T., Nyman, S., Lindhe, J. & Siriti, M. (1984) Potentials for root resorption during periodontal wound healing. *Journal of Clinical Periodontology* 11, 41–52.

Lindhe, J., Nyman, S. & Karring, T. (1984) Connective tissue reattachment as related to presence or absence of alveolar bone. *Journal of Clinical Periodontology* 11, 33–40.

Lo'e, H. & Waerhaug, J. (1961) Experimental replantation of teeth in dogs and monkeys. *Archives of Oral Biology* 3, 176–184.

Luciani F, Papa E., Leggeri A., Calabrese C., Coniglione F., Calabrese L. Diagnosis and Treatment Planning in Oral Surgery using Cone Beam Computed Tomography (CBCT): a Narrative Review. *International Journal of Clinical Dentistry*. 2022 (15); 4: 795-820.

Melcher, A. H. (1976) On the repair potential of periodontal tissues. *Journal of Periodontology* 47, 256–260.

Nyman, S., Gottlow, J., Karring, T. & Lindhe, J. (1982) The regenerative potential of the periodontal ligament. An experimental study in the monkey. *Journal of Clinical Periodontology* 9, 257–265.

Nyman, S., Gottlow, J., Karring, T. Lindhe, J. (1982) The regenerative potential of the periodontal ligament. An experimental study in the monkey. *Journal of Clinical Periodontology*

Ottria L., Luciani F., Piva P., Alagna AM, Arcuri C, Bartuli FN. The flap recovery on the impacted lower third molar surgery comparing 3 different flap designs: A clinical study. *Oral & Implantology*; 2017 (10); 3: 270-275. doi: 10.11138/orl/2017.10.3.270.

Polimeni, G., Koo, K. T., Qahash, M., Xiropaidis, A. V., Albandar, J. M. & Wikesjo U. M. E. (2004) Prognostic factors for alveolar regeneration: effect of a space-providing biomaterial on guided tissue regeneration. *Journal of Clinical Periodontology* 31, 725–729.

Polimeni, G., Xiropaidis, A. V. & Wikesjo, U.M. E. (2006) Biology and principles of periodontal wound healing/regeneration. *Periodontology* 2000 41, 30–47.

Reynolds, M. A., Aichelmann-Reidy, M. E., Branch-Mays, G. L. (2003) The efficacy of bone replacement grafts in the treatment of periodontal osseous defects. A systematic review. *Annals of Periodontology* 8, 227–265.

Staubli, N., Schmidt, J. C., Buset, S. L., Gutekunst, C. J., Rodriguez, F. R., Schmidlin, P. R., & Walter, C. (2018). Traditional or regenerative periodontal surgery?—a comparison of the publications between two periodontal journals over time. *Clinical oral investigations*, 22(1), 29–46. <https://doi.org/10.1007/s00784-017-2159-2>

Tavelli, L., McGuire, M. K., Zucchelli, G., Rasperini, G., Feinberg, S. E., Wang, H. L., & Giannobile, W. V. (2020). Biologics-based regenerative technologies for periodontal soft tissue engineering. *Journal of periodontology*, 91(2), 147–154. <https://doi.org/10.1002/JPER.19-0352>

Trombelli, L., Heitz-Mayfield, L., Needleman, I., Moles, D. & Scabbia, A. (2002) A systematic review of graft materials and biological agents for periodontal intraosseous defects. *Journal of Clinical Periodontology* 29 (Suppl. 3), 117–135.

Urban, I. A., & Monje, A. (2019). Guided Bone Regeneration in Alveolar Bone Reconstruction. *Oral and maxillofacial surgery clinics of North America*, 31(2), 331–338. <https://doi.org/10.1016/j.coms.2019.01.003>.

Wikesjo, U. M. E. Nilve'us, R. (1990) Periodontal repair in dogs: effect of wound stabilization on healing. *Journal of Periodontology* 61, 719–724.