

## Real Time Three Dimensional Fetal Echocardiography Using Two Dimensional Array Technology.

Dev Maulik\*, MD, PhD, David Mundy, MD and Timothy Bennett, MD

*Department of Obstetrics and Gynecology, University of Missouri-Kansas City School Medicine, Kansas City, Missouri, USA*

**Abstract:** Three dimensional (3D) echocardiography represents a major paradigm shift in medical ultrasound imaging. As opposed to reconstructed 3D echocardiography which is based on a series of two dimensional images, the revolutionary development of the two dimensional (2D) matrix phased array transducer permits true real time live 3D imaging of the fetal heart. Preliminary experience has demonstrated that real time/live 3D echocardiography is not only feasible in assessing the fetal cardiac anomalies, it also permits unique comprehensive views of the fetal heart that are unattainable with 2D echocardiography. With further evolution of the technology, and appropriate education and training RT3D echocardiography may evolve as a powerful supplement to conventional 2D echocardiography.

**Key Words:** Real time three dimensional, Fetal echocardiography, Live 3D, Two dimensional matrix transducer.

### INTRODUCTION

Congenital heart disease (CHD) continues to be a significant contributor to adverse perinatal outcomes and its prenatal recognition significantly improves the perinatal outcome [1]. Prenatal diagnosis of CHD has been possible only because of the advances in fetal echocardiography over the last three decades (Table 1). Recent advances in three dimensional (3D) ultrasound imaging represent one of the most important technological innovations in this field. Even in 2D echocardiography, the operator conceptually recreates the spatial 3D reality of the fetal heart out of the 2D sonographic images. Although the current approach continues to function well, the advantages of 3D imaging are potentially significant revealing anatomical and functional complexities of the heart.

Currently there are two approaches to 3D sonography: (a) real time 3D (RT3D) echocardiography which generates and displays 3D images in real time, and (b) reconstructed 3D echocardiography which displays 3D images synthesized from sequential 2D images [2]. Real time 3D echocardiography is also known as live 3D echocardiography. The term four dimensional echocardiography is used to denote 3D images in motion, time being the fourth dimension. However, this may not distinguish between real time and reconstructed images. The technology of real time 3D echocardiography is still evolving and this review critically appraises this emerging technology in relation to fetal applications. The use of real time 3D in adult cardiac imaging [3] and in fetal cardiac assessment have been reported [4].

**Table 1:** Developmental History of Fetal Echocardiography

Echo Mode	First Author	Journal
M-mode	Winsberg	Invest Radiol, 1972
2D Echo	Allan et al	Br Heart J, 1980
	Kleinman et al	Pediatrics, 1980
Duplex M-mode	DeVore et al	Am J Ob Gyn, 1980
Duplex PW Doppler	Maulik et al	Am J Cardiol, 1982
Color Flow Doppler	Maulik et al	Am J Cardiol, 1985(Ab)
		Angiology, 1986

\*Address correspondence to Dev Maulik MD: Department of Obstetrics and Gynecology, University of Missouri Kansas City School Medicine, 2411 Holmes Street Kansas City, MO 64108-2792 USA Email: umkc\_som\_journal@umkc.edu

## DEVELOPMENT OF THREE DIMENSIONAL ECHOCARDIOGRAPHY

The innovation of 3D medical imaging can be traced to computed tomography (CT) and magnetic resonance imaging (MRI) technologies and essentially where the 2D tomographic image slices generated by these modalities are digitally reconstructed to produce 3D images. These developments have revolutionized medical imaging and diagnostics. However, even with the continuing advances in technology, CT and MRI are not useful for diagnostic imaging of the fetal heart.

Over the past decades, pioneering investigators utilized various experimental approaches involving offline reconstruction of 2D images [5-7]. The mode of image acquisition required locating the position of the transducer so that images could be collated in 3D spatial orientation. The method of tracking the transducer location included mechanical acoustic and magnetic devices. One of the most frequently utilized techniques in adult echocardiography employed a rotational transesophageal transducer with reconstruction of the 3D images with on or offline computers. However, these 3D methods could not perform in real time because of technological limitations.

Similar technical solutions evolved for creating of 3D echocardiographic images in the fetus [8, 9]. These approaches were based on postimaging reconstruction of fetal cardiac anatomy out of stored scanned volume data acquired by automatic or freehand techniques. These techniques produced fetal cardiac images that were not amenable to any useful interpretation because of the image quality and a lack of coherence between cardiac anatomical imaging and cardiac activity. These limitations, however, were substantially rectified through the innovation of gating techniques such as spatio-temporal image correlation (STIC) combined with a motorized rotating transducer head [10]. The method was innovated in Kretztechnik of Austria which is now a subsidiary of GE Healthcare. This approach is currently available in various ultrasound devices and is used to produce surface rendered images of the fetus (Figure ). There are numerous reports on fetal echocardiography using reconstructed approach with STIC. However, this approach does not offer true real time 3D cardiac imaging and has several limitations including high susceptibility to motion artifacts.

Two dimensional phased array technology for true RT3D ultrasound imaging was developed at the Duke University by von Ramm and associates [11]. Apparently the idea was first conceived for potential use as a sonar camera for underwater search and rescue. Because of its diagnostic potentials, the concept led to the development of medical imaging transducers with 2D array of numerous piezoelectric elements. and sparse phased array technology. In this array system, only a limited set of the elements of the array are used for transmission and reception of echoes. The image resolution of the sparse array technology was not adequate and the device as produced commercially (Volumetrics Ultrasound, North Carolina, USA) was not widely used. The next significant advances occurred in the Andover facility of the Agilent Technologies Healthcare Solutions Group, now a part of the Philips Medical System (Andover, Massachusetts, US) leading to the development of second generation two dimensional phased array technology. More recently, Siemens has also developed its own brand of real time 3D imaging technology. However, this is not available for fetal application at the time of writing this review.

The developmental milestones of 3D echocardiography of the fetus are summarized in Table 2.

**Table 2:** Developmental History of Three Dimensional Fetal Echocardiography

<b>Echo Mode</b>	<b>First Author</b>	<b>Journal</b>
3D Fetal Echo – 2D image integration	Sklansky et al	J Ultrasound Med, 1999
Reconstructed 3D Fetal Echo – STIC	DeVore et al	Ultrasound Ob Gyn, 2003
Real time 3D	Maulik et al	Echocardiography, 2003

## BASIC PRINCIPLES OF REAL TIME THREE DIMENSIONAL SONOGRAPHY

There are three fundamental steps of 3D sonography: (a) image acquisition, (b) image processing and (c) image display. These steps are sequential. Contemporaneous implementation of these processes during scanning constitutes RT3D ultrasound (Fig. 1).

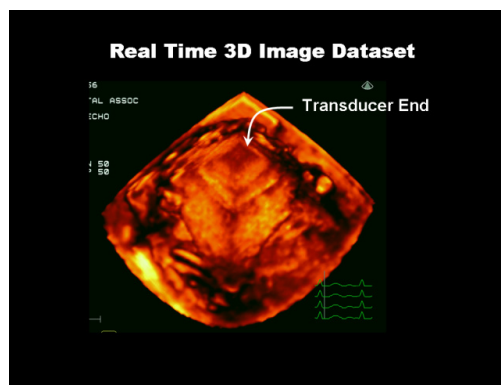
## IMAGE ACQUISITION AND PROCESSING

### Two Dimensional Matrix Transducer

The 2D matrix transducer is a phased array device comprised of approximately two to three thousand piezoelectric elements distributed in a two dimensional matrix array. All the elements transmit and receive unlike the sparse array system. The system steers the acoustic beam both in the azimuth and elevation producing a 3D pyramidal volume image data set in real time. The enormous volume of data thus generated offer a formidable challenge for real time processing. However, this issue was resolved by organizing the elements in groups known as subarrays with each subarray having its own beamformer. The subarray beam forming provides front end processing of the ultrasound signals, reduces the enormous computing burden, and facilitates RT3D image generation and display. Multiple miniaturized computer processor boards embedded inside the transducer handle perform this task.

### Image Data Processing

The 3D image data are then transmitted to the ultrasound device's main computer system which handles simultaneously multiple streams of digital image data. Utilizing advanced data processing, the system generates a three dimensional pyramid shaped digital image data set (Fig. 1).

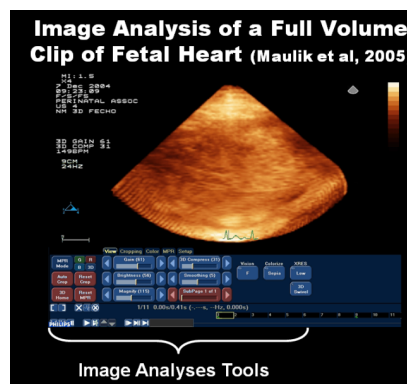


**Figure 1:** Real time 3D image data set is displayed. The upper end of the pyramid indicates the two dimensional transducer footprint (arrow).

No gating is needed for this acquisition. This is known as the live 3D volume acquisition. A wider pyramidal volume known as the full volume measuring can also be imaged by swift automatic real time acquisition and integration of subvolumes. Generation of the full volume, however, requires some form of cardiac gating. In the adult or pediatric patient this is provided by the electrocardiogram of the patient. Obviously this is not feasible in the fetus. We have successfully simulated cardiac gating with an external electronic pulse generator trigger enabling us to acquire full volume data set of the fetal heart without any recognizable artifacts. The gating function is now integrated in the device.

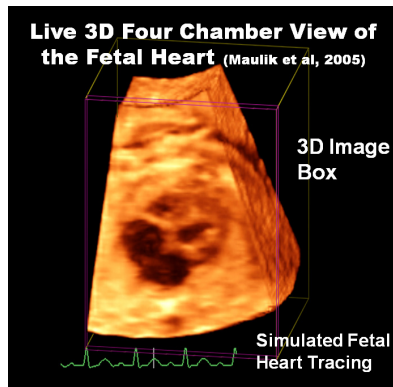
## THREE DIMENSIONAL IMAGE DISPLAY AND ANALYSES

The final critical component in 3D imaging is the analyses and display of the volume data set. This can be performed on the machine or offline using a proprietary software program (QLab, Philips Medical Systems) (Fig. 2).



**Figure 2:** Real time 3D fetal echocardiography: A full volume 3D image data clip of the fetal heart and software image analysis tools are displayed in this illustration.

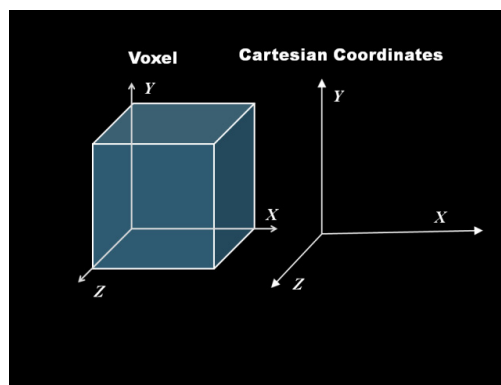
Three dimensional images can be displayed by (a) surface rendering with identification of various structures, or (b) volume rendering which creates a texture mapped block such as a pyramidal 3D object which can be rotated and cropped to reveal internal structures or flow (Fig. 3).



**Figure 3:** Live 3D echocardiogram showing a four chamber view of the fetal heart. Fine line box depicts 3D orientation of the image data. The electrocardiogram in the lower part of the figure is actually simulated fetal heart tracing.

In addition to the structural evaluation, assessment of several cardiac functional parameters such as the ventricular volume and the ejection fraction can be determined. The software also allows optimization of the image attributes such as brightness and contrast. Fetal applications of these echocardiographic techniques are further discussed below.

The 3D image processing and display require defining the spatial location of a point in 3D space from the image data. The unit of 3D spatial graphic information is known as a voxel. The term stands for volume pixel and constitutes the smallest definable unit of a 3D image. A voxel is the 3D counterpart of a pixel which defines location in a 2D plane. Geometrically, the relative spatial locations of a voxel are represented by the Cartesian coordinates  $x$ ,  $y$  and  $z$  (Fig. 4).

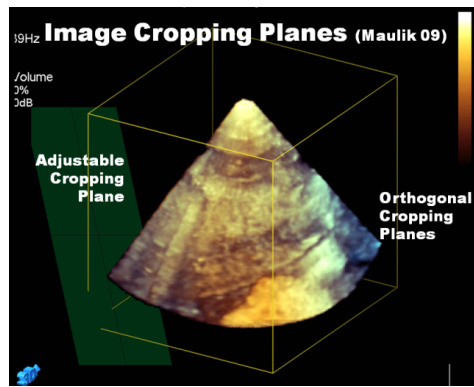


**Figure 4:** Graphic illustration of the concept of a voxel which forms the units of the 3D image data. X, Y and Z represents the orthogonal coordinates (Cartesian) for the 3D space.

The location is defined by the point's distances from three orthogonal planes determined by these coordinates. This is a fundamental concept for 3D image processing and interpretation. Each voxel can be digitally quantified to represent objective properties such as opacity, density, color, velocity, or even time.

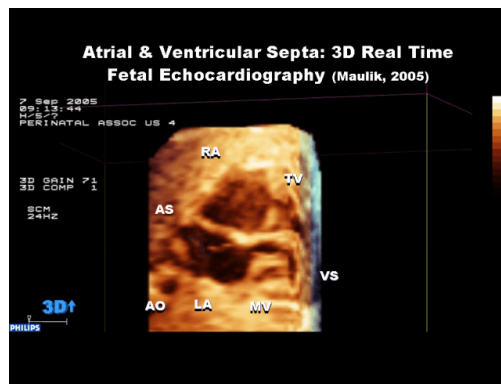
### VOLUME RENDERED VIEWS

The volume rendered moving image clips are reanalyzed with the software. This includes cropping image volume along the Cartesian orthogonal co-ordinates, X, Y, Z (Fig. 5). Additional intracardiac anatomical views can be revealed by rotating the cropped 3D volume. Cropping can also be performed in variable inclined or oblique planes also known as adjustable planes.



**Figure 5:** Real time 3D fetal echocardiography. Fetal cardiac 3D image volume data is shown with the orthogonal (line box around the volume) and adjustable (green panel) cropping planes.

This technique permits a systematic examination of the cardiac chambers, the atrioventricular connections, the mitral and tricuspid valves, the interventricular and interatrial septa, and the outflow tracts and their interrelationship (Fig. 6).

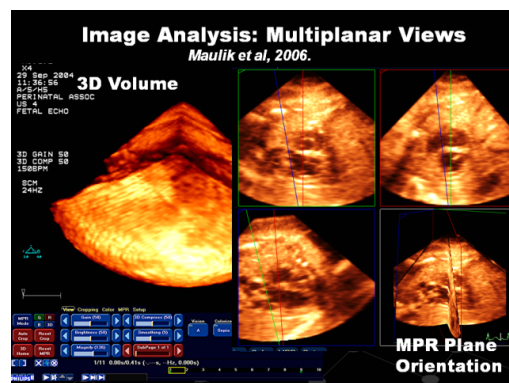


**Figure 6:** Real time 3D fetal echocardiogram showing cardiac structures following cropping in two orthogonal planes and rotating the image data set.

Moreover, it enables visualization of surface or “en face” views of intracardiac structures. Such anatomical views and details could be of great value for prenatal diagnosis and prognostication.

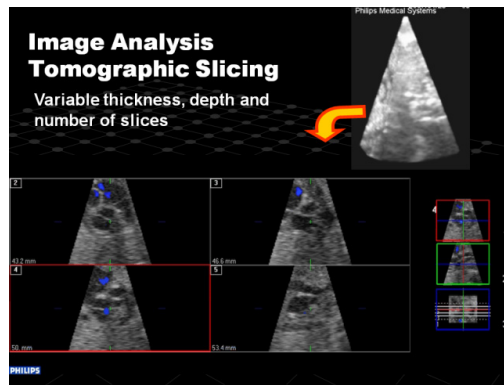
## TWO DIMENSIONAL VIEWS OF THREE DIMENSIONAL IMAGE DATA: MULTIPLANAR AND TOMOGRAPHIC VIEWS

Multipanar viewing using orthogonal and inclined planes can also be performed revealing display of 2D cardiac images in three separate planes simultaneously (Fig. 7).



**Figure 7:** Real time 3D fetal echocardiography. The left panel shows the 3D image data volume and the software analytic tools. The right panel shows multiplanar views of the fetal heart. The lower right subpanel shows the image planes (MPR) of the other three 2D cardiac images.

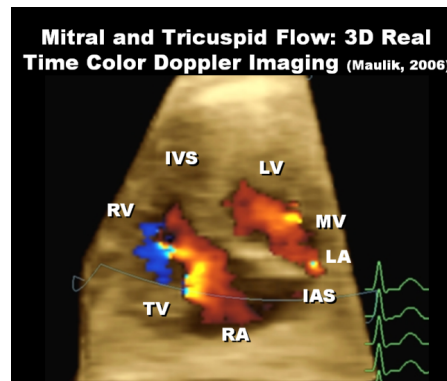
Similarly, tomographic 2D image slices of the heart can be generated with control over the region of interest, the number of slices and the thickness of a slice (Fig. 8)



**Figure 8:** Real time 3D fetal echocardiogram showing the tomographic slicing of the 3D cardiac image volume (upper right panel). The lower most right panels show the orientation, thickness and number of image slices.

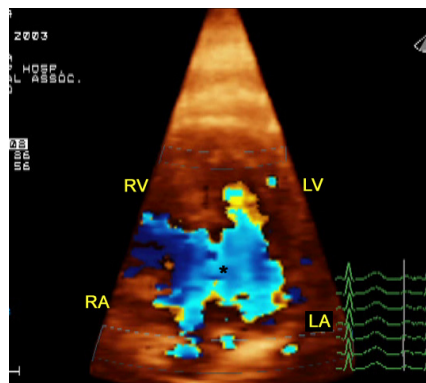
### THREE DIMENSIONAL REAL TIME COLOR DOPPLER ECHOCARDIOGRAPHY

Three dimensional color Doppler imaging of the intracardiac flow can be acquired with 2D matrix array technology (Fig. 9). However, the inherent limitations of Doppler sonography such as angle dependence are also applicable in these modalities.



**Figure 9:** Real time 3D color Doppler fetal echocardiogram showing atrioventricular flow. LA = left atrium; LV = left ventricle; RA = right atrium; RV = right ventricle; MV = mitral valve; TV = tricuspid valve; IAS = interatrial septum; IVS = interventricular septum; S = ventricular septum

Three dimensional color Doppler flow depiction can be used to quantify abnormal flow conditions such as regurgitant jets and turbulent flow (Fig. 10). Potential also exists to quantify volumetric flow using this approach.



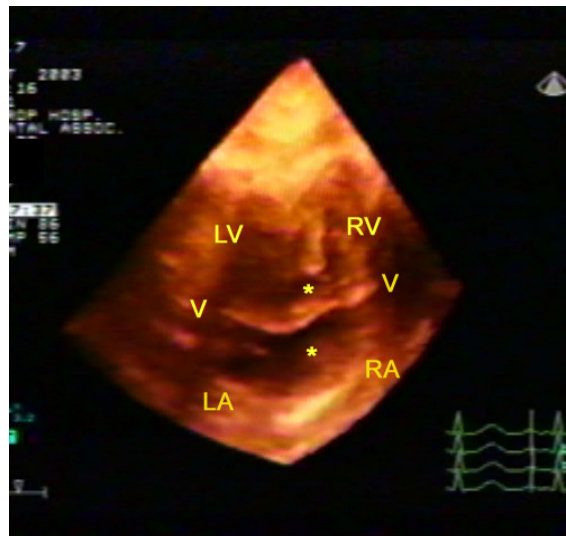
**Figure 10:** Live 3D echocardiography in 36 week old fetus with complete atrioventricular septal defect. Four chamber views cropped to show the abnormal atrioventricular hemodynamics. (Modified with permission from reference 4)

## FUNCTIONAL ASSESSMENT OF THE HEART

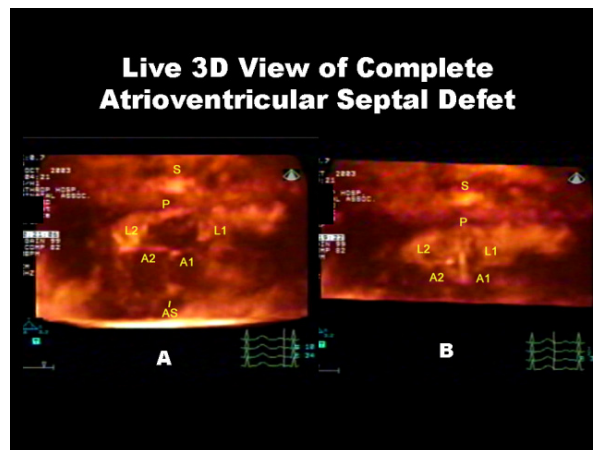
An additional innovative aspect of the image analytic software is the ability to perform dynamic cardiac quantification such as the ventricular volume through the cardiac cycle and the ejection fraction. The distinct advantage of RT3D approach over traditional echocardiography is that it is not subject to assumptions regarding the volume and the shape. The current RT3D technology allows fast creation of a full 3D wire-mesh endocardial volume that is sensitive to the annulus and apex motions. Detailed analysis of the left regional and global ventricular function can be performed using RT3D technology.

## FETAL APPLICATION OF RT3D ECHOCARDIOGRAPHY

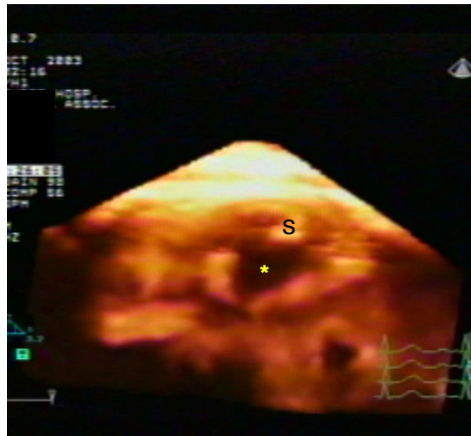
The feasibility of using RT3D fetal echocardiography was demonstrated by Maulik and colleagues in 2003. The study demonstrated the unique capabilities of the technique in clarifying the complex structural and hemodynamic abnormalities of congenital heart defects of the fetus. Specifically, the en face views of cardiac lesions such as common atrio-ventricular valves or a ventricular septal defect provide anatomical perspectives beyond the scope of the existing two dimensional echocardiography technology (Figs. 11, 12 and 13) [4].



**Figure 11:** Live 3D echocardiography in 36 week old fetus with complete atrioventricular septal defect. Four chamber views cropped to show the common atrioventricular valve (v) and the defect (asterisk). (Modified with permission from reference 4)



**Figure 12:** Live 3D echocardiography in 36 week old fetus with complete atrioventricular septal defect. The pyramidal section has been cropped from the top and rotated toward the examiner to display all five leaflets of the common atrioventricular valve (V); posterior (P), left lateral (L1), left anterior (A1), right anterior (A2), and right lateral (L2). Small portion of the ventricular septum (S) and atrial septum (AS) have been retained to show their relationship to V. V is open in A and closed in B (Modified with permission from reference 4)



**Figure 13:** Live 3D echocardiography in 36 week old fetus with complete atrioventricular septal defect. En face viewing of the defect (asterisk) from the inferior aspect. (Modified with permission from reference 4)

Subsequent publications have further confirmed this [12]. Acar and colleagues used RT3D echocardiography using the matrix probe in 60 fetuses 16 of whom had congenital cardiac defects or myocardial dysfunction. The procedure was successful in 93%. The investigators found the technique helpful allowing a multiplanar and novel inside 3D views of the fetal heart. Chen and co-workers compared diagnostic efficacy of RT3D echocardiography with 2D echocardiography in 30 patients with complex defects. [13]. Receiver operating characteristic (ROC) analysis showed that when in predicting the surgical findings, RT3D echocardiography was correct in 75.6% and 2D echocardiography was correct in 64.4% of the cases.

### CHALLENGES FOR REAL TIME 3D ECHOCARDIOGRAPHY OF THE FETUS

The major challenge for the current stage of the technology is the natural resistance to adopting apparently complex new technology. This is partly related to the fact the value of real time 3D echocardiography in prenatal diagnosis of complex cardiac defects remains underestimated. There are also technological issues related to fetal application of the technology. This technology is developed primarily for adult and pediatric cardiac diagnosis and therefore is not optimized for fetal application. Specifically the currently available 3 Mz adult transducer may not provide optimal resolution for prenatal diagnosis. The current 7 MHz pediatric transducer provides significantly improved image resolution but may not always provide enough depth penetration. The newer generation transducers with pure crystal technology may improve this situation.

The software tools for image analysis are highly sophisticated but may offer a steep learning curve for many. A recent study demonstrated the benefits of intensive education and training on the diagnostic efficacy. Jenkins and associates [14] investigated the impact of an intensive interactive training course on the efficacy of RT3D echocardiography in adult patients and found that training significantly improved the correct diagnosis rate of the new technique. However, there was no additional value of the technique over traditional 2D technology without such training although most participants had access to the RT3D method. This would be even more relevant for fetal application of the technology. Emergence of automation in image analysis may also significantly enhance its adoption for the main stream practice. Finally there is a great need for further research and education in this field.

### REFERENCE

- [1] Tworetzky W, McElhinney DB, Reddy VM, Brook MM, Hanley FL, Silverman NH Improved surgical outcome after fetal diagnosis of hypoplastic left heart syndrome. *Circulation*. 2001;103:1269-73.
- [2] Maulik D. "Four Dimensional B Mode and Color Doppler Echocardiography of the Human Fetus." In Maulik, D (ed) *Principles and Practice of Doppler Sonography in Obstetrics and Gynecology*, 2nd Edition; Springer-Verlag, NY. 2005.
- [3] Singh V, Nanda NC, Agrawal G, Vengala S, Dod HS, Misra V, Narayan V. Live three-dimensional echocardiographic assessment of mitral stenosis. *Echocardiography*. 2003;20:743-50.
- [4] Maulik D, Nanda NC, Singh V, *et al* Live three-dimensional echocardiography of the human fetus. *Echocardiography*. 2003;20:715-21.
- [5] Dekker DL, Piziali RL and Dong E Jr. A system for ultrasonically imaging the human heart in three dimensions. *Computer Biomed Research*. 1974; 7:544-553.



- [6] Ghosh A, Nanda NC, Maurer G. Three-dimensional reconstruction of echo-cardiographic images using the rotation method. *Ultrasound Med Biol.* 1982;8:655-61.
- [7] Matsumoto M, Inoue M, Tamura S, Tanaka K, Abe H. Three-dimensional echocardiography for spatial visualization and volume calculation of cardiac structures. *J Clin Ultrasound.* 1981;9:157-65.
- [8] Sklansky MS, Nelson TR, Pretorius DH. Three-dimensional fetal echocardiography: gated versus nongated techniques. *J Ultrasound Med.* 1998;17:451-7.
- [9] Falkensammer P, Brandl H. *Ultrasound Technology Update: 4D fetal echocardiography; Spatio-temporal image correlation.* GE Medical Systems, Kretz Ultrasound 2003; <http://www.gemedicalsystems.com>.
- [10] DeVore GR, Polanco B, Sklansky MS, Platt LD. The 'spin' technique: a new method for examination of the fetal outflow tracts using three-dimensional ultrasound. *Ultrasound Obstet Gynecol.* 2004;24:72-82.
- [11] Von Ramm OT, Smith SW, Pavy HG Jr. High speed ultrasound volumetric imaging system. Part II. Parallel processing and image display. *IEEE Trans Ultrason Ferroelec Ferq Contr.* 1991; 38:109-115.
- [12] Acar P, Dulac Y, Taktak A, Abadir S. Real-time three-dimensional fetal echocardiography using matrix probe. *Prenat Diagn.* 2005;25:370-5.
- [13] Chen GZ, Huang GY, Tao ZY, Liu XQ, Lin QS. Value of real-time 3-dimensional echocardiography sectional diagnosis in complex congenital heart disease evaluated by receiver operating characteristic analysis. *J Am Soc Echocardiogr.* 2008;21:458-63.
- [14] Jenkins C, Monaghan M, Shirali G, Guraraja R, and Marwick TH. An intensive interactive course for 3D echocardiography: is 'crop till you drop' an effective learning strategy? *Eur J Echocar* (2008) 9, 373–380.