

Case report - Congenital

Importance of accurate diagnosis using real-time three-dimensional echocardiography in the surgical treatment of congenital intramitral ring in infants

Malgorzata Pawelec-Wojtalik^{a,b,*}, Fiore S. Iorio^{b,c}, Ashraf M. Anwar^{b,d}, Ashraf A.H. El Midany^{b,e}^aDepartment of Pediatric Cardiology, University of Medical Sciences, Poznan, Poland^bDepartment of Pediatric Cardiology, KFAFH, Jeddah, Kingdom Saudi Arabia^cDepartment of Cardiac Surgery, Tor Vergata University Hospital, Rome, Italy^dDepartment of Cardiology, Al Azhar University, Cairo, Egypt^eDepartment of Cardiac Surgery, Ain Shams University, Cairo, Egypt

Received 18 May 2011; received in revised form 29 July 2011; accepted 3 August 2011

Abstract

Congenital mitral ring is a rare type of congenital mitral stenosis. There are two types of mitral ring: the intramitral ring and the supramitral ring. Intramitral rings are often associated with complex valve pathology, and therefore have a worse prognosis than supramitral rings, in which the mitral apparatus is usually normal. The role of echocardiography in the evaluation of the mitral valve apparatus is crucial, because it allows an identification of the types of malformation, their hemodynamic repercussion and early predictors of the outcome. We describe two cases of intramitral ring, the diagnostic challenge they provided, and the value of the information obtained using real-time three-dimensional echocardiography in such cases.

© 2011 Published by European Association for Cardio-Thoracic Surgery. All rights reserved.

Keywords: Mitral valve stenosis, congenital; Mitral valve stenosis; Real-time three-dimensional echocardiography

1. Introduction

Congenital anomalies of the mitral valve (MV) comprise a wide range of leaflet anomalies and anomalies of the subvalvular apparatus. Isolated congenital mitral stenosis (CMS) constitutes a very rare lesion. It is often associated with other heart defects, such as aortic valve stenosis, coarctation of the aorta (CoA) and septal defects. In such cases, pulmonary hypertension can develop very early in life [1].

Two types of mitral ring have been identified: the supramitral (SMVR) and the intramitral (IMVR) ring [2]. Surgical repair of CMS in low-birthweight infants is a challenging procedure [3]. Surgical results are better in SMVR and IMVR cases than in other forms of CMS. A quick and accurate diagnosis is instrumental to the overall outcome of the treatment [2].

We would like to describe here our experience with two low-birthweight infants with IMVR co-occurring with other cardiac problems. The use of real-time three-dimensional echocardiography (RT3DE) in the second case was decisive in making an adequate diagnosis and recommending surgical treatment.

2. Case reports

2.1. Case report 1

A 3 kg, four-month-old baby was admitted for closure of a large ventricular septal defect (VSD). Two-dimensional echocardiography (2DE) showed a large VSD of 7–10 mm, moderate CMS with an MV annulus of 9 mm and a maximal diastolic gradient (PG_{max}) of 18 mmHg, elevated right ventricular systolic pressure (RVSP) 43 mmHg, a persistent foramen ovale, and a patent ductus arteriosus (PDA). The surgical decision was to close the VSD and PDA, and at that particular moment no correction of the MV was advised.

The child was administered sildenafil treatment (2 mg/kg/d) postoperatively and discharged from hospital in good condition. Postoperative 2DE examination showed no residual VSD, the RVSP was 49 mmHg and the MV diastolic PG_{max} was 19 mmHg. Follow-up 2DE five months later revealed an increase in diastolic PG_{max} to 44 mmHg across the MV. Subsequently, the decision was to repair or even replace the MV.

Intraoperative transeophageal echocardiography (TEE) showed a small MV annulus, as well as leaflets that were not fully open during diastole and were abnormally bent, with discrete mitral regurgitation. At operation, an IMVR connected to the anterior and posterior leaflets was found. The ring was removed, and a gentle commissurotomy was performed.

*Corresponding author. Department of Pediatric Cardiology, University of Medical Sciences, Szpitalna 27/33, Poznan, Poland. Tel.: +48-603681182.

E-mail address: mpwojt@poczta.onet.pl (M. Pawelec-Wojtalik).

The child was discharged in good clinical condition. Early postoperative 2DE showed mild MV regurgitation, a diastolic PG_{max} of 20 mmHg and an RVSP of 38 mmHg.

2.2. Case report 2

A 4 kg, six-month-old infant diagnosed with VSD, atrial septal defect and pulmonary hypertension was admitted with stable hemodynamics. 2DE revealed a small VSD, ASD type II, CMS with a diastolic PG_{max} of 22 mmHg, CoA and pulmonary hypertension. The left ventricle and MV annulus were of adequate size, and there were two papillary muscles. An abnormally bent posterior MV leaflet was found, suggesting IMVR (Fig. 1a). The MV diastolic PG_{max} was 22 mmHg, and the RVSP was 57 mmHg.

RT3DE was performed using an IE 33 (Philips Medical System, WA, USA) with an S8-3 probe. Full volume acquisition was obtained from an apical window, and cropping was performed to obtain an en face view of the MV. Both the anterior and posterior MV leaflets were mildly thickened and attached to two separate papillary muscles. In between the two leaflets, a small, thick, incomplete ring-like structure was entangled (Fig. 1b). It was decided to correct the CoA, close the PDA and band the pulmonary artery (PA) only.

After six months, the MV diastolic PG_{max} increased dramatically to 34 mmHg, and the RVSP to 70 mmHg. The child did not grow well; his body weight was only 4.7 kg. Thus, a decision was taken to repair the MV.

Intraoperatively, the incomplete IMVR was found crossing the posteromedial commissure and was peeled off (Fig. 2). The MV was mildly thickened with good coaptation and

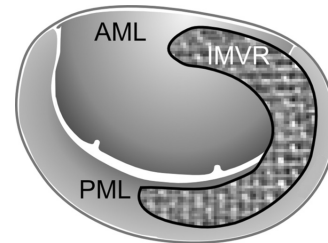


Fig. 2. Schematic representation of intraoperative findings. AML, anterior mitral leaflet; IMVR, intramitral ring; PML, posterior mitral leaflet.

opening. The postoperative course was uneventful. The patient was administered sildenafil (2 mg/kg/d) and discharged home after 10 days with echo findings of RVSP 60 mmHg and MV diastolic PG_{max} 11 mmHg, and a trivial mitral insufficiency.

3. Discussion

The majority of patients with CMS are likely to undergo MV repair, with good results [3]. Surgical repair of the MV is not always successful, and valve replacement may eventually be necessary. Among the factors potentially increasing the risk, and thus contributing to the poor overall result, are age less than one year and associated cardiac anomalies [4]. The two children in the cases were younger than one year and had a low bodyweight and complex cardiac diseases.

Different types of CMS have been described by Moore et al., one of them being the supralvalvular mitral ring [2, 5]. This type of mitral stenosis has good operative prognosis [2, 6].

Adequate diagnosis of the SMVR may be difficult [2]. We had difficulty diagnosing the IMVR in our first patient too, despite the fact that the TEE was carried out before the operation. The experience we gained in the course of treating the first patient allowed us to raise suspicion based on the 2DE in the second case.

Previous studies have shown that the use of RT3DE can improve the detection of MV abnormalities in young children [7, 8]. In the second case, RT3DE proved the diagnosis of IMVR by giving a detailed anatomical description of the MV apparatus (leaflets, papillary muscles, orifice and chordae). The en face view of the MV confirmed to the surgeon that the decision to operate was correct and, additionally, the surgeon found the RT3DE image to be useful due to its similarity to the surgical view seen intraoperatively.

A two-step surgical treatment was applied in both cases. The diagnosis in the second child was accurate very early on, but the operation on the MV was delayed by six months, as it was deemed a high-risk surgical procedure (it was difficult to convince the surgeon to correct the MV anomaly). Despite very good operative results and correct MV function, both children demonstrated elevated pulmonary artery pressure and needed sildenafil treatment.

Due to the fact that the membrane has been shown to increase during infancy, early surgical repair of the MV (i.e. before the changes in the ventricles and pulmonary hypertension become significant) is crucial [2].

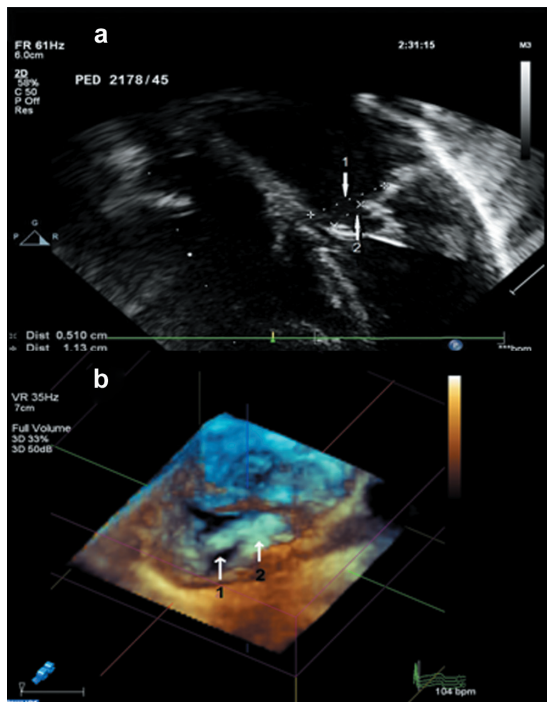


Fig. 1. (a) Two-dimensional echocardiography showing an apical four-chamber view. Arrow one indicates the mitral valve (MV) annulus, and arrow two an abnormally bent posterior MV leaflet. (b) Real-time three-dimensional echocardiography image showing an en face view of the MV. Arrow one shows the MV orifice, and arrow two the intramitral ring.

4. Conclusions

RT3DE is a useful tool in diagnosing an intramitral membrane in low-birthweight infants, which provides a unique opportunity to obtain adequate early diagnosis, and thus subsequently allows to satisfying surgical results to be obtained.

References

- [1] Serraf A, Zoghbi J, Belli E, Lacour-Gayet F, Aznag H, Houyel L, Lambert V, Piot D, Planche C. Congenital mitral stenosis with or without associated defects: an evolving surgical strategy. *Circulation* 2000;102:166–171.
- [2] Toscano A, Pasquini L, Iacobelli R, Di Donato RM., Raimondi F, Carotti A, Di Ciommo V, Sanders SP. Congenital supra-valvar mitral ring: an underestimated anomaly. *J Thorac Cardiovasc Surg* 2009;137:538–542.
- [3] Hoashi T, Bove EL, Devaney EJ, Hirsch JC, Ohye RG. Mitral valve repair for congenital mitral valve stenosis in pediatric population. *Ann Thorac Surg* 2010;90:36–41.
- [4] Prifti E, Vanini V, Bonaacchi M, Frati G, Bernabei M, Giunti G, Crucean A, Luisi SV, Murzi B. Repair of congenital malformations of the mitral valve: early and midterm results. *Ann Thorac Surg* 2002;73:614–621.
- [5] Moore P, Adatia I, Spevak PJ, Keane JF, Perry SB, Castaneda AR, Lock JE. Severe congenital mitral stenosis in infant. *Circulation* 1994;89:2099–2106.
- [6] Collison SP, Kaushal SK, Dagar KS, Iyer PU, Girotra S, Radhakrishnan S, Shrivastava S, Iyer KS. Supramitral ring: good prognosis in a subset of patients with congenital mitral stenosis. *Ann Thorac Surg* 2006;81:997–1001.
- [7] Thakahashi K, Macki AS, Rebryka IM, Ross DB, Robertson M, Dyck JD, Inage A, Smallhorn F. Two-dimensional versus transthoracic real-time three-dimensional echocardiography in the evaluation of the mechanisms and sites of atrioventricular valve regurgitation in a congenital heart disease population. *J Am Soc Echocardiogr* 2010;23:726–734.
- [8] Zakkar M, Patni R., Punjabi PP. Mitral valve regurgitation and 3D echocardiography. *Future Cardiol* 2010;6:231–242.