

POR 00278

Pseudo aneurysm of the external carotid artery: report of a case

M. Maurizi, G. Almadori, G. Paludetti, F. Ottaviani and A. Loschi

Institute of Otorhinolaryngology, University of Perugia, Perugia (Italy)

(Received August 14th, 1984)

(Accepted October 3rd, 1984)

Key words: one-year-old infant – otorrhagia – non-invasive diagnosis – surgical treatment

Summary

The authors report a case of left otorrhagia in a 1-year-old male infant in the presence of a mass involving the parotideal and upper cervical regions, which had appeared after an infection of the upper airways. Non-invasive techniques, such as echography and CT scan, provided useful but contradicting information. Surgery allowed us to define the diagnosis of mycotic aneurysm of the external carotid artery. The authors, after pointing out the extreme rarity of such a pathology, discuss the ethiopathogenetic theories, the clinical features, the diagnosis and the surgical and medical treatment of the disease. Concerning surgery ligation of the external carotid artery is the treatment of choice, since distally the blood flow is provided by a conspicuous collateral circle and because a possible postoperative septic dissemination is avoided.

Introduction

Aneurysms of the extracranial carotid artery are extremely rare [3,10,19,24,25]. Atherosclerosis, blunt or penetrating traumas, infections, cystic medial necrosis, fibromuscular dysplasia and congenital anomalies are the most common causes of cervical carotid aneurysms, which occur with decreasing frequencies in the common, internal and external carotid arteries, respectively [8,12,15,26,32]. Mycotic carotid aneurysms are even more uncommon [1,11,14,16], especially during childhood [33];

Correspondence: M. Maurizi, Istituto di Clinica Otorinolaringoiatrica, dell' Università, Policlinico Monteluce, I-06100 Perugia, Italy.

in fact, to our knowledge, no case affecting the external carotid artery has been described in the literature since 1966.

The aim of the present paper is to report a case of an external carotid artery aneurysm in an infant, resulting from a cervical infection, and to point out the main diagnostic and therapeutic aspects.

Case Report

A.R., a 1-year-old male infant, was referred to our Clinic because of a brisk and profuse left otorrhagia. At the physical examination, a hard, fixed mass, involving the parotideal and upper cervical regions was present (Fig. 1). It had appeared after an acute tonsillitis 4 days before, followed by an inferior facial palsy. The left palatine tonsil and the lateral pharyngeal wall were medialized. In spite of an antibacterial therapy (erythromycin), he showed fever, dysphagia and occipital and auricular pain at admission. Leucocytosis, increased ESR and ASL, and a slight hypochromic microcytic anaemia were detected. The CT scan showed an almost round and conspicuous mass involving the left soft cervical tissues, without osteolytic lesions, cancelling the muscular structures and showing density values around +45, characteristic of parenchymal tissues (Fig. 2). A liquid content could instead

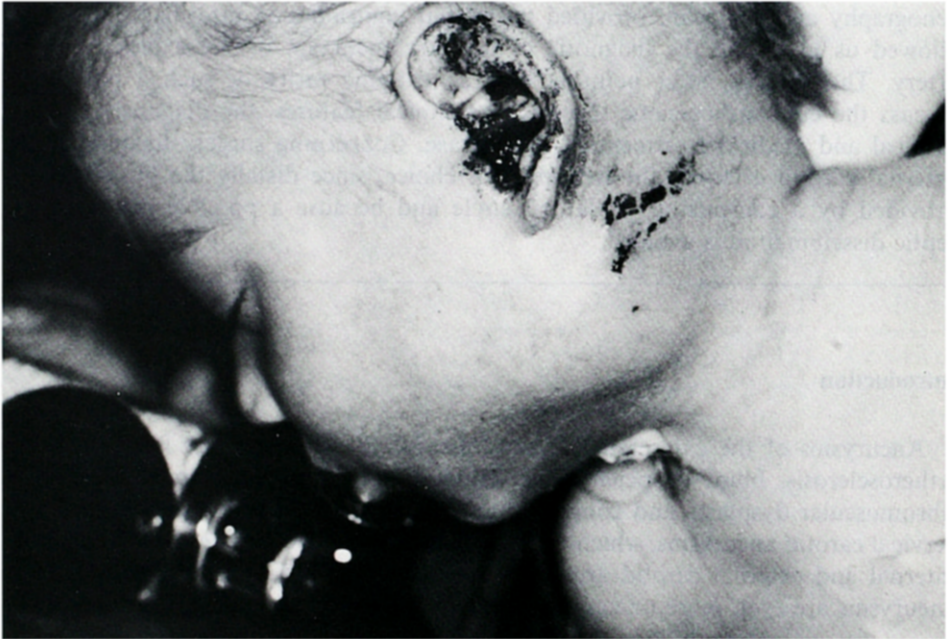

Fig. 1. A.R., 1 year. A hard, fixed mass involving the parotideal and upper cervical regions is evident. A left otorrhagia is present.

be detected at echography (Fig. 3). The day after the admission, while performing a toilet of the external auditory meatus, a new brisk and profuse bleeding occurred, which could hardly be stopped by packing. At surgery, immediately behind and beneath the mandibular angle, a cavity was detected as large as an orange, with an incomplete 15 mm thick wall, containing coagulated blood and clearly purulent material (Fig. 4A). After having removed some coaguli, a brisk haemorrhage occurred from the external carotid artery, which showed a clear-cut interruption. The artery was proximally and distally ligated and a toilet of the cavity was performed, removing all the coaguli and the wall (Fig. 4B). A large communication between the external auditory meatus and the cavity became thus evident. Histology revealed necrotic and fibrous tissue with a conspicuous haemorrhagic infiltration. The postoperative course was satisfactory. The infant was discharged after 8 days without fever and an 8-month follow-up showed excellent local and general conditions.

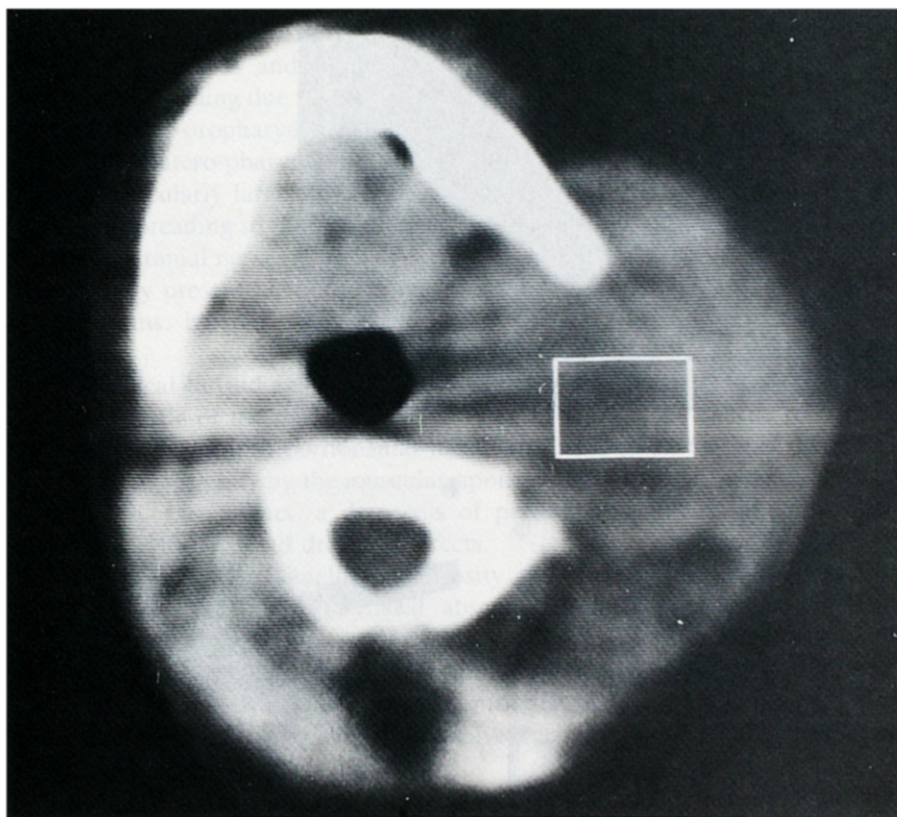


Fig. 2. Cervical CT scan shows an almost round mass involving the whole upper cervical left region, without osteolytic signs, cancelling the normal muscular structures. The density is substantially homogeneous around values of +45, such as of parenchymal tissues.

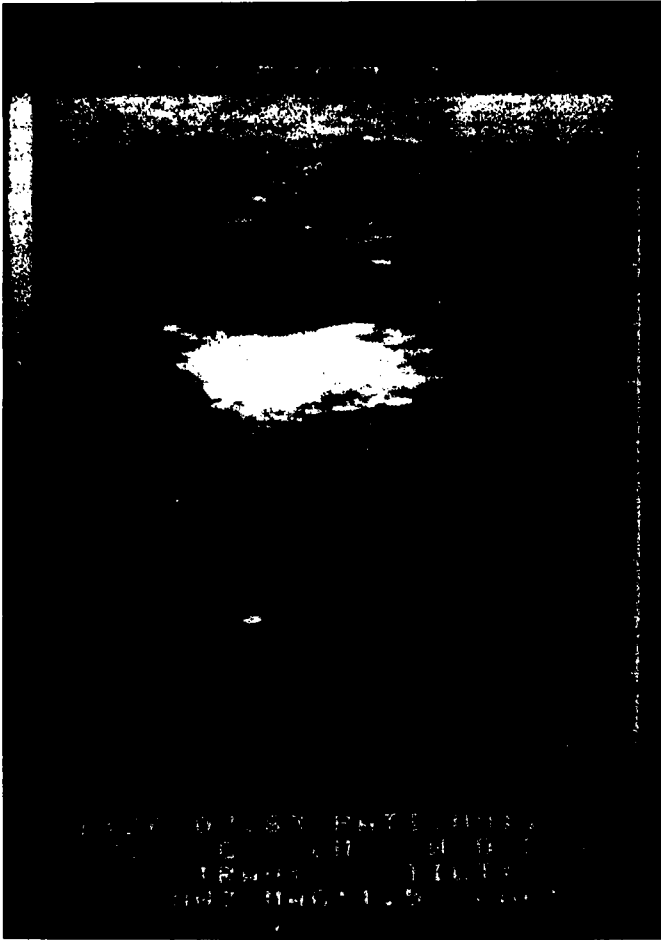


Fig. 3. Transverse echography of the upper cervical mass indicates the presence of liquid content.

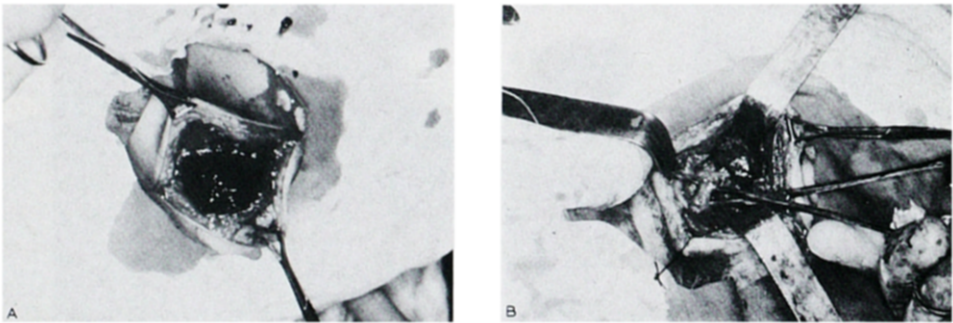


Fig. 4. At surgery, a cavity containing coagulated blood and clearly purulent material could be detected (A). After having removed the coaguli, a brisk haemorrhage occurred from the external carotid artery, that showed a clear-cut interruption. Bleeding stopped after ligating the distal and proximal branches of the artery (B).

Discussion

Aneurysms due to infection are improperly defined 'mycotic', a term first used by Osler [22] to denote aneurysms which resulted from septic emboli originating in vegetations of bacterial endocarditis. The term has subsequently been modified to include any infection in the walls of aneurysms either from luminal spread via vasa vasorum or local extension of an adjacent infectious process. Based upon the pre-existing arterial status and upon the sources of infection, they can be classified as primary, secondary, cryptogenetic and embolomycotic aneurysms due to intravascular (infected emboli, septicemia or extension of endocardial infections) or extravascular sources [23], as the reported case.

In the mycotic aneurysms due to extravascular infection, the infectious agents reach the arterial wall via the perivascular lymphatic vessels; its destruction causes a massive bleeding and sometimes the formation of haematoma within the surrounding tissues, better known as 'pseudoaneurysms' or 'false aneurysms' [1]. The bacterial agents commonly involved are *Streptococcus β -haemolyticus*, *Bacteroides fragilis*, anaerobic organisms and some mycotic agents particularly resistant to medical treatment [2,11,16].

The most serious and dramatic symptom is represented by an often hardly controllable bleeding due to spontaneous rupture into the nose, the external auditory meatus and the oropharynx [4,6,9,28,34]. Blood reaches the external auditory meatus through the latero-pharyngeal space, the parotideal lodge and from the Santorini spaces, particularly large in infants [34]. Common but less dramatic symptoms are local pain spreading to the occipital and auricular areas, involvement of the VII, IX, X and XII cranial nerves and of the superior cervical ganglion, and fever; leucocytosis is usually present [5,8,13]. Less commonly observed are severe, recurrent facial pain, tinnitus, blurred vision and dizziness, probably due to transient cerebral ischemia.

The cervical carotid aneurysms are usually characterized by a pulsating mass just below the angle of the mandible; sometimes, however, they can be recognized as a pulsating pharyngeal or peritonsillar mass, with little or no external manifestations, being pushed medially by the muscular-aponeurotic system of the neck [27,29,31]. In the present case, in fact, a diagnosis of peritonsillar abscess and its subsequent drainage, could have had dramatic effects.

Differential diagnosis includes tortuosity and kinking of neck arteries, lymphangiomas, peritonsillar or pharyngeal abscesses, branchial cleft cysts. The history, clinical and instrumental signs, such as echography, CT scan and arteriography are necessary for a correct diagnosis. In the present case diagnosis was made based upon otorrhagy, as instrumental data were conflicting, with echography being the more accurate. Arteriography, which would have been the more reliable technique, was not performed due to age [8,11,27].

The clinical course of mycotic aneurysms may be rapid such as in the reported case or, more often, slow, with a progressive enlargement of the aneurysm until rupture and bleeding within the surrounding soft tissues [1].

Ligation and excision of the aneurysm represent the safest treatment. If aneurysm

presents spontaneous rupture and bleeding, ligation of proximal and distal branches of the artery has to be performed [16,20]. If the aneurysm involves a critical artery, the blood circulation can be restored by means of an autologous bypass [5,7,16–18,30]. This second procedure may be dangerous, provoking a postoperative septic dissemination if the infection is not totally eradicated and therefore it should be performed only if necessary. In all cases, however, an appropriate antibacterial treatment should be performed before, during, and after surgery [23]. In the present case the restoration of the distal circulation by means of a bypass seemed unnecessary, because a collateral blood flow rapidly follows after ligation of external carotid artery; the risk of disseminating emboli and of an often fatal rebleeding could thus be avoided.

References

- 1 Anderson, C.B., Mycotic aneurisms. In R.B. Rutherford (Ed.), *Vascular Surgery*, W.B. Saunders, Philadelphia, 1977, pp. 709–721.
- 2 Anderson, C.B., Butcher, H.R. and Ballinger, W.F., Mycotic aneurysms, *Arch. Surg.*, 109 (1974) 712–717.
- 3 Beall, A.C., Crawford, E.S., Cooley, D.A. and De Bakey, M., Extracranial aneurysms of the carotid artery. Report of seven cases, *Postgrad. Med.*, 32 (1962) 93–102.
- 4 Busby, D.R., Shemmons, D.M. and Miller, T.F., Fatal epistaxis via carotid aneurysm and eustachian tube, *Arch. Otolaryng.*, 87 (1968) 295–298.
- 5 Day, A.L., Extracranial–intracranial bypass grafting in the surgical treatment of bacterial aneurysms: report of two cases, *Neurosurgery*, 9 (1981) 583–588.
- 6 Ehni, G. and Barrett, J.H., Haemorrhage from the ear due to an aneurysm of the internal carotid artery, *New Engl. J. Med.*, 87 (1960) 1323–1325.
- 7 Fiévet, P., Veyssier, P., Grunewald, P. and Philippe, J.M., Anéurisme ‘mycotique’ primitif de la carotide primitive. A propos d’un cas, *J. Chir.*, 116 (1979) 527–530.
- 8 Goldstone, J., Aneurysms of the extracranial carotid artery. In R.B. Rutherford (Ed.), *Vascular Surgery*, W.B. Saunders, Philadelphia, 1977, pp. 1131–1139.
- 9 Hashemi, H.A., Mazhari, A., Radbod, K. and Kamren, B., ‘Otorrhagia’. A symptom of posterior auricular artery aneurysm, *J. Laryng.*, 92 (1978) 1127–1132.
- 10 Houser, O.W. and Baker, H.L., Jr., Fibromuscular displasia and other uncommon diseases of the cervical carotid artery: angiographic aspects, *Amer. J. Roentgenol.*, 104 (1968) 201–212.
- 11 Howell, H.S., Baburao, T. and Graziano, J., Mycotic cervical carotid aneurysm, *Surgery*, 81 (1977) 357–359.
- 12 Johnston, J.N., Helsby, C.R. and Stell, P.M., Aneurysm of the external carotid artery, *J. cardiovasc. Surg.*, 21 (1980) 105–107.
- 13 Kaupp, H.A., Haid, S.P., Jurayj, M.N., Bergan, J.J. and Trippel, O.H., Aneurysms of the external carotid artery, *Surgery*, 72 (1972) 946–952.
- 14 Lambert, M.J. III, Johns, M.E., Mentzer, R. and Fitz-Hugh, G.S., Mycotic carotid artery aneurysms, *Otolaryng. Head Neck Surg.*, 87 (1979) 624–627.
- 15 Lane, R.J. and Weisman, R.A., Carotid artery aneurysms: an otolaryngologic perspective, *Laryngoscope*, 90 (1980) 897–911.
- 16 Ledgerwood, A.M. and Lucas, C.E., Mycotic aneurysm of the carotid artery, *Arch. Surg.*, 109 (1974) 496–498.
- 17 Monson, R.C. and Alexander, R.H., Vein reconstruction of a mycotic internal carotid aneurysm, *Ann. Surg.*, 191 (1980) 47–50.
- 18 Mundth, E.D., Darling, R.C., Alvarado, R.H., Buckley, M.S., Linton, R.R. and Austen, W.G., Surgical management of mycotic aneurysms and the complications of infections in vascular reconstructive surgery, *Amer. J. Surg.*, 117 (1969) 460–470.

- 19 Nakao, G.C., Extracranial Aneurysms der Arteria Carotis Interna, *Med. Klin.*, 63 (1969) 58–60.
- 20 O'Connorn, T.W., Lord, R.S.A. and Tracy, G.D., Treatment of mycotic aneurysms, *Med. J. Aust.*, 2 (1972) 1161–1163.
- 21 Okafor, B.C., Aneurysm of the external carotid artery following a foreign body in the pharynx, *J. Laryng.*, 92 (1978) 429–434.
- 22 Osler, W., The Gulstonian lectures on malignant endocarditis, *Brit. med. J.*, 1 (1885) 467–470.
- 23 Patel, S. and Johnston, K.W., Classification and management of mycotic aneurysms, *Surg. Gynec. Obstet.*, 144 (1977) 691–694.
- 24 Raphael, H.A., Bernatz, P.E., Spittel, J.A. Jr. and Ellis, F.M., Cervical carotid aneurysms: treatment by excision and restoration of arterial continuity, *Amer. J. Surg.*, 105 (1963) 771–778.
- 25 Reid, M.R., Aneurysms in the Johns Hopkins Hospital (all cases treated in the Surgical Service from the opening of the hospital to January, 1922), *Arch. Surg.*, 12 (1926) 1–74.
- 26 Rhodes, E.L., Stanley, J.C. Hoffman, G.L., Cronenwett, J.L. and Fry, W.J., Aneurysms of the extracranial carotid artery, *Arch. Surg.*, 105 (1972) 786–789.
- 27 Rittenhouse, E.A., Radke, M. and Summer, D.S., Carotid artery aneurysm: review of the literature and report of a case with rupture into the oropharynx, *Arch. Surg.*, 105 (1972) 786–789.
- 28 Salinger, S., 'Symposium on Tonsil Surgery: Hemorrhage from pharyngeal and peri-tonsillar abscess'. *Laryngoscope*, 44 (1934) 765.
- 29 Shipley, A.M., Winslow, N. and Walker, W.W., Aneurysm in the cervical portion of the internal carotid artery. An analytical study of the cases reported in the literature between August 1, 1925 and July 31, 1936. Report of two new cases, *Ann. Surg.*, 105 (1937) 673–678.
- 30 Smith, R.F., Szilagyi, D.E. and Colville, J.M., Surgical treatment of mycotic aneurysm, *Arch. Surg.*, 85 (1962) 663–674.
- 31 Van Rensberg, L.C.J., Aneurysm of the internal carotid artery presenting as a peritonsillar abscess, *S. Afr. med. J.*, 38 (1964) 567–569.
- 32 Wemple, J.B. and Smith, G.W., Extracranial carotid aneurysm, *J. Neurosurg.*, 24 (1966) 667–671.
- 33 Wind, E.S., Wisoff, B.C., Baron, M.G., Balsam, D., Gootman, N. and Harrison, D., Mycotic aneurysm in infancy: a complication of umbilical artery catheterization, *J. pediat. Surg.*, 17 (1982) 321–325.
- 34 Young, N., Bleeding from ear as sign of leaking aneurysm of extracranial portion of internal carotid artery, *J. Laryng.*, 56 (1941) 35–64.