

# JAW EXPANSIVE LESIONS: POPULATION INCIDENCE AND CT DENTASCAN ROLE

V. FIASCHETTI, E. FANUCCI, M. RASCIONI, L. OTTRIA\*,  
A. BARLATTANI\*, G. SIMONETTI

Department of Diagnostic and Molecular Imaging, Interventional Radiology and Radiation Therapy

\*Department of Odontostomatological Sciences

University of Rome "Tor Vergata", Rome, Italy

## SUMMARY

**Jaw expansive lesions: population incidence and CT dentalscan role.**

**Aim.** The aim of the study is to evaluate the incidence of different expansive lesions and the advantages of the clinical employment of Dentalscan to study bones lesions and to establish a common diagnostic path.

**Materials and methods.** Since January 2005 to November 2009, 3200 patients, not selected for sex or age, have undergone a CT "Dentalscan" in the department of Diagnostic Imaging, Tor Vergata University Hospital (PTV), a suspect bone pathology was found in 704 of them through the XR-orthopantomography (OPT). CT images were obtained with General Electric CT Light Speed multislice. Images were saved in the Advantage Workstation (GE) supported by the "Dentalscan" dedicated software and by the 3D software (3D SSD). The protocol was: Slice thickness 1,25 mm, gap 0, matrix 512 x 512, 140 KV and 70 mA.

All the lesions were also studied with the dedicated three-dimensional reconstructor 3D SSD. Biopsy for diagnosis was performed on all the lesions, except one (false positive with digital OPT).

The technique sensitivity was assessed for two important classes: benign and malignant lesions.

**Results.** Through CT Dentalscan a detailed evaluation of the jaws lesions and their extension was obtained.

656 patients (93.1 %) out of 704 examined for a suspicious lesion on the orthopantomography had a benign lesion: (127 follicular cysts (18.2 %), 181 radicular cysts (25.1%), 93 non odontogenic cysts (13.2%), 29 fibroma (4.2%), 198 odontomes (28.2%), 24 ameloblastoma (3.6%), 4 brown tumors (0.7%), 47 (6.9%) had malignant lesions: (12 carcinoma (1.7%), 29 metastasis (4.3%), 6 sarcoma (0.8%), 1 Dentalscan CT resulted to be negative (1 false positive of digital OPT).

The sensitivity of the technique for both groups was 99% for benign lesions and 98% for malign lesions.

**Conclusions.** CT Dentalscan characteristics suggest to consider these techniques as the gold standard for the evaluation of jaw expansive lesions and the support of surgical planning.

**Key words:** dentalscan, expansive lesions.

## RIASSUNTO

**Lesioni espansive del mascellari: incidenza nella popolazione e ruolo della TC dentalscan.**

**Scopo del lavoro.** Scopo del lavoro è valutare l'incidenza delle varie lesioni espansive e i possibili vantaggi nell'impiego clinico del Dentalscan nella valutazione delle lesioni ossee anche nell'ottica di una standardizzazione dell'iter diagnostico.

**Materiali e metodi.** Nel periodo compreso tra gennaio 2005 e novembre 2009, presso il Dipartimento di Diagnostica per immagini del Policlinico Universitario di Tor Vergata (PTV), sono stati sottoposti a studio con TC "Dentalscan" 3200 pazienti, non selezionati per sesso e per età, di cui 704 con patologia ossea sospetta all'indagine radiografica tradizionale eseguita con ortopantomografia (OPT). Gli esami TC sono stati ottenuti con apparecchio General Electric CT Light Speed multislice e sono stati successivamente trasferiti alla stazione di lavoro "Advantage windows" (GE) supportata dal software di ricostruzione dedicato "Dentalscan" oltre che dal software di ricostruzione tridimensionale (3D SSD). È stato impiegato un protocollo con spessore di strato di 1,25 mm, gap 0, matrice 512 x 512, 140 KV e 70 mA.

Tutte le lesioni ossee sono state studiate anche con ricostruzione tridimensionale 3D SSD. In tutti i casi tranne uno (falso positivo all'OPT digitale) si è reso necessario l'esame biptico per una diagnosi di certezza.

È stata inoltre valutata la sensibilità della tecnica per due grandi gruppi: lesione benigna e lesione maligna.

**Risultati.** La TC Dentalscan ha consentito in tutti i casi uno studio dettagliato delle lesioni riscontrate a livello dell'osso mascellare e della mandibola e la loro estensione. Di 704 (22%) pazienti esaminati con lesione ossea sospetta all'ortopantomografia, 656 (93.1%) avevano alterazioni di tipo benigno, di cui 127 cisti follicolari (18.2%), 181 cisti radicolari (25.1%), 93 cisti non odontogene (13.2%), 29 fibromi (4.2%), 198 odontomi (28.2%), 24 ameloblastomi (3.6%), 4 tumori bruni (0.7%), 47 (6.9%) alterazioni maligne: (12 carcinomi (1.7%), 29 metastasi (4.3%), 6 sarcomi (0.8%), in 1 paziente la TC Dentalscan è risultata negativa (1 falso positivo all'OPT digitale).

La sensibilità della tecnica per due grandi gruppi è stata del 99% per le lesioni benigne e del 98% per le lesioni maligne.

**Conclusione.** Le caratteristiche intrinseche della tecnica la propongono come tecnica di scelta nella valutazione dei processi espansivi dei mascellari facendo da supporto anche alla pianificazione chirurgica.

**Parole chiave:** dentalscan, processi espansivi.

## Introduction

In the past only conventional XR were used to detect lesions involving the jaws (1).

Jaw anatomy makes the study with conventional XR difficult because of the overlapping of bones structures.

Spiral Computed Tomography with the dedicated software "Dentascan" changed the diagnostic approach in this branch (1,16).

The Dentascan is a dedicated reconstruction software for the dental diagnostic that allows a multiplanar vision of the jaws (3,5).

The software allows panoramic reconstruction from the CT axial view and vertical-seriate orthogonal or paraxial (tomograms), giving detailed images of the alveolar and dental bone and of the anatomy of the jaws (4).

Dentascan was introduced in the middle eighties and employed basically for dental implantology. Now it is considered the gold standard and its use is routine (4).

Used also in other fields, such as the evaluation of expansive lesions, Dentascan is currently under development in order to define a correct diagnostic iter (1,5).

Expansive lesions of maxillary bone involve different tissues. The first important division is between benign and malign pathology, the second division is between lesions of odontogenic tissue and periskeletal soft tissues. One more division is based on lesions with own characteristics, cystic or solid. It's necessary as well to consider metastatic lesions that are not frequent but could involve the jaws.

CT images often allow the differentiation of benign lesions and cysts from malignant lesions; otherwise biopsy is usually necessary to establish the final diagnosis (1,5).

The purpose of our study is to evaluate the incidence of different expansive lesions and the advantages of Dentascan clinic usage so as to study bone lesions and reach the standardization of the diagnostic iter.

## Materials and methods

Since January 2005 to November 2009, 3200 patients, not selected for sex or age, have undergone a CT "Dentascan" in the department of Diagnostic Imaging, Tor Vergata University Hospital (PTV). A suspect bone pathology was found in 704 of them through the XR-orthopantomography (OPT). The remaining 2496 patients were examined for implantology or implant control, and for the study of dental inclusions.

CT images were obtained with General Electric CT Light Speed multislice. Images were saved in Advantage Workstation (GE) supported by the "Dentascan" dedicated software and by the 3D software (3D SSD). Patients were positioned with the hard palate for the superior arch and with the body of mandibular bone for the inferior arch perpendicular to the top of the patient board.

The arches were spaced with lints to allow immobility and grip among the teeth.

The head was immobilized in ad hoc support with a Velcro tape fixed under the chin and two rubber pillows were located on both sides of the neck.

The patient was invited not to move the head, not to swallow and not to open the mouth during the exam. On the lateral reference scanogram a packet of volumetric acquisition was situated parallel to the arch under examination, and in particular parallel to the inferior limit of the lower jaw, for the inferior arch, and parallel to the hard palate for the superior arch, in order to involve the whole height of the arch.

The protocol was : Slice thickness 1,25 mm, gap 0, matrix 512 x 512, 140 KV and 70 mA.

Data were processed and reconstructed with Dentascan dedicated software on the longitudinal axis of the arches and gap 1 mm ("panorex" reconstruction) and along oblique planes orthogonal to the longitudinal axis of the arches (oblique reconstructions or toradial- tomograms) gap 1 mm.

All of the bone lesions were also examined with the dedicated three-dimensional reconstructor 3D SSD. Biopsy for diagnosis was performed on all lesions, except one (false positive with digital OPT).

The technique sensitivity for two important classes, benign and malignant lesions was evaluated.

## Images analysis

In our study the incidence of different expansive lesions, odontogenic, and non odontogenic, benign and malignant was assessed. We evaluated some elements to determine the extension of the lesion and bad prognostic signs:

- Tridimensional morphology and characteristics of the lesions;
- Enlargement of cortex;
- Invasion of soft tissues;
- The lesion position in relation to important structures such as mandibular canal, incisive canal and nose-palatal canal;
- The relationship between the mucous membrane of the nose and jawbone sinus;
- The density of the bone in all the arch and in particular near the lesion referring it to the Mish classification and to the study with ROI positioning;
- The best surgical planning or the advantages of a vestibular or oral access;
- The prediction of the prognosis and potential complications.

## Results

All lesions found in the jaws were accurately studied by CT Dentascan and their extension was assessed. 656 patients (93.1%) out of 704 (22%), examined for a suspicious lesion on the ortopantomography, had a benign lesion: 127 follicular cysts (18.2%) (Fig.1), 181 radicular cysts (25.1%), 93 non odontogenic cysts (13.2%), 29 fibroma (4.2%), 198 odontomes (28.2%), 24 ameloblastoma (3.6%) (Fig.2), 4 brown tumors (0.7%), 47 (6.9%) malignant lesions (12 carcinoma (1.7%) (Fig.3), 29 metastasis (4.3%), 6 sarcoma (0.8%), 1 CT Dentascan resulted negative (1 false positive of digital OPT) (Fig. 4, Tab. 1).

In all patients we examined, CT Dentascan enabled a detailed morphological analysis of the lesions, a correct localization of them and the relationship with vital structures, nasal cavity, air sinuses, and with dental elements, all important aspects for a correct surgical planning.

In 98% of cases we could study the mandibular canal and in 46% of patients the incisive canal.

Only in patients with inadequate cortex of the channel due to a low rate of calcium, almost old toothless people, we couldn't evaluate the location either exactly or accurately.

In all patients we defined the surgical planning with millimetric precision and set the best (oral or vestibular) for biopsy and type of surgical approach. In all cases a prediction of the prognosis and of the potential complications was possible.

20 patients (2.8%) had to repeat the exam due to motion artefacts.

3 patients (0.4%), which had a lesion extended over the cortex in the soft tissues, had to be examined also with MR in order to better evaluate the relation with the nearer soft tissues involved for contiguity.

2 benign lesions (brown tumors) were classified as malignant because of the morphostructural alteration of the bone and the important reworking of the cortex.

1 small metastatic lesion, not modifying the cortex, was classified as benign.

The sensitivity of the technique for both groups was 99% for benign lesions, and 98 % for malignant lesions.

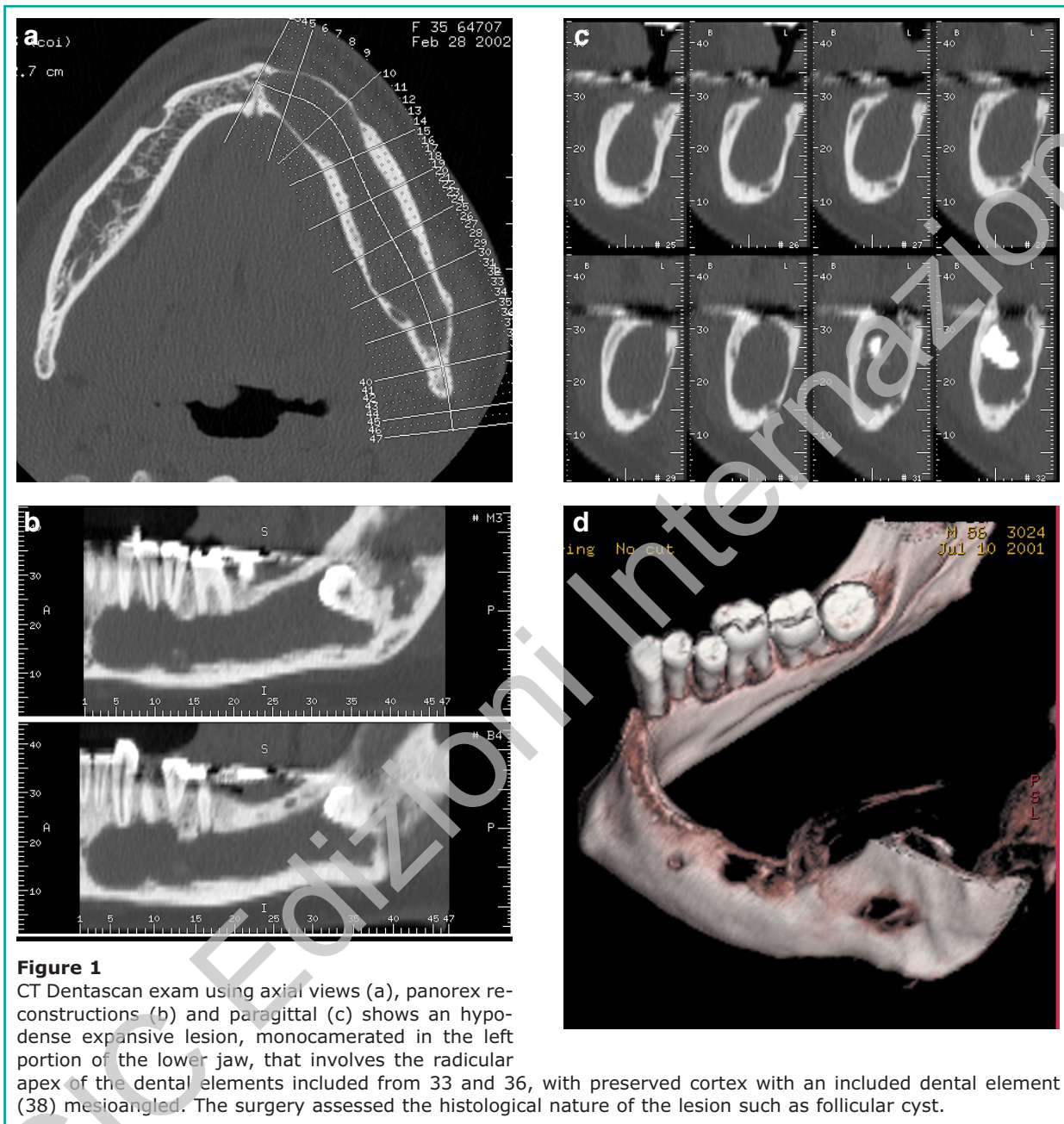
## Discussion

Today Diagnostic imaging is the base for the management of patients in all the odontostomathologic and surgical maxillo-facial activities: diagnosis, stadiation, treatment planning, final assessment and follow-up.

CT Dentascan, developed for the evaluation of dental implants at the beginning, is a daily routine application at present, and an important technique also for the surgical planning of jaws lesions.

According to Literature (1-3,5,15), our experience supports the growing role of CT Dentascan in the evaluation of jaws lesions, in the diagnosis, and in the assessment of local extension of lesions in order to determine the surgical planning, choose the best approach (oral or vestibular), assess the surgical extension, and make a diagnostic prediction.

As indicated by our case study and Literature, 656



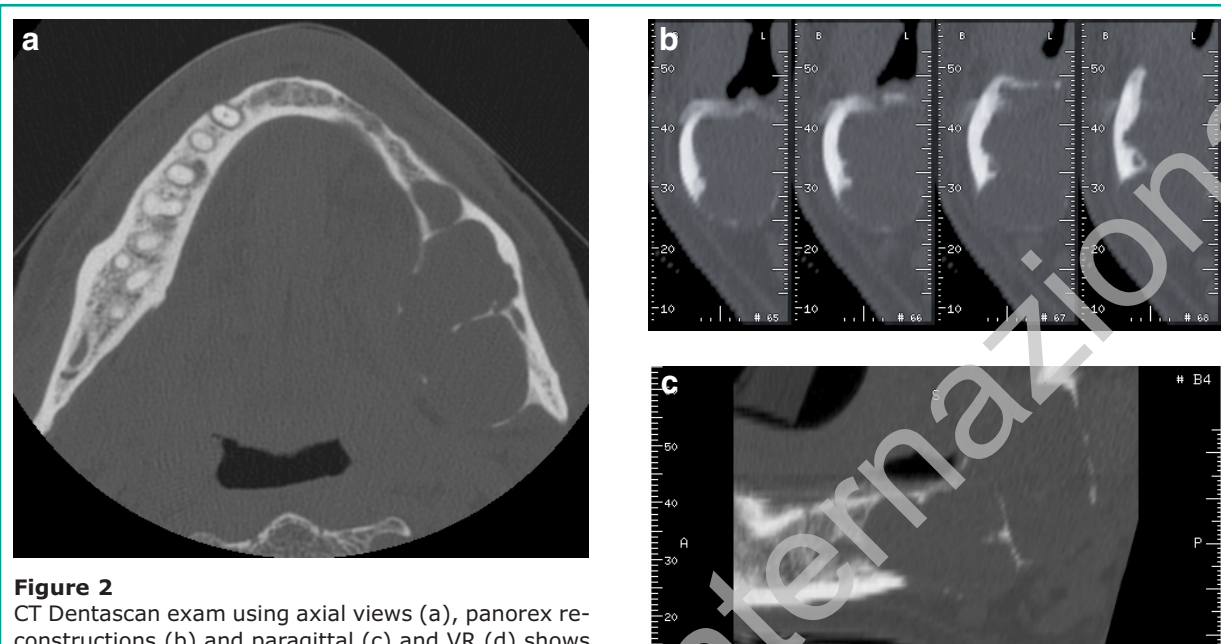
patients (93.1 %) out of 704 (22%), examined for a suspicious lesion on the ortopantomography, had a benign lesion and 47 (6.9%) had malignant lesions, 1 CT Dentascan resulted negative (1 false positive of digital OPT).

In all patients we could define the exact extension of the lesion, the involvement of nearer anatomical structures and study the surgical planning required

to set the right approach (oral or vestibular) for biopsy and surgical planning.

CT Dentascan has several advantages for spatial resolution: it allows an absolutely precise topographic localization of the lesion, based on axial, coronal (panorex) and sagittal or paraxial views. At the same time the relation between the lesion and the surrounding anatomical structures is highlighted. This technique





**Figure 2**

CT Dentascan exam using axial views (a), panorex reconstructions (b) and paragittal (c) and VR (d) shows a hypodense expansive lesion, multicamered in the left portion of the lower jaw that swells the bone thinning and interrupting the cortex on the lingual and marginal limit. It is not evident that the mandibular canal could be included in the lesion. The biopsy identified an ameloblastoma.

exactly shows the mandibular canal, the incisive and the nose-palate one. Then, it is essential for surgical procedures in this site to minimize the risk of iatrogenic injury, which could be high without accurate information (1,5).

CT Dentascan enables a detailed view of nasal cavity and air sinuses affording a millimetric evaluation of the connections with the contiguous lesion. This is an important detail if the lesion is inside the sinus and it is necessary to open the maxillary sinus that is 30-50 mm deep.

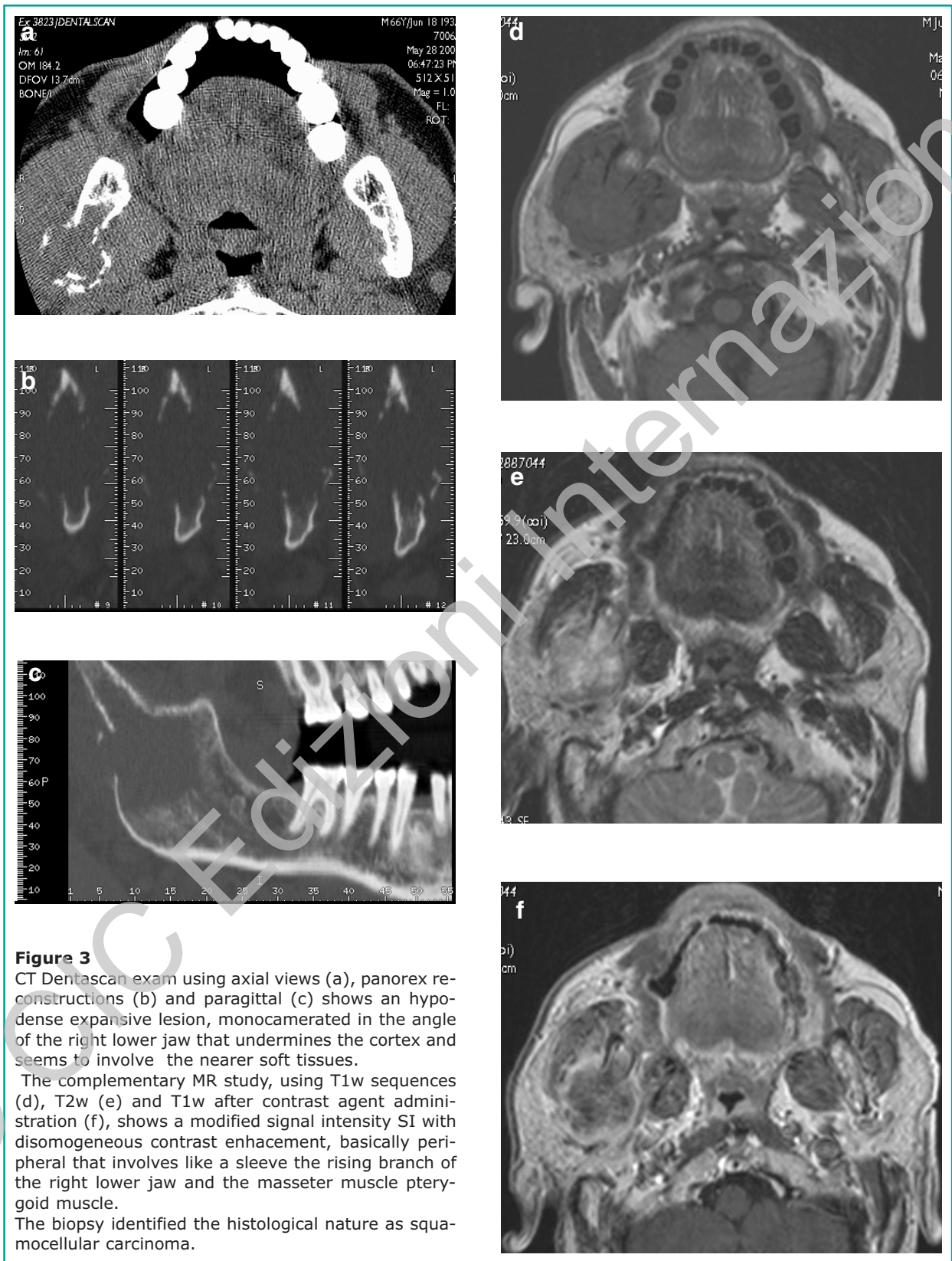
The technique offers such an accurate detail of the skeletal structures that shows the existence of an enlargement of the cortex or the concomitance of osteosclerosis and bone reactive lysis. The measurement of bones thickness is reliable and it is essential to determine the surgical planning and evaluate the mucous membrane of the air sinuses.

Unlike conventional radiography and CT with conic beam, this technique allows to study soft tissues and check the mucous membrane and any possible reactive thickenings.

It also gives the opportunity to exactly set the mea-

sure of the expansive lesion volume through three-dimensional reconstructions (3D SSD) equally significant to determine the surgical planning. Therefore it provides a careful display of the three-dimensional morphology of the maxillary arches through three-dimensional reconstructions (3D SSD) of the facial musculature and their relationship in patients with bad dental occlusions. It seems to be useful for the assessment before and after surgical treatment, and for orthognatic surgery (9).

The limit of this technique the high radiant dose. The study of the dental arches and the bones structures of the jaws through CT multislice with dedicated Dentascan software entails a higher dosimetric impact for the patients, with reported values of dose in Literature (8-11) higher 20-30 times than the conventional orthopantomographyc exam. Cohnen et al. (11) compared the absorbed dose with orthopantomography, single slice spiral CT Dentascan with routine protocol and low dose protocol (reducing mA), and multislice Dentascan CT. Orthopantomography resulted to have the low dose impact (peack dose 0.65 mGy, effective dose 0.01 mSv) followed in increa-

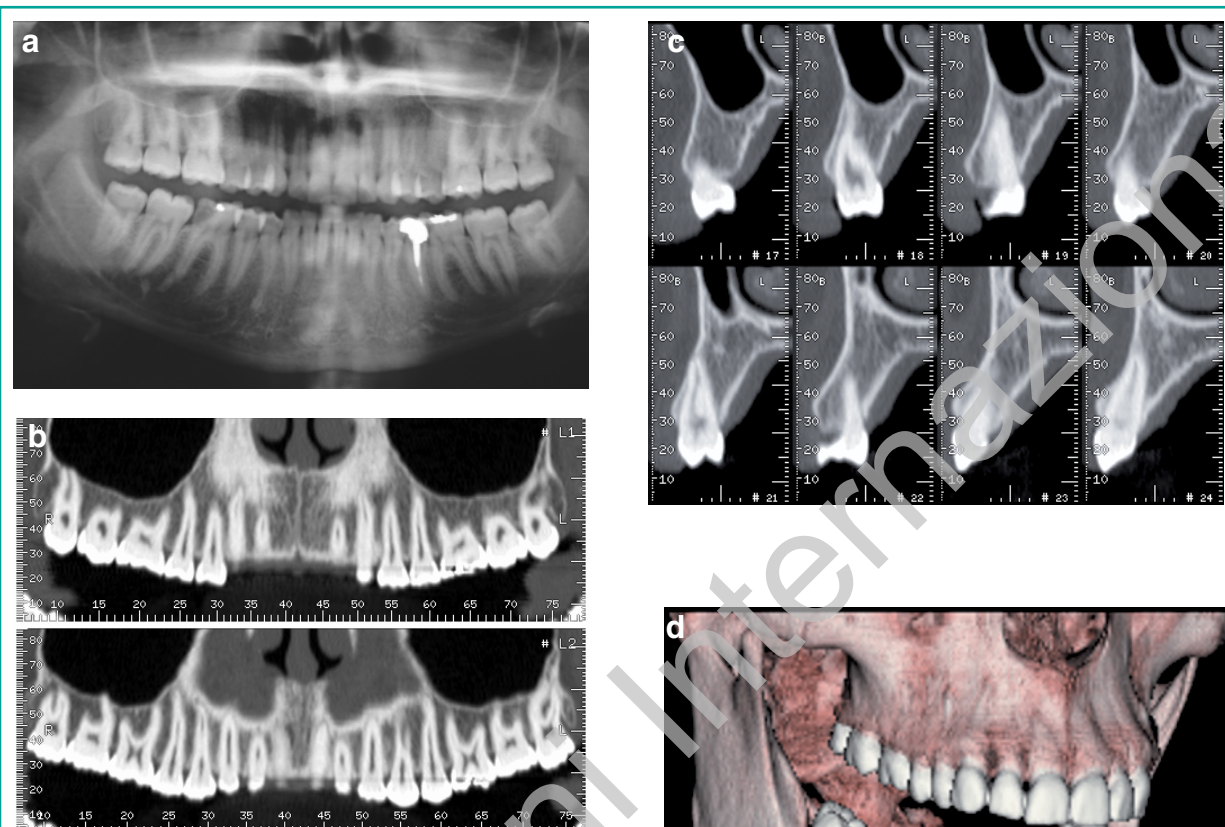


**Figure 3**

CT Dentascan exam using axial views (a), panorex reconstructions (b) and paragittal (c) shows an hypodense expansive lesion, monocamerated in the angle of the right lower jaw that undermines the cortex and seems to involve the nearer soft tissues.

The complementary MR study, using T1w sequences (d), T2w (e) and T1w after contrast agent administration (f), shows a modified signal intensity SI with disomogeneous contrast enhancement, basically peripheral that involves like a sleeve the rising branch of the right lower jaw and the masseter muscle pterygoid muscle.

The biopsy identified the histological nature as squamocellular carcinoma.



**Figure 4**

Digital OPT exam that shows radiotransparent area periapex of 11-14. CT Dentascan exam using panorex reconstructions (b) and paraxittal (c) shows regular bone structure in this site with regular trabecular network. VR reconstructions (d) support a bone without distortion.

**Table 1** - Patients with suspicious lesion on the orthopantomography studied by CT Dentascan: our series.

703 patients*	Lesions N	Lesions %
Follicular cysts	127	18.2
Radicular cysts	181	25.1
No odontogenic cysts	93	13.2
Fibroma	29	4.2
Odontomes	198	28.2
Ameloblastoma	24	3.6
Brown tumors	4	0.7
Carcinoma	12	1.7
Metastasis	29	4.3
Sarcoma	6	0.8
<b>TOTAL</b>	<b>703</b>	<b>100</b>

\*1 CT Dentascan resulted negative (1 false positive of digital OPT)

single order by spiral single slice CT with low dose (peak dose 6.1-10.9 mGy, effective dose 0.15-0.36 mSv), spiral single slice CT with standard protocol and the multislice CT that presented a similar absorbed dose (peak dose 23 mGy, effective dose 0.61-0.74 mSv). Some studies that used multislice spiral CT (6,12) showed that a remarkable decrease in the dose resulted from the use of protocols with 80 KV.

In Literature (8,11,12) it is evident how the parotid glands, the cerebellum and the thyroid absorb the highest dose during orthopantomography, while during Dentascan CT there is the jaw in addition to those organs.

The gonads are not involved even without the apron, according to some works (9,13) they absorb a similar dose to that of the background.

The credibility of the CB CT (cone beam) to study



jaws is growing, it allows the fast acquisition of information on a volume with administration of a low dose (7,9,11,13,14).

The lower dose absorbed with this new technique, cone beam, is partially explicable with a higher rumor in the imagine, that although it limits the resolution, it doesn't limit the contrast resolution as well as the anatomical details of the bone, important for particular applications. The dose can be also reduced by 50% (7,13,14,18).

An hypothetical of a Dental MR could allow a three-dimensional radiological study of dental arches without exposing the patient to X-ray (15).

This technique doesn't ever let to an easy identification of vital structures, such as vascular and nervous beams, and doesn't show the thickness and the density of the cortex and of the network of the bone trabecula. Even allowing the morphological evaluation of the jaws and the existence of focal lesions, the diagnostic accuracy of this technique is much lower than that of Dentscan CT used for these anatomical structures.

The MR limit is linked to its own features. Thanks to its high performance in the tissue characterization it is the gold standard for the study of soft structures and it is essential as a complementary diagnostic tool for Dentscan CT in the evaluation of focal lesions of the jaws and in a correct assessment of the extension of the lesion.

Only 3 patients (0.4%) in our study needed a MR study to exactly evaluate the soft tissues involvement where the lesion was extended over the bone cortex near the closer soft structures.

Moreover there are some limits: the existence of magnetic materials that could produce distortion artefacts and the need for the absolute immobility of the patient in order to have satisfactory diagnostic images.



## Conclusions

Dentscan CT allows a detailed morphological analysis of the expansive lesions of the jaws, an exact localization, an exact definition of the relation with vital structures, nasal cavity, with the sinuses and dental elements, which are all important aspects for a

correct surgical planning.

The accuracy of the detail of the skeletal structures enables the evaluation of the expansion of the cortex and of the presence of osteosclerosis and bone reactive lysis. The measurement of the bone thickness is reliable and necessary for the surgical planning and the evaluation of the mucous membrane of the sinuses.

The intrinsic characteristics of this technique suggest this is the gold standard for the study of expansive lesions of the jaws and a support for surgical planning.



## References

1. Abrahams JJ. Dental CT Imaging: a look at the jaw. *Radiology* 219: 334-345, 2001.
2. Abrahams JJ, Berger S: Inflammatory disease of the jaw: appearance on reformatted CT images. *AJR Am J Roentgenol* 1998;170:1085-1091.
3. Abrahams JJ, Frisoli JK, Dembner J. Anatomy of the jaw, dentition, and related region. *Semin Ultrasound CT MR* 1995;16: 453-467.
4. Abrahams JJ: The role of diagnostic imaging in dental implantology. *Radiol Clin North Am* 1993;31: 163-180.
5. Au-yeung K.M., Ahuja A.T., Ching A.S.C., Metreweli C.: DentaScan in Oral Imaging. *Clinical Radiology* 2001;56: 700-713.
6. Ballanti F, Lione R, Fiaschetti V, Fanucci E, Cozza P. Low-dose CT protocol for orthodontic diagnosis. *European Journal of Paediatric Dentistry* 2008; vol. 9(2).
7. Bangbose BO, Adeyemo WL, Ladeinde AL, Ogunlewe MO. Cone Beam computed tomography (CBCT): the new vista in oral and maxillofacial imaging. *Nig Q J Hosp Med.* 2008 Jan-Mar;18(1):32-5.
8. Bianchi J, Goggins W, Rudolph M :In vivo, thyroid and lens surface dose with spiral and conventional computed tomography in dental implant radiography. *Oral Surg Oral Med Oral Pathol Oral Radiol Endod* 2000;90: 249-253.
9. Bianchi SD, Rocuzzo M., Albrito F e Coll: Dosi assorbite nella radiologia dentale. *Radiologia Medica* 1996;92: 114-121.
10. Cavalcanti MPG, Vannier MW: Measurement of the volume of oral tumors by three-dimensional spiral computed tomography. *Dentomaxillofacial Radiology* 2000;29: 35-40.
11. Cohnen M, Kemper J, Mobes O, Pawelzik J, Modder U. Radiation dose in dental radiology. *European Radiology* 2002;12: 634-637.
12. Fanucci E, Leporace M, Di Costanzo G, Fiaschetti V, Simonetti G.: Multidetector CT and dentscan softwa-



- re: dosimetric evaluation and technique improvement. Radiol Med. 2006 Feb;111(1):130-8.
13. Hashimoto K, Kawashima S, Araki M, Iwai K, Sawada K, Akiyama Y. Comparison of image performance between cone-beam computed tomography for dental use and four-row multidetector helical CT. J Oral Sci. 2006 Mar;48(1):27-34.
  14. Kau CH, Boži M, English J, Lee R, Bussa H, Ellis RK. Cone-beam computed tomography of the maxillofacial region-an update. Int J Med Robot. 2009 Sep 23.
  15. Nasel, Pretterklieber M, Gahleitner A, Czerny C, Breitenseher M, Imhof H: Osteometry of the mandible performed using dental MR Imaging. American Journal of Neuroradiology 20(7): 1221-1227, 1999.
  16. Preda L, Rodriguez Y, Baena R et al. La Tomografia Computerizzata nell'implantologia: aspetti tecnici e metodologici. La Radiologia Medica 1999;98: 447-453.
  17. Roithmann R, Kassell EE, Kirsch JC, Wortzman G, Abrahams JJ, Noyek AM: New radiographic techniques for detection of mandibular invasion by cancer. Oper Tech Otolaryngol Head Neck Surg 1993;2: 149-154.
  18. Scarfe WC, Farman AG. Wath is cone-beam and how does it work? Dent Clin North Am. 2008 Oct;52(4):707-30.

---

*Correspondence to:*

Dott.ssa Valeria Fiaschetti  
Department of Diagnostic and Molecular Imaging,  
Interventional Radiology and Radiation Therapy  
University of Rome "Tor Vergata",  
Viale Oxford 81, 00133 Rome, Italy  
Tel.: +0390620902400  
Fax: +390620902404