

Transcatheter mitral valve implantation in severe mitral annular calcification: a case report

Giulio Russo ^{1*}, Valerio Maffi¹, Gianluca Massaro ¹, Gaetano Chiricolo¹, Giuseppe Massimo Sangiorgi¹, Aris Moschovitis², and Maurizio Taramasso ²

¹Department of Biomedicine and Prevention, Cardiology Unit, Policlinico Tor Vergata, University of Rome, 00100 Rome, Italy; and ²HerzZentrum Hirslanden, 8032 Zurich, Switzerland

Received 18 June 2024; revised 16 October 2024; accepted 13 December 2024; online publish-ahead-of-print 31 December 2024

Background

Mitral annular calcification (MAC) is characterized by severe calcification of mitral annulus and might be associated with both mitral regurgitation and stenosis. It is technically challenging for both surgical and percutaneous approach and is burdened by high mortality.

Case summary

The present case report describes a complex case of mitral steno-insufficiency (baseline transvalvular gradient = 5 mmHg, effective regurgitant orifice area 0.45 cm², vena contracta 0.8 cm), due to MAC in an 83-year-old lady. In consideration of the clinical context (MAC) and patient's several comorbidities and history of previous surgical interventions, she was deemed not suitable for surgery and a percutaneous treatment was selected (valve-in-MAC). Due to significant paravalvular leak, further implantation of a plug was required.

Conclusion

The MAC represents a clinical and technical challenge for surgery. Transcatheter mitral valve implantation in MAC is a feasible alternative although it is technically challenging and burdened by high mortality. Detailed procedural planning is of utmost importance to achieve successful outcomes.

Keywords

Transcatheter mitral valve implantation • Mitral annular calcification • Valve-in-MAC • Mitral regurgitation • Mitral stenosis • Case report

ESC curriculum

4.3 Mitral regurgitation • 4.4 Mitral stenosis

Learning points

- Mitral annular calcification (MAC) may be associated to both stenosis and regurgitation and represents a clinical and technical challenge for both surgical and percutaneous interventions.
- Transcatheter approach (valve-in-MAC) is technically feasible but requires careful planning.
- Left ventricle outflow tract obstruction, paravalvular leak, and prosthesis migration represent major concerns for valve-in-MAC.

Introduction

Mitral annular calcification (MAC) is a degenerative condition characterized by progressive calcium deposition along the mitral annulus and represents a distinct entity from rheumatic mitral disease. It may cause both mitral valve stenosis (more frequently) and regurgitation.

Its frequency may vary according to age, reaching up to 40% in elderly. Moreover, it may be found in almost half of the patient undergoing transcatheter aortic valve implantation.

In general, it is burdened by high mortality due to high-risk profile and several technical challenges. For these reasons, often patients affected by MAC are deemed unsuitable for surgery. Transcatheter mitral valve

* Corresponding author. Tel: +390620901, Email: giuliorusso.md@gmail.com, Twitter: @giuliorusso

Handling Editor: Andreas Metzner

Peer-reviewers: Aiste Monika Jakstaite; Shingo Kuwata

Compliance Editor: Sibghat Tul Llah

© The Author(s) 2024. Published by Oxford University Press on behalf of the European Society of Cardiology.

This is an Open Access article distributed under the terms of the Creative Commons Attribution License (<https://creativecommons.org/licenses/by/4.0/>), which permits unrestricted reuse, distribution, and reproduction in any medium, provided the original work is properly cited.

implantation (TMVI) in MAC (valve-in-MAC) has emerged an alternative option over the last years. We present a case of severe mitral regurgitation (MR) due to MAC treated by percutaneous implantation of mitral prosthesis.

Summary figure

2010	Chronic coronary syndrome treated with four coronary artery bypass
2019	Moderate MR combined with moderate aortic stenosis
2023	Worsening dyspnoea with severe MR at echocardiography
2024	TMVI in MAC

Case presentation

An 83-year-old lady was referred to our centre because of worsening dyspnoea (New York Heart Association, NYHA III–IV). The patient had all cardiovascular risk factors (hypertension, diabetes, smoking, dyslipidaemia, and positive familiar history for cardiovascular disease) and persistent atrial fibrillation under anticoagulation with vitamin K antagonists and had previously undergone three coronary artery bypass graft (CABG). At physical examination, a systo-diastolic murmur was present at the apex. The echocardiogram showed good left ventricular function (left ventricular ejection fraction, LVEF = 60%) with mild-to-moderate aortic stenosis, severe mitral steno-insufficiency (transvalvular mean gradient = 5 mmHg, effective regurgitant orifice area 0.45 cm², vena contracta 0.8 cm) with severe MAC, and severe tricuspid regurgitation (Figure 1).¹ No CABG disease was reported at

angiography. The clinical was discussed at local heart team and deemed high risk for surgery (STS score > 8, EuroScore II 29.47%) and unsuitable for transcatheter mitral edge-to-edge repair.^{2,3} Consequently, the patient was screened for transvenous–transseptal percutaneous valve-in-MAC with computed tomography (CT) scan and deemed suitable for the procedure (Figure 2): in particular, calcium burden and distribution were assessed with a total MAC score of 9 points together with neo-LVOT simulation.⁴ After screening failure for Tendyne prosthesis (Abbott, USA), Sapien 3 Ultra was selected (Edwards Lifesciences, USA). After transseptal puncture in the posterior–inferior quadrant of the fossa ovalis, the patient underwent successful TMVI with Sapien 3 Ultra 29 mm (Edwards Lifesciences, USA)^{5,6} (Figure 3). In addition, due to significant residual paravalvular leak (PVL), a plug (Amplatzer Valvular Plug III, AVP III, Abbott, USA) was implanted (Figures 4 and 5). The first attempt was unsuccessful and the AVP III embolized requiring recapture with the snare (Figure 6). It was finally successfully implanted at second attempt (Figure 7). Post-procedural echocardiogram showed no residual MR (transvalvular gradient 1 mmHg) and good LVEF (see Supplementary material online, Video S1).

The patient was discharged 7 days after the procedure in good clinical status, and at 30-day follow-up, the patient was alive.

Discussion

Currently, MAC represents the most complex subtype of mitral valve disease and is burdened by high mortality for both surgery and transcatheter therapies due to high-risk profile of patients and to technical anatomic challenges.⁷ It may be associated to both mitral stenosis and MR: in the first case, reduced annular dilatation during diastole and restriction of the anterior mitral leaflet motion may represent the main mechanism responsible for the stenosis, while in the second case, the combination of several factors leads to MR (e.g. the failure of the calcified annulus to contract at the end of diastole and calcium

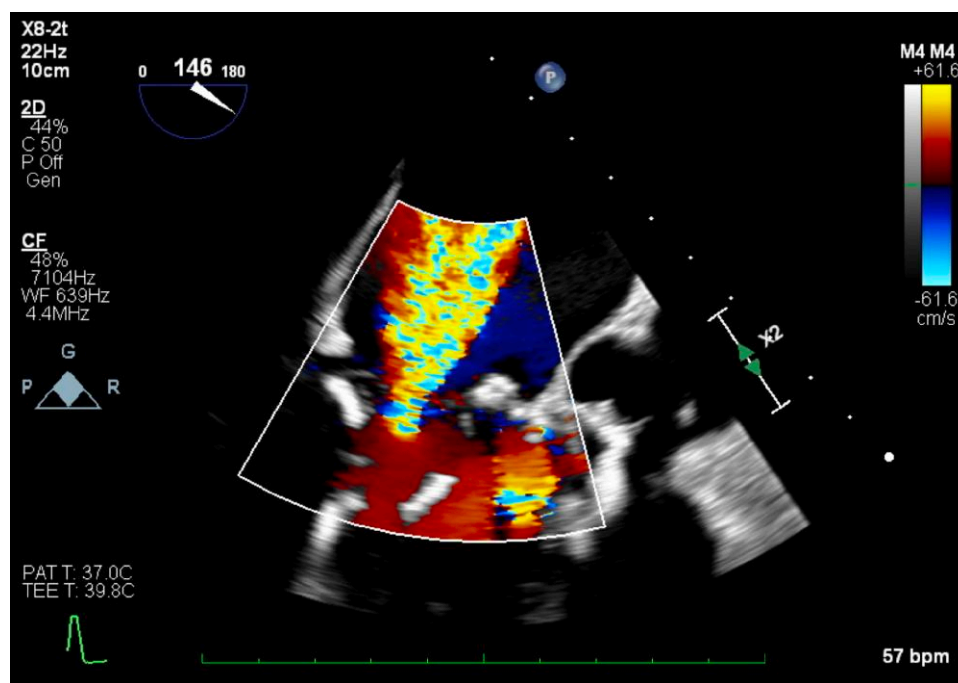


Figure 1 Mitral regurgitation at baseline as assessed by transesophageal echocardiogram.

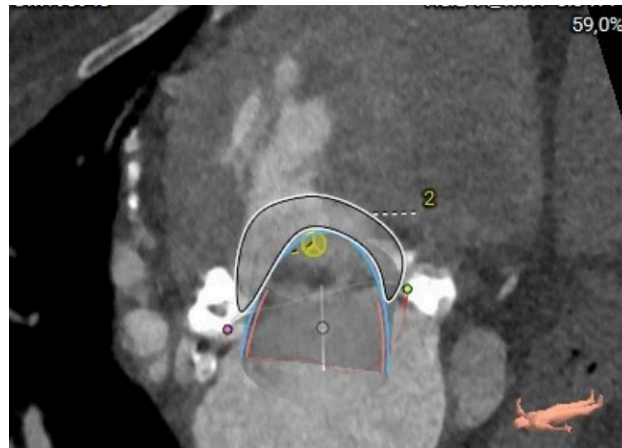


Figure 2 Procedural planning with computed tomography scan and assessment of neo-left ventricle outflow tract of 329 mm² (indicated by the area with number 2).

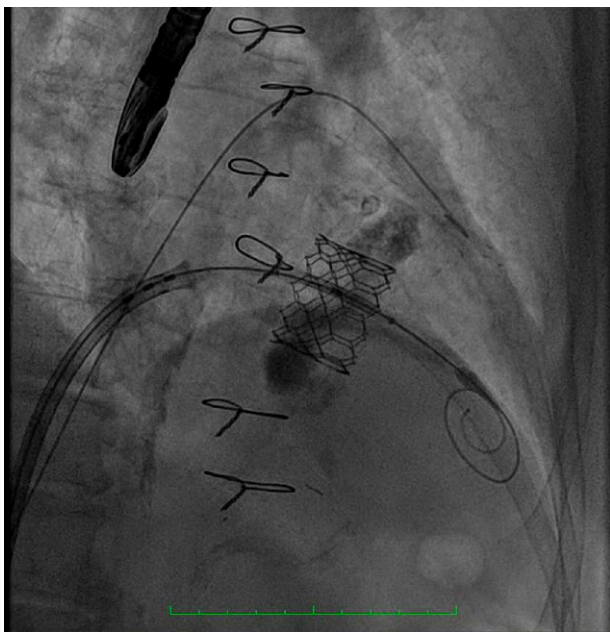


Figure 3 Implantation of prostheses in mitral position.

infiltration of the base of the leaflets reducing their mobility, increasing traction on the chordae, and elevating the leaflets).

While European guidelines indicate surgery as the first option therapy for most cases of mitral valve disease, MAC is often deemed unsuitable for surgery due to its intrinsic high operative risk.⁸ Consequently, the recent development of percutaneous technologies gradually leads to consider transcatheter therapies as a possible alternative for MAC.⁹ So far, results have been contrasting demonstrating the technical feasibility in some selected cases but confirming high mortality also for percutaneous approach. Indeed, according to a recent registry,

30-day and 1-year mortality may reach 35% and 63%, respectively.^{6,10} Such outcomes may be explained by several issues:

- Left ventricular outflow tract obstruction (LVOTO): It is due to the implanted prosthesis pushing the anterior mitral leaflet towards the septum. It represents the most important concern for TMVI as it may occur in up to 40% in valve-in-MAC predicting high 1-year mortality rate, and at the same time, it is the most frequent cause of screening failure. Several percutaneous techniques have been investigated over the last years in order to reduce the risk of LVOTO including intentional anterior mitral leaflet laceration, alcohol septal ablation, and, for patients with previous edge-to-edge intervention, the so-called ElastaClip.¹¹
- Prostheses fixation: MV anatomy is characterized by asymmetrical shape of the annulus and leaflets, large annular dimensions, absence of calcifications in most cases, and a complex subvalvular anatomy. Due to the complex anatomy, sealing and reliable fixation represent another important concern of TMVI. Radial forces as the only mechanism providing fixation might be not enough and might increase the risk of compression and damage to adjacent structures such as the LVOT, the conduction system, the coronary sinus, the left circumflex artery, and the aortic root. Moreover, the dynamic, D-shaped of native MV may affect both fixation and sealing contributing to prostheses embolization and to PVL.
- Durability and thrombogenicity: Currently, no data exist about the long-term durability of transcatheter prostheses in mitral position. According to surgical experience with bioprosthesis, the degeneration process begins 5 years after MV intervention and the freedom from structural valve deterioration varies from 70% to 90% at 10 years. Multiple factors influence the thrombogenicity and degeneration risk. Most of them are valve-related factors and include device profile, shape, and leaflet/stent material. Based on the experience gained so far, although no univocal approach in terms of drugs choice and duration of therapy has been established, it is highly advisable to use at least one antiplatelet/anticoagulant drug, with anticoagulant being preferred over antiplatelet.

The case presented shows all the complexities of patients affected by MAC. In particular, the patient was excluded from surgery because of age, prior cardiac surgery, and multiple comorbidities

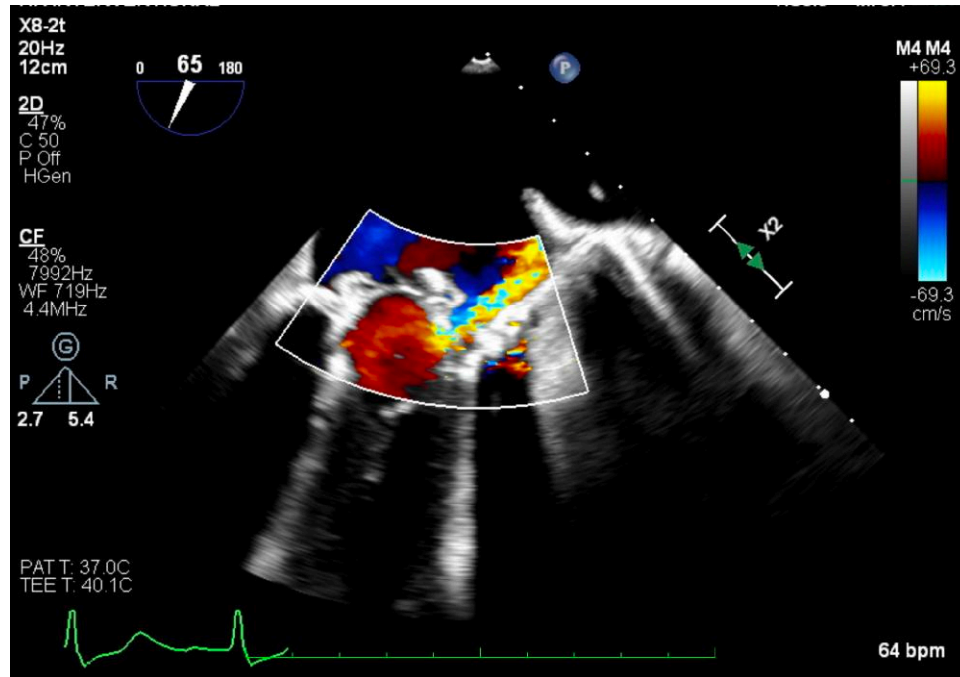


Figure 4 Residual paravalvular leak in 2D echocardiogram.

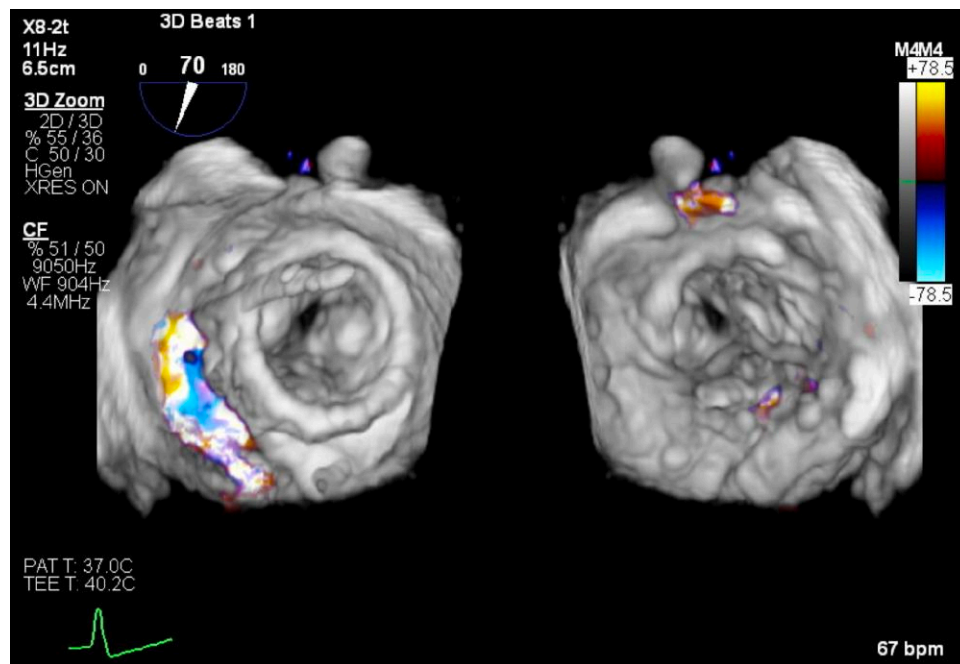


Figure 5 Residual paravalvular leak in 3D echocardiogram.

with high/prohibitive risk according to both STS score and EuroScore II. The patient was therefore selected for percutaneous valve-in-MAC after adequate screening with CT scan. According to calcium distribution and valve anatomy, the risk of PVL and

consequent need for a plug implantation was considered already before the procedure. Indeed, despite successful prosthesis implantation, as a consequence of high calcific annulus, the patient required PVL closure.

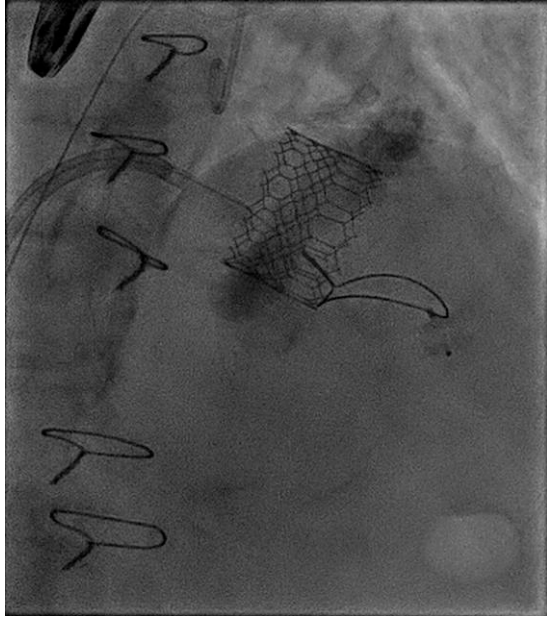


Figure 6 Plug snaring.

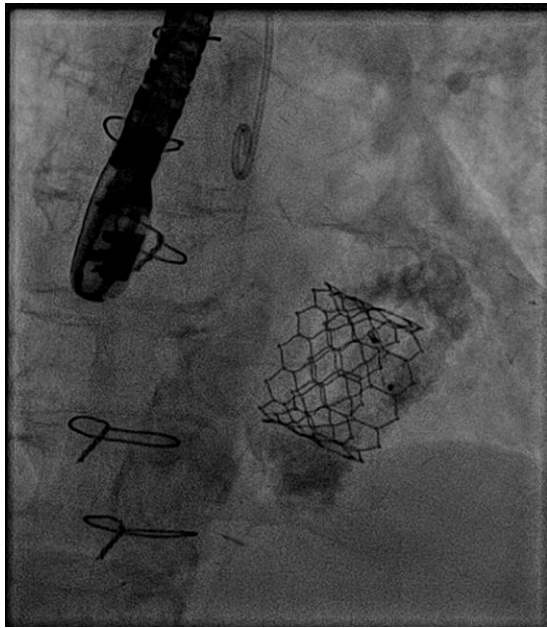


Figure 7 Plug implantation.

Conclusions

Transcatheter mitral valve-in-MAC represents a feasible procedure although it remains a highly challenging scenario. Heart team and appropriate procedural planning play a key role to achieve optimal outcomes.

Lead author biography



Giulio Russo is an interventional cardiologist at Policlinico Tor Vergata University Hospital in Rome with specific interest in complex coronary interventions and structural heart disease interventions.

Supplementary material

Supplementary material is available at *European Heart Journal – Case Reports* online.

Consent: The patient gave consent to undergo the procedure and to publish the clinical case. I confirm to have respected the COPE guidelines.

Conflict of interest: G.R. received fellowship training grant from EAPCI, sponsored by Edwards Lifesciences. M.T. reports consultancy fees from Abbott Vascular, Edwards Lifesciences, 4Tech, Boston Scientific, CoreMedic, Mitraltch, and SwissVortex, outside the submitted work. The remaining authors have no conflict of interest to declare.

Funding: None declared.

Data availability

Data are available upon reasonable request.

References

- Cannata F, Sticchi A, Russo G, Stankowski K, Hahn RT, Alessandrini H, et al. Mitral regurgitation evolution after transcatheter tricuspid valve interventions—a sub-analysis of the TriValve registry. *Eur Heart J Cardiovasc Imaging* 2024;jeae227. Online ahead of print
- Gavazzoni M, Taramasso M, Zuber M, Russo G, Pozzoli A, Miura M, et al. Conceiving MitraClip as a tool: percutaneous edge-to-edge repair in complex mitral valve anatomies. *Eur Heart J Cardiovasc Imaging* 2020;21:1059–1067.
- Russo G, d’Aiello A, Pedicino D, Kuwata S, Sangiorgi GM, Taramasso M, et al. Understanding transcatheter edge-to-edge repair “knobology”: advanced catheter steering for different scenarios of transeptal puncture. *Catheter Cardiovasc Interv* 2024;103:1138–1144.
- Guerrero M, Wang DD, Pursnani A, Eleid M, Khalique O, Urena M, et al. A cardiac computed tomography-based score to categorize mitral annular calcification severity and predict valve embolization. *JACC Cardiovasc Imaging* 2020;13:1945–1957.
- Russo G, Taramasso M, Maisano F. Transeptal puncture: procedural guidance, challenging situations and management of complications. *EuroIntervention* 2021;17:720–727.
- Maisano F, Russo G, Tagliari AP, Gavazzoni M, Taramasso M. Left femoral vein access for transcatheter mitral valve interventions in unfavorable interatrial septal anatomy. *Catheter Cardiovasc Interv* 2021;98:E971–E976.
- Yoon SH, Whisenant BK, Bleiziffer S, Delgado V, Dhoble A, Schofer N, et al. Outcomes of transcatheter mitral valve replacement for degenerated bioprostheses, failed annuloplasty rings, and mitral annular calcification. *Eur Heart J* 2019;40:441–451.
- Vahanian A, Beyersdorf F, Praz F, Milojevic M, Baldus S, Bauersachs J, et al. 2021 ESC/EACTS guidelines for the management of valvular heart disease. *Eur Heart J* 2022;43:561–632.
- Russo G, Gennari M, Gavazzoni M, Pedicino D, Pozzoli A, Taramasso M, et al. Transcatheter mitral valve implantation: current status and future perspectives. *Circ Cardiovasc Interv* 2021;14:e010628.
- Guerrero M, Urena M, Himbert D, Wang DD, Eleid M, Kodali S, et al. 1-year outcomes of transcatheter mitral valve replacement in patients with severe mitral annular calcification. *J Am Coll Cardiol* 2018;71:1841–1853.
- Khan JM, Babaliaros VC, Greenbaum AB, Foerst JR, Yazdani S, McCabe JM, et al. Anterior leaflet laceration to prevent ventricular outflow tract obstruction during transcatheter mitral valve replacement. *J Am Coll Cardiol* 2019;73:2521–2534.