

Radiofrequency Heat Ablation and Vertebroplasty in the Treatment of Neoplastic Vertebral Body Fractures

SALVATORE MASALA¹, MARIO ROSELLI², FRANCESCO MASSARI¹, ROBERTO FIORI¹,
ANTONIO URSONE¹, EMANUELA FOSSILE², ANASTASIA LAUDISI² and GIOVANNI SIMONETTI¹

*Departments of ¹Interventional Radiology and ²Medical Oncology,
University of Rome " Tor Vergata ", 81 Oxford Street – 00133, Rome, Italy*

Abstract. *Background: Metastatic cancer is the most common malignant disease of the skeletal system. Traditionally, conventional fractionated external beam radiotherapy has been the treatment of choice. Recently, minimally invasive surgical techniques (MISS) have been added to the therapeutic armamentarium. The purpose of our study was to assess the effectiveness and safety of Radiofrequency Heat Ablation and Vertebroplasty in the treatment of neoplastic Vertebral Compressive Fractures (VCF). The aim of radiofrequency heat ablation is to destroy the tumor tissue before stabilizing the vertebra through the intrasomatic injection of cement. Patients and Methods: We treated patients with unremitting pain over spine, in absence of symptomatic spinal cord or roots compression and refractory to conventional therapeutic options such as radiation therapy, chemotherapy, surgery and use of analgesics. Results: The method demonstrated swift pain relief associated with an evident augmentation in the weight-bearing resistance. Conclusion: The association of Radiofrequency Heat Ablation and Vertebroplasty is an effective, simple and safe treatment of vertebral collapse consequent to metastases.*

Approximately 70% of patients with cancer have evidence of metastatic disease at the time of their deaths (1,2). The spinal column is the most common location among osseous sites for metastatic deposits (3). Spinal involvement may occur in up to 40% of patients with cancer. Spinal cord compression from epidural metastases occurs in 5-10% of cancer patients and in up to 40% of patients with pre-existing non-spinal bone metastases (4-9). Of those with body spinal disease, 10-20% develop symptomatic spinal cord compression (8,10,11). The

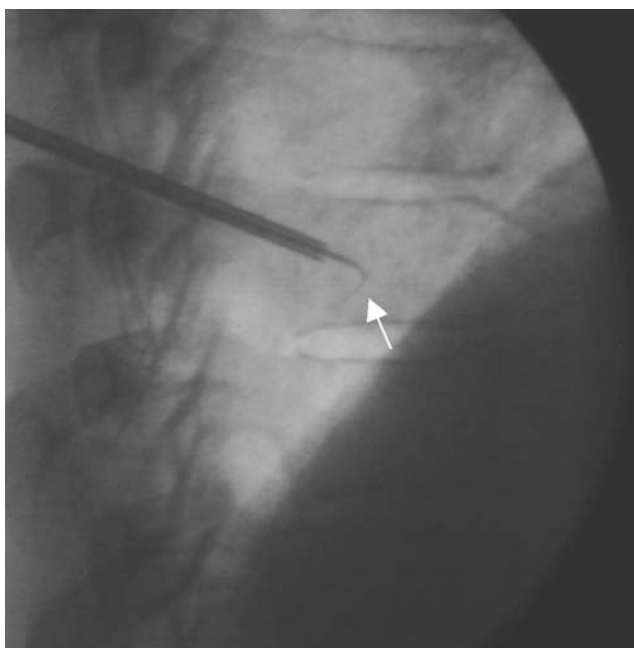
thoracic spine is the most common site of disease (70%), followed by the lumbar spine (20%) and cervical spine (10%) (7,8,12). Metastatic spinal disease can arise from one of three locations: the vertebral column (85%), the paravertebral region (10-15%) and, rarely, the epidural or subarachnoid/intramedullary space itself (<5%) (7,8,12). The posterior half of the vertebral body is usually involved first, with the anterior body, lamina and pedicles invaded later (13). Multiple lesions at non-contiguous levels occur in 10-40% of cases (7,8,12,14). Approximately 50% of metastases arise from one of these primary types of cancer: breast, lung, prostate or melanoma (7). These commonly cause spinal metastases in 74.3%, 44.9%, 90.5% and 54.5% of patients, respectively (4). These are followed by renal cancer, gastrointestinal cancer, thyroid cancer, sarcoma and the lymphoreticular malignancies: lymphoma and multiple myeloma.

Painful bone metastases commonly occur in advanced cancer patients. They are difficult to manage because of pain, reduction in mobility and performance status. Possible mechanisms that may cause pain from bone metastases include: stimulation of nerve endings in the endosteum resulting from the release of chemical agents from the destroyed bone tissue such as prostaglandins, bradykinin, substance P, or histamine; stretching of the periosteum by increasing size of the tumor; fractures; tumor growth into surrounding nerves and tissues. Few of these mechanisms are supported by definitive data. Stimulation of nerve endings in the endosteum by chemical agents released from the destroyed bone tissue is probably the main cause of bone pain from small metastases; as metastases enlarge, stretching of the periosteum additionally contributes to the pain (15).

Vertebral fractures are generated when the combination of the axial and rotational charges on the spine exceed the resistance offered by the vertebral body (16). The Vertebral Compressive Fracture (VCF) is defined as a reduction in height, which must be at least 20% beyond its initial dimensions. In relation to its severity, it is distinguished as mild 20-25%, moderate 25-40%, or severe >40% (17). The presence of a vertebral fracture puts the individual in the

Correspondence to: Salvatore Masala, MD, Department of Diagnostic Radiology, " Tor Vergata " University General Hospital, 81 Oxford Street – 00133, Rome, Italy. Tel: +039-0620902401, Fax: +039-0620902404, e-mail: salva.masala@tiscali.it

Key Words: Metastases, vertebral compression fracture, interventional radiology, radiofrequency heat ablation, vertebroplasty.



Radiofrequency heat ablation and vertebroplasty, fluoroscopic images (Figures 1-2):

Figure 1. Needle electrode tip deployed (white arrow) into the central part of the lesion, generates a well-defined area of tumor necrosis.

following years at a 5 times greater risk of having a second VCF, which in almost 20% of the cases occurs within a one-year period (18-20).

Complications of VCF include, in more than a third of these patients, chronic pain, lower quality of lifestyle, progressive kyphosis of the spine and reduction of volumes of the thoracic and abdominal cavities. In consequence to this it generates pulmonary compression, with a reduction of vital capacity (VC) to 9% for each level fractured and of "forced expiratory volume to 1 second" (FEV1), as well as gastrointestinal dysfunction. (18,21-24).

Patients and Methods

Indications. Vertebroplasty is a technique increasingly utilized in the field of VCF, based on primary and secondary neoplasm. It is extremely useful in the treatment of aggressive vertebral hemangiomas, bone osteolytic metastases and destructive multiple myeloma, which is associated with VCF in 55-70% of the cases (25).

Contraindications. The contraindications of the combined procedure consist of osteoblastic tumors, fractures with retropulsion of the fragments within neural foramen, spread of tumor within the epidural space, local infection (osteomyelitis, discitis or epidural abscess), coagulative disorders, pain not related to vertebral collapse, steady asymptomatic fractures, and tumor involvement or missing integrity of pedicles or joint facets (26-29).

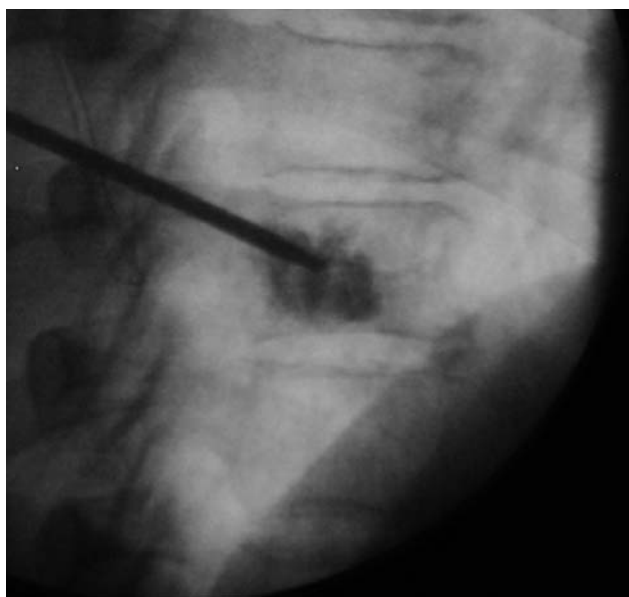


Figure 2. PMMA is injected through the needle into the vertebral body to stabilize the osteolytic lesion.

Technique. All the patients were subjected to a thorough clinical examination in order to determine the symptomatic vertebral level, which is revealed by acute pain and tenderness over the spine at or near the level of radiographic compression deformity (30).

Radiographic examinations and CT were preliminarily performed to evaluate the location, severity and the extension of the collapsed vertebra, as well as to ascertain the visibility of the vertebral pedicles and the integrity of the posterior wall. Magnetic resonance is fundamental in the pre-treatment diagnosis and in the follow-up to evaluate the success of the procedure. The presence of intraspongious edema, particularly in fat suppression sequences, testifies to a recent fracture.

The study was performed under the appropriate institutional ethics approvals and in accordance with the principles embodied in the Declaration of Helsinki. Written informed consent was obtained from each participating subject.

The whole procedure of Radiofrequency (RF) Heat Ablation and Vertebroplasty is performed under CT-fluoroscopy guidance and after administration of local anaesthesia. The patient is placed in prone position with two rolls of soft material inserted transversally, respectively under the chest and the pelvis, to obtain the maximum extension of the spine (17,21,26,30,31). After confining the vertebra and its corresponding pedicles to be treated, a small cutaneous incision is made in the dorsal or lumbar area. Then a bone biopsy needle of 11-Gauge is introduced through the posterior portion of the pedicles, sloping anteriorly, medially and caudally into the tumor (17,21,26,30,31). The access to the vertebral body is normally unilateral with transpedicular pathway, however one can opt for an inter-costo-vertebral entrance into the thoracic levels or posterolateral for the lumbar ones (32).

Once the exact position of the needle had been verified, a 19-Gauge needle electrode (MIRAS-RC, Invatec) and a thermocouple were introduced coaxially through the inserted

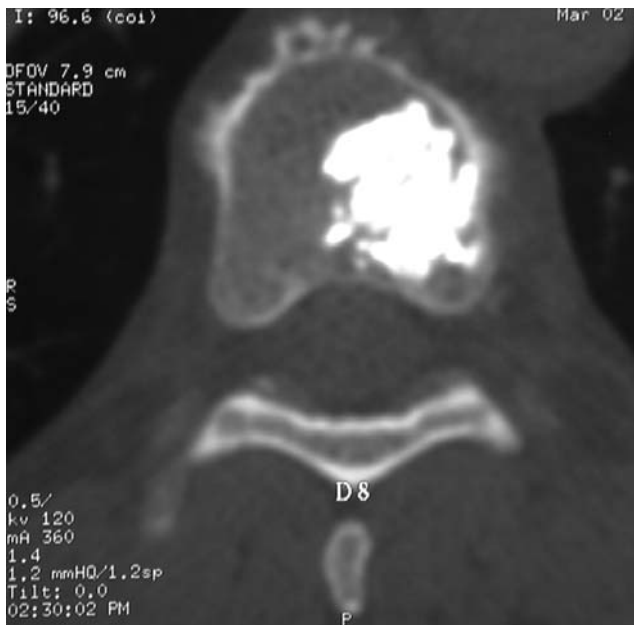


Figure 3. Post-procedure control of PMMA distribution, axial CT-image.

cannula into the central part of the lesion (Figure 1). After unsheathing the spiral electrode tine, which opened to a diameter of 9 mm and length of 10 mm in the metastasis, the needle was connected with a radiofrequency generator. The radiofrequency heat ablation started at an energy level of 15 W. The deployed energy was increased by 5W every 2 min, up to 25 W. Control CT scans revealed microbubble formation in the treated area, indicating tumor necrosis (33).

Meanwhile the cement was prepared by combining liquid monomer and powder cement polymer; everything was amalgamated until it formed into a paste with doughy viscosity. The Polymethylmethacrylate (PMMA) was charged into a dedicated device and injected through the vertebroplasty needle into the vertebral body under continuous fluoroscopic guidance (Figure 2). Control CT scans revealed a homogeneous distribution in the tumor necrosis. To complete the procedure, the needle was extracted, the cutaneous incision was sutured and the patient was instructed to remain in bed, positioned supine, for the following 4 h (34).

The most commonly encountered complication was localized pain and tenderness at the needle sites in the first 72 h after the procedure, usually caused by local bruising or hematoma, which can be resolved with mild analgesics (30). The length of the process for each vertebra was around 35-45 min. A traditional radiographic and CT inspection is performed immediately after the procedure to evaluate the results obtained (Figure 3). In general, the patient was dismissed on the following day.

Results

From January to May 2004, we treated 3 patients (F=2, M=1; ages ranged from 63 to 82 years, mean age 72.3) with metastatic vertebral collapse. Respectively, 2 (F=2) had fractures consequent to breast cancer and 1 (M=1) due to

lung cancer. All patients underwent a single level treatment (Dorsal D8 n= 1, D12 n=1; Lumbar L3 n=1).

Tokuhashi *et al.* proposed a preoperative prognostic scoring system. Six parameters employed in the assessment system are: 1) general medical condition, 2) number of extraspinal metastases, 3) number of vertebral metastases, 4) metastases to the major internal organs (lungs, liver, kidneys and brain), 5) primary site of cancer and 6) severity of spinal cord palsy. Each parameter ranged from 0 to 2 points. Patients who have a total score ≥ 9 survive an average of 12 months or more and are indicated for excisional procedure; whereas those with a score ≤ 5 generally die within 3 months or less and are candidates for a palliative operation. No recommendations were made for patients with a total score of 6 to 8 points (35) (Table I).

The procedure was successfully performed in our patients, whose improvements were swift and persistent in reducing all symptoms, decreasing from an average of 8.6 points of VAS to 2.6 (VAS of Huskisson = Visual analog scale, pain score with points assigned subjectively from patient pre- and post-procedure in a range between 0 absence of grief and 10 maximum pain). Resistance was considerably increased. We did not find any condition of extravasations of PMMA in the epidural or foraminal sites with marrow or radicular compression.

Discussion

Traditional therapies to control pain and to treat bone metastases include radiation therapy, chemotherapy, hormonotherapy (prostate, breast), analgesics and, recently, pamidronate (biphosphonate) has been recognized as useful in osteolytic lesions (15). These conventional therapies, with their well known drawbacks and side-effects, provide reasonable pain relief, obtaining variable success rates. Furthermore, radiotherapy and chemotherapy require a two- to four-week delay to reach efficiency. In some cases, radiotherapy may not be an option because of radiation insensitivity of the tumor or high radiation doses previously delivered. Furthermore, chemotherapy may not be recommended because of its toxicity. Intolerable analgesic-related side-effects may develop with increased doses (15,36,37). Surgical resection is considered the only potentially curative option for secondary malignant bone tumors. However, in secondary bone tumors few patients are surgical candidates. Minimally invasive techniques with quick pain relief can be an alternative option to conventional treatments (15).

Radiofrequency ablation is one of the most promising thermal ablation techniques for the treatment of non-resectable tumors. The use of radiofrequency ablation was first reported in 1990 for the treatment of hepatic tumors (15).

An alternating electric current operated in the range of radiofrequency can produce a focal thermal injury in living

Table I. Scoring system for preoperative evaluation of metastatic spine tumor prognosis (35).

		Patient 1	Patient 2	Patient 3
Evaluation system for the prognosis of metastatic spine tumors				
General condition (performance status)	Score	Female (63)	Female (72)	Male (82)
Poor (PS 10-40%)	0	0	0	0
Moderate (PS 50-70%)	1			
Good (PS 80-100%)	2			
Number of extraspinal metast. foci				
≥3	0	0	0	0
1-2	1			
0	2			
Number of metast. vertebral body				
≥3	0		0	
2	1	1		
1	2			2
Metastases major internal organs				
Unremovable	0	0		
Removable	1		1	1
No metastases	2			
Primary site of the cancer				
Lung, stomach	0			0
Kidney, liver, uterus, others, unidentified	1			
Thyroid, prostate, breast, rectum	2	2	2	
Spinal cord palsy				
Complete	0			
Incomplete	1			
None	2	2	2	2
	Total			
	12	5	5	5

tissue. Shielded needle electrodes are used to concentrate the energy in selected tissue. The tip of the electrode conducts the current, that oscillates in the range of high frequency (200-1.200 kHz), which causes local ionic agitation and subsequent frictional heat, which leads to localized coagulation necrosis. Schematically, a closed-loop circuit is created by placing a generator, a large dispersive electrode (ground pad), a patient and a needle electrode in series (15). The aim of performing radiofrequency heat ablation before vertebroplasty was to destroy tumor tissue and to thrombose the paravertebral and intravertebral venous plexus and, thereby, minimize procedure-related complications. Major benefits of radiofrequency heat ablation are the immediate cell death and the accurate control of lesion size with an imaging-guided procedure (33). The purpose of vertebroplasty was then to stabilize the vertebra. Necrotizing tumor tissue by radiofrequency heat ablation optimizes cement distribution, facilitated by changes in tumor consistency as a result of thermal alterations (33). Percutaneous injection of PMMA bone cement into the vertebral body, described for the first time by Galibert *et al.* in 1984 as "Vertebroplasty", and successfully applied to the treatment of C2 aggressive hemangiomas, is also used on VCF secondary to

osteolytic tumors and osteoporosis (38). Pulmonary embolism and spinal compressions, that can derive from the extrusion of cement, are rare potential complications.

In our study, although limited, vertebroplasty demonstrated itself to be an effective, simple and safe method for the treatment of vertebral compression fractures, providing a precocious and long-lasting pain relief and an evident increase in the resistance of the vertebral body.

Acknowledgements

The authors thank Invatec (Innovative Technologies) for providing the equipment and technical support for this study.

References

- Harrington K: Metastatic tumors of the spine: diagnosis and treatment. *J Am Acad Orthop Surg* 1: 76-86, 1993.
- Klimo P Jr and Schmidt MH: Surgical management of spinal metastases. *Oncologist* 9(2): 188-196, 2004.
- Bohm P and Huber J: The surgical treatment of bony metastases of the spine and limbs. *J Bone Joint Surg Br* 84: 521-529, 2002.

- 4 Wong DA, Fornasier VL and MacNab I: Spinal metastases: the obvious, the occult, and the impostors. *Spine* 15(1): 1-4, 1990.
- 5 Healey JH and Brown HK: Complications of bone metastases: surgical management. *Cancer* 88(12 Suppl): 2940-2951, 2000.
- 6 Bilsky MH, Lis E, Raizer J, Lee H and Boland P: The diagnosis and treatment of metastatic spinal tumor. *Oncologist* 4(6): 459-469, 1999.
- 7 Byrne TN: Spinal cord compression from epidural metastases. *N Engl J Med* 327(9): 614-619, 1992.
- 8 Gerszten PC and Welch WC: Current surgical management of metastatic spinal disease. *Oncology (Huntingt)* 14(7): 1013-1024, 2000.
- 9 Barron Kd, Hirano A, Araki S and Terry Rd: Experiences with metastatic neoplasms involving the spinal cord. *Neurology* 9(2): 91-106, 1959.
- 10 Schaberg J and Gainer BJ: A profile of metastatic carcinoma of the spine. *Spine* 10(1): 19-20, 1985.
- 11 Lada R, Kaminski HJ and Ruff R: Metastatic spinal cord compression. In: Vecht C, ed. *Neuro-oncology Part III. Neurological Disorders in Systemic Cancer*. Amsterdam: Elsevier Biomedical Publishers, 1997:167-189.
- 12 Gilbert RW, Kim JH and Posner JB: Epidural spinal cord compression from metastatic tumor: diagnosis and treatment. *Ann Neurol* 3(1): 40-51, 1978.
- 13 Adams M and Sonntag VKH: Surgical treatment of metastatic cervical spine disease. *Contemp Neurosurg* 23: 1-5, 2001.
- 14 Cook AM, Lau TN, Tomlinson MJ *et al*: Magnetic resonance imaging of the whole spine in suspected malignant spinal cord compression: impact on management. *Clin Oncol (R Coll Radiol)* 10: 39-43, 1998.
- 15 Gangi A, Guth S, Imbert JP, Marin H, Jeung MY and Wong LLS: Radiofrequency ablation of bone metastases. *ECR 2003 Cum Laude*.
- 16 Mathis JM, Barr JD, Belkoff SM, Barr MS, Jensen ME and Deramond H: Percutaneous vertebroplasty: a developing standard of care for vertebral compression fractures. *Am J Neuroradiol* 22(2): 373-381, 2001.
- 17 McKiernan F, Jensen R and Faciszewski T: The dynamic mobility of vertebral compression fractures. *J Bone Miner Res* 18(1): 24-29, 2003.
- 18 Zoarski GH, Snow P, Olan WJ, Stallmeyer MJ, Dick BW, Hebel JR and De Deyne M: Percutaneous vertebroplasty for osteoporotic compression fractures: quantitative prospective evaluation of long-term outcomes. *J Vasc Interv Radiol* 13(2 Pt 1): 139-148, 2002.
- 19 Belkoff SM, Mathis JM, Fenton DC, Scribner RM, Reiley ME and Talmadge K: An *ex vivo* biomechanical evaluation of an inflatable bone tamp used in the treatment of compression fracture. *Spine* 26(2): 151-156, 2001.
- 20 Higgins KB, Harten RD, Langrana NA and Reiter MF: Biomechanical effects of unipedicular vertebroplasty on intact vertebrae. *Spine* 28(14): 1540-1548, 2003.
- 21 Ahrar K, Schomer DF and Wallace MJ: Kyphoplasty for the treatment of vertebral compression fractures. *Semin Intervent Radiol* 19(3): 235-243, 2002.
- 22 Amar AP, Larsen DW, Esnaashari N, Albuquerque FC, Lavine SD and Teitelbaum GP: Percutaneous transpedicular polymethylmethacrylate vertebroplasty for the treatment of spinal compression fractures. *Neurosurgery* 49(5): 1105-1114, 2001.
- 23 Garfin SR, Yuan HA and Reiley MA: New technologies in spine: kyphoplasty and vertebroplasty for the treatment of painful osteoporotic compression fractures. *Spine* 26(14): 1511-1515, 2001.
- 24 Coumans JV, Reinhardt MK and Lieberman IH: Kyphoplasty for vertebral compression fractures: 1-year clinical outcomes from a prospective study. *J Neurosurg* 99(1 Suppl): 44-50, 2003.
- 25 Masala S, Cesaroni A, Sergiacomi G, Fiori R, Massari F, Manenti G, Nardi PV and Simonetti G: Percutaneous kyphoplasty: New treatment for painful vertebral body fractures. *In Vivo* 18(2): 149-153, 2004.
- 26 Fournay DR, Schomer DF, Nader R, Chlan-Fournay J, Suki D, Ahrar K, Rhines LD and Gokaslan ZL: Percutaneous vertebroplasty and kyphoplasty for painful vertebral body fractures in cancer patients. *J Neurosurg* 98(1 Suppl): 21-30, 2003.
- 27 Linville DA 2nd: Vertebroplasty and kyphoplasty. *South Med* 95(6): 583-587, 2002.
- 28 Ledlie JT and Renfro M: Balloon kyphoplasty: one-year outcomes in vertebral body height restoration, chronic pain, and activity levels. *J Neurosurg* 98(1 Suppl): 36-42, 2003.
- 29 Masala S, Fiori R, Massari F and Simonetti G: Kyphoplasty and vertebroplasty: new equipment for vertebral fractures treatment. *J Exp Clin Cancer Res* 22(4 Suppl): 75-79, 2003.
- 30 Stallmeyer MJ, Zoarski GH and Obuchowski AM: Optimizing patient selection in percutaneous vertebroplasty. *J Vasc Interv Radiol* 14(6): 683-696, 2003.
- 31 Hardouin P, Fayada P, Leclot H and Chopin D: Kyphoplasty. *Joint Bone Spine* 69(3): 256-261, 2002.
- 32 Gangi A, Wong LLS, Guth S and Dietemann JL: Percutaneous vertebroplasty: indications, technique, and results. *Semin Intervent Radiol* 19(3): 265-270, 2002.
- 33 Schaefer O, Lohrmann C, Markmiller M, Uhrmeister P and Langer M: Technical innovation. Combined treatment of a spinal metastasis with radiofrequency heat ablation and vertebroplasty. *Am J Roentgenol* 180(4): 1075-1077, 2003.
- 34 Dudeney S, Lieberman IH, Reinhardt MK and Hussein M: Kyphoplasty in the treatment of osteolytic vertebral compression fractures as a result of multiple myeloma. *J Clin Oncol* 20(9): 2382-2387, 2002.
- 35 Tokuhashi Y, Matsuzaki H, Toriyama S, Kawano H and Ohsaka S: Scoring system for the preoperative evaluation of metastatic spine tumor prognosis. *Spine* 15(11): 1110-1113, 1990.
- 36 Callstrom MR, Charboneau JW, Goetz MP, Rubin J, Wong GY, Sloan JA, Novotny PJ, Lewis BD, Welch TJ, Farrell MA, Maus TP, Lee RA, Reading CC, Petersen IA and Pickett DD: Painful metastases involving bone: feasibility of percutaneous CT- and US-guided radio-frequency ablation. *Radiology* 224(1): 87-97, 2002.
- 37 Poggi G, Gatti C, Melazzini M, Bernardo G, Strada M, Teragni C, Delmonte A, Tagliaferri C, Bonezzi C, Barbieri M, Bernardo A and Fratino P: Percutaneous ultrasound-guided radiofrequency thermal ablation of malignant osteolyses. *Anticancer Res* 23(6D): 4977-4983, 2003.
- 38 Galibert P, Deramond H, Rosat P and Le Gars D: Preliminary note on the treatment of vertebral angioma by percutaneous acrylic vertebroplasty. *Neurochirurgie* 33(2): 166-168, 1987.

Received July 19, 2004
Accepted July 28, 2004