

The health of soft tissues around four dental implants loaded immediately supporting a 4-year-old fixed screw-retained prosthesis

P. Carosi¹, L. Ottria¹, F. Lio¹, A. Laureti² and P. Papi³

¹Department of Chemical Science and Technologies, Dentistry, University of Rome "Tor Vergata", Rome, Italy; ²Fondazione Policlinico Universitario A. Gemelli IRCCS, Institute of Dentistry and Maxillofacial Surgery, Università Cattolica del Sacro Cuore, Rome, Italy; ³Department of Oral and Maxillo-Facial Sciences, "Sapienza" University of Rome, Rome, Italy

The aim of this study was to assess the soft tissues health around the implant/abutment interfaces of fixed screw-retained prosthesis supported by four dental implants after at least 1-year in function. All the implants were placed between December 1, 2015 and April 30, 2019. Digital implant surgical planning was performed for all the complete-arch rehabilitations and then full-guided surgery was performed. The fixed-interim prostheses were delivered the day of the surgery and replaced by definitive prostheses after the healing period. Patients were followed-up to determinate peri-implant scores, such as Plaque Score (PS) and Bleeding on Probing (BoP). A total of 160 implants were placed in 37 patients, whereas 3 patients received both arches rehabilitated. A total of 40 complete-arch rehabilitations were performed, 26 in the maxilla and 14 in the mandible. Only 5 implants failed resulting in an overall implant survival rate of 96.9%. BoP was detected around 6 implants (3.7%) and 16 implants showed a superficial amount of plaque resulting a Plaque Score of 10%. Within the limitation of this study, it seems that the use of a fixed screw-retained prostheses supported by four dental implants to rehabilitate edentulous jaws could be a valid treatment option in the short and medium term without critical peri-implant issues. However, several perspective studies with longer follow-up are needed to achieve more predictable results.

Nowadays, treatment of edentulous patients aims to restore both masticatory and aesthetic function by means of prostheses that are functionally stable and identical from the natural dentition over time (1-9). Fixed prostheses supported by dental implants have become more and more required by the patients. These prostheses are a well-documented method to treat from a single tooth gap to full mouth rehabilitation (10-19). The main limitation of full-arch rehabilitation is the possible reabsorption of posterior jaws due to the presence of hopeless teeth or long-time edentulism.

Bone reabsorption is often related to a pneumatization of maxillary sinus in the maxillary jaws and a surfacing of the inferior alveolar nerve. In the beginning of 2000, it was proposed to insert implants with >12 mm length in tilted position of 30° in order to avoid the maxillary sinus or the mental foramen and to get in contact with native bone (20-27). The technique provided the use of four implants with two straights in frontal area and two tilted in the posterior region (28-33). The four implants had to be placed in regular and symmetric manner to provide an inter-implant distance as large as possible.

Key words: computer guided surgery, digital workflow, soft tissue, full arch

Corresponding author:

Paolo Carosi

Department of Chemical Science and Technologies, Dentistry,
University of Rome "Tor Vergata",
Rome, Italy

e-mail: carosipaolo29@gmail.com

57(S1)

0393-974X (2020)

Copyright © by BIOLIFE, s.a.s.

This publication and/or article is for individual use only and may not be further reproduced without written permission from the copyright holder.

Unauthorized reproduction may result in financial and other penalties
DISCLOSURE: ALL AUTHORS REPORT NO CONFLICTS OF INTEREST RELEVANT TO THIS ARTICLE.

Traditionally, a mucoperiosteal flap had to be raised to visualize the implant recipient site. This can be unnecessary when computer-guided surgery is performed by means of surgical templates that give guidance to the surgeon because the accuracy that 3D study gives to the clinician provides to perform a minimally invasive flapless implant surgery causing less pain and discomfort to the patients and improving healing process due to the preservation of blood circulation in the soft tissues.

Immediate loading protocol for edentulous complete arches have been developed and have been largely accepted by clinicians and patients. The immediate loading of dental implants to restore complete arch is performed by means of an interim screw-retained prosthesis solidarized onto the implants. However, oral hygiene maintenance can be a hard challenge for the patients (34-39). A considerable accumulation of plaque can be encountered around the implants/abutments interfaces and plaque deposits have been reported to cause mucositis.

The aim of this study was to assess the soft tissues health around the implant/abutment interfaces of fixed screw-retained prosthesis supported by four dental implants after at least 1-year in function. This research is reported according to the STROBE statement.

MATERIALS AND METHODS

This retrospective study included all patients treated in a private dental clinic with fixed full arch screw retained prosthesis supported by four dental implants loaded immediately in the maxilla and/or mandible between December 1, 2015 and April 30, 2019 to have at least 1 year of follow-up after definitive prosthesis delivery.

All patients signed an informed consent for data collection. The medical status of patients regarding any diseases was documented. The patients included in this study needed to present complete edentulous jaws or hopeless teeth requiring extraction refusing invasive grafting procedures. In addition, the patients needed to suite the following inclusion criteria: absence of oral mucosal disease; suitable bone dimension for the insertion of 4 implants of the following minimum dimensions: \emptyset

$\geq 4.1\text{mm}$ x length 8mm or $\emptyset 3.3\text{mm}$ x length 10mm. Furthermore, patients with one of these conditions were excluded: heavy smokers (more than 5 cigarettes per day); drug or alcohol abuse; poor oral hygiene; radiotherapy in the head and neck region; patients undergoing antitlastic chemotherapy. The procedures accomplished in this study were in accordance with the Helsinki Declaration of 1964 and revised in 2013 about ethical principles regarding human experimentation.

For each rehabilitation, a case study was digitally performed by means of implant planning software (coDiagnostix, Dental Wings, Montreal, Canada) (Fig. 1).

The digital data from the patients were merged together in order to perform a full guided static-template assisted surgery. On the day of the surgery, all patients received antibiotic prophylactic therapy: 2 g of amoxicillin (or clindamycin 600 mg if allergic to penicillin) 1 hour before the surgery and rinsed with chlorhexidine mouthwash 0.2% for 1 minute before the intervention. Local anesthesia was performed using articaine with adrenaline 1:100000 (40-41). All hopeless teeth were extracted the day of the implant surgery as gently as possible if they cannot be useful to support the surgical template. The precise fit of surgical templates was checked before the surgery.

To stabilize the templates a surgical silicon index was used, and two or three pre-planned anchor pins were inserted. All implants were inserted using a full guided surgery. Implants sites were prepared using a dedicated drill set (Straumann, Straumann Holding AG, Basel, Switzerland) following manufacturer's guidelines. Two types of dental implants (Straumann Bone Level and Straumann Bone Level Tapered, Straumann) could be used. Mucoperiosteal flaps were raised if any implant site needed guided bone regeneration (GBR). Care was taken to not overextend the flaps to maintain miniminvasivity. The implant insertion torque was measured after the removal of surgical template to avoid any interferences. Following implant placement, screw retained abutments (SRA, Straumann) were placed to correct angle compensation for tilted posterior implants and to correct implant angulation in the anterior zone when placed in the residual alveolar ridge. Soft tissue closure was performed using Polyglycolic Acid (PGA) sutures (Vicryl, Ethicon, Somerville, NJ, USA).

The interim prosthesis based on the digital plan was designed and milled by the dental technician from a block

of polymethyl methacrylate (PMMA, dima Mill temp, Kulzer) and blocked-out to the titanium copings. The prosthesis, without cantilever, was attached to the SRAs and it was screwed to 15 Ncm of torque. Patients were instructed to rinse with 0.2% chlorhexidine mouthwash for one minute twice a day for 15 days, to have a soft diet for one month and to avoid any trauma on the surgical sites. If an implant demonstrated mobility, pain or soft tissue irritation it had to be removed, recorded in the database as a failure, and then replaced after 3 months. The definitive prosthesis consisted of a titanium infrastructure around which acrylic resin denture base material with denture teeth (Fig. 2).

The occlusal scheme was adapted to the opposing dentition. In addition, patients were instructed to wear a nightguard to protect the acrylic teeth during the night. Patients were recalled every 4 months for professional oral hygiene and every 12 months for the annual radiographic and clinical examination. Panoramic radiographs were performed by an independent operator in order to assess radiographic peri-implant bone quality following the European Association for Osseointegration guidelines¹⁰ (Fig. 3). Periodontal

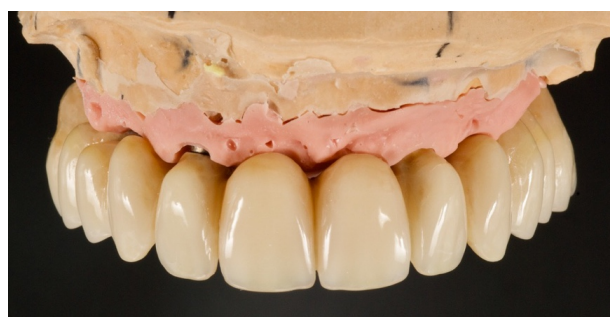

Fig. 2. Definitive prosthesis.

parameters bleeding on probing (BoP) and plaque score (PS) were recorded at each planned visit.

Outcomes

Soft tissue parameters around the implant/abutment interfaces (Fig. 4) were assessed by means of a periodontal probe (Hu-Friedy PGF-GFS, Hu-Friedy, Chicago, IL., USA). The BoP was recorded at four sites around each implant (mesial, distal, buccal and lingual) according to the Mombelli Index. The probe was carefully inserted 1 mm into the sulcus and the provoked bleeding within 20 s was assessed (0 = no bleeding; 1 = spot bleeding, 2 =

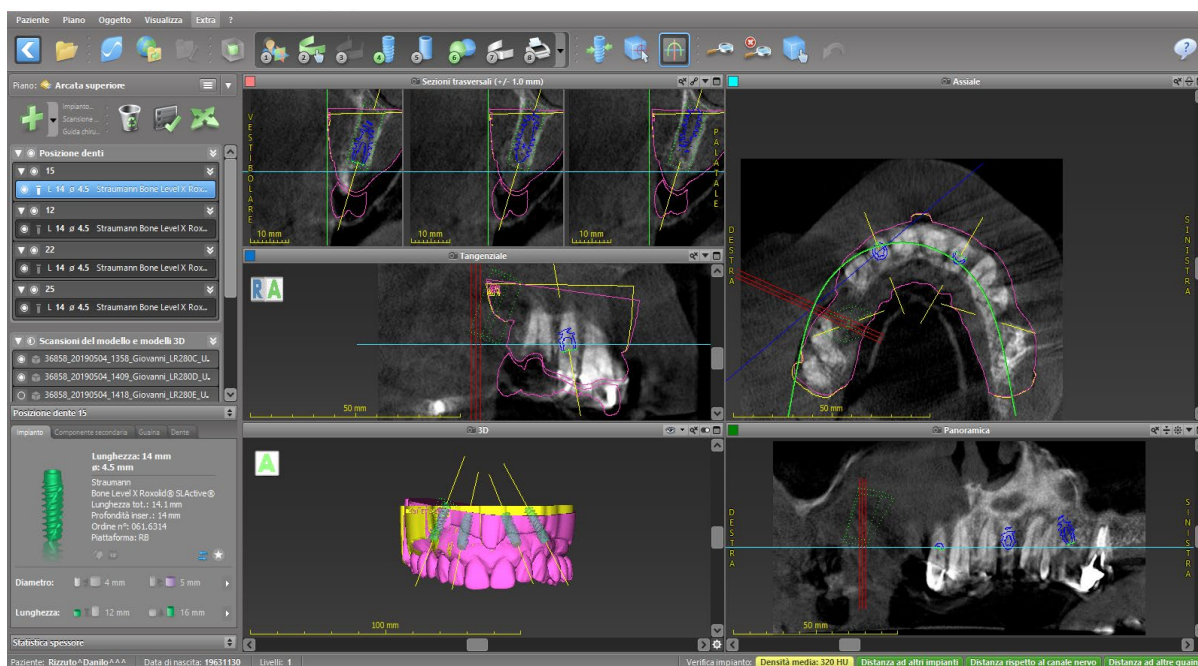


Fig. 1. Digital planning of the rehabilitation.

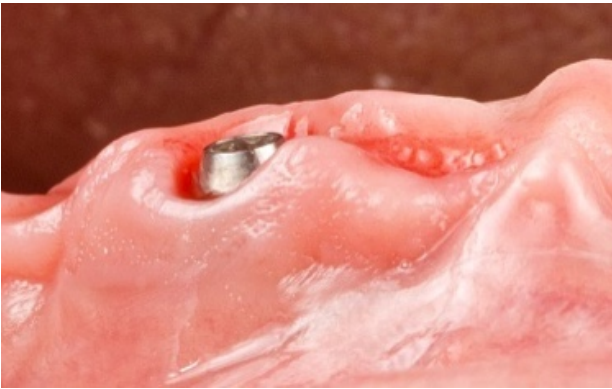

Fig. 3. *Implant/abutment interface.*

linear bleeding, and 3 = spontaneous bleeding).

The PS was measured by running the periodontal probe parallel to the abutment surfaces and scored at one site for implants as the presence of plaque (yes/no) on the abutment/restoration complex. An independent blinded dental hygienist who was not involved in the study recorded all the periodontal measurements.

Statistical analysis

All the data were imported onto a master spreadsheet and the name of the patients were codified to be de-

identified. Descriptive analysis was performed using mean and standard deviation. The implant was used as unit in the statistical analysis.

RESULTS

Clinical data from 37 patients of both sexes (20 men and 17 women), mean age, 68.3 years ranged from 46 to 97 years, rehabilitated with a fixed screw-retained prosthesis supported by four dental implants inserted using computer guided surgery, and followed-up with a minimum period of 1 year were collected and analyzed in the statistical analysis (Table I).

A total of 160 dental implants were placed and all of them were loaded immediately receiving a fixed screw-retained interim complete-arch prostheses without cantilevers (Table II). A total of 26 maxillary arches and 14 mandibular arches were rehabilitated. Three out of 40 patients received both arches rehabilitated. One-hundred four implants were placed in the maxilla and fifty-six were placed in the mandible. BoP was detected around 6 implants (3.7%) and 16 implants showed a superficial amount of plaque resulting a Plaque Score of 10%.

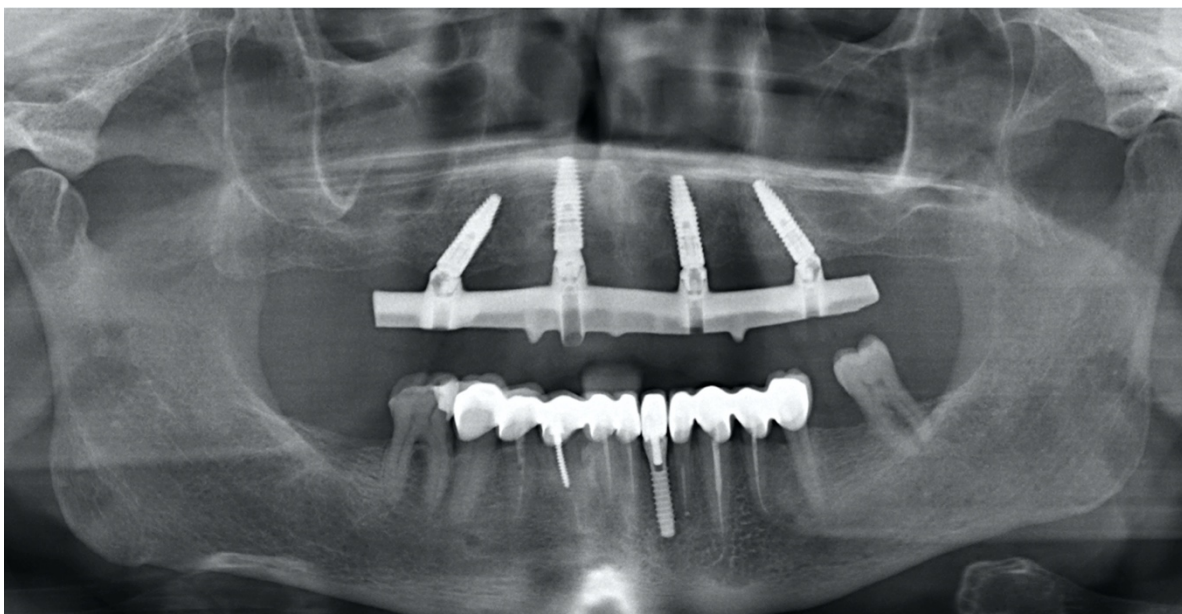


Fig. 4. *Panoramic X-Ray of the definitive prosthesis.*

Eighty-three implants were placed in healed sites (51.9%) while seventy-seven implants were placed in post-extraction sockets (48.1%). One-hundred six implants were placed flapless (66.2%) while fifty-four implants were placed raising a mucoperiosteal

flap (33.8%). Forty-eight implant sites needed GBR (30%). Two different types of dental implants were used: 12 Bone Level (BL, Straumann, Straumann Institute AG) and 148 Bone Level Tapered (BLT, Straumann, Straumann Institute AG). A total of

Table I. *Main characteristics of the patients.*

Patients (Female, Male)	37 (17, 20)
Age	68.3 (46-97)
Smokers \leq 5 cigarettes per day	9
Complete arches rehabilitated	40
Maxilla	26
Mandible	14
Opposite dentition	
Natural teeth and ceramic crowns	17
Removable dentures	13
Natural teeth	4
Both arches treated	3

Table II. *Main characteristics of the implants.*

Number of implants	160
Failed implants	5
Type of implants	
Bone Level Tapered RegularCrossfit [®]	108
Bone Level Tapered NarrowCrossfit [®]	40
Bone Level RegularCrossfit [®]	12
Implants in the maxilla	104
Implants in the mandible	56
Implants length:	
14 mm	87 (54.4%)
12 mm	58 (36.2%)
10 mm	12 (7.5%)
8 mm	3 (1.9%)

120 4.1 mm Ø RegularCrossfit® implants (RC, Straumann, Straumann Institute) were used, while 40 3.3 mm Ø NarrowCrossfit® implants (NC, Straumann, Straumann Institute) were used. The most used implant length was 14 mm 87 times (54.4%), followed by 12 mm 58 times (36.2%), 10 mm 12 times (7.5%) and 8 mm 3 times (1.9%). Forty definitive screw-retained prostheses were delivered. Concerning the opposite dentition, 17 patients presented natural teeth and some fixed ceramic crowns, 13 patients had removable dentures, 4 patients presented all natural teeth and 3 patients had both arches rehabilitated. No dropouts occurred during the entire follow-up. After the healing period, a total of 40 definitive prostheses were delivered (Fig. 5). All the 37 patients were followed up for at least 1 year. All the data collected were included in the statistical analysis. No deviations occurred and all the 37 patients were treated following the original protocol. At the last follow-up.

DISCUSSION

This retrospective study aimed to assess the soft tissues health around the implant/abutment interfaces of fixed screw-retained prosthesis supported by four dental implants after at least 1-year in function (42-51). The main limitation of this study is in its intrinsic retrospective nature. The rehabilitation of complete arch by means of four dental implants supporting a fixed screw-retained prosthesis had

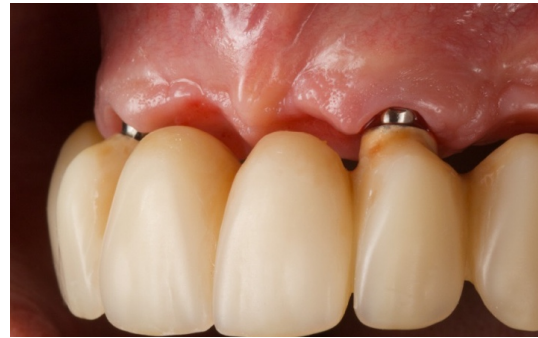

Fig. 6. *Prosthetic scalloped design.*

become a validated therapeutic option³. Through the last years, several studies investigated how long only four dental implants can support fixed-complete-arch prosthesis over short- and long-term follow-up.

The peri-implant tissues healthy is strictly connected also to the prosthetic design. (Fig. 6). The interim prostheses had no cantilevers while the definitive prostheses were designed in order to have 12 mm or 15 mm maximum of cantilevers in the maxilla and in the mandible respectively to minimize biomechanical risks. In addition, several studies investigated the amount of plaque and the presence of BoP around the implant/abutment interfaces. The results are not similar with this study. As a matter of fact, a study by Menini et al reported a BoP of 21.1%. The type of dental implants used in this study can have influenced the peri-implant values recorded. All the implants used had core made of titanium-zirconium alloy (Roxolid®) and a chemically

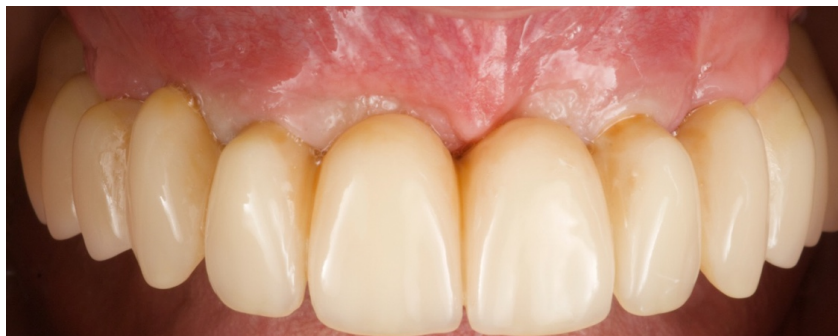

Fig. 5. *Definitive prosthesis in situ.*

modified sandblasted, large-grit and acid-etched surface (SLActive®). The described characteristics of the type of dental implants used may be crucial when immediate loading is performed. Frequently, implant failures occur in the early healing phase of osseointegration. The period between the 2nd and the 4th week after implant placement is the turning point from the primary mechanical stability to the secondary biological stability.

The possibility to achieve a secondary stability by means of a hydrophilic modified surface faster reduces the risks in the early phase and eliminates the stability dip between the primary and secondary stability (52-59). The prosthesis realization has to be carefully made in order to achieve a high prosthesis success rate over the medium and long period. Constant recall to perform professional oral hygiene and occlusion and radiographic checks in combination with nightguard wearing are mandatory to achieve a successful rehabilitation through the years.

If any implant site required GBR a mucoperiosteal flap was raised only above the requiring site to not compromise surgical template stability and maintaining an acceptable implant surgery accuracy (60-63). Finally, it is mandatory to remind that diagnosis, treatment planning and surgical procedures have to be performed carefully and a learning curve is required to better understand and use the computer-assisted implant planning software to achieve successful and free of issues rehabilitations.

Complete arch rehabilitations are always a hard challenge to face for every clinician and the maintenance is as hard as the clinical situations. However, within the limitation of this study, it seems that the use of a fixed screw-retained prostheses supported by four dental implants to rehabilitate edentulous jaws could be a valid treatment option in the short and medium term without critical peri-implant issues. However, several perspectives studies with longer follow-up period are required to assess the reliability of this treatment protocol.

REFERENCES

- Carosi P, Ferrigno N, De Renzi G, Laureti M. Digital Workflow to Merge an Intraoral Scan and CBCT of Edentulous Maxilla: A Technical Report. *J Prosthodont* 2020; 29(8):730-732.
- Pozzi A, Polizzi G, Moy PK. Guided surgery with tooth-supported templates for single missing teeth: A critical review. *Eur J Oral Implantol* 2016; 9(Suppl 1):S135-53.
- Krekmanov L, Kahn M, Rangert B, Lindström H. Tilting of posterior mandibular and maxillary implants for improved prosthesis support. *Int J Oral Maxillofac Implants* 2000; 15(3):405-14.
- Aparicio C, Perales P, Rangert B. Tilted Implants as an Alternative to Maxillary Sinus Grafting: A Clinical, Radiologic, and Periotest Study. *Clin Implant Dent Relat Res* 2001; 3(1):39-49.
- Fortin T, Bosson JL, Isidori M, Blanchet E. Effect of flapless surgery on pain experienced in implant placement using an image-guided system. *Int J Oral Maxillofac Implants* 2006; 21(2):298-304.
- Maló P, Rangert B, Nobre M. All-on-4 Immediate-Function Concept with Branemark SystemR Implants for Completely Edentulous Maxillae: A 1-Year Retrospective Clinical Study. *Clin Implant Dent Relat Res* 2005; 7(Suppl 1):s88-s94.
- Maló P, Nobre M de, Lopes A. The rehabilitation of completely edentulous maxillae with different degrees of resorption with four or more immediately loaded implants: a 5-year retrospective study and a new classification. *Eur J Oral Implantol* 2011; 4(3):227-43.
- Papi P, Di Murro B, Pranno N, et al. Prevalence of peri-implant diseases among an Italian population of patients with metabolic syndrome: A cross-sectional study. *J Periodontol* 2019; 90(12):1374-1382.
- Cuschieri S. The STROBE guidelines. *Saudi J Anaesth* 2019; 13(Suppl 1): S31-S34.
- Harris D, Horner K, Gröndahl K, et al. E.A.O. guidelines for the use of diagnostic imaging in implant dentistry 2011. A consensus workshop organized by the European Association for Osseointegration at the Medical University of Warsaw. *Clin Oral Implants Res* 2012; 23(11):1243-1253.
- Mombelli A, Lang NP. The diagnosis and treatment of peri-implantitis. *Periodontol* 2000 1998; 17:63-76.
- Salvi GE, Brägger U. Mechanical and technical risks in implant therapy. *Int J Oral Maxillofac Implants*

- 2009; 24(Suppl):69–85.
13. Menini M, Setti P, Pera P, Pera F, Pesce P. Peri-implant Tissue Health and Bone Resorption in Patients with Immediately Loaded, Implant-Supported, Full-Arch Prosthesis. *Int J Prosthodont* 2018;31(4):327-333.
 14. Wen B, Zhu F, Li Z, Zhang P, Lin X, Dard M. The osseointegration behavior of titanium-zirconium implants in ovariectomized rabbits. *Clin Oral Implants Res* 2014; 25(7):819–825.
 15. Lauritano D, Moreo G, Limongelli L, Palmieri A, Carinci F. Drug-Induced Gingival Overgrowth: The Effect of Cyclosporin A and Mycophenolate Mophetil on Human Gingival Fibroblasts. *Biomedicines* 2020; 8(7):221.
 16. Lauritano D, Palmieri A, Lucchese A, Di Stasio D, Moreo G, Carinci F. Role of Cyclosporine in Gingival Hyperplasia: An In Vitro Study on Gingival Fibroblasts. *Int J Mol Sci* 2020; 21(2):595.
 17. Lauritano D, Moreo G, Limongelli L, Tregambi E, Palmieri A, Carinci F. Drug-Induced Gingival Overgrowth: A Pilot Study on the Effect of Diphenylhydantoin and Gabapentin on Human Gingival Fibroblasts. *Int J Environ Res Public Health* 2020; 17(21):E8229.
 18. Di Stasio D, Lauritano D, Iquebal H, Romano A, Gentile E, Lucchese A. Measurement of Oral Epithelial Thickness by Optical Coherence Tomography. *Diagnostics (Basel)* 2019; 9(3):90.
 19. Lico S, Andrisani C, Bassi MA, Candotto V, Silvestre FJ, Lauritano D. Computer-guided implant insertion in a patient with impacted maxillary canines: Case report. *J Biol Regul Homeost Agents* 2017; 31(2, Suppl 1):247-251.
 20. Bassi MA, Andrisani C, Lopez MA, Gaudio RM, Lombardo L, Lauritano D. Guided bone regeneration in distal mandibular atrophy by means of a preformed titanium foil: A case series. *J Biol Regul Homeost Agents* 2016; 30(2 Suppl 1): 61-68.
 21. Lopez MA, Bassi MA, Confalone L, Carinci F, Ormianer Z, Lauritano D. The use of resorbable cortical lamina and micronized collagenated bone in the regeneration of atrophic crestal ridges: A surgical technique. Case series. *J Biol Regul Homeost Agents* 2016; 30(2 Suppl 1):81-85.
 22. Carosi P, Barlattani A, Lorenzi C, Bianchi N, Arcuri C. Diode laser as an adjunct to nonsurgical chronic periodontitis therapy: A review. *J Biol Regul Homeost Agents* 2020; 34(3):45-54.
 23. Testi D, Nardone M, Melone P, Ottria L, Arcuri C. HPV and oral lesions: Preventive possibilities, vaccines and early diagnosis of malignant lesions. *Oral Implantol (Rome)* 2016; 8(2-3):45-51.
 24. Germano F, Germano F, Piro M, Arcuri C, Ottria L. Clinical protocol with digital CAD/CAM chairside workflow for the rehabilitation of severely worn dentition patients. *Oral Implantol (Rome)* 2017; 10(3):247-261.
 25. Lio F, Ottria L, Mazzetti V, Leggeri A, Casella S, Arcuri L. The effectiveness of subgingival irrigant ozone-based as adjuvant for non-surgical periodontal therapy in the treatment of chronic periodontitis: A review. *J Biol Regul Homeost Agents* 2020; 34(3 Suppl 1):27-34.
 26. Pirelli P, Fanucci E, Giancotti A, Di Girolamo M, Guillemineault C. Skeletal changes after rapid maxillary expansion in children with obstructive sleep apnea evaluated by low-dose multi-slice computed tomography. *Sleep Med* 2019; 60:75.
 27. Arcuri C, Petro E, Sollecchia G, Mummolo S, Marzo G. Laser in periodontal pockets: In vivo and in vitro study. *J Biol Regul Homeost Agents* 2020; 34(3 Suppl 1):139–146.
 28. Esin S, Pasini M, Miceli M, Cosseddu G, Giuca MR, Batoni G. Longitudinal study on the effect of oral hygiene measures on the salivary count of microbial species with cariogenic potential. *J Biol Regul Homeost Agents* 2018; 32(6):1407-1420.
 29. Miceli M, Cosseddu G, Pasini M, Semeraro S, Lardani L, Giuca MR. Simplified basic periodontal examination in adolescents before and after a tailored treatment dental program. *Minerva Stomatol* 2020; 69(2):72-78.
 30. Giuca MR, Miceli M, Carli E, Lardani L, Marchio V, Baldini C. Impact of Sjögren's syndrome on oral health and quality of life: an observational cross-sectional study. *J Biol Regul Homeost Agents* 2020;34(3 Suppl. 1):129-137.
 31. Marchetti E, Petro E, Gaggioli F, Lardani L, Mancini L, Marzo G. The dentist's role in diagnosis and treatment of obstructive sleep apnea syndrome: a literature review. *J Biol Regul Homeost Agents* 2020; 34(3 Suppl. 1):173-180.

32. Pasini M, Giuca MR, Ligorì S, Mummolo S, Fiasca F, Marzo G, Quinzi V. Association between Anatomical Variations and Maxillary Canine Impaction: A Retrospective Study in Orthodontics. *Appl Sci* 2020; 10(16):5638.
33. Mazza D, Di Girolamo M, Cecchetti F, Baggi L. MRI findings of working and non-working TMJ during unilateral molar clenching on hard bolus. *J Biol Regul Homeost Agents* 2020; 34(3 Suppl. 1):1-8.
34. Milia E, Usai M, Szotáková B, Elstnerová M, Králová V, D'hallewin G, Spissu Y, Barberis A, Marchetti M, Bortone A, Campanella V, Mastandrea G, Langhansová L, Eick S. The Pharmaceutical Ability of *Pistacia lentiscus* L. Leaves Essential Oil Against Periodontal Bacteria and *Candida* sp. and Its Anti-Inflammatory Potential. *Antibiotics (Basel)* 2020; 9(6):281.
35. Marchetti E, Mummolo S, Mancini L, Quinzi V, Pontieri E, Marzo G, Campanella V. Decontamination in the dental office: a comparative assessment of a new active principle. *Dental Cadmos* 2021;89(3):200-206.
36. Mummolo S, Nota A, Albani F, et al. Salivary levels of *Streptococcus mutans* and Lactobacilli and other salivary indices in patients wearing clear aligners versus fixed orthodontic appliances: An observational study. *PLoS One* 2020; 15(4):e0228798.
37. Marchetti E, Casalena F, Capestro A, Tecco S, Mattei A, Marzo G. Efficacy of two mouthwashes on 3-day supragingival plaque regrowth: a randomized crossover clinical trial. *Int J Dent Hyg* 2017; 15(1):73–80.
38. Mummolo S, Severino M, Campanella V, Barlattani A Jr, Quinzi V, Marchetti E. Chlorhexidine gel used as antiseptic in periodontal pockets. *J Biol Regul Homeost Agents* 2019;33(3 Suppl. 1):83-88.
39. Mummolo S, Severino M, Campanella V, Barlattani A Jr, Quinzi V, Marchetti E. Periodontal disease in subjects suffering from coronary heart disease. *J Biol Regul Homeost Agents* 2019; 33(3):73–82.
40. Libonati A, Nardi R, Gallusi G, Angotti V, Caruso S, Coniglione F, Marzo G, Mattei A, Tecco S, Paglia L, Campanella V. Pain and anxiety associated with Computer-Controlled Local Anaesthesia: systematic review and meta-analysis of cross-over studies. *Eur J Paediatr Dent* 2018;19(4):324-332.
41. Campanella V, Libonati A, Nardi R, Angotti V, Gallusi G, Montemurro E, D'Amario M, Marzo G. Single tooth anesthesia versus conventional anesthesia: a cross-over study. *Clin Oral Investig* 2018;22(9):3205-3213.
42. Mazza D, Di Girolamo M, Cecchetti F, Baggi L. Appearance of normal MRI anatomy of the lingual nerve using steady-state free precession sequences at 3-T. *J Biol Regul Homeost Agents* 2020; 34(3 Suppl. 1):19-26.
43. Cecchetti F, Di Girolamo M, Ippolito DG, Baggi L. Computer-guided implant surgery: analysis of dynamic navigation systems and digital accuracy. *J Biol Regul Homeost Agents* 2020; 34(3 Suppl. 1):9-17.
44. Ruggiero F, Carbone D, Mugavero R, Palmieri A, Lauritano D, Baggi L, Nardone M, Martinelli M, Carinci F. Human polyomavirus in tonsillar microbiota of an Afghan population group. *J Biol Regul Homeost Agents* 2018; 32(2 Suppl. 1):185-190.
45. Ottria L, Candotto V, Cura F, Baggi L, Arcuri C, Nardone M, Gaudio RM, Gatto R, Spadari F, Carinci F. HPV acting on E-cadherin, p53 and p16: literature review. *J Biol Regul Homeost Agents* 2018; 32(2 Suppl. 1):73-79.
46. Carinci F, Scapoli L, Contaldo M, Santoro R, Palmieri A, Pezzetti F, Lauritano D, Candotto V, Mucchi D, Baggi L, Tagliabue A, Tettamanti L. Colonization of *Legionella* spp. In dental unit waterlines. *J Biol Regul Homeost Agents* 2018; 32(2 Suppl. 1):139-142.
47. Mancini L, Quinzi V, Mummolo S, Marzo G, Marchetti E. Angiotensin-converting enzyme 2 as a possible correlation between COVID-19 and periodontal disease. *Appl Sci (Switzerland)* 2020; 10(18):6224.
48. Saccomanno S, Quinzi V, Sarhan S, Laganà D, Marzo G. Perspectives of tele-orthodontics in the COVID-19 emergency and as a future tool in daily practice. *Eur J Paediatr Dent* 2020; 21(2):157–162.
49. Quinzi V, Saccomanno S, Manenti RJ, Giancaspro S, Coceani L, Marzo G. Efficacy of rapid maxillary expansion with or without previous adenotonsillectomy for pediatric obstructive sleep apnea syndrome based on polysomnographic data:

- A systematic review and meta-analysis. *Appl Sci (Switzerland)* 2020; 10(18):6485.
50. Mummolo S, Mancini L, Quinzi V, D'Aquino R, Marzo G, Marchetti E. Rigenera® autologous micrografts in oral regeneration: Clinical, histological, and radiographical evaluations. *Appl Sci (Switzerland)* 2020; 10(15):5084.
 51. Quinzi V, Tecco S, Nota A, Mummolo S, Marzo G. Mesial rotation of the upper first molar: Association with anterior dental crowding in mixed and permanent dentition. *Appl Sci (Switzerland)* 2020; 10(15):5301.
 52. Quinzi V, Salvatorelli C, Panetta G, Rizzo FA, Mummolo S. Autotransplantation of immature third molars as substitutes for congenitally missing second premolars: An alternative solution in a young patient with oligodontia. *J Biol Regul Homeost Agents* 2020; 34(3):155–163.
 53. Daniele V, Macera L, Taglieri G, et al. Thermoplastic disks used for commercial orthodontic aligners: Complete physicochemical and mechanical characterization. *Materials (Basel)* 2020; 13(10):2386.
 54. Marchetti E, Mancini L, Bernardi S, et al. Evaluation of different autologous platelet concentrate biomaterials: Morphological and biological comparisons and considerations. *Materials (Basel)* 2020; 13(10):2282.
 55. Giuca MR, Pasini M, Pacini M, Carli E, Lardani L, Ferro R. Use of extra-oral scanner for the study of arch form in a sample of Italian adolescents with ideal occlusion. *J Biol Regul Homeost Agents* 2020; 34(3 Suppl. 1):107-116.
 56. Nastasio S, Sciveres M, Maggiore G. The Best Choice for Second-line Agent in Standard Treatment-refractory Children with Autoimmune Hepatitis. *J Pediatr Gastroenterol Nutr* 2018; 66(3):e86-e87.
 57. Quinzi V, Ferro R, Rizzo FA, et al. The Two by Four appliance: A nationwide cross-sectional survey. *Eur J Paediatr Dent* 2018, 19(2):145–150.
 58. Arreghini A, Trigila S, Lombardo L, Siciliani G. Objective assessment of compliance with intra- and extraoral removable appliances. *Angle Orthod* 2017 Jan;87(1):88-95.
 59. Perrini, F., Lombardo, L., Arreghini, A., Medori, S., Siciliani, G. Caries prevention during orthodontic treatment: In-vivo assessment of high-fluoride varnish to prevent white spot lesions. *Am J Orthod Dentofacial Orthop* 2016;149(2):238-43.
 60. Manfredini, D., Stellini, E., Gracco, A., Lombardo, L., Nardini, L.G., Siciliani, G. Orthodontics is temporomandibular disorder-neutral. *Angle Orthod* 2016;86(4):649-54.
 61. Lombardo L, Carinci F, Martini M, Gemmati D, Nardone M, Siciliani G. Quantitative evaluation of dentin sialoprotein (DSP) using microbeads - a potential early marker of root resorption. *Oral Implantol (Rome)* 2016;9(3):132-142.
 62. Pisani L, Bonaccorso L, Fastuca R, Spena R, Lombardo L, Caprioglio A. Systematic review for orthodontic and orthopedic treatments for anterior open bite in the mixed dentition. *Prog Orthod* 2016;17(1):28.
 63. Lombardo L, Toni G, Stefanoni F, Mollica F, Guarneri MP, Siciliani G. The effect of temperature on the mechanical behavior of nickel-titanium orthodontic initial archwires. *Angle Orthod* 2013;83(2):298-305.