





Cite this article as: Trabalza Marinucci B, Maurizi G, Vanni C, Cardillo G, Poggi C, Pardi V *et al.* Surgical treatment of pulmonary sequestration in adults and children: long-term results. *Interact CardioVasc Thorac Surg* 2020;31:71–7.

Surgical treatment of pulmonary sequestration in adults and children: long-term results

Beatrice Trabalza Marinucci ^a, Giulio Maurizi^{a,*}, Camilla Vanni^a, Giuseppe Cardillo^b, Camilla Poggi ^c,
Valerio Pardi ^d, Alessandro Inserra ^d and Erino A. Rendina^a

^a Department of Thoracic Surgery, Sant'Andrea Hospital, Sapienza University, Rome, Italy

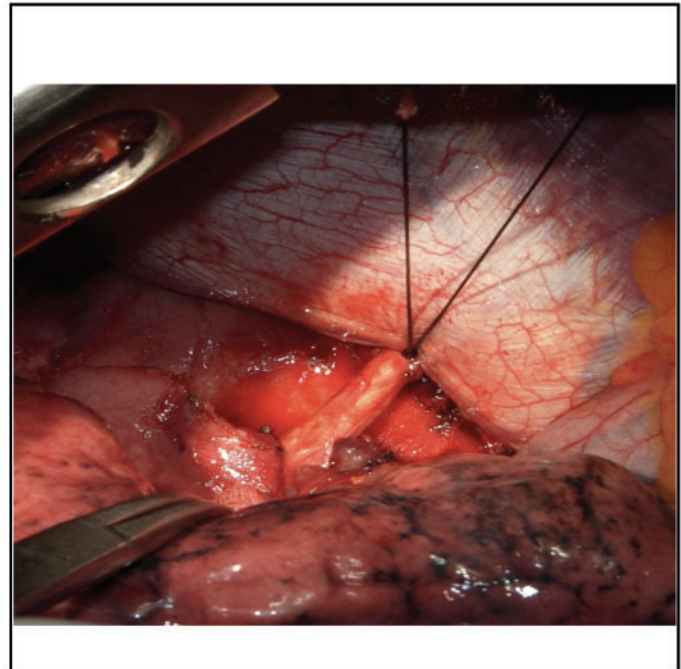
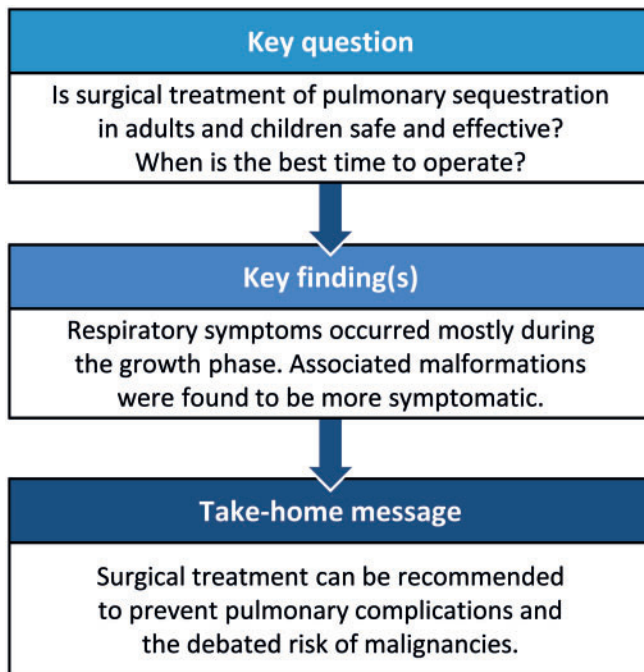
^b Department of Thoracic Surgery, San Camillo Forlanini Hospital, Rome, Italy

^c Department of Thoracic Surgery, Policlinico Umberto I, Sapienza University, Rome, Italy

^d Department of General and Thoracic Surgery, Bambino Gesù Children's Research Hospital IRCCS, Rome, Italy

* Corresponding author. Department Thoracic Surgery, Sant'Andrea Hospital, Sapienza University, Via di Grottarossa 1035, 00189 Rome, Italy. Tel: +39-6-33775773; fax: +39-6-33775578; e-mail: giulio.maurizi@uniroma1.it (G. Maurizi).

Received 23 September 2019; received in revised form 11 January 2020; accepted 30 January 2020



Abstract

OBJECTIVES: Few experiences comparing paediatric and adult patients treated for pulmonary sequestration (PS) have been reported. Surgical treatment is considered the best choice, but the time of surgery is still controversial. We present our experience in this setting, comparing characteristics, histological results and outcome of paediatric and adult patients undergoing PS resection.

METHODS: Between 1998 and 2017, a total of 74 patients underwent lobectomy or sublobar resection for PS. Sixty patients were children (group A: ≤16 years old) and 14 were adults (group B: >16 years old). Preoperative diagnosis was radiological. PS was intralobar (42 cases) and extralobar (32 cases). The operation was a muscle-sparing lateral thoracotomy or video-assisted thoracoscopic surgery. Preoperative characteristics, histological results and short-/long-term results of the 2 groups were retrospectively analysed and compared.

RESULTS: Thirty-seven percent of the patients in group A presented with respiratory symptoms and 79% in group B ($P=0.44$). Most symptomatic patients were treated with a lobectomy. In group A, 2 patients (3%) had a malignant transformation of the lesion. Patients with a prenatal diagnosis treated after the age of 1 year became more symptomatic than those operated on before the age of 1 year (57% vs 23%; $P=0.08$). No differences were found in postoperative complications. Long-term stable remission of respiratory symptoms was obtained in 91% of patients in group A and 100% in group B. Adulthood ($P=0.03$) and the association with congenital cystic adenomatoid malformation ($P=0.03$) were negative prognostic factors for the development of respiratory symptoms.

CONCLUSIONS: Surgical treatment of PS is safe and feasible. Despite the small number of patients included, study results indicated that an early operation during childhood may prevent the subsequent development of respiratory symptoms. Surgical treatment is also recommended to prevent the rare transformation into malignancy.

Keywords: Pulmonary sequestration • Lung surgery • Paediatric surgery

ABBREVIATIONS

BOOP	Bronchiolitis obliterans organizing pneumonia
CCAM	Congenital cystic adenomatoid malformation
CPM	Congenital pulmonary malformation
CT	Computed tomography
EL-PS	Extralobar pulmonary sequestration
IL-PS	Intralobar pulmonary sequestration
PPB	Pleuropulmonary blastoma
PS	Pulmonary sequestration
VATS	Video-assisted thoracoscopic surgery

INTRODUCTION

Congenital pulmonary malformations (CPMs) comprise a wide spectrum of lesions originating from an abnormal pulmonary development during embryogenesis. In the last decades, the extensive use of prenatal ultrasonography has led to a progressive increase in the prenatal identification of CPMs. Clinical presentation and gravity depend on the size and localization of the lesion [1]. Pulmonary sequestration (PS) represents 0.15–6.45% of CPMs, with an incidence of 1/20 000 in the general population; it is characterized by a mass of non-functioning lung tissue separated from the normal tracheobronchial tree, and it receives its vascular supply from a systemic artery [2, 3]. It is classified as intralobar PS (IL-PS) when it is incorporated in the parenchyma of a lobe, and as extralobar PS (EL-PS) when it is separated from the adjacent normal parenchyma by its own pleural envelope [4]. IL-PS is generally localized in the left lower lobe, and it presents with bronchioles lined up by a preserved ciliated pseudostratified epithelium with inflammatory lymphoplasmic cellular infiltration [5, 6]. EL-PS is frequently localized adjacent to the mediastinum or the diaphragm. It is characterized by bronchiectasis containing areas of bronchiolitis obliterans organizing pneumonia (BOOP). In nearly 25% of cases, PS presents in association with another congenital malformation, the congenital cystic adenomatoid malformation (CCAM), which represents 25% of all CPMs [6]. It is considered a hamartomatous cystic lesion of the lung and is grouped into 3 types based on its appearance: cystic, intermediate and solid. Stocker later renamed them types 1–3 and then added type 0 and type 4, based on the tissue's origin. Type 0, the rarest, is a small cyst arising from tracheal or bronchial tissue; type 4 is a large cyst of about 10 cm arising from alveolar tissue [7]. This enlarged spectrum represented 5 successive groups of the airway malformations [8]. PS is most frequently associated with type 2 [9]. Rare cases of CCAM show malignant

transformation: malignancies are mainly pleuropulmonary blastomas (PPBs) in infants and young children and bronchoalveolar carcinomas in older children and adults. A bronchoalveolar carcinoma usually develops within a type 1 lesion: the predisposition to malignancy could reflect, in part, an inherited instability in the alveolar tissue adjacent to the congenital cysts. In fact, it has been suggested that the cysts might also serve as a vehicle for the retention and persistence of unstable mesenchymal cells. The most frequent mesenchymal tumour associated with CPMs is the PPB [10]. Although this tumour is rare, Hartman and Stochat reported a series of 230 cases of primary lung tumours in children, 4% of which were considered to arise from the transformation of the CCAM [8, 11]. Later, Ozcan *et al.* [12] reported 33 cases of primary rhabdomyosarcoma, 15 of which arose in a pre-existing CPM. Recently, Nasr *et al.* [13] found a 2% association between PPB and CPMs. Finally, a review by Casagrande and Pederiva [11] highlighted 168 cases (76 children and 92 adults) in which a lung tumour was associated with a CPM. Considering these experiences, the association between tumour and lung malformations does not seem to be a coincidental event. This is one of the reasons why treatment is still controversial. Some authors suggest a conservative approach until clinical manifestations occur, not considering the possibility of malignant transformation, whereas others advise preventive surgical excision to avoid both symptomatic complications and malignancy [14]. Surgery is considered an effective strategy to treat symptomatic lesions [3, 15]. Some published studies report low rates of postoperative mortality and morbidity and good long-term results after surgery [3, 14, 16]. The aim of our study was to confirm the safety and feasibility of surgical treatment and to clarify the best time to operate, considering all the differences among patients of different ages.

MATERIALS AND METHODS

Our multi-institutional retrospective study included 74 patients affected by PS and treated surgically in 3 centres in Rome, Italy (Sapienza University; Bambino Gesù Children's Research Hospital; San Camillo Forlanini Hospital) between 1998 and 2017.

Patients were divided in 2 groups: paediatric patients (0–16 years), group A ($n=60$) and adult patients (>16 years), group B ($n=14$). Diagnosis was radiological for all patients using computed tomography (CT) scans with contrast medium. In group A, most of the lesions were detected prenatally using ultrasonography during the second trimester of pregnancy and confirmed by CT scans performed during the first 3 months after birth. In group B, PS was detected by radiography, then confirmed by CT scans.

Table 1: Characteristics of the entire population

Variables	Group A (n = 60)	Group B (n = 14)	P-value
Sex, n (%)			0.7732
Male	27 (45)	7 (50)	
Female	33 (55)	7 (50)	
Age (years), mean ± SD/range	2 ± 3.35/0.1–15	46.6 ± 14.65/22–72	0.0001
Prenatal diagnosis, n (%)	46 (76.6)	0	0.0001
Clinical presentation, n (%)			0.0045
Symptomatic	22 (36.7)	11 (78.6)	
Asymptomatic	38 (63.3)	3 (21.24)	
Type of resection, n (%)			0.2250
Lobectomy	35 (58.3)	11 (78.6)	
Sublobar resection	25 (41.7)	3 (21.4)	
Surgical approach, n (%)			0.7020
Thoracotomy	50 (83.3)	11 (78.6)	
VATS	10 (16.7)	3 (21.4)	
Type of sequestration, n (%)			0.5663
IL-PS	33 (55)	9 (64.3)	
EL-PS	27 (45)	5 (35.7)	
Histological diagnosis, n (%)			0.7581
PS	38 (63.3)	10 (71.4)	
PS + CCAM	22 (36.7)	4 (28.6)	
Malignant transformation, n (%)	2 (3.34)	0 (0)	1
Hospital stay (days), mean ± SD/range	7.9 ± 1.83/5–15	7.07 ± 1.97/5–12	0.1536
Deaths within 30–90 days, n (%)	0	0	NR
Postoperative complications, n (%)	4 (6.7)	2 (14)	0.1705
Symptom remission, n (%)	20/22 (91)	11/11 (100)	0.5417
Follow-up period (years), mean ± SD/range	9.5 ± 0.7/1–20	7.1 ± 1.4/0.5–14	0.1489

CCAM: congenital cystic adenomatoid malformation; EL: extralobar; IL: intralobar; PS: pulmonary sequestration; SD: standard deviation; VATS: video-assisted thoracoscopic surgery.

PS was IL (IL-PS) in 42 cases and EL (EL-PS) in 32. Preoperative assessment in both groups included evaluation of pulmonary function by spirometry and evaluation of cardiovascular status by electrocardiography and echocardiography when required. In children under 5 years old, the infant pulmonary function test was used. It consisted of rapid thoracic compression and plethysmography combined: a vest was placed around the thoracic cage of the baby and a mask was placed over the baby's nose and mouth, then connected to a computerized pneumography system. The patient was sedated, and the pneumatic vest was inflated, compressing the thorax. Air flowed to the baby through the mask. The combination with plethysmography allows the determination of fractional lung volumes [17–19]. All patients underwent an operation: lobectomy or sublobar resection (segmentectomy or wedge resection) depending on the localization and the size of the sequestration [20, 21]. An accurate histopathological analysis was done to verify associated CPMs or signs of malignancy. Treated patients underwent a follow-up examination based on clinical and radiological evaluations and spirometry at 3 and 6 months postoperatively. Radiographic examinations were required after a month and after a year. Demographic characteristics, preoperative diagnosis, symptoms, type of resection, histological diagnosis and associated CPMs, length of hospital stays and outcomes were analysed and compared between the 2 groups. Postoperative complications were defined based on descriptions from the literature, considering nerve damage and neuropathic pain, loss of muscle strength and scoliosis. In group A, the characteristics and outcomes of patients with a prenatal diagnosis treated up to 1 year of age were compared with those operated on after 1 year of age. The study was approved by the institutional review board, and informed consent was obtained

before the operation. The major limitation is the small number of cases observed.

Statistical analyses

Data are presented as mean ± standard deviation. Discrete variables were compared using the Fisher's exact test, and continuous variables were analysed using the *t*-test; a *P*-value <0.05 was accepted as significant. A univariable analysis, using logistic regression, was applied to identify a correlation among independent variables and a multivariable analysis was applied to confirm the correlation. The data were analysed using the statistical package SPSS, version 25.0 (SPSS Software, IBM Corp., Armonk, NY, USA).

RESULTS

The average age was 2 ± 3.35 years (range 0–15) in group A and 46.6 ± 14.65 years (range 22–72) in group B. In group A, 27 patients (45%) were boys and 33 (55%) were girls, whereas in group B, there were 7 men (50%) and 7 women (50%). All patient characteristics are illustrated in Table 1.

In group A, PS was right sided in 11 cases (18.3%) and left sided in 49 patients (81.7%) versus 6 right lesions (42.8%) and 8 left lesions (57.2%) in group B.

In group A, the diagnosis of PS was made prenatally in 46 patients (76.6%); in 9 cases (15%), PS was proven after the occurrence of respiratory symptoms; in the last 5 patients (8.4%), PS was an incidental finding. In group B, PS was an incidental finding in 3 patients (21.4%), whereas it was proven after the occurrence of respiratory symptoms in 11 cases (78.6%).

Table 2: Respiratory symptoms

Symptoms	Group A (symptomatic patients, <i>n</i> = 22), <i>n</i> (%)	Group B (symptomatic patients, <i>n</i> = 11), <i>n</i> (%)	<i>P</i> -value
Pneumonia	9 (41)	6 (54)	0.458
Recurrent bronchitis	10 (45)	6 (54)	0.622
Bronchiolites	9 (41)	5 (45)	0.803
Severe cough	6 (27)	5 (45)	0.296
Haemoptysis	2 (9)	6 (54)	0.004
Dyspnoea	8 (36)	4 (36)	1
Pneumothorax	1 (4)	0	
Respiratory distress	4 (18)	0	

At the time of surgery, 22 (36.7%) patients in group A versus 11 (78.6%) in group B presented with symptoms related to the PS, so group B was considered the most symptomatic ($P=0.004$). The symptoms are illustrated in Table 2; haemoptysis was considered the most statistically significant symptom in group B.

In group A, 35 patients had a lobectomy (59%) and 25 (42%) had a sublobar resection; lobectomy was performed in 11 cases (79%) in group B. Of all the patients presenting with symptoms, 20 (91%) had a lobectomy in group A and 10 (90%), in group B (Fig. 1).

PS was IL (IL-PS) in 33 patients (55%) and EL (EL-PS) in 27 (45%) in group A, whereas PS was IL in 9 (64.3%) and EL in 5 cases (35.7%) in group B ($P=0.5$). Twenty-two cases (36.7%) were associated with CCAM [EL-PS in 18 (81.8%) and IL-PS in 4 (18.2%)] in group A, and 4 cases (28.6%) were associated with CCAM [EL-PS in 3 (75%) and IL-PS in only 1 (25%)] in group B ($P=0.7$).

Considering the entire study population, isolated PS were characterized by lymphoplasmic cellular inflammatory infiltration associated with pulmonary fibrosis, bronchiectasis and areas of preserved ciliated pseudostratified epithelium. Otherwise, PS associated with CCAM presented BOOP inflammatory infiltration associated with fibrosis and back-to-back cysts (Fig. 2A and B).

Acute inflammatory infiltration was evidenced in lesions of patients who presented with respiratory symptoms: 32% presented with epithelium dysplasia ($P=0.0009$); 40% presented with BOOP ($P=0.0001$); 16% presented with goblet cell hyperplasia ($P=0.02$).

Twenty-three cases of epithelium dysplasia (48%) were found in PS versus 18 cases (69%) in PS and CCAM. Dysplasia comprised 10 cases of goblet cell hyperplasia (21%) and 21 cases of BOOP (44%) in PS versus 8 cases of goblet cell hyperplasia (44%) and 15 BOOP (83%) in PS and CCAM. Two paediatric patients with associated lesions (PS and CCAM) (8%) showed malignant transformation in PPB. Both of these patients had prenatal diagnoses and were operated on after they were 1 year old ($P=0.02$).

The 30- and 90-day mortality rates were both 0%. Postoperative (short- and mid-term) complications including air leak, haemorrhage, pulmonary atelectasis and intercostal nerve damage (a consequence of the surgical approach, which causes chronic neuropathic pain) were noted in 2 adult (14%) and in 4 paediatric patients (6.7%) at the follow-up examination. Group A had a mean of 7.9 ± 1.83 days of hospitalization, whereas group B had a mean of 7.07 ± 1.97 days. Symptom remission after surgical treatment was seen in 20 of the 22 group A patients who were

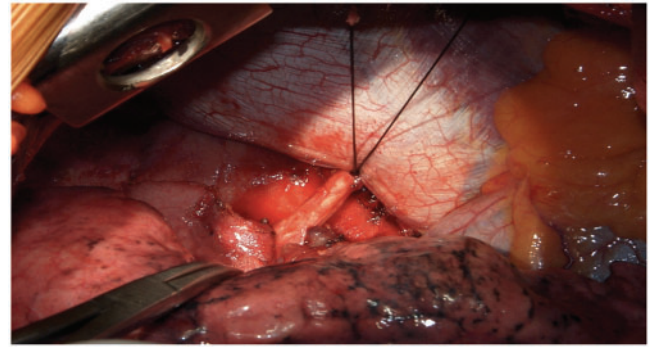


Figure 1: Intraoperative picture showing the resection of an anomalous systemic artery during a lobectomy for intralobar pulmonary sequestration.

symptomatic before surgery (91%) and in all of the group B patients who were symptomatic before surgery. The rate of relapse of symptoms was 5% all in paediatric patients.

When we considered patients who received prenatal diagnoses ($n=46$) (Table 3), we found that those treated after 1 year of age had developed more symptoms at the time of surgery than those operated on before 1 year of age (57% vs 23%; $P=0.08$). Lobectomy was required in 19 babies operated on before 1 year of age (49%) and 5 were operated on after 1 year of age (71%).

A univariable analysis was used to verify which of the following independent variables could determine the occurrence of respiratory symptoms: age, type of PS, sex or association with CPM. Significant correlation was found between the occurrence of respiratory symptoms and age ($P=0.03$) and between the occurrence of respiratory symptoms and associated anomalies ($P=0.04$). These correlations seem to describe the more frequent occurrence of symptoms in adult patients and in patients presenting with PS associated with CCAM. Multivariable analysis confirmed that age and association with CPM could be considered negative independent prognostic factors for the occurrence of respiratory symptoms ($P=0.01$; both) (Table 4). Linear regression (Table 5) analysis indicated that neither sex, age, side, nor type of resection was a significant predictor of symptom relapse at the follow-up examination (9.5 ± 0.7 in group A and 7.1 ± 1.4 in group B). IL-PS could be described as the most protective factor, even though it was not significant ($P=0.16$).

DISCUSSION

Even though a study published by Van Raemdonck *et al.* [3] focused on the comparison between paediatric and adult patients treated for PS and despite the limitations associated with the small sample, our study is one of the largest comparing paediatric and adult patients. In fact, we analysed several series: 35 cases from Hôpital Foch in Paris published in 1970 [22], 27 cases from a Canadian study published in 1985 [23] and finally a review of 26 cases published in 1998 [24].

Our results, based on 74 surgically treated patients (60 children and 14 adults), are in line with those reported in the published articles that recommend the need for surgical treatment to guarantee the remission of respiratory symptoms or to prevent their manifestation [3, 6, 15, 25]. The available evidence suggests that only 5% will become symptomatic in the first 5 years, at a median age of 7 months, and that the others tend to develop symptoms in adulthood [14].

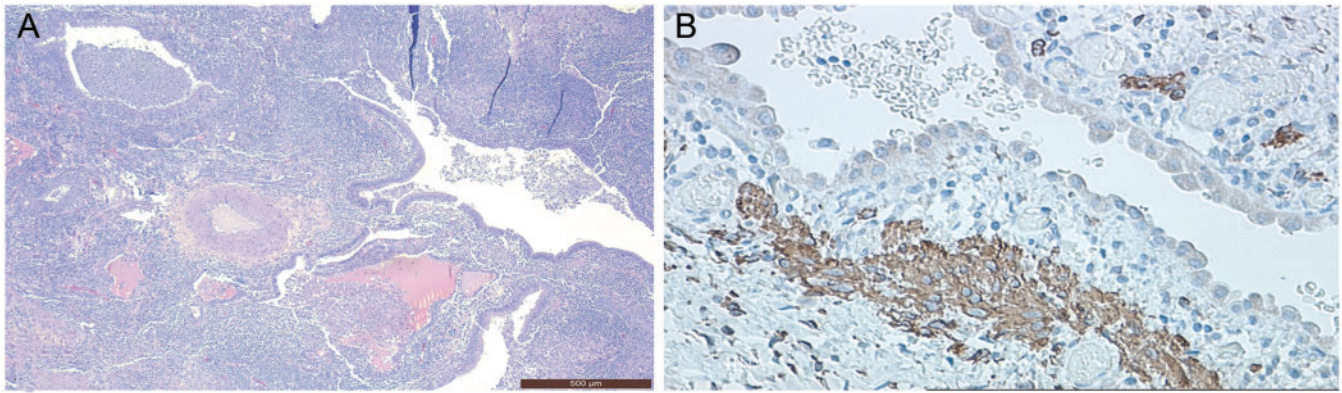


Figure 2: Histopathological patterns. **(A)** Sequestration + congenital cystic adenomatoid malformation: back-to-back cysts, hyperplastic arteriole and bronchiolitis or organizing pneumonia. **(B)** Malignant transformation: proliferation of rhabdomyoblasts (evidenced by desmin + colouration) under the cyst walls.

In our experience, PS was detected because of the occurrence of related respiratory symptoms in adults, whereas the paediatric patients most frequently were diagnosed prenatally. Among the paediatric patients, those operated on after 1 year of age developed more respiratory symptoms than those treated before 1 year of age.

Our results showed that in both groups, among all the variables, only age and associated CPMs (PS and CCAM) were significantly related to the occurrence of respiratory symptoms.

In both groups, the surgical excision of the lesion was done via a lobectomy more frequently than by sublobar resection. According to the data in the literature, the dimensions of the lesion and the large amount of fibrotic tissue caused by chronic inflammation are correlated with the necessity of a more destructive treatment. Lobectomy is recommended to prevent residual disease and some later malignancies whereas lung-sparing surgery such as segmentectomy is indicated for small, defined or bilateral lesions. If CPMs are not contained in a defined anatomical segment, a wedge resection could be performed, considering that parts of the affected lobe could be healthy and have normal arterial inflow [20, 21].

Open surgical access was preferred in both groups. Thoracotomy allows easy access to hilar structures using different intercostal spaces, making it easier than video-assisted thoracoscopic surgery (VATS) to manage the anomalous vascularization and the variable sizes of the lesions. The main difficulty during resection is the identification of the aberrant artery, which may be thickened or more fragile and is often hidden by anatomical inflammatory changes caused by recurrent infections. Dense adhesions can make VATS dissection difficult, and proliferative inflammatory vessels can render the surgical field bloody and blurred [21]. VATS is considered the best choice in selected cases of simple sequestration without hilum adhesions or anatomical changes, but access via a thoracotomy is sometimes required to better manage an eventual vessel injury when the aberrant or varicose bronchial arteries are not well defined by preoperative imaging [20]. In our series, some patients were treated by VATS during the last observation period, which is why the number of patients is small: 10 (16.7%) in group A versus 3 (21.4%) in group B. Because of the limitations caused by the small number of patients, no differences in outcome were found in comparison with the open access approach. In children, the usefulness of VATS was limited because we were unable to use the instruments in patients weighing <10 kg because of the limited size of their

Table 3: Patients with prenatal diagnosis operated on up to or after the age of 1 year

Variables	Operation ≤ age 1(39; 85%)	Operation > age 1(7; 15%)	P-value
Age (years), mean ± SD	0.4 ± 0.2	3.1 ± 3.7	
Sex, n (%)			0.7752
Male	20 (51)	4 (57)	
Female	19 (49)	3 (43)	
Clinical presentation, n (%)			0.0867
Symptomatic	9 (23)	4 (57)	
Asymptomatic	30 (77)	3 (43)	
Type of resection, n (%)			0.4177
Lobectomy	19 (49)	5 (71)	
Sublobar resection	20 (51)	2 (29)	
Type of sequestration, n (%)			0.4177
IL-PS	19 (49)	5 (71)	
EL-PS	20 (51)	2 (29)	
Side, n (%)			0.0782
Right	16 (41)	0 (0)	
Left	23 (59)	7 (100)	
Histology, n (%)			0.6667
PS	27 (69)	4 (57)	
PS + CCAM	12 (31)	3 (43)	
Malignant transformation, n (%)	0	2 (29)	0.0203
Hospital stay (days), mean ± SD	7.9 ± 1.99	7.7 ± 1.8	0.6935
Death within 30–90 days, n (%)	0	0	NR
Postoperative complications, n (%)	9 (23)	1 (14)	1

CCAM: congenital cystic adenomatoid malformation; EL: extralobar; IL: intralobar; NR: natural region; PS: pulmonary sequestration; SD: standard deviation.

thoracic cavity and the difficulty of working with a 12-mm trocar. Currently, the development of high-resolution digital cameras, smaller instruments and better optics has enabled us to perform complex dissections thoracoscopically. During the years of follow-up, most of our treated patients reported the total absence of respiratory symptoms, such as haemoptysis, infections, cough, recurrent pneumonias or respiratory distress, confirming the effectiveness of the treatment. Thoracotomy access permits muscle-sparing surgery, which prevents massive parietal tissue destruction and the following long-term complications such as scoliosis or loss of muscle strength.

We tried to determine the best time for surgery. When we compared mortality rates, postoperative complications, length of hospital stays and outcomes between the 2 groups, we did not

Table 4: Univariable and multivariable analyses of the development of respiratory symptoms

Variables	Univariable			Multivariable		
	OR	P-value	95% CI	OR	P-value	95% CI
Age (years) (<16 vs >16)	1.025	0.030	1.002–1.047	1.030	0.010	1.007–1.054
Sex (male versus female)	0.826	0.655	0.357–1.911			
Side (left versus right)	0.926	0.868	0.377–2.276			
Type of PS (IL-PS versus EL-PS)	1.570	0.315	0.652–3.780			
Associated CPMs (PS versus PS + CCAM)	0.358	0.035	0.138–0.929	0.271	0.011	0.100–0.740

CCAM: congenital cystic adenomatoid malformation; CI: confidence interval; CPMs: congenital pulmonary malformations; EL: extralobar; IL: intralobar; OR: odds ratio; PS: pulmonary sequestration.

Table 5: Univariable analysis of respiratory symptom relapse after surgery

Variables	OR	P-value	95% CI
Age (years) (<16 vs >16)	-2.209	0.155	1.554–1.442
Sex (male versus female)	0.888	0.498	1.309–0.678
Side (left versus right)	0.555	0.315	0.652–3.780
Type of PS (IL-PS versus EL-PS)	-1.876	0.159	0.138–0.929
Type of resection (lobectomy versus sublobar resection)	1.501	0.271	1.100–1.364

CI: confidence interval; EL: extralobar; IL: intralobar; OR: odds ratio; PS: pulmonary sequestration.

find any significant differences. Therefore, we may assume that surgical treatment during adulthood requires a larger parenchymal resection due to the frequent development in this group of recurrent and chronic respiratory inflammation. We can hypothesize that sparing the parenchyma could be achieved in early treatment during childhood. For babies operated on before the age of 1 year, a less extensive resection was possible, because no inflammatory complications occurred at this time. At the median follow-up, nearly 10% of this group presented with respiratory complications such as asthma, bronchitis and respiratory distress. These complications may be due to a change in the tracheobronchial tree caused by compensatory lung growth after resection. A previous study from Calzolari *et al.* suggested instead that these symptoms were probably related to the congenital developmental abnormality that causes CPMs. In fact, lesions may not be limited to a single lung segment, but the whole respiratory structure may be affected to differing degrees, which may result in persistent respiratory symptoms after excision of the lesion that tend to regress with age [14]. Therefore, surgery alone does not seem to be responsible for pulmonary complications in children who are operated on. A minority of other long-time complications reported in both groups, such as scoliosis or neuropathic pain, do not allow determination of whether they are correlated with the time of surgery or if they are just coincidental. Further studies on this matter are required in a larger and more homogeneous population and with a longer follow-up period.

Histological examination of excised lesions revealed the presence of associated CPMs (PS and CCAM) in 36.7% of paediatric patients and in 28.6% of adult patients. Various studies report histological characteristics of CCAM in 50% of EL-PS and in 15% of IL-PS. These 'back-to-back' cysts are surrounded by mesenchymal stroma with foci of goblet cell hyperplasia or immature smooth-muscle cells [9, 26, 27]. Histological differences between the 2

groups of patients were not apparent, but we noted the presence of foci of atypical goblet cell hyperplasia under the walls of the cysts in some of the associated CPMs. Considering that CCAM type 1 presented focal atypical goblet cell hyperplasia in ~33% of cases described in literature, it has recently been thought to be a possible precursor to adenocarcinoma because it exhibits the same chromosomal aberrations. For this reason, atypical goblet cell hyperplasia is considered a precancerous lesion [8, 11]. In contrast, CCAM type 4 shows significant morphological overlap with type I PPB: both are characterized by air-filled cysts with primitive mesenchymal cells beneath an intact, benign-appearing epithelium [11]. In our experience, 2 paediatric cases, detected prenatally and not treated within the first year of life, showed malignant transformation to PPB, evidenced by blastomatous cells and mesenchymal cells in a myxoid stroma, increased expression of vimentin, alpha 1 antitrypsin, actin and desmin. These sporadic cases are not sufficient to hypothesize congenital lesion malignancy, even though our hypothesis is supported by the International Pleuropulmonary Blastoma Registry, which reports that 66% of PPB are detected in association with lung cysts. According to the International Pleuropulmonary Blastoma Registry, a lung cyst can evolve into solid PPB at any time between 12 and 72 months of age [28]. Whether PPB causes cysts or arises in pre-existing cysts is still under debate. It is difficult to determine if a congenital cyst developed into a PPB or was an unrecognized PPB from the beginning. Further studies are required.

The concomitant presence of PS and CCAM that we reported seemed to increase the occurrence of respiratory symptoms before treatment. According to the literature, the 2 associated CPMs (PS and CCAM) have similar clinical and radiological characteristics, so it could be difficult to detect a CCAM in the context of a PS. Considering these similarities, surgical resection can also be recommended as a straightforward way to obtain a final diagnosis of the lesion in order to distinguish isolated lesions from associated CPMs. According to the literature, an associated lesion (PS and CCAM) that is not resected might represent an increased risk for the development of respiratory symptoms and a risk factor for the rare possibility of malignant transformation. In fact, previous reviews reported that malignancy may occur at any age without a definitive pattern of association between the tumour and the CPM type [11, 27, 29].

CONCLUSIONS

In conclusion, within the limitations posed by a retrospective study and the brief follow-up period, we could affirm that

surgical excision is a safe and feasible treatment for PS. We suggest that the operation be performed soon after the diagnosis, considering that the symptoms occur more frequently over time, and a wider parenchymal resection could be required. Continuous infections can lead to anatomical inflammatory changes that can cause technical difficulties during dissection. Early surgery in childhood might allow the parenchyma to be spared due to fewer inflammatory complications and to regeneration based on the persistence of alveologenesis for some months after birth. Data arising from the present study suggest surgical treatment not only for the remission and the prevention of respiratory symptoms related to the lesion, but also for a final diagnosis of the lesion, with the goal to prevent the debated risk of cancerogenesis. Further studies including more patients and a randomized trial are required to support our results.

ACKNOWLEDGEMENTS

The authors thank Marta Silvi for data management.

Conflict of interest: none declared.

Author contributions

Beatrice Trabalza Marinucci: Data curation; Formal analysis; Investigation; Writing—original draft. **Giulio Maurizi:** Conceptualization; Data curation; Methodology; Supervision; Writing—original draft. **Camilla Vanni:** Data curation; Formal analysis; Writing—original draft. **Giuseppe Cardillo:** Data curation. **Camilla Poggi:** Data curation; Investigation. **Valerio Pardi:** Data curation; Formal analysis. **Alessandro Inserra:** Conceptualization; Data curation. **Erino A. Rendina:** Conceptualization; Supervision; Visualization.

REFERENCES

- Stanton M. The argument for a non-operative approach to asymptomatic lung lesions. *Semin Pediatr Surg* 2015;24:183–6.
- Savic B, Birtel FJ, Tholen W, Funke HD, Knoche R. Lung sequestration: report of seven cases and review of 540 published cases. *Thorax* 1979;34:96–101.
- Van Raemdonck D, De Boeck K, Devlieger H, Demedts M, Moerman P, Coosemans W *et al.* Pulmonary sequestration: a comparison between pediatric and adult patients. *Eur J Cardiothorac Surg* 2001;19:388–95.
- Gezer S, Taştepe İ, Sirmalı M, Findik G, Türüt H, Kaya S *et al.* Pulmonary sequestration: a single-institutional series composed of 27 cases. *J Thorac Cardiovasc Surg* 2007;133:955–9.
- Pryce DM. Lower accessory pulmonary artery with intralobar sequestration of lung: a report of seven cases. *J Pathol Bacteriol* 1946;58:457–67.
- Conran RM, Stocker JT. Extralobar sequestration with frequently associated congenital cystic adenomatoid malformation, type 2: report of 50 cases. *Pediatr Dev Pathol* 1999;2:454–63.
- Andrade CF, Ferreira H, Fischer GB. Congenital lung malformations. *J Bras Pneumol* 2011;37:259–71.
- Stacher E, Ullmann R, Halbwedl I, Kammerer GM, Boccon GL, Nicholson A *et al.* Atypical goblet cell hyperplasia in congenital cystic adenomatoid malformation as a possible preneoplasia for pulmonary adenocarcinoma in childhood: a genetic analysis. *Hum Pathol* 2004;35:565–70.
- Sfakianaki AK, Copel JA. Congenital cystic lesions of the lung: congenital cystic adenomatoid malformation and bronchopulmonary sequestration. *Rev Obstet Gynecol* 2012;5:85–93.
- Hartman GE, Shochat SJ. Primary pulmonary neoplasms of childhood: a review. *Ann Thorac Surg* 1983;36:108–19.
- Casagrande A, Pederiva F. Association between congenital lung malformations and lung tumors in children and adults: a systematic review. *J Thorac Oncol* 2016;11:1837–45.
- Ozcan C, Celik A, Ural Z, Veral A, Kandiloğlu G, Balik E. Primary pulmonary rhabdomyosarcoma arising within cystic adenomatoid malformation: a case report and review of the literature. *J Pediatr Surg* 2001;36:1062–5.
- Nasr A, Himidan S, Pastor AC, Taylor G, Kim P. Is congenital cystic adenomatoid malformation a premalignant lesion for pleuropulmonary blastoma? *J Pediatric Surg* 2010;80:1086–9.
- Calzolari F, Braguglia A, Valfrè L, Dotta A, Bagolan P, Morini F. Outcome of infants operated on for congenital pulmonary malformations. *Pediatr Pulmonol* 2016;51:1367–72.
- Corbett HJ, Humphrey GME. Pulmonary sequestration. *Paediatr Respir Rev* 2004;5:59–68.
- Rashmi S, Davenport M. The argument for operative approach to asymptomatic lung lesions. *Semin Pediatr Surg* 2015;24:187–95.
- Lesnick BL, Davis SD. Infant pulmonary function testing. Overview of technology and practical considerations—new current procedural terminology codes effective 2010. *Chest* 2011;139:1197–202.
- Mohtasham L, Panitch HB. Current approaches in infant pulmonary testing. *Curr Pediatr Rep* 2014;2:9–17.
- Dotta A, Palamides S, Braguglia A, Crescenzi F, Ronchetti MP, Calzolari F *et al.* Lung volumes and distribution of ventilation in survivors to congenital diaphragmatic hernia (CDH) during infancy. *Pediatr Pulmonol* 2007;42:600–4.
- Wang LM, Cao JL, Hu J. Video-assisted thoracic surgery for pulmonary sequestration: a safe alternative procedure. *J Thorac Dis* 2016;8:31–6.
- Chengwu L, Pu Q, Ma L. Video-assisted thoracic surgery for pulmonary sequestration compared with posterolateral thoracotomy. *J Thorac Cardiovasc Surg* 2013;146:557–61.
- Accard JL, Toty L, Personne CL, Hertzog P. Etude d'une série de 35 séquestrations avec référence aux formes particulières. *Ann Chir Thorac Cardiovasc* 1970;9:501–10.
- Begin P, Lamarre A, Blanchette G. Pulmonary sequestration: a retrospective study of 27 cases in pediatric and hospital centers questioning surgery as an immediate therapeutic approach. *Union Med Can* 1985;114:301–7.
- Halkic N, Cuénoud PF, Corthésy ME, Ksontini R, Boumghar M. Pulmonary sequestration: a review of 26 cases. *Eur J Cardiothorac Surg* 1998;14:127–33.
- Azizkhan RG, Crombleholme TM. Congenital cystic lung disease: contemporary antenatal and postnatal management. *Pediatr Surg Int* 2008;24:643–57.
- Mastrogiljo MG, Barone A, Disanto MG, Ginori A, Ambrosio MR, Carbone SF *et al.* Type II congenital airway malformation associated with intralobar pulmonary sequestration: report of a case and review of classification criteria. *Pathologica* 2016;108:38–41.
- Hirose R, Suita S, Taguchi T, Koyanagi T, Nakano H. Extralobar pulmonary sequestration mimicking cystic adenomatoid malformation in prenatal sonographic appearance and histological findings. *J Pediatr Surg* 1995;30:1390–3.
- Messinger YH, Stewart DR, Priest JR, Williams GM, Harris AK, Schultz P *et al.* Pleuropulmonary blastoma: a report on 350 central pathology-confirmed pleuropulmonary blastoma cases by the International Pleuropulmonary Blastoma Registry. *Cancer* 2015;121:276–85.
- Achiron R, Hegesh J, Yagel S. Fetal lung lesions: a spectrum of disease. New classification based on pathogenesis, two-dimensional and color Doppler ultrasound. *Ultrasound Obstet Gynecol* 2004;24:107–14.